

Contents lists available at [ScienceDirect](http://www.sciencedirect.com)**Acta Haematologica Polonica**journal homepage: www.elsevier.com/locate/achaem**Case report/Kazuistyka****Primary Hodgkin lymphoma of the nasopharynx:
Case report***Justyna Grela-Kowalik*^{1,*}, *Dariusz Zatoński*¹, *Tomasz Zatoński*²¹Department of Otorhinolaryngology Hospital, Zgorzelec, Poland²Department of Otolaryngology – Head and Neck Surgery Medical University of Wrocław, Poland

ARTICLE INFO

Article history:

Received: 16.01.2017

Accepted: 14.04.2017

Available online: 25.05.2017

Keywords:

- Hodgkin lymphoma
- Nasopharyngeal tumor
- Extranodal
- Primary location

ABSTRACT

Primary extranodal location of Hodgkin lymphoma is uncommon. We present a case of a 43-year old man with isolated Hodgkin disease localized in the nasopharynx who presented with a complaint of bilateral nasal congestion. Primary location of Hodgkin lymphoma (HL) in the non-lymphoid tissue is very uncommon and the primary isolated involvement of the nasopharynx has been described in 35 cases in the worldwide literature.

© 2017 Polskie Towarzystwo Hematologów i Transfuzjologów, Instytut Hematologii i Transfuzjologii. Published by Elsevier Sp. z o.o. All rights reserved.

Introduction

Primary extranodal location of Hodgkin lymphoma is uncommon. Hodgkin lymphoma formerly was called a cancer of the lymphatic system. Relates primarily a disease of the lymph nodes, extranodal sites are rare and usually concern lung, liver, bone marrow, kidney and skin. Very rarely figure outside of nodes is the first manifestation of the disease (0.25% of cases).

Lymphomas occupy the second place among head and neck cancer after squamous cell carcinoma. Hodgkin's lymphoma is approx. 4% total cancer head and neck in most cases, it involves lymph nodes [1]. The figure outside of nodes within the head and neck is very rare and applies lymphatic Waldeyer ring consisting of tonsils, throat, language, trumpet and throat follicles, lymph band of the rear wall the pharynx.

The etiology is not known to do end can play a role of EBV infection. Stands out 2 types of Hodgkin lymphoma: classic disease (with 4 subtypes) and disease of domination lymphocytes.

Hodgkin lymphoma of the nasopharynx is less than 1% total Hodgkin lymphoma. Most of the reported cases in the literature concern the stage I and II EA and after treatment with chemotherapy and radiation showed good results [2, 4].

In Poland every year recorded 1000 cases of Hodgkin lymphoma most people in the 20–30 years of age and after 50 years of age. The symptoms of lymphoma are non-specific, it is characteristic swollen glands in the neck, armpit, groin, as well as persistent fever, night sweats, fatigue, weight loss, pruritus, cough.

Diagnosis is based on histopathological examination, however, it is important to also interview and imaging studies, increasingly important PET, both in the diagnosis and monitoring of disease [1].

* Corresponding author at: Department of Otorhinolaryngology Hospital, Zgorzelec, Poland.

E-mail address: justynagrela@yahoo.com (J. Grela-Kowalik).

<http://dx.doi.org/10.1016/j.achaem.2017.04.001>

Case report

43-Year-old patient reported to the department because of the severity of symptoms in the form of nasal obstruction and impaired speech "nasal". The first symptoms occurred three years earlier. The lymphatic tissue from the back wall of oropharynx was biopsied and showed any cancerous changes (histopath.: inflammation chronic mucosae sine neoplasmate).

During this hospitalization endoscopic examination of the nasopharynx, stating vividly red, round tumor, filling almost all of the nasopharynx (Fig. 1) In addition, the laryngological examination there were no deviations from the norm. Chest X-ray: no focal lesions.

Computer tomography of the neck was performed which showed in the field nasopharynx soft tissue mass of polycyclic outline, well defined, with dimensions of $2.3 \times 2 \times 3.1$ cm. Lymph nodes of the neck and submandibular area are in diameter to 1 cm. In the mediastinum without lymphadenopathy (Figs. 2 and 3).

In connection with suspected hemangioma nasopharyngeal patient was referred to a reference center of oncology, where he has qualified for endoscopic surgery to remove the tumor. Because of major bleeding, biopsy of a tumor of the nasopharynx, and the histopathology showed fragments of lymphoid tissue-covered focal normal respiratory epithelium without tumor lesion.

Due to the lack of improvement in nasal obstruction two months later, the patient was qualified for endoscopic surgery to remove the tumor nasopharynx, uncomplicated postoperative course. Histopathological research showed the classical Hodgkin's lymphoma (a type of "lymphocyte - Rich"), immunophenotype cells Reed - Sternberg: CD 30+, CD15+, MUM 1+ 5 + PAX, Ki-67+, CD3-, CD20-, bcl2-, EBV-, LMP-Ab1-, PD1-, CD4-macroscopically; irregular, beige fragments of tissue, including of dimensions. $1.5 \text{ cm} \times 1.3 \text{ cm} \times 0.4 \text{ cm}$.

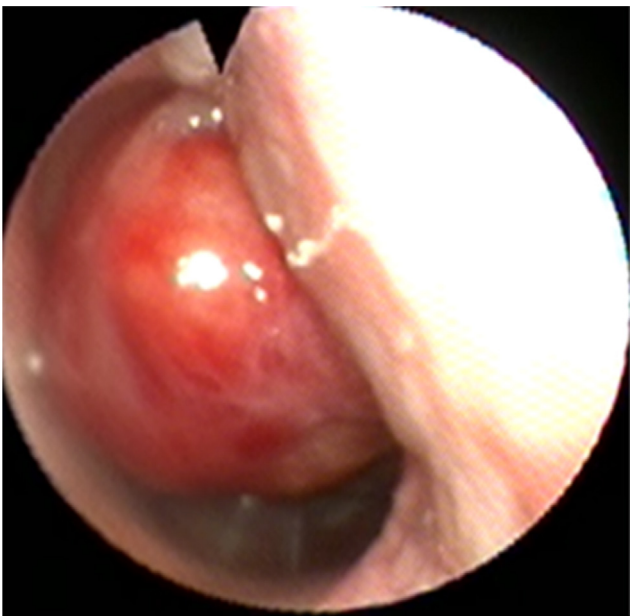

Fig. 1 – Endoscopy of the nasopharynx

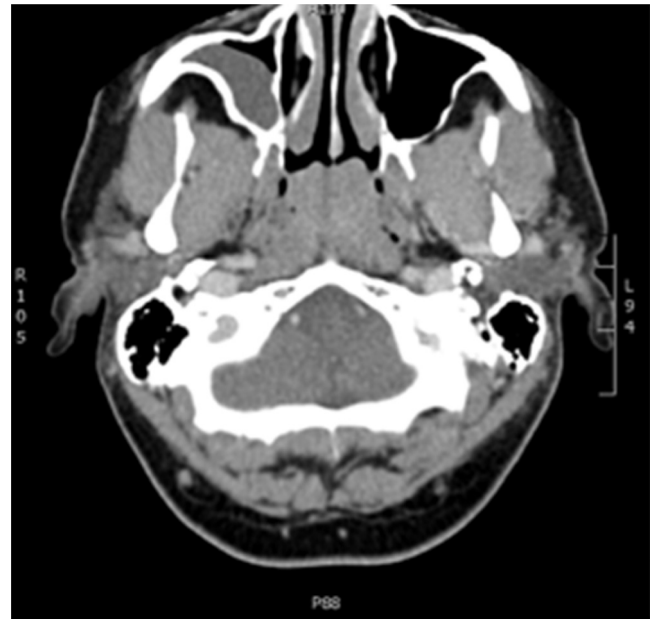


Fig. 2 – Computer tomography scan of the neck coronary projection

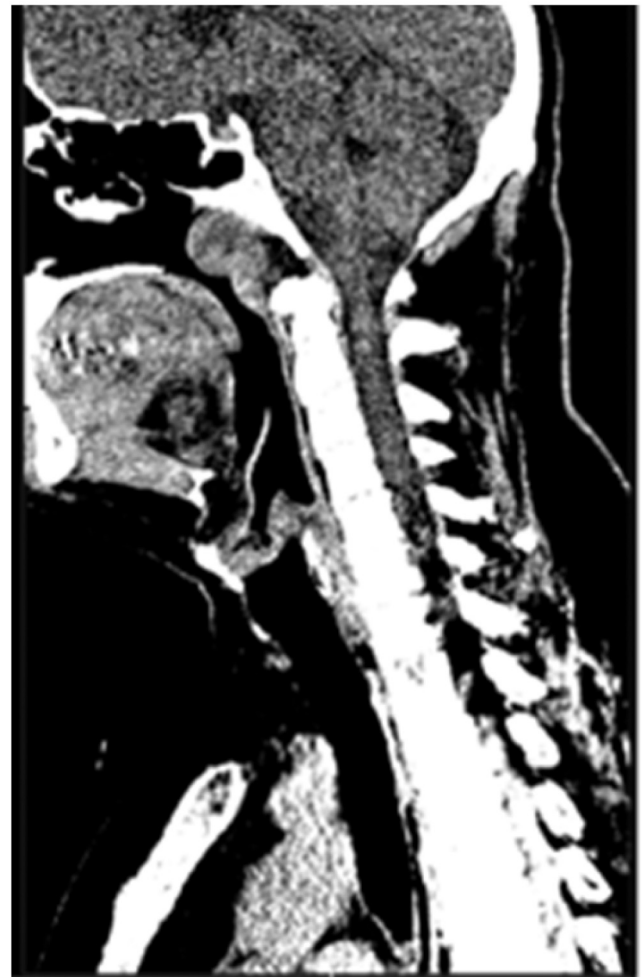

Fig. 3 – Computer tomography scan of the neck sagittal projection

PET before treatment with adjuvant showed no active infiltration HL.

The MR neck revealed no pathological structures within the nasopharynx only a single lymph nodes in a group 1a, 2a, 2b, 3 on Wed 0.5 cm.

As complementary treatment was used: 2 courses ABVD chemotherapy and radiotherapy IMRT photo 6 MeV.

Control double-PET within 24-months observation without active infiltration HL.

Discussion

Hodgkin's lymphoma nasopharyngeal cancer is rare and about 1% of Hodgkin's lymphomas. It occurs in patients young and middle-aged. World literature describes just over 100 cases of Hodgkin's lymphoma and nasopharyngeal only 35 cases of this form of insulation up to the nasopharynx, without nodal manifestations. Iyengar et al., in a retrospective analysis of 3500 patients with HL recorded in 40 years (1967–2007) reported only 34 patients with Hodgkin's lymphoma was originally located in the head and neck, and only 9 cases related to the nasopharynx [5].

In Poland, is described one case of 35-year-old woman with isolated Hodgkin's lymphoma nasopharyngeal [3]. Eavey and Goodman have identified 2 cases of Hodgkin's lymphoma within the nasopharynx of the 500 cases of Hodgkin's lymphoma localized in the head and neck. In studies Anselmo from 2150 cases of Hodgkin's lymphoma in the years 1977–2001, Hodgkin lymphoma was located in the nasopharynx in 7 patients, and only 1 patient was a form of insulation up to the nasopharynx [7].

Epstein-Barr virus is a known factor in the etiology of Hodgkin's disease, interesting is why the nasopharynx reservoir of EBV is not a common location for this tumor. Moreover, in most cases of Hodgkin lymphoma located in the nasopharynx not show the presence of EBV [8].

The most common subtype of Hodgkin's lymphoma nasopharyngeal is mobile mixed type. Important in differentiating types of lymphoma are immunohistochemical studies. In the treatment of Hodgkin's lymphoma departs from the same radiotherapy and therapies used complex chemotherapy (ABVD = Adriamycin, Bleomycin, Vinblastine, Dacarbazine), and radiation therapy and lymph nodes in the neck nasopharynx doses 20–50 Gy.

Most patients are young men with stage I, II with a good prognosis [2, 4].

Conclusions

Nasopharyngeal lymphoma is a very rare cancer of the nasopharynx, but should be considered in the differential in the case of tumors of the nasopharynx. Ambiguous results of imaging tests and stretch tend often to remove the tumor

in its entirety and diagnosis after histopathological examination, including immunostaining.

Lymphoma nasopharynx can imitate changes such as mononucleosis, NK-T cell lymphoma, T-cell/B-cell lymphoma. Accordingly, the immunohistochemical study is very important. Its objective is to correct diagnosis and rule out other lymphomas in that area [6].

Conflict of interest/Konflikt interesu

None declared.

Financial support/Finansowanie

None declared.

Ethics/Etyka

The work described in this article has been carried out in accordance with The Code of Ethics of the World Medical Association (Declaration of Helsinki) for experiments involving humans; EU Directive 2010/63/EU for animal experiments; Uniform Requirements for manuscripts submitted to Biomedical journals.

REFERENCES / PIŚMIENNICTWO

- [1] Owosho AA, Gooden CE, McBee AG. Hodgkin lymphoma of the nasopharynx: case report with review of the literature. *Head Neck Pathol* 2015;9:369–375.
- [2] Anselmo AP, Cavalieri E, Cardarelli L, Gianfelici V, Osti FM, Pescarmona E, et al. Hodgkin's disease of the nasopharynx: diagnostic and therapeutic approach with a review of the literature. *Ann Hematol* 2002;81:514–516.
- [3] Krzeska-Malinowska I, Moczyński B. Nasopharynx as a rare site of the first symptom of Hodgkin's disease. *Otolaryngol Pol* 1990;44:321–322.
- [4] Bensouda Y, El Hassani K, Ismaili N, Lalya I, Boutayeb S, Benjaafar N, et al. Primary nasopharyngeal Hodgkin's disease: case report and literature review. *J Med Case Rep* 2010;4:116. <http://dx.doi.org/10.1186/1752-1947-4-116>.
- [5] Iyengar P, Mazloom A, Shihadeh F, Berjawi G, Dabaja B. Hodgkin lymphoma involving extranodal and nodal head and neck sites: characteristics and outcomes. *Cancer* 2010;116:3825–3829.
- [6] Cencini E, Fabbri A, Lazzi S, Bocchia M. Primary nasopharyngeal Hodgkin lymphoma. *Head Neck Pathol* 2015;9(December (4)):536–537 [online 2015 Jun 25].
- [7] Eavey RD, Goodman MI. Hodgkin's disease of the nasopharynx. *Am J Otolaryngol* 1982;3:417–421.
- [8] Kapadia SB, Roman LN, Kingma DW, Jaffe ES, Frizzera G. Hodgkin's disease of Wladyer's ring. Clinical and histoimmunophenotypic findings and associations and association with Epstein-Barr virus in 16 cases. *Am J Surg Pathol* 1995;19:1431–1439.