

# DEVELOPMENT OF HIPPOCAMPUS MRI IMAGE SEGMENTATION ALGORITHM FOR PROGRESSION DETECTION OF ALZHEIMER'S DISEASE (AD)

MOHAMED AHMED GILANI MOHAMED

A project report submitted in  
partial fulfillment of the requirement for the award of the  
Degree of Master of Electrical Engineering

Faculty of Electrical and Electronic Engineering  
Universiti Tun Hussein Onn Malaysia

FEBRUARY 2022

To my beloved family, thank you.



## ACKNOWLEDGEMENT

Alhamdulillah, all praises to Allah for the strengths and the blessing in completing this project. This project would not have been possible without the guidance and the help of several individuals who in one way or another have contributed and extended their valuable assistance.

Given this valuable chance, I might want to offer my most sincere gratitude to my supervisor, Dr. Wan Mahani Hafizah Binti Wan Mahmud for her help and unending assistance on this investigation despite being incredibly occupied with her undertaking's projects, she directs me through this project with counsel and feedbacks. I might likewise want to express gratitude toward her for her direction which was a striking power that empowered me to effectively finish this project. Her guidance, encouragement, and suggestions provided me necessary insight into the project and paved the way for the meaningful ending of this thesis.

Besides, I owe my family a debt of gratitude for all the support along the period of the project. To the soul of my mother that was pushing me going forward in any frustration or breakage. This journey would not have been possible without the support of my family, especially my father who always stood back and keep supporting me through my studies, and to my biggest, the grandmother with her prayers and their endless support. Last but not least, I would like to thank my friends for giving me their help, inspiration, and also interminable assistance and exhortation all through this project.

## ABSTRACT

Alzheimer's disease is becoming one of the most serious ailments that people face. Alzheimer's disease primarily affects those over the age of 65. is defined by the death of brain cells, which results in memory loss. as well as a lack of judgment, linguistic abilities, and decision-making capability Furthermore, no research has been conducted on developing a monitoring system for Alzheimer's disease that can continuously monitor Alzheimer's patients to identify any signs of development. Current research focuses mostly on early diagnosis and does not include disease monitoring. Monitoring is critical since it allows doctors to assess the disease development of Alzheimer's patients quantitatively. This study indicates developing an algorithm for detecting and progressing through the hippocampus of patients with Alzheimer's disease in MRI images. The active contour method (Chan-Vese) was utilized to extract the ROI parameters (hippocampus). The active contours algorithm deforms an item's initial border in an image to latch onto typical features inside the region of interest given an approximation of the object's perimeter. This is constantly stretched until it reaches the ROI's boundary. The interactive area selection approach is used to allow the user to determine the ROI depending on their needs. The algorithm will be applied once the ROI has been specified. The algorithm will be able to identify the parameters, such as the number of pixels, area pixels, and mean value, by extracting the hippocampal shape. The extraction of parameters will allow us to determine the extent of the patient's Alzheimer's progression. As a result, the study was successful in developing a semi-automated and robust model based on the Chan-Vese segmentation methodology, where it could observe the shrinking of the patient brain by the progression method using the total pixels of the hippocampus and its area by getting decreased at the second visit, one of the results showed at the first visit the total number of the pixels was 707 then at the second visit it shows 650 so the progression percentage 9%, and the proposed method produced promising segmentation results. In addition, a graphical user interface (GUI) was created to identify the progression percentage. As a future plan, this project can use machine learning to train the data for auto-detection for the hippocampus which will be significantly robust and more effective.

## ABSTRAK

Penyakit Alzheimer menjadi salah satu penyakit paling serius yang dihadapi oleh orang ramai. Penyakit Alzheimer terutamanya memberi kesan kepada mereka yang berumur lebih dari 65 tahun. Perkara ini ditakrifkan sebagai kematian sel-sel otak yang mengakibatkan kehilangan ingatan serta kekurangan pertimbangan, kebolehan linguistik, dan keupayaan membuat keputusan. Tambahan pula, tiada penyelidikan dijalankan bagi membangunkan sistem pemantauan penyakit Alzheimer yang mampu memantau pesakit Alzheimer secara konsisten bagi mengenal pasti sebarang tanda perkembangan. Kebanyakan penyelidikan semasa tertumpu pada diagnosis awal dan tidak termasuk pemantauan penyakit. Pemantauan adalah penting kerana ia membolehkan doktor menilai perkembangan penyakit pesakit Alzheimer secara kuantitatif. Kajian ini menunjukkan dengan membangunkan algoritma untuk mengesan dan memantau melalui *hippocampus* pesakit dengan penyakit Alzheimer dalam imej MRI. Kaedah kontur aktif (Chan-Vese) telah digunakan untuk mengekstrak parameter ROI (*hippocampus*). Algoritma kontur aktif mengubah bentuk sempadan awal item dalam imej untuk diselak pada ciri tipikal di dalam kawasan yang penting berdasarkan anggaran perimeter objek. Ia sentiasa diregangkan sehingga mencapai sempadan ROI. Pendekatan pemilihan kawasan interaktif digunakan untuk membolehkan pengguna menentukan ROI berdasarkan keperluan mereka. Algoritma akan digunakan setelah ROI ditentukan. Algoritma akan dapat mengenal pasti parameter seperti bilangan piksel, piksel kawasan dan nilai min dengan mengekstrak bentuk *hippocampal*. Pengekstrakan parameter akan membolehkan kita menentukan tahap perkembangan Alzheimer pesakit. Hasilnya, kajian ini berjaya membangunkan model separa automatik dan teguh berdasarkan metodologi segmentasi Chan-Vese, di mana ia dapat memerhatikan pengecutan otak pesakit dengan kaedah perkembangan menggunakan jumlah piksel *hippocampus* dan kawasannya. dengan mendapat penurunan pada lawatan kedua, salah satu keputusan menunjukkan pada lawatan pertama jumlah bilangan piksel adalah 707 kemudian pada lawatan kedua menunjukkan 650 jadi peratusan kemajuan 9%, dan kaedah yang dicadangkan menghasilkan keputusan segmentasi yang menjanjikan. Selain itu, antara muka pengguna grafik (GUI) telah dicipta untuk mengenal pasti peratusan.

## TABLE OF CONTENTS

ACKNOWLEDGEMENT	I
ABSTRACT	II
ABSTRAK	III
TABLE OF CONTENTS	IV
LIST OF FIGURES	VII
LIST OF TABLES	1
LIST OF SYMBOLS AND ABBREVIATIONS	2
CHAPTER 1 INTRODUCTION	3
1.1 Background of Project	3
1.2 Problem Statement	4
1.3 Aim of The Project	4
1.4 Objectives	5
1.5 Project Scope	5
1.6 Report Outline	5
CHAPTER 2 LITERATURE REVIEW	6
2.1 Introduction	6
2.2 Alzheimer	6
2.2.1 What is Alzheimer's disease	6
2.2.2 Detecting of Alzheimer's disease	7
2.2.3 Alzheimer's Disease Neuroimaging Initiative (ADNI)	8
2.2.4 Magnetic Resonance Imaging (MRI)	9
2.3 Image processing	10
2.3.1 Pre-Image Processing	10



PTTA UTHM

PERPUSTAKAAN TUNKU TUN AMINAH

2.3.2 MRI Slicing	10
2.3.3 Filtering Process	11
2.3.4 Segmentation Process	13
2.3.5 Progression detection and its validity	15
2.4 Summary	16
<b>CHAPTER 3 PROJECT METHODOLOGY</b>	<b>17</b>
3.1 Introduction	17
3.2 Project and methodology flowchart	17
3.3 Data Acquisition	19
3.4 Data processing	19
3.4.1 Pre-processing	19
3.4.2 Filter process	20
3.4.3 Segmentation process	20
3.5 Development of the Graphical User Interface (GUI)	22
<b>CHAPTER 4 RESULTS AND DISCUSSION</b>	<b>23</b>
4.1 Introduction	23
4.2 Image Filtering	23
4.3 Segmentation process	26
4.4 Progression detection parameters	27
4.5 Result for GUI development	29
<b>CHAPTER 5 CONCLUSION AND FUTURE WORK</b>	<b>30</b>
5.1 Overview	30
5.2 Conclusion	30
5.3 Future work	30
<b>REFERENCE</b>	<b>32</b>
<b>APPENDIX A</b>	<b>39</b>
<b>APPENDIX B</b>	<b>40</b>
<b>APPENDIX C</b>	<b>41</b>
<b>APPENDIX D</b>	<b>44</b>





## LIST OF FIGURES

Figure 2.1	Hippocampus in the brain and its position	7
Figure 3.1	Flowchart for the overall project	12
Figure 3.2	Segmentation process	18
Figure 3.3	GUI front page	22
Figure 4.1	Median filter	23
Figure 4.2	Contrast Limited Adaptive Histogram Equalization filter	24
Figure 4.3	Histogram Equalization filter	24
Figure 4.4	Gaussian filter	25
Figure 4.5	: Segmented image.	26
Figure 4.6	Middle part	26
Figure 4.7	ROI selection	27
Figure 4.8	Interface page of the system	29



## LIST OF TABLES

Table 2.1	Summary of some types of filters.	12
Table 2.2	Summary of segmentation techniques [24]	14
Table 4.1	The values of MSE and PSNR	25
Table 4.2	MR Images segmented	27



## LIST OF SYMBOLS AND ABBREVIATIONS

AD	–	Alzheimer’s Disease
ADNI	–	Alzheimer’s Disease Neuroimaging Initiative
MTL	–	Medial Temporal Lobe
GUI	–	Graphical User Interface
MRI	–	Magnetic Resonance Imaging
MSE	–	Mean Squared Error
PSNR	–	Peak signal-to-noise ratio
VoI	–	Variation of Information
AC	–	Active Contour
MCI	–	Mild Cognitive Impairment
ROI	–	Region of Interest
CLAHE	–	Contrast Limited Adaptive Histogram Equalization
RH	–	Right Hippocampus
LH	–	Left Hippocampus
PA	–	Patient



## CHAPTER 1

### INTRODUCTION

#### 1.1 Background of Project

Alzheimer's disease has become one of the most common illnesses that individuals endure. Alzheimer's disease typically affects those above the age of 65. It is a form of dementia caused by a neurodegenerative disorder [1]. Alzheimer's disease is caused by the death of brain cells resulting in memory loss. The disease progresses through various phases, from mild to moderate to severe. The illness begins off mild and worsens over time. This illness is classified into three stages: mild, moderate, and severe. When the disease has advanced to the next stage, the most common early sign is short-term memory loss.

Alzheimer's patients have significant memory loss, as well as loss of judgment and linguistic skills. The patient will also be lost reasoning ability and decision-making ability. In the later stages of Alzheimer's disease, patients will not understand or use speech to communicate even basic things. They will still be unable to identify others, including relatives[2].

Implementation of the latest technology into the development of a computerized diagnostic system is not new. Many previous researchers have looked at this issue utilizing various advanced tools. However, there is yet to be any study on building a monitoring system for Alzheimer's disease that can continually monitor Alzheimer's patients to identify any progression signs. However, for such a system to be developed, a thorough investigation needs to be performed on the AD data from multiple patient visits to the hospital. Therefore, this study would like to develop an algorithm for segmenting the brain hippocampus from MRI images to detect AD progression. To develop such an algorithm, specific image processing, and analysis techniques will be performed to segment the hippocampus of brain MRI images taken from the ADNI database. All processing and analysis techniques in this study will be performed using MATLAB software. Finally, it is hoped that by the end of this study,

a new algorithm for segmenting and detecting the progression of AD based on MRI images will be successfully developed and optimized. Eventually, the discovery of this study may lead to the development of a system that could be used to monitor the progression of AD worldwide.

## **1.2 Problem Statement**

The advanced technology and approaches towards developing early detection and diagnosis system of Alzheimer's Disease (AD) have been progressively explored to assist medical doctors performing their job [3]. However, current research mainly focuses on the early diagnosis and does not involve monitoring the disease. Early diagnosis is critical because treatment can be done as soon as possible to limit or even prevent disease development.

Monitoring is also crucial as it could help medical practitioners carefully evaluate AD patient disease progression quantitatively[4]. Segmentation of the hippocampus, which is considered as diffuse brain atrophy, which includes atrophy of the cerebral cortex, and atrophy of the medial temporal lobe (MTL) components, is a significant pathogenic feature of Alzheimer's disease that can play a critical role in the accuracy of detecting or progression of the disease [5]. Then, a segmentation algorithm could be built to investigate the progression of the disease from time to time.

This study proposes to formulate an algorithm to be used for MRI images of patients with AD to accurately detect and progress through the hippocampus of AD in MRI images.

## **1.3 Aim of The Project**

This project aims to investigate and develop an algorithm for the segmentation of hippocampus MRI images for Alzheimer's disease to assess the performance of the developed algorithm.

## 1.4 Objectives

The objectives of this project are:

1. To investigate the image processing techniques available to search for the best method for developing the hippocampus MRI image segmentation algorithm.
2. To develop of hippocampus MRI image segmentation algorithm.
3. To develop a Graphical User Interface (GUI) to detect the progression of Alzheimer's Disease.

## 1.5 Project Scope

The scope mainly is:

- i. Collecting and selecting the data set made based on the data from Alzheimer's Disease Neuroimaging Initiative (ADNI) with patients' multiple visits to the hospital (<http://adni.loni.usc.edu/>).
- ii. The experiment has been tested on 10 patients with a specified images range
- iii. MATLAB was used as the main software for this project.

## 1.6 Report Outline

Chapter 1 gives a general introduction to the project, problem statements, objectives, and project scope. Subsequently, it details the goal of this project in objectives, followed by the project's problem statement and the project's scope.

Chapter 2 covers the literature review that explained the importance of image processing techniques, including image pre-processing, image segmentation, and the most used methods that describe and intend to diagnose Alzheimer's disease based on the ADNI database and related work with this project.

Chapter 3 presents the methodology of the project that will explain all methods to complete the project. It includes a flow chart and a detailed explanation.

Chapter 4 presents the results and its discussion.

Chapter 5 discusses some conclusions and future work on this project.

## CHAPTER 2

### LITERATURE REVIEW

#### 2.1 Introduction

This chapter attempts to review the relevant literature and research related to the technique of image processing and Alzheimer's disease overview.

#### 2.2 Alzheimer

##### 2.2.1 What is Alzheimer's disease

Alzheimer's disease is a form of neurodegenerative dementia. The illness causes two regions of the brain to shrink and the ventricles to expand in the brain. The hippocampus and cerebral cortex are the two components that are involved. The cytoskeletal alterations in Alzheimer's disease are extensively spread, and the medial temporal lobes and neocortical association regions are severely damaged. It is critical to understand how the disease begins and progresses to create therapeutic measures targeted towards prevention [6].

Alzheimer's disease cannot be cured, although the progression of the illness can be reduced. As a result, early detection is critical. Figure 1 displays the hippocampus and cerebral cortex position in the brain through MR[7].

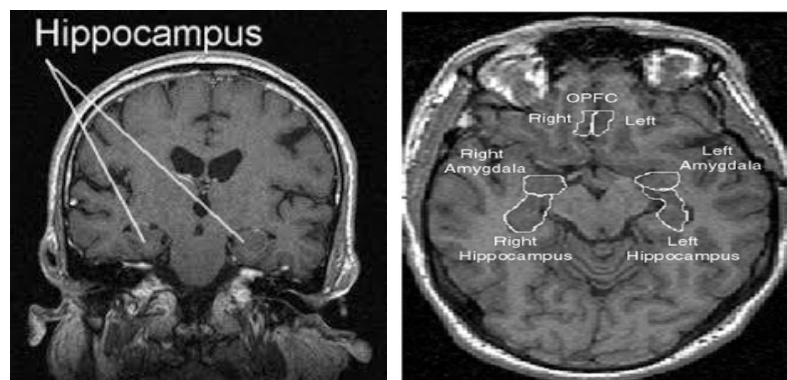


Figure 2.1 Hippocampus in the brain and its position

### 2.2.2 Detecting of Alzheimer's disease

Damage to the hippocampus and cerebral cortex affects the brain area responsible for judgments, planning, reasoning, and remembering [3]. The pathological progression of Alzheimer's disease is generally accompanied by structural changes that begin with the entorhinal cortex and hippocampus inside the temporal lobe of the brain, followed by neocortical regions. The temporal lobe of the brain, especially the medial temporal lobe (MTL) structures, plays an important role in the consolidation of information and the formation of short-term and long-term memory [8]. The hippocampus, which sits through the length of the MTL and belongs to the limbic system, is a significant component of the memory circuitry and is one of the first regions to be affected by AD [9].

In addition. The size or volume of hippocampal assessing for the detecting AD, The Hippocampal volumes has a volume of 3.48 (0.43) and the right had a volume of 3.68 (0.42). There were some There weren't significant variations in hippocampus volume between males and females ( $p > .05$ ). additionally. The improvements are aimed at giving a thorough volumetric assessment of the hippocampus. Changes in hippocampus morphology may be analyzed using the tracing procedure we developed. [10]

Alzheimer's disease is classified into three stages: mild, moderate, and severe. There are several categorization techniques available for the automated diagnosis of Alzheimer's disease. Bayes classifiers, random forests, support vector machines, and neural networks are among the approaches used. These techniques can only identify the existence of the disease but cannot provide precise information on the disease's phases [11]. There are other statistical approaches and machine learning algorithms



available to assist in the diagnosis of Alzheimer's disease [12]. Before this, researchers detect Alzheimer's disease by using Electroencephalogram (EEG) signal and doing pre-process [13]. Researchers utilize a filtering method in Simulink to eliminate unwanted noise. There is also a deep learning method, which is a modern branch of machine learning that is inspired by the human brain [14]. To resolve how the disease begins and progresses, longitudinal follow-up of individuals starting at a pre-symptomatic level using in-vivo techniques is needed. Previous studies used patients with mild cognitive disabilities to do this. Furthermore, because these people do not meet the criterion for Alzheimer's disease, they already have signs of the disease. The offspring of patients with autosomal dominant hereditary Alzheimer's disease is another population of people that may be observed longitudinally with a reasonable probability of detecting the disease's early symptoms[6]. The right hippocampus plays a critical role in spatial memory in older adults, while the role of the left hippocampus in verbal memory is more prominent[15].

### **2.2.3 Alzheimer's Disease Neuroimaging Initiative (ADNI)**

The National Institute on Aging (NIA), the National Institute of Biomedical Imaging and Bioengineering (NIBIB), the Food and Drug Administration (FDA), commercial pharmaceutical corporations, and non-profit groups formed the ADNI in 2003 as a \$60 million, five-year public-private cooperation. The major objective of ADNI has been to determine if serial Magnetic Resonance Imaging is effective (MRI). It can be used to track the emergence of moderate cognitive impairment (MCI) and the early stages of Alzheimer's disease (AD). Identification of sensitive and specific indicators of Alzheimer's disease in its early stages. The progression is designed to assist researchers and doctors in their efforts to improve.[16]. Experts and datasets from studies are brought together by the Alzheimer's Disease Neuroimaging Initiative (ADNI) in an effort to better understand the progression of Alzheimer's disease. Scientists at the ADNI gather and verify data from several sources, including MRI and PET scans, genetic testing, cognitive tests, CSF, and biomarkers in the blood. Participants in the North American ADNI project, which included Alzheimer's disease patients, moderate cognitive impairment persons, and older controls, supplied data. Alzheimer's disease (AD) is the sixth leading cause of death in the United States, affecting more than half

of those over the age of 85. Biomarkers, including blood tests, testing of cerebrospinal fluid (CSF), and MRI/ PET imaging have been validated since 2005 by the Alzheimer's Disease Neuroimaging Initiative (ADNI). Adverse effects of Alzheimer's disease may be prevented, treated, or even cured if new research is facilitated by ADNI's extraordinary data access policy. ADNI, with its established, defined methodologies for imaging and biomarker collection and analysis, enables scientists to perform coherent research and exchange consistent data with other researchers across the world [17].

#### **2.2.4 Magnetic Resonance Imaging (MRI)**

Magnetic Resonance Imaging (MRI), a radiological imaging technique, was created following the abandonment of ultrasound. It was widely utilized for imaging-based brain tumor identification. The magnetic resonance imaging (MRI) technique is used to produce a detailed image of a human bodily organ. Magnetic resonance imaging is another name for it. Radio waves and high magnetic fields are being utilized to examine bodily areas that were previously inaccessible by X-rays, CT-Scans, or ultrasounds. MRI makes use of a powerful magnetic field and radio waves to produce high-resolution pictures of inside organs and tissues. Since its inception, MRI methods have been refined by physicians and researchers to aid in medical treatments and scientific study [18].

Moreover, the basic structure of MRI utilizes the fact that protons have angular momentum, which is polarised in a magnetic field. This means that a pulse of radiofrequency can alter the energy state of protons. When the pulse is turned off, the protons will return to their energy stage and emit a radiofrequency signal. Combining different gradients and pulses, “sequences” can be designed to be sensitive to other tissue characteristics. In broad terms, structural MRI in AD can be divided into assessing atrophy (or volumes) and changes in tissue characteristics that cause signal alterations on certain sequences, such as white matter hyperintensities on T2-weighted MRI resulting from vascular damage. Magnetic resonance imaging (MRI) has been proved to be very useful in assessing pathological tissues in AD [19]. Structural magnetic resonance (MR) imaging can identify disease-induced structural changes in the brain, assisting in the diagnosis of Alzheimer's disease. For the AD classification

challenge, MR image characteristics derived from hippocampus regions are typically employed [8].

### **2.3 Image processing**

The term "image processing" encompasses a wide range of techniques and mathematical operations performed on images. Digital images may be adapted or touched by modifying the way they're built mathematically. Applied to two-dimensional image arrays, image processing is one of the digital signal processing methods. Image processing may be used for a variety of purposes, including improving the visual appeal of an image and making it easier to understand it when it's too confusing or noisy. As a result of many elements such as the environment, equipment, and other noise sources, certain forms of additives may be removed from images via the use of image processing. As a result, it has also been used to extract relevant information from images that may be utilized for various reasons in the future.

#### **2.3.1 Pre-Image Processing**

Image processing is information processing in which the input and output are images [20]. Magnetic Resonance Imaging (MRI) provides a clear picture of diseased regions. Noises in obtained medical images can cause image creation to be blurry, making it harder for specialists to diagnose patients. It will use conventional signal processing techniques to 2D images in image processing.

Using medical image processing technologies, it is possible to improve, offer additional information, and speed up the interpretation of medical pictures. Furthermore, image filtering and edge detections are critical processes in image processing and analytic preparation [20].

#### **2.3.2 MRI Slicing**

Analyze7T format is used to store the entire MRI image length. micro software loads the volume into the process. The image depicts how the MRI appears as it is loaded into the software. The image shows a coronal view of the rat brain, simply one slice of

a brain MRI was taken from front to back. In this experiment, can just look at the MRI's coronal view. So using the MRICro software to save only the coronal view of the MRI volume into 176 different slices [21].

Preprocessing the image data involves layer-by-layer scanning in order to create a 3D image, therefore the opposite procedure is performed which is, MRI images are preprocessed by layering (slicing) them up from the bottom of the head to the top [22].

### 2.3.3 Filtering Process

Various types of filters are used in image processing. Some filters include Median, Wiener, CLAHE, Histogram Equalization, and Gaussian Low Pass filter. They may boost the contrast Images that have been converted to grayscale still have a low contrast level. Grayscale image processing using the Histogram Equalisation technique can improve image contrast. Semantic image content filtering (SICF) is a novel filtering approach. This filter tries to maintain the image's basic structure while removing unimportant minor features. Filters may also be used to decrease image noise, remove haze, and mat images, among other purposes [23]. For the enhancement phase, Matched filter (MF), Frangi's filter (FF), Gabor wavelet filter (GF) are used in combination for combination purposes weighted mean and median ranking is used, and for segmentation fuzzy c-means, ORSF to optimize threshold is used. MF enhances vascular structures by convolution, GF improves by calculating eigenvalues that represent vascular structures, GF enhances small vessels as it is less sensitive to noise [24]. A researcher visualized the filters' capabilities in medical image edge detection, which aids in diagnosing Alzheimer's disease using MRI images. The noise efficiency of these filters was investigated after the inclusion of random Gaussian noise and salt and pepper noise. The PSNR and MSE of the detected images and the spectral efficiency of each filter were analytically compared [25]. PSNR is defined as the signal's maximum potential power ratio to the noise's maximum possible power. The PSNR value is shown using a logarithmic decibel scale [26]. The PSNR value is calculated as follows Equation. Mean Squared Error (MSE) between two images such as  $I(x,y)$  and  $K(x,y)$ , is defined as:

$$MSE = \frac{1}{MN} \sum_{i=0}^{m-1} \sum_{j=0}^{n-1} [I(i,j) - K(i,j)] \quad (1)$$

From Equation (1), we can see that MSE is a representation of the absolute error.

$$PSNR = 20 \log_{10}(MAX I) - 10 \log_{10}(MSE) \quad (2)$$

Here, *MAX I* (Peak Value) is the maximal in the image data. If it is an 8-bit unsigned integer data type, the peakval is 255 [8]. From Equation (3), we can see that it is a representation of absolute error in dB. [27]

The filter's output is seen to vary based on the type of noise applied to the picture. These comparisons may be used to determine which fractional filter to be used for edge detection [28]. Table 2.1 shows a summary from some researchers on the filtering process.

Table 2.1 Summary of some types of filters.

Year or journal	Filter type	Remark
[29][30]	Contrast Limited Adaptive Histogram Equalization (CLAHE)	If some grey levels in the image exceed the threshold, the excess is evenly distributed to all grey levels. After this processing, the image will not be over-enhanced, and the problem of noise amplification can be reduced.
[29]	Isotropic Gaussian kernels are used for smoothing	Smoothed images can be used to determine the local volume of various tissues to compare variations across groups (such as grey matter and white matter)
[31]	The histogram	To enhance the signal-to-noise ratio of the texture output and to shorten the computation time of matrix-based texture characteristics
[24]	The Laplacian	After obtaining several image scales, 3D Otsu is used to produce segmentation maps.
[32]	Gaussian filters	Intending to maintain edge detail, the filter chooses pixels that are comparable to the pixel being corrected and applies a weighted average function within a tiny defined region. Denoising is also performed using Gaussian filters.

### 2.3.4 Segmentation Process

The most important role of image analysis is image segmentation, and processing involves image segmentation. The results of segmentation have a major influence on all following image processing operations, such as object representation and definition, attribute measurement, and even higher-level tasks like object classification.

As a result, image segmentation is crucial, and the delineation, characterization, and simulation of regions of interest in every medical image is a key procedure [24]. Its goal is to simplify and make visual analysis easier. As a result, the method is designed to make it easier to remove the suspicious areas from the MRI [33]. The process can be done by setting the threshold to be segmented. Some people have achieved good segmentation results utilizing improving the region growth method [34]. Once the ROI is decided upon and located, then selection and application of segmentation algorithms are made.

Various proposed segmentation algorithms have their corresponding application areas, but they help detect anatomical structures' automatic delineation [35][36].

An iterative brain tumor segmentation strategy based on the Chan and Vese model was proposed in a study to locate and segment tumors from brain MRI data. The importance of this suggested technique is that it can be simply modified using assigned iterations to develop a strong and independent segmentation framework[37]. The chan-veese model can detect objects with borders that aren't always defined by gradient by minimizing energy, which is a special form of the minimal partition problem. The problem becomes a "mean-curvature flow"-like evolving the active contour, which will halt on the appropriate boundary in the level set formulation[38], interior contours are automatically recognized, and the initial curve can be anywhere in the image[39].

The hippocampus can be segmented using both the K-Means Clustering and Watershed techniques. However, the K-Means Clustering method yields more segmented items[40].

The segmentation algorithms which automate the radiological tasks are referred to as medical image segmentation algorithms [36]. Table 2.2 below shows a summary of some segmentation techniques.

Table 2.2: Summary of segmentation techniques [24]

	Types	Advantages	Disadvantages
Threshold	Local Thresholding	Ease of Implementation No need for prior information	Produces noisy and blurred edges
	Otsu's Method	Minimizes inter-class adianta-class variations. No histogram shape was considered prior.  Extendable to multi-level thresholding.	Creation of binary classes in grey-level images. Increase in complexity with an increase in levels of the threshold. Regions might get merged or mixed.
	Gaussian Mixture Approach	Used for generalization of histogram-based problems. Minimizes classification error probability. preferred for small-size classes.	All histograms don't follow the Gaussian model. Resulting in intensities that are finite and non-negative. Difficult for flat models. Simplified approach for multi thresholding
Region-Based	Region Growing	Based on similarity and immune to noise. Convenient and easy computation.	Seed point specification. Generation of holes in sensitive regions. Costly approach.
	Region Merging and Splitting	Splitting an image on-demand resolution. Follows quad-tree approach, fast and efficient. Splitting is done by calculating the mean, variance of the segment pixel value. Less noise generation Merging is different from the splitting technique.	May result in blocky segments.
Edge Based/ Boundary Based	Edge Detection	Selects a large region in an image. Used for images with uneven illumination.	Applicability for simplified backgrounds. May form closed contours all the time.
	Laplacian of Gaussian (LoG)	Detection of blurry edges, sharp focused fine detail. Effective detection of edge orientation.	Difficulty in working at corners. Finding orientation by Laplacian filter is difficult
	Watershed	Reduces over-segmentation. Separation of overlapping objects. Fast and reliable output.	Time-consuming and gradient-based.
	Active contour	The contour is adjusted until it fits the boundaries of the region of interest.	The accuracy of the active contour algorithm depends on the initial choice of the approximate form and initial position.[41]
Clustering	K-Means/Iso-data algorithm	Fast and easier to implement. Reduces the number of clusters and cluster variability.	should know a-prior no. of clusters. Sensitive to selection and initialization of centroids.
	Fuzzy C-Means algorithm	Unsupervised & considers vagueness, uncertainty in an image.	An optimal solution is undefined. Initialization is sensitive. Least compatible for noisy images

Several tests could be applied to studies of reproducibility, accuracy, and efficiency in image segmentation. Such as Hausdorff distance to measures the distance between the boundaries of two regions [42], Automated probabilistic fractional MR image segmentation, and manual segmentation were evaluated using the Dice similarity coefficient (DSC) which is a statistical validation metric[43].

As the average conditional entropy of one given the other equals the distance between two segments, the Variation of Information (VoI) measure roughly assesses the fraction of unpredictable behavior in one that cannot be described by the other. Better result, by the lower value of VoI [44].

Another study proposed ASM+D to extract the Hippocampus using the static model, ASM (Active Shape Model). used the distance between the two hippocampi as a priori knowledge. [45].

The Variation of Information (VoI) measure approximates the fraction of unpredictability in one that cannot be explained by the other by defining the distance between two segments as the average conditional entropy of one given the other. The lower the value of the VoI, the better the outcome[9].

Moreover, a study proposed the Chan-Vese active contour without edges approach, which is one force decreases the contour while another force expands it. When the contour approaches the border of our interest items, these two pressures are balanced, allowing us to identify the contour of the object, resulting in exact segmentation. The algorithm's effectiveness has been evaluated and validated using diverse brain MRI scans. The suggested technique may successfully detect and segment abnormalities as well as their geometrical dimensions[46].

### **2.3.5 Progression detection and its validity**

A regression analysis of time versus Blessed score was used to assess the pace of advancement for each individual, as follows, The initial visit was labeled as time zero, and each successive visit was recorded as the number of months after the initial visit. Alzheimer's disease progresses at a varied and frequently unpredictable rate [47].

The disease is distinguished by gradual cognitive loss as well as behavioral and motor performance abnormalities to more properly define and anticipate the overall



## REFERENCE

- [1] I. M. Tabakis, M. Dasygenis, and M. Tsolaki, "A monitoring system for people living with Alzheimer's disease," *4th Panhellenic Conf. Electron. Telecommun. PACET 2017*, vol. 2018-Janua, pp. 1–4, 2017, doi: 10.1109/PACET.2017.8259985.
- [2] N. B. Lokam and D. Yakob, "an Approach Towards Development of Pmv," *Int. J. Smart Sens. Intell. Syst.*, vol. 3, no. 4, p. 2010, 2010.
- [3] I. Bhushan, M. Kour, G. Kour, S. Gupta, S. Sharma, and A. Yadav, "Annals of Biotechnology Alzheimer ' s disease : Causes & treatment – A review," vol. 1, no. 1, 2018.
- [4] R. K. Lama, J. Gwak, J. S. Park, and S. W. Lee, "Diagnosis of Alzheimer's Disease Based on Structural MRI Images Using a Regularized Extreme Learning Machine and PCA Features," *J. Healthc. Eng.*, vol. 2017, no. 1, 2017, doi: 10.1155/2017/5485080.
- [5] N. Yamanakkanavar, J. Y. Choi, and B. Lee, "MRI segmentation and classification of human brain using deep learning for diagnosis of alzheimer's disease: A survey," *Sensors (Switzerland)*, vol. 20, no. 11, pp. 1–31, 2020, doi: 10.3390/s20113243.
- [6] N. C. Fox, W. R. Crum, R. I. Scahill, J. M. Stevens, J. C. Janssen, and M. N. Rossor, "Imaging of onset and progression of Alzheimer's disease with voxel-compression mapping of serial magnetic resonance images," *Lancet*, vol. 358, no. 9277, pp. 201–205, 2001, doi: 10.1016/S0140-6736(01)05408-3.
- [7] S. Sarraf, D. DeSouza, J. Anderson, and G. Tofighi, "DeepAD: Alzheimer's Disease Classification via Deep Convolutional Neural Networks using MRI and fMRI," *bioRxiv*, no. January 2017, p. 070441, 2016, doi: 10.1101/070441.
- [8] L. R. Squire and S. Zola-Morgan, "The medial temporal lobe memory system," *Science (80-. )*, vol. 253, no. 5026, pp. 1380–1386, 1991, doi:

10.1126/science.1896849.

- [9] S. F. Eskildsen, P. Coupé, D. García-Lorenzo, V. Fonov, J. C. Pruessner, and D. L. Collins, “Prediction of Alzheimer’s disease in subjects with mild cognitive impairment from the ADNI cohort using patterns of cortical thinning,” *Neuroimage*, vol. 65, pp. 511–521, 2013, doi: 10.1016/j.neuroimage.2012.09.058.
- [10] T. L. McHugh *et al.*, “Hippocampal volume and shape analysis in an older adult population,” *Clin. Neuropsychol.*, vol. 21, no. 1, pp. 130–145, 2007, doi: 10.1080/13854040601064534.
- [11] M. S. Rafii and P. S. Aisen, “The search for Alzheimer disease therapeutics — same targets, better trials?,” *Nat. Rev. Neurol.*, vol. 16, no. 11, pp. 597–598, 2020, doi: 10.1038/s41582-020-00414-3.
- [12] S. El-Sappagh *et al.*, “Alzheimer’s disease progression detection model based on an early fusion of cost-effective multimodal data,” *Futur. Gener. Comput. Syst.*, vol. 115, pp. 680–699, 2021, doi: 10.1016/j.future.2020.10.005.
- [13] P. Thakare and V. R. Pawar, “Alzheimer disease detection and tracking of Alzheimer patient,” *Proc. Int. Conf. Inven. Comput. Technol. ICICT 2016*, vol. 1, no. 2007, 2016, doi: 10.1109/INVENTIVE.2016.7823286.
- [14] V. Sathiyamoorthi, A. K. Ilavarasi, K. Murugeswari, S. Thouheed Ahmed, B. Aruna Devi, and M. Kalipindi, “A deep convolutional neural network based computer aided diagnosis system for the prediction of Alzheimer’s disease in MRI images,” *Meas. J. Int. Meas. Confed.*, vol. 171, no. June 2020, p. 108838, 2021, doi: 10.1016/j.measurement.2020.108838.
- [15] A. Ezzati *et al.*, “With Verbal Episodic and Spatial Memory in Older Adults,” vol. 93, pp. 380–385, 2017, doi: 10.1016/j.neuropsychologia.2016.08.016.Differential.
- [16] L. Khedher, J. Ramírez, J. M. Górriz, A. Brahim, and F. Segovia, “Early diagnosis of Alzheimer’s disease based on partial least squares, principal component analysis and support vector machine using segmented MRI images,”

- Neurocomputing*, vol. 151, no. P1, pp. 139–150, 2015, doi: 10.1016/j.neucom.2014.09.072.
- [17] C. S. Sandeep and A. S. Kumar, “A Review on the Early Diagnosis of Alzheimer’s Disease (AD) through Different Tests, Techniques and Databases,” *N<sup>o</sup>*, vol. 76, no. 1, pp. 1–22, 2015.
- [18] K. A. Johnson, N. C. Fox, R. A. Sperling, and W. E. Klunk, “Brain imaging in Alzheimer disease,” *Cold Spring Harb. Perspect. Med.*, vol. 2, no. 4, pp. 1–24, 2012, doi: 10.1101/cshperspect.a006213.
- [19] S. Patro, “Early Detection of Alzheimer ’ s Disease using Image Processing,” vol. 8, no. 05, pp. 468–471, 2019.
- [20] L. K. Lee and S. C. Liew, “A survey of medical image processing tools,” *2015 4th Int. Conf. Softw. Eng. Comput. Syst. ICSECS 2015 Virtuous Softw. Solut. Big Data*, pp. 171–176, 2015, doi: 10.1109/ICSECS.2015.7333105.
- [21] A. Sengupta, “Automation of Landmark Selection for Rodent Brain MRI-histology Registration Using Thin-plate Splines,” p. 100, 2012, [Online]. Available: <http://digitalcommons.unl.edu/computerscidiss/45/>.
- [22] S. Sun, “Empirical Analysis for Earlier Diagnosis of Alzheimer’s Disease Using Deep Learning,” *Int. Conf. Intell. Data Eng. Autom. Learn.*, vol. 19, p. 103, 2020.
- [23] W. Ye and K. K. Ma, “Semantic image content filtering via edge-preserving scale-aware filter,” *Proc. - Int. Conf. Image Process. ICIP*, vol. 2017-Sept, pp. 2443–2447, 2018, doi: 10.1109/ICIP.2017.8296721.
- [24] A. S. Dar and D. Padha, “Medical Image Segmentation A Review of Recent Techniques, Advancements and a Comprehensive Comparison,” *Int. J. Comput. Sci. Eng.*, vol. 7, no. 7, pp. 114–124, 2019, doi: 10.26438/ijcse/v7i7.114124.
- [25] K. Dimililer, “Effect of image enhancement on MRI brain images with neural networks,” vol. 102, no. August, pp. 39–44, 2016, doi: 10.1016/j.procs.2016.09.367.

- [26] R. Mehra, "Estimation of the Image Quality under Different Distortions," *Int. J. Eng. Comput. Sci.*, vol. 5, no. 17291, pp. 17291–17296, 2016, doi: 10.18535/ijecs/v5i7.20.
- [27] U. Sara, M. Akter, and M. S. Uddin, "Image Quality Assessment through FSIM, SSIM, MSE and PSNR—A Comparative Study," *J. Comput. Commun.*, vol. 07, no. 03, pp. 8–18, 2019, doi: 10.4236/jcc.2019.73002.
- [28] S. M. Ismail, A. G. Radwan, A. H. Madian, and M. F. Abu-Elyazeed, "Comparative study of fractional filters for Alzheimer disease detection on MRI images," *2016 39th Int. Conf. Telecommun. Signal Process. TSP 2016*, pp. 720–723, 2016, doi: 10.1109/TSP.2016.7760979.
- [29] S. K. L. S.K., A. Khanna, S. Tanwar, J. J. P. C. Rodrigues, and N. R. Roy, "Alzheimer detection using Group Grey Wolf Optimization based features with convolutional classifier," *Comput. Electr. Eng.*, vol. 77, pp. 230–243, 2019, doi: 10.1016/j.compeleceng.2019.06.001.
- [30] T. P. H. Nguyen, Z. Cai, K. Nguyen, S. Keth, N. Shen, and M. Park, "Pre-processing Image using Brightening, CLAHE and RETINEX," no. March 2020, 2020, [Online]. Available: <http://arxiv.org/abs/2003.10822>.
- [31] C. López-Gómez, R. Ortiz-Ramón, E. Mollá-Olmos, and D. Moratal, "ALTEA: A Software Tool for the Evaluation of New Biomarkers for Alzheimer's Disease by Means of Textures Analysis on Magnetic Resonance Images," *Diagnostics*, vol. 8, no. 3, p. 47, 2018, doi: 10.3390/diagnostics8030047.
- [32] M. Mafi, H. Martin, M. Cabrerizo, J. Andrian, A. Barreto, and M. Adjouadi, "A comprehensive survey on impulse and Gaussian denoising filters for digital images," *Signal Processing*, vol. 157, pp. 236–260, 2019, doi: 10.1016/j.sigpro.2018.12.006.
- [33] K. Bhima and A. Jagan, "Analysis of MRI based brain tumor identification using segmentation technique," *Int. Conf. Commun. Signal Process. ICCSP 2016*, pp. 2109–2113, 2016, doi: 10.1109/ICCSP.2016.7754551.
- [34] D. P. Veitch *et al.*, "Understanding disease progression and improving

- Alzheimer's disease clinical trials: Recent highlights from the Alzheimer's Disease Neuroimaging Initiative," *Alzheimer's Dement.*, vol. 15, no. 1, pp. 106–152, 2019, doi: 10.1016/j.jalz.2018.08.005.
- [35] U. R. Acharya *et al.*, "Automated Detection of Alzheimer's Disease Using Brain MRI Images– A Study with Various Feature Extraction Techniques," *J. Med. Syst.*, vol. 43, no. 9, 2019, doi: 10.1007/s10916-019-1428-9.
- [36] P. R. Kumar, T. Arunprasath, M. P. Rajasekaran, and G. Vishnuvarthanan, "Computer-aided automated discrimination of Alzheimer's disease and its clinical progression in magnetic resonance images using hybrid clustering and game theory-based classification strategies," *Comput. Electr. Eng.*, vol. 72, pp. 283–295, 2018, doi: 10.1016/j.compeleceng.2018.09.019.
- [37] E. A. Radhi and M. Y. Kamil, "Breast Tumor Detection Via Active Contour Technique," *Int. J. Intell. Eng. Syst.*, vol. 14, no. 4, pp. 561–570, 2021, doi: 10.22266/ijies2021.0831.49.
- [38] T. F. Chan and L. A. Vese, "Active contours without edges," *IEEE Trans. Image Process.*, vol. 10, no. 2, pp. 266–277, 2001, doi: 10.1109/83.902291.
- [39] E. Sert and A. Alkan, "Image Edge Detection Based on Neutrosophic Set Approach Combined with Chan-Vese Algorithm," *Int. J. Pattern Recognit. Artif. Intell.*, vol. 33, no. 3, 2019, doi: 10.1142/S0218001419540089.
- [40] D. Holilah, A. Bustamam, and D. Sarwinda, "Detection of Alzheimer's disease with segmentation approach using K-Means Clustering and Watershed Method of MRI image," *J. Phys. Conf. Ser.*, vol. 1725, no. 1, 2021, doi: 10.1088/1742-6596/1725/1/012009.
- [41] S. Matoug, "Predicting Alzheimer'S Disease By Segmenting and Classifying 3D-Brain Mri Images Using Clustering Technique and Svm Classifiers," *J. Phys. Conf. Ser.*, vol. 341(1), no. 012019, p. 130, 2015, [Online]. Available: doi: 10.1088/1742-6596/341/1/012019.
- [42] K. Shen, "Automatic Segmentation and Shape Analysis of Human Hippocampus in Alzheimer ' s Disease," *Am. J. Neuroradiol.*, vol. 12, p. 204,

2011.

- [43] K. H. Zou *et al.*, “Statistical Validation of Image Segmentation Quality Based on a Spatial Overlap Index,” *Acad. Radiol.*, vol. 11, no. 2, pp. 178–189, 2004, doi: 10.1016/S1076-6332(03)00671-8.
- [44] M. Xess and S. Agnes, “Analysis of Image Segmentation Methods Based on Performance Evaluation Parameters,” *Int. J. Comput. Eng. Res.*, vol. 4, no. 3, pp. 122–129, 2014, [Online]. Available: <http://files.figshare.com/1447850/I04302068075.pdf>.
- [45] B. R. Amira, B. Faouzi, A. Hamid, and M. Bouaziz, “Computer-Assisted diagnosis of Alzheimer’s disease,” *Int. Image Process. Appl. Syst. Conf. IPAS 2014*, no. July 2017, 2014, doi: 10.1109/IPAS.2014.7043281.
- [46] M. Zawish, A. A. Siyal, K. Ahmed, A. Khalil, and S. Memon, “Brain tumor segmentation in MRI images using Chan-veese technique in MATLAB,” *2018 Int. Conf. Comput. Electron. Electr. Eng. ICE Cube 2018*, pp. 2–7, 2019, doi: 10.1109/ICECUBE.2018.8610987.
- [47] R. S. Doody, V. Pavlik, P. Massman, S. Rountree, E. Darby, and W. Chan, “Progression of Alzheimer ’ s Disease,” *Alzheimers. Res. Ther.*, vol. 2, no. 2, pp. 1–9, 2010.
- [48] E. Ortoft and H. A. Crystal, “Rate of Progression of Alzheimer’s Disease,” *J. Am. Geriatr. Soc.*, vol. 37, no. 6, pp. 511–514, 1989, doi: 10.1111/j.1532-5415.1989.tb05681.x.
- [49] S. Lee, H. Lee, and K. W. Kim, “Magnetic resonance imaging texture predicts progression to dementia due to Alzheimer disease earlier than hippocampal volume,” *J. Psychiatry Neurosci.*, vol. 45, no. 1, pp. 7–14, 2020, doi: 10.1503/jpn.180171.
- [50] M. Kayalvizhi, G. Kavitha, and C. M. Sujatha, “Analysis of ventricle regions in Alzheimer’s brain MR images using level set based methods,” *Int. J. Biomed. Eng. Technol.*, vol. 12, no. 3, pp. 300–319, 2013, doi: 10.1504/IJBET.2013.057266.

- [51] A. Eileen Pious and U. K. Sridevi, "A study of automatic segmentation of White Matter Hyperintensity for detection of Alzheimer's disease," *J. Phys. Conf. Ser.*, vol. 1831, no. 1, 2021, doi: 10.1088/1742-6596/1831/1/012003.
- [52] G. B. K. and T. S. S. Sandhya Gudise, "MR Brain Image Segmentation to Detect White Matter, Gray Matter, and Cerebro Spinal Fluid Using TLBO Algorithm," *Int. J. Image Graph.*, vol. 21, no. 03 (July 2021), 2021.

