

Case Report

Case of Macular Hole Secondary to Ocular Toxoplasmosis Treated Successfully by Vitrectomy with Inverted Internal Limiting Membrane Flap

Mizuki Ikeda Takayuki Baba Yuri Aikawa Jiro Yotsukura
Hirotaka Yokouchi Shuichi Yamamoto

Department of Ophthalmology and Visual Science, Chiba University Graduate School of Medicine, Chiba, Japan

Keywords

Full-thickness macular hole · Inverted internal limiting membrane · Ocular toxoplasmosis · Pars plana vitrectomy

Abstract

We report a case of ocular toxoplasmosis that developed a full-thickness macular hole (FTMH) which was successfully treated by pars plana vitrectomy combined with an inverted internal limiting membrane (ILM) flap. A 49-years-old Japanese man was aware of blurred vision in his right eye. Slit-lamp biomicroscopy, ophthalmoscopy, and optical coherence tomography (OCT) of the right eye showed that there was a grayish-white subretinal lesion at the macula accompanied by retinal exudation and mild vitreous flare and iritis. An increase in the level of serum IgM for toxoplasma led to a diagnosis of ocular toxoplasmosis. He developed a FTMH adjacent to the lesion 2 weeks after administering sulfamethoxazole/trimethoprim, and his decimal visual acuity was 0.15. Because the FTMH remained 3 months after the resolution of inflammation and his metamorphopsia persisted, vitrectomy with an inverted ILM flap was performed. After the surgery, the visual acuity improved to 0.2 with the closure of the FTMH confirmed by OCT. A FTMH in an eye with ocular toxoplasmosis was successfully closed by vitrectomy with an inverted ILM flap.

© 2021 The Author(s).
Published by S. Karger AG, Basel

Introduction

Ocular toxoplasmosis is an infectious disease caused by *Toxoplasma gondii*. *T. gondii*, and its oocyst can cause retinochoroiditis in the posterior segment of the eye of humans, and it is manifested as an acute or recurrent infection. In the recurrent cases, the active

region is usually observed with some scar tissues. The retinal characteristics of ocular toxoplasmosis are the presence of well-bordered, greyish subretinal lesions at the posterior pole. It is occasionally accompanied by vitritis and retinal vasculitis. Once the lesion becomes inactive, a subretinal scar develops. Small satellite lesions appear when there is a recurrence [1, 2]. A combination of oral pyrimethamine and sulfadiazine [3] or trimethoprim and sulfamethoxazole [4] together with oral corticosteroid is usually used to treat ocular toxoplasmosis. The treatment is continued until the exudation by the chorioretinal lesion stops and turns into a scar with a negative serological test for toxoplasmosis. The visual prognosis of ocular toxoplasmosis depends on the location of the subretinal lesion, and a severe visual disturbance with vision <6/60 has been reported if the lesion involves the macula [5].

A full-thickness macular hole (FTMH) rarely develops in eyes with ocular toxoplasmosis. The prevalence of a FTMH has been reported to occur in 0.4% of eyes with acquired ocular toxoplasmosis [6]. The effect of surgery for the FTMH is unknown, and the indication for intervention and the optimum surgical approach is yet to be determined. Thus, we report the surgical outcome of a case with FTMH in an eye with ocular toxoplasmosis and discuss the effect of an inverted internal limiting membrane (ILM) flap for closing the hole.

Case Report/Case Presentation

A 49-years-old Japanese man, who was aware of declining vision in his right eye for 1 week, was referred to Chiba University Hospital. He had a medical history of diabetes and hypertension and both were well controlled. His decimal best-corrected visual acuity was 0.15 in the right eye and 1.2 in the left eye. The intraocular pressure was 17 mm Hg OD and 14 mm Hg OS. Mild iritis was observed in his right eye. The crystalline lens was clear, but there were mild vitreous flare and retinal vasculitis. A yellowish-white subretinal lesion of the size of the optic disc was observed at the macula of the right eye (shown in Fig. 1). The left eye was free from any inflammation. Optical coherence tomography showed a highly reflective layer at the outer retina accompanied by retinal edema due to exudations in the right eye. Blood tests showed an elevation of toxoplasma-IgM to 1.6 IU/mL (reference range: <0.7 IU/mL) and toxoplasma-IgG to 159 IU/mL (reference range: <6 IU/mL), and the patient was diagnosed with ocular toxoplasmosis in his right eye. Treatment was started with 400 mg of sulfamethoxazole and 80 mg of trimethoprim orally. The oral prednisolone was also started from 30 mg and was tapered in 1 month. The treatment was continued for 6 weeks, and a FTMH developed adjacent to the lesion at 2 weeks after beginning the treatment (shown in Fig. 2). The size of the macular hole was about 500 µm in diameter.

Because the FTMH was unchanged, and the metamorphopsia was severe; we performed phacovitrectomy with implantation of an intraocular lens. The ILM was made visible by BBG (ILM-blue, DORC, Zuidland, Netherland) and peeled, and the ILM flap was used to cover the hole. There was a thin epiretinal membrane observed around the macular hole. The ILM was very fragile and was easily peeled away. Therefore, making a large ILM flap was more difficult compared to the eyes with an idiopathic macular hole. An air tamponade was used, and the patient was instructed to maintain a facedown position for 3 days. The postoperative inflammation was relatively strong, and the intense topical steroid, NSAIDS, and the subconjunctival injection of dexamethasone were used after the surgery. A closure of the FTMH was confirmed 3 days after the surgery, and the hole remains closed postoperatively. The MH closed with type 2 closure which showed the attached MH edge and the absence of retinal tissue at the central fovea. The degree of metamorphopsia was reduced, and the best-corrected visual

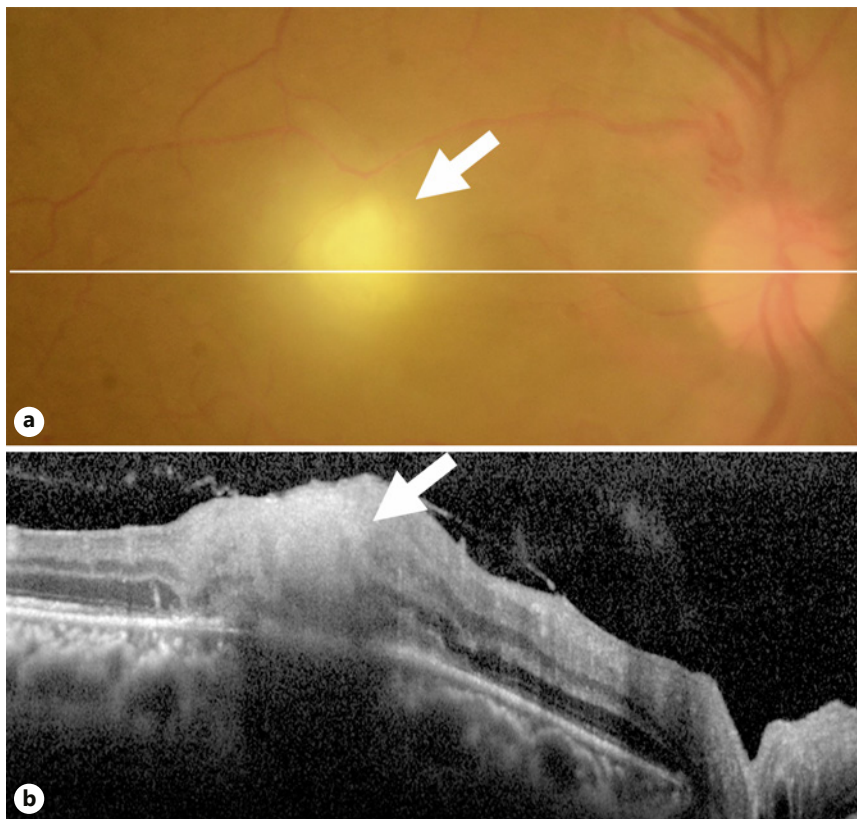


Fig. 1. Images of the right eye of a 49-years-old Japanese man at the initial visit with ocular toxoplasmosis and a FTMH. **a** Fundus photograph shows the yellowish-white tissue at the superotemporal macula region (arrow). Moderate vitritis is observed around the lesion. His decimal visual acuity was 0.09 in the right eye. The white line indicates the location of the OCT scan shown in **b**. **b** Horizontal OCT image showing a highly reflective, thickened retina suggesting a prominent, full-thickness inflammation due to the ocular toxoplasmosis (arrow). FTMH, full-thickness macular hole; OCT, optical coherence tomography.

acuity improved from 0.15 to 0.2 and was stable at the last visit at 7 months after the surgery (shown in Fig. 3).

Discussion/Conclusion

Ocular toxoplasmosis has been reported to develop in 2–20% of cases with toxoplasmosis [7]. The typical findings of ocular toxoplasmosis are localized chorioretinitis with a yellowish-white lesion and 1–3 disc diameter size subretinal lesions at the posterior pole. In eyes with recurrences, several lesions including greyish scars are observed [2]. Complications of ocular toxoplasmosis are anterior uveitis, cataracts, vitreous hemorrhage, vitreous opacity, epiretinal membrane, retinal vein occlusion, choroidal neovascularization, retinal breaks, rhegmatogenous retinal detachment, and macular hole. The prevalence of macular hole is very low [6], and the optimum treatment has not been determined because of its scarcity and uncertain response to surgeries.

The retina surrounding the toxoplasmosis lesion becomes atrophic after the resolution of inflammation. The atrophy results from damages of the neighboring retina and pigment epithelium. The cause for developing a FTMH is not clear, but the atrophy plays some role [8].

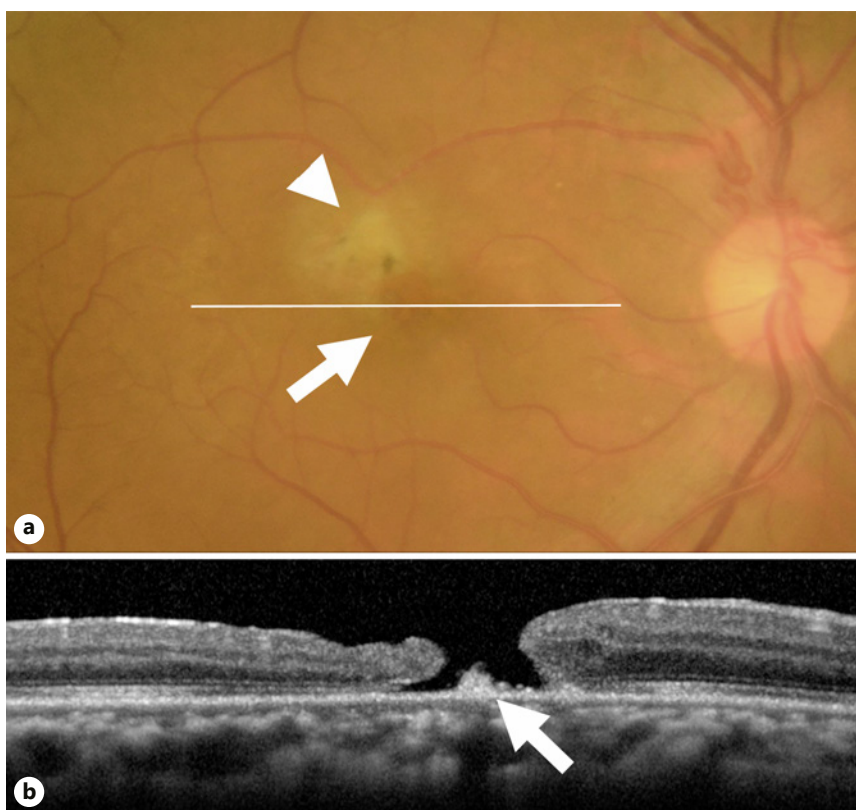


Fig. 2. Images of the right eye at 4 months after the treatment for ocular toxoplasmosis. **a** Fundus photograph shows a greyish-white scar tissue at the superotemporal macula region (arrowhead) and a FTMH (arrow) adjacent to the scar tissue. His decimal visual acuity was 0.15 in the right eye. A white line indicates the location of OCT scan in **b**. **b** Horizontal OCT image showing a FTMH. Tissue can be seen at the bottom of the hole (arrow). FTMH, full-thickness macular hole; OCT, optical coherence tomography.

In cases with an undetached vitreous from the posterior pole, the subsequent posterior hyaloid detachment may cause macular traction and induce a FTMH [9]. In any case, the underlying pathology affects the visual outcome even if the surgery successfully closes the macular hole. In our case, the hole was successfully closed, and visual acuity was improved. There have also been cases that were successfully treated with vitrectomy and ILM removal [10, 11], and we suggest that the use of an inverted ILM flap was important for the closure of the macular hole. The efficacy of the use of an inverted ILM flap has been shown for a refractory MH such as the secondary MH in proliferative diabetic retinopathy, a recurrent MH, a large-sized MH, and a MH in a highly myopic eye [12, 13]. The atrophic retina and subretinal scar may hinder the approximation of the tissue postoperatively. The inverted ILM flap can help the closure by providing a scaffold for glial cells to close the hole [14]. We suggest that surgery be performed if the patient has metamorphopsia and visual discomfort which was related to the macular hole as well as to toxoplasma chorioretinitis. It is also important to explain to the patient about the possibility of minimal or no improvement before obtaining consent to perform the surgery.

We successfully treated a case of ocular toxoplasmosis with a FTMH with vitrectomy and an inverted ILM flap. Although the visual improvement was limited because of the subretinal scar and chorioretinal atrophy, the visual disturbances, and visual acuity were improved. Vitrectomy using ILM flap for a FTMH in an eye with ocular toxoplasmosis is worth considering.

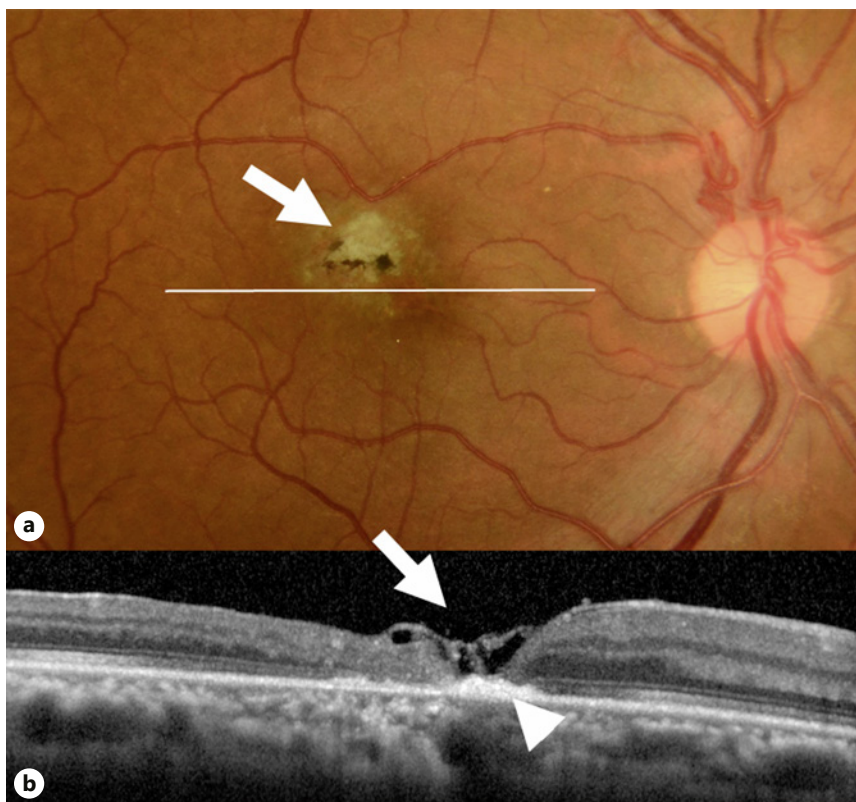


Fig. 3. Images of the right eye at 6 months after the vitrectomy with an ILM flap. **a** Fundus photograph shows a greyish scar with scattered pigmentation (arrow). The macular hole is closed. His right visual acuity improved to 0.2 with reduced metamorphopsia. A white line indicates the location of OCT scan in **b**. **b** An OCT image showing that the macular hole is covered with an ILM flap (arrow). The foveal contour is U-shaped. There is a hyper-reflective scar at the bottom of the closed macular hole (arrowhead). ILM, internal limiting membrane; OCT, optical coherence tomography.

Acknowledgements

The authors thank Professor Emeritus Duco Hamasaki of Bascom Palmer Eye Institute, University of Miami, Coral Gables, FL, USA, for providing critical discussions and suggestions to our study and editing of the final manuscript.

Statement of Ethics

The patient consented to publication of the case in writing. Written informed consent was obtained from the patient for publication of this case report and any accompanying images.

Conflict of Interest Statement

The following author has no financial disclosures: M.I., Y.A., J.Y., H.Y., and T.B.: personal fees from Bayer, personal fees from Kowa, personal fees from Santen, personal fees from Senju, personal fees from Alcon, grants and personal fees from Novartis, and outside the submitted work. S.Y.: grants and personal fees from HOYA, grants and personal fees from

Senju, grants and personal fees from Pfizer, grants and personal fees from Santen, grants and personal fees from Alcon Japan, grants and personal fees from Alcon Pharma, grants and personal fees from Bayer, grants and personal fees from Kowa, personal fees from Nikon, personal fees from Wakamoto, personal fees from Chuo Sangyo, personal fees from Daiichi Sankyo, personal fees from Jamex, personal fees from Sun Contact Lens, personal fees from Finedex, personal fees from Novartis, personal fees from Chugai, personal fees from Abbvie, and outside the submitted work.

Funding Sources

This research was not supported by any competing interests of grants.

Author Contributions

Conception and design: Ikeda and Baba. Data collection: Ikeda and Aikawa. Writing draft: Ikeda and Baba. Analysis and interpretation: Baba, Yotsukura, Yokouchi, and Yamamoto. Overall responsibility: Ikeda, Baba, Aikawa, Yotsukura, Yokouchi, and Yamamoto.

References

- 1 Borkowski PK, Brydak-Godowska J, Basiak W, Świtaj K, Żarnowska-Prymek H, Olszyńska-Krowicka M, et al. The impact of short-term, intensive antifolate treatment (with pyrimethamine and sulfadoxine) and antibiotics followed by long-term, secondary antifolate prophylaxis on the rate of toxoplasmic retinochoroiditis recurrence. *PLoS Negl Trop Dis*. 2016;10(8):e0004892.
- 2 Bosch-Driessen LE, Berendschot TT, Ongkosuwito JV, Rothova A. Ocular toxoplasmosis: clinical features and prognosis of 154 patients. *Ophthalmology*. 2002;109(5):869–78.
- 3 Soheilian M, Sadoughi MM, Ghajarnia M, Dehghan MH, Yazdani S, Behboudi H, et al. Prospective randomized trial of trimethoprim/sulfamethoxazole versus pyrimethamine and sulfadiazine in the treatment of ocular toxoplasmosis. *Ophthalmology*. 2005;112(11):1876–82.
- 4 Yazici A, Ozdal PC, Taskintuna I, Kavuncu S, Koklu G. Trimethoprim/sulfamethoxazole and azithromycin combination therapy for ocular toxoplasmosis. *Ocul Immunol Inflamm*. 2009;17(4):289–91.
- 5 Scherrer J, Iliev ME, Halberstadt M, Kodjikian L, Garweg JG. Visual function in human ocular toxoplasmosis. *Br J Ophthalmol*. 2007;91(2):233–6.
- 6 Aleixo AL, Curi AL, Benchimol EI, Amendoeira MR. Toxoplasmic retinochoroiditis: clinical characteristics and visual outcome in a prospective study. *PLoS Negl Trop Dis*. 2016;10(5):e0004685.
- 7 Jabs DA. Ocular toxoplasmosis. *Int Ophthalmol Clin*. 1990;30(4):264–70.
- 8 Goldenberg D, Goldstein M, Loewenstein A, Habot-Wilner Z. Vitreal, retinal, and choroidal findings in active and scarred toxoplasmosis lesions: a prospective study by spectral-domain optical coherence tomography. *Graefes Arch Clin Exp Ophthalmol*. 2013;251(8):2037–45.
- 9 Orefice JL, Costa RA, Orefice F, Campos W, da Costa-Lima D Jr, Scott IU. Vitreoretinal morphology in active ocular toxoplasmosis: a prospective study by optical coherence tomography. *Br J Ophthalmol*. 2007;91:773–80.
- 10 Arana B, Fonollosa A, Artaraz J, Martinez-Berriotxo A, Martinez-Alday N. Macular hole secondary to toxoplasmic retinochoroiditis. *Int Ophthalmol*. 2014;34(1):141–3.
- 11 Sousa DC, Andrade GC, Nascimento H, Maia A, Muccioli C. Macular hole associated with toxoplasmosis: a surgical case series. *Retin Cases Brief Rep*. 2021 Mar 1;15(2):110–3.
- 12 Chen SN, Yang CM. Internal limiting membrane flaps for coexistent macular hole and retinal detachment in eyes with proliferative diabetic retinopathy. *J Ophthalmol*. 2018;2018:3470731–5.
- 13 Mete M, Alfano A, Guerriero M, Prigione G, Sartore M, Polito A, et al. Inverted internal limiting membrane flap technique versus complete internal limiting membrane removal in myopic macular hole surgery: a comparative study. *Retina*. 2017;37(10):1923–30.
- 14 Shiode Y, Morizane Y, Matoba R, Hirano M, Doi S, Toshima S, et al. The role of inverted internal limiting membrane flap in macular hole closure. *Invest Ophthalmol Vis Sci*. 2017;58(11):4847–55.