

Three-trocar laparoscopic cholecistectomy in patient with *situs viscerum inversus totalis*. Case report and review of the literature.

D.R. IUSCO, S. SACCO, I. ISMAIL, S. BONOMI, S. VIRZI

SUMMARY: Three-trocar laparoscopic cholecistectomy in patient with *situs viscerum inversus totalis*. Case report and review of the literature.

D.R. IUSCO, S. SACCO, I. ISMAIL, S. BONOMI, S. VIRZI

Situs viscerum inversus totalis is a rare defect with a genetic predisposition, which can present difficulties in the management of abdominal pathology, especially in laparoscopic surgery (mirror-image anatomy). We report the case of a 52-year-old female with *situs viscerum inversus totalis*, known from pediatric age, with a medical history of colic pain in the epigastrium radiating to the right abdominal quadrant. Laparoscopic cholecistectomy was safely performed with a three trocar technique. To the best of our knowledge this is the first time that laparoscopic cholecistectomy by three trocars was performed in a patient with *situs viscerum inversus*. We also review the relevant literature concerning this issue.

RIASSUNTO: Colecistectomia laparoscopica a tre trocar in paziente con *situs viscerum inversus totalis*. Case report e revisione della letteratura.

D.R. IUSCO, S. SACCO, I. ISMAIL, S. BONOMI, S. VIRZI

Il *situs viscerum inversus totalis* è una rara condizione ereditata geneticamente che può comportare difficoltà nel trattamento di patologie addominali, specialmente se laparoscopico, per la caratteristica immagine "a specchio" degli organi. Presentiamo il caso di una donna di 52 anni affetta da *situs viscerum inversus totalis* noto dall'età pediatrica, con un'anamnesi di dolore colico in epigastrio irradiato al quadrante addominale superiore di destra. La paziente è stata trattata in tutta sicurezza con colecistectomia laparoscopica con tecnica a tre trocar. Al meglio della nostra conoscenza questa è la prima colecistectomia laparoscopica eseguita con tecnica a tre trocar in paziente con *situs viscerum inversus totalis*. Si presenta inoltre una revisione della letteratura su questo argomento.

KEY WORDS: *Situs viscerum inversus totalis* - Cholelithiasis - Laparoscopic cholecystectomy.
Situs viscerum inversus totalis - Colelitiasi - Colecistectomia videolaparoscopica.

Introduction

Situs viscerum inversus (SVI) is a rare autosomal recessive condition in which organs are transposed from their normal location to the opposite side of the body. This condition may involve the whole abdominal and thoracic viscera (*situs inversus totalis*) or, more rarely, may be only partial (*situs inversus partialis*). The incidence of SVI ranges from 1:10000 to 1:20000 live births (1). Organ transposition may be associated with other congenital anomalies, such as renal dysplasia, biliary atresia, congenital heart disease, or pancreatic fibrosis. *Situs inversus totalis* associated with bronchitis, chronic sinusitis, and deficient tracheobronchial ci-

lia is known as the Kartagener's syndrome (2,3).

Since the first performed by Mouret in France in 1987, laparoscopic cholecystectomy (LC) has rapidly evolved as the gold standard therapeutic modality for gallstone disease (4), but in SVI technical difficulties may be encountered due to the mirror-image of the organs (5-7).

We present a case of 52 year-old patient with SVI *totalis* suffering from symptomatic gallbladder disease treated by laparoscopy with a three trocar technique, reviewing the literature and discussing the surgical technique and the possible difficulties of LC in SVI. To the best of our knowledge this is the first report of cholecistectomy performed with a three trocar technique in a patient with *situs viscerum inversus*.

Case report

A 52 year-old female, with known *situs viscerum inversus totalis* and previous abdominal surgery, was admitted to our Department. SVI was discovered at the age of 2 years after a routine medical examination. Past

Azienda Unità Sanitaria Locale, Bologna, Italy
Surgical Department
Bentivoglio Hospital, Bentivoglio (Bologna), Italy
Division of Surgery
(Chief: S. Virzi)

© Copyright 2012, CIC Edizioni Internazionali, Roma

medical history showed appendectomy, two Cesarean section and laparotomic ovariectomy. The patient had a recent history of intermittent hepigastric pain radiating to the right upper quadrant associated with nausea and vomiting.

Physical examination showed apex beat in the right hemithorax and abdomen soft, not tender. The cardiac shadow and stomach bubble were displayed on the right side of the chest X-ray. An electrocardiography showed right axis deviation and right ventricular hypertrophy, in keeping with dextrocardia. Laboratory data showed no abnormality of liver function tests and white blood cell count. An abdominal ultrasound scan confirmed the presence of situs viscerum inversus totalis and a 2 cm stone in the gallbladder. The common bile duct was not dilated. An esophagogastroscopy showed hiatal hernia and antral gastritis.

With the diagnosis of symptomatic cholelithiasis the patient underwent laparoscopic cholecystectomy. A three trocar techniques with the so called "French position" was used as routinely done, but the position of the trocar was "customised" to the special situation. At first, a small open laparoscopy was practised in the sub-umbilical portion, and a 10-mm trocar was inserted into the abdominal cavity. A 12 mmHg pneumoperitoneum was created and a 10-mm trocar was placed under direct vision in the right upper quadrant; a 5 mm trocar was then placed in the left flank (Fig. 1). The operating surgeon was in between the legs of the patient, while the assistant was on the right side of the patient holding the camera. After an initial diagnostic laparoscopy that confirmed the SVI, the operating surgeon used the left hand to grasp and lift upward and medially the gallbladder and the right hand to dissect the posterior face of the Calot triangle by means of a hook, identifying the cystic duct and the cystic artery. The dissection of the anterior face of the Calot triangle was achieved by grasping the gallbladder with the right hand moving it laterally and dissecting with the hook in the left hand, through the 5mm port positioned in right side of the patient. After this dissection the instruments were put again in their original places, the cystic duct and the cystic artery were clipped and cutted, so that cholecystectomy was carried out without difficulties (Fig. 2). A drain was inserted and was in place for 24 hours.

Postoperative period was uneventful and the patient was discharged on the second postoperative day.

Discussion

Situs viscerum inversus (SVI - transposition of the viscera) has been observed in animals since the time of Aristotele (8). Marco Severino first recognized dextrocardia in 1643. More than a century later, Mathew Baillie described the complete mirror-image reversal of the thoracic and abdominal organs in *situs inversus* (9). The genetic pattern of this condition is known, the gene involved in SVI is located on the long arm of chromosome 14 in human subjects; it is transmitted as a recessive autosomal character with incomplete penetrance (10-13). Typically, if no organ anomalies are associated to this condition, the diagnosis is accidental and patients with SVI have a normal life expectancy.

Left sided gallbladder may also present as an anatomic anomaly without *situs viscerum inversus*. This condition is rare and only a few cases are reported in literature so far (14). Two variants of this condition are known. The first variant (true left sided gallbladder) (15) consists of the gallbladder positioned under the left hepatic lobe, medially to a round ligament originating normally from the left umbilical vein (16). The second variant consists in a gallbladder

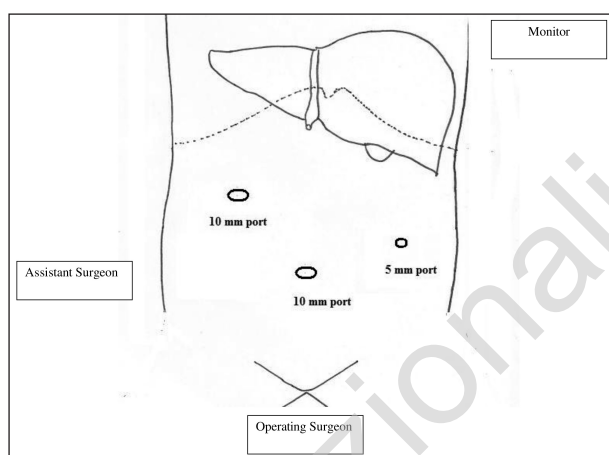


Fig. 1 - Position of the trocars and of the surgical team.

normally positioned under the fourth hepatic segment, medially to a right-sided round ligament (17). In these cases particular attention must be paid to the Calot Triangle anatomy since different variants of confluence of the cystic duct in the common bile duct are described (15).

Clinically the symptoms of gallbladder stone in patients with SVI are reversed, i.e. left quadrant colicky pain, although sometimes symptoms can be misleading. As the central nervous system may not share the general transposition, the pain may be felt in the epigastrium alone or in the right-upper quadrant and in the mid-scapular region (8,18,19). In patients with acute cholecystitis and SVI pain can be felt in the left upper quadrant due to irritation of the peritoneum (8,20). In our case and in other two cases described by Puglisi and Docimo, the pain was referred to the epigastrium and to the right quadrant (6,21). Discordance between the site and irradiation of pain and the site location of the organs, led us to perform other diagnostic exams such as esophagogastroscopy which were all negative.

First laparoscopic cholecystectomy in a patient with SVI was reported by Campos in 1991 (3) and since then thirty-eight other cases have been reported in literature, making a point that laparoscopic procedure is not a contraindication for such patients (5, 22). Ten out of the thirty-eight presented patients were male and twenty-eight female, aging from 20 to 80 years-old; 26 patients had *situs inversus totalis*, and 3 had *situs inversus partialis*, in 9 cases the kind of *situs inversus* was not reported. All the patients had symptomatic cholelithiasis, 6 of them also suffered from acute cholecystitis (23,24). Furthermore, 4 had also choledocholithiasis. In 3 of them laparoscopic cholecystectomy combined with successful extraction of stones from the common bile duct using endoscopic retrograde cholangiopancreatography (ERCP) was performed (5,23), and in the fourth laparoscopic exploration of the common bile duct and ERCP were performed (25). In another report, intraoperative cholangiogram and additional appendectomy

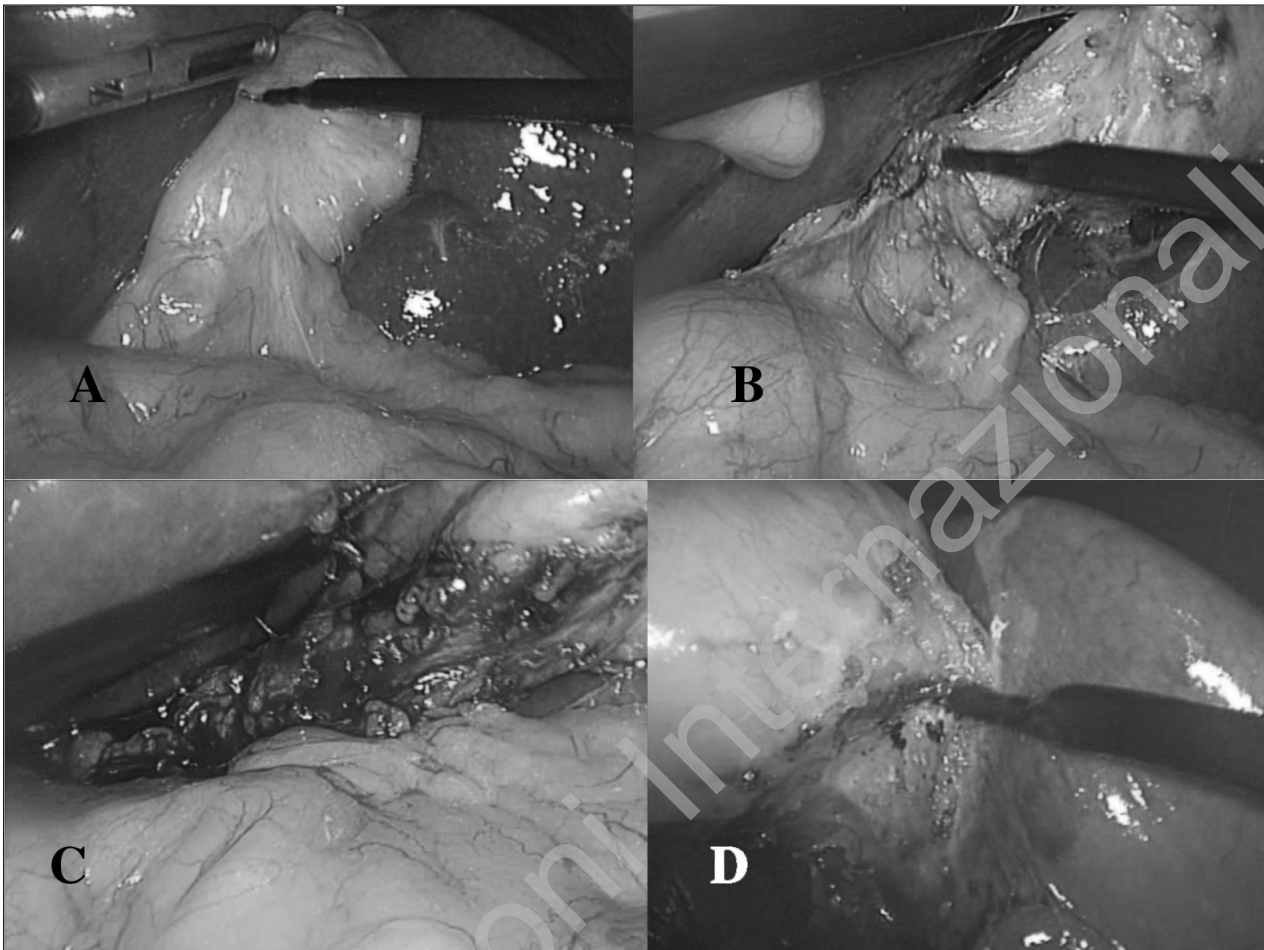


Fig. 2 - Steps of the laparoscopic procedure. A - grasping the gallbladder; B - dissection of the posterior face of the Calot triangle; C - dissection of the anterior face of the Calot triangle (note the hook used with the left hand); D - colecistectomy.

were performed (26). Laparoscopic cholecystectomy, laparoscopic exploration of the common bile duct, intraoperative cholangiogram and additional appendectomy were successful in all cases, with none of the patients showing postoperative complications.

The most challenging factor for performing LC in patients with SVI is the mirror-image anatomy. This uninvited condition may lead to some problems in orientation and dissection during the procedure since most of the surgeons are right handed (27). From a technical point of view, in fact, all the reported cases the surgical techniques have always been “customized” for this condition. We routinely perform laparoscopic cholecistectomy, and if necessary intraoperative cholangiography, using a three trocar technique by means of a 10 mm umbilical port, a 5 mm port in the right flank, and a 10 mm port in upper left quadrant (or in the subxifoid area as preferred by the surgeon) in the so-called French position. We use a fourth trocar only in case of technical difficulties such as an hepatic hilum very deeply located, or hidden by a left hepatic lobe or by a voluminous sagging gallbladder. In the case described we sim-

ply switch the position of the operative trocar maintaining the position in between the legs of the patient for the operating surgeon while the assistant surgeon holding the camera was positioned on the right and the video monitor on the left of the patient (Fig 1).

Three trocar cholecistectomy has been proven to be safe and effective (28). The theoretical main advantages of this technique is that it causes less pain, is less expensive, leaves less scars and reduces the risks linked to trocar insertion, i.e. bleeding, injuries of the abdominal wall and the viscera, and even hernias (29). Moreover it is always possible to use a fourth trocar (or other expedients) or to convert to open surgery should the safety of the manoeuvres be in question or involve prolonging of the procedure. To the best of our knowledge this is the first case in which three trocar technique has been used for laparoscopic cholecistectomy in a patient with *situs viscerum inversus*. We think that the possibility of dissecting the anterior face of the Calot Triangle with the left hand, has been pivotal in the success of this procedure.

The operation lasted 55 minutes slightly more than the

usual time used to perform a routine cholecystectomy (30-40 minutes). The increase in the operative time, reported in many cases, is obviously due to the initial awkwardness for to the unusual anatomy, but beside the need for changing the site of the instruments, we had no particular difficulties in performing laparoscopic cholecystectomy. No intraoperative cholangiography was performed because a clear identification of Calot Triangle was achieved during surgery and safe dissection and clipping of the biliary and vascular structures were performed.

We can conclude that laparoscopic cholecystectomy even

if slightly more time consuming can be performed safely in patients with *situs viscerum inversus*, using particular expedients, such as strategic positioning of the surgeons and laparoscopic instruments. The use of three trocar instead of four did not change the feasibility and the safety of this operation.

Conflict of interests

The authors declare that they have none conflict of interests.

References

1. Al-Jumaily M, Hoche F. Laparoscopic cholecystectomy in situs inversus totalis: is it safe? J Laparoendosc Adv Surg Tech A 2001;11(4):229-31.
2. Nursal TZ, Baykal A, Iret D, Aran O. Laparoscopic cholecystectomy in a patient with situs inversus totalis. J Laparoendosc Adv Surg Tech A 2001;11(4): 239-41.
3. Campos L, Siepes E. Laparoscopic cholecystectomy in a 39-year-old female with situs inversus. J Laparoendosc Surg 1991; 1(2):123-5.
4. Dubois F, Icard P, Berthelot G, Levard H. Celioscopic cholecystectomy: preliminary report of 36 cases. Ann Surg 1990; 211(1):60-2.
5. Aydin U, Unalp O, Yazici P, Gurcu B, Sozbilen M, Coker A. Laparoscopic cholecystectomy in a patient with situs inversus totalis. World J Gastroenterol 1990;12(47):7717-9.
6. Puglisi F, Troilo VL, De Fazio M, Capuano P, Lograno G, Catalano G, Martines G, Memeo V. Cholecystectomy in situs viscerum inversus totalis. Does laparoscopy increase the pitfalls? Chir Ital 2006;58(2):179-83.
7. Malatani TS. Laparoscopic cholecystectomy in situs inversus totalis: a case report and a review of the literature. Ann Saudi Med 1996;16(4):458-9.
8. Drover JW, Nguyen KT, Pace RF. Laparoscopic cholecystectomy in a patient with situs inversus viscerum: a case report. Can J Surg 1992;35(1):65-6.
9. Masood R, Samiullah, Chaudhary IA, Taimur. Laparoscopic cholecystectomy for left sided gallbladder: an unusual case. J Ayub Med Coll Abbottabad 2009;21(1):162-3.
10. Oh SP, Li E. Gene-dosage-sensitive genetic interactions between *inversus viscerum* (*iv*), nodal, and activin type IIB receptor (*ActRIIB*) genes in asymmetrical patterning of the visceral organs along the left-right axis. Dev Dyn 2002;224(3):279-90.
11. Supp DM, Witte DP, Potter SS, Brueckner M. Mutation of an axonemal dynein affects left-right asymmetry in *inversus viscerum* mice. Nature 1997;389(6654):963-6.
12. McGrath J, Horwich AL, Brueckner M. Duplication/deficiency mapping of *situs inversus viscerum* (*iv*), a gene that determines left-right asymmetry in the mouse. Genomics 1992;14(3):643-8.
13. Brueckner M, McGrath J, D'Eustachio P, Horwich AL. Establishment of leftright asymmetry in vertebrates: genetically distinct steps are involved. Ciba Found Symp 1991;162:202-12.
14. Cirila A, De Vecchi A. Left-sided ectopic gallbladder. Quad Radiol 1965;30(4):749-58.
15. Gui D, Magalini S, Prete F, Sermoneta D. What's right when the gallbladder's left? A case report. Surg Endosc 2002;16(11):1637.
16. Siebermair J. Left-sided gallbladder--a rare anatomic variant. Chirurg 1986;57(10):653-4.
17. Fujita N, Shirai Y, Kawaguchi H, Tsukada K, Hatakeyama H. Left-sided gallbladder on the basis of a right-sided round ligament. Hepatogastroenterology 1998;45(23):1482-4.
18. Southam JA. Left-sided gallbladder: calculous cholecystitis with situs inversus. Ann Surg 1975;182(2):135-7.
19. Heimann T, Sicular A. Acute cholecystitis with situs inversus. N Y State J Med 1979;79(2):253-4.
20. Goh P, Tekant Y, Shang NS, Ngoi SS. Laparoscopic cholecystectomy in a patient with empyema of the gallbladder and situs inversus. Endoscopy 1992;24(9):799-800.
21. Docimo G, Manzi F, Maione L, Canero A, Veneto F, Lo Schiavo F, Sparavigna L, Amoroso V, De Rosa M, Docimo L. Case report: laparoscopic cholecystectomy in situs viscerum inversus. Hepatogastroenterology 2004;51(58):958-60.
22. Patle NM, Tantia O, Sasmal PK, Khanna S, Sen B. Laparoscopic cholecystectomy in situs inversus. Our experience of 6 cases. Indian J Surgery 2010;72:391-4.
23. Pitiakoudis M, Tsaroucha AK, Katotomichelakis M, Polychronidis A, Simopoulos C. Laparoscopic cholecystectomy in a patient with situs inversus using ultrasonically activated coagulating scissors. Report of a case and review of the literature. Acta Chir Belg 2005;105(1):114-7.
24. Kirshtein B, Lantsberg S, Mizrahi S, Lantsberg L. Laparoscopic cholecystectomy for acute cholecystitis in patient with situs viscerum inversus. Surg Laparosc Endosc Percutan Tech 2006;16(3):169-71.
25. Wong J, Tang CN, Chau CH, Luk YW, Li MK. Laparoscopic cholecystectomy and exploration of common bile duct in a patient with situs inversus. Surg Endosc 2001;15(2):218.
26. Djohan RS, Rodriguez HE, Wiesman IM, Unti JA, Podbielski FJ. Laparoscopic cholecystectomy and appendectomy in situs inversus totalis. JSLS 2000;4(3):251-4.
27. Hugh TB. New strategies to prevent laparoscopic bile duct injury--surgeons can learn from pilots. Surgery 2002;132(5):826-35.
28. Sun S, Yang K, Gao M, He X, Tian J, Ma B. Three-port versus four-port laparoscopic cholecystectomy: meta-analysis of randomized clinical trials. World J Surg 2009;33(9):1904-8.
29. Trichak S. Three-port vs standard four-port laparoscopic cholecystectomy. Surg Endosc 2003;17(9):1434-6.