

## Recurrent varicose veins of the lower limbs after surgery. Role of surgical technique (stripping vs. CHIVA) and surgeon's experience

M. MILONE, G. SALVATORE, P. MAIETTA, L.M. SOSA FERNANDEZ, F. MILONE

**SUMMARY:** Recurrent varicose veins of the lower limbs after surgery. Role of surgical technique (stripping vs. CHIVA) and surgeon's experience.

M. MILONE, G. SALVATORE, P. MAIETTA, L.M. SOSA FERNANDEZ, F. MILONE

**Background.** Surgical treatment of varicose veins of the lower limbs resolves symptoms and improves quality of life. However, the high recurrence (20-80%) is a costly and complex issue.

**Patients and methods.** This is a retrospective review of 1489 patients with varicose vein of the lower limbs seen at our hospital between January 1980 and December 2005. The aim is to evaluate the effect of surgical technique (stripping vs. CHIVA) and surgeon's experience in reducing recurrences.

**Results.** With experienced surgeons, CHIVA appears to be more effective than stripping in reducing the recurrence rate ( $p < 0.05$ ). However, when performed by an inexperienced surgeon the results are far worse than those achieved with stripping.

**Conclusion.** There was a clear reduction in recurrences at 5-10 years with CHIVA than with conventional stripping. However, if performed incorrectly, results are far worse with CHIVA. In fact, good results are far more difficult to achieve with CHIVA than with stripping, which is repeatable and easy to perform.

**RIASSUNTO:** Le recidive nella chirurgia delle varici degli arti inferiori. Ruolo della metodica (stripping vs. CHIVA) e dell'esperienza dell'operatore.

M. MILONE, G. SALVATORE, P. MAIETTA, L.M. SOSA FERNANDEZ, F. MILONE

**Premessa.** Il trattamento chirurgico delle varici degli arti inferiori assicura la risoluzione dei sintomi e il miglioramento della qualità di vita nei pazienti con varici non complicate. Tuttavia, la chirurgia ha un alto tasso di recidive (20-80%) generando una problematica comune, complessa e costosa.

**Pazienti e metodi.** Abbiamo elaborato uno studio retrospettivo su 1.489 pazienti con varici degli arti inferiori, trattati dal 1° gennaio 1980 al 31 dicembre 2005, per valutare l'incidenza di recidive in relazione alla metodica utilizzata, stripping vs. CHIVA (Cure Conservatrice et Haemodynamique de l'Insuffisance Veineuse en Ambulatoire), e all'esperienza dell'operatore.

**Risultati.** Statisticamente significativa ( $p < 0,05$ ) è risultata la riduzione di recidive con la tecnica CHIVA se eseguita da operatore esperto, mentre i risultati ottenuti con la medesima tecnica eseguita da operatore inesperto risultano peggiori della tradizionale ablazione safenica.

**Conclusioni.** Il metodo CHIVA ha dimostrato un chiaro miglioramento nella riduzione delle recidive a 5-10 anni rispetto al tradizionale stripping. Tuttavia i risultati di una CHIVA non perfettamente eseguita sono molto peggiori rispetto al tradizionale stripping. Di conseguenza la CHIVA necessita di un significativo training e quindi di un'adeguata esperienza di chirurgia vascolare e di ultrasonografia. Ottenere buoni risultati con la metodica CHIVA è molto più impegnativo rispetto all'effettuazione di uno stripping, una tecnica standardizzata e di più facile esecuzione.

**KEY WORDS:** Varicose veins - Lower limbs - CHIVA - Stripping.  
Varici - Arti inferiori - CHIVA - Stripping.

### Introduction

Lower limbs varices are a sign of chronic venous disease caused by valvular incompetence in the superficial venous system. The Edinburgh studies show that this condition affects a third of the population, and its treatment is one of the most frequent surgical operations in the world. Surgery resolves symptoms and improves quality

of life in patients with uncomplicated varices (3). However, recurrence is common (20-80%), complex, and costly (4).

For more than a hundred years the standard treatment was ablation of various veins and stripping of the saphenous vein (5). In 1988 Franceschi (6) described a new method, CHIVA (*Cure Conservatrice et Hemodynamique de l'insuffisance veineuse en ambulatoire*). CHIVA is a methodical, therapeutic and conservative alternative to the conventional radical technique, made possible by the progress of Doppler ultrasonography enabling anatomic and functional mapping of the superficial venous system. The two methods are perfectly alternative, as there are no indications as to why one should be performed in preference to the other, except that CHIVA cannot be performed on saphenous veins >10 mm or where there is deep venous incompetence.

## Patients and methods

A total of 1489 patients with varices of the lower limbs treated between January 1, 1980 and December 31, 2005 at the Federico II University of Naples Department of Surgery, Orthopedics, Trauma and Emergencies were studied retrospectively. Patients with chronic venous disease C: 2-6 A-S, E: P, A: S, P: R, according to the CEAP classification (7,8), were included. Stripping and CHIVA with preoperative Doppler or ultrasound evaluation were performed by the same surgeons for the same indications in both groups.

The efficacy of surgery was evaluated on the basis of recurrences, measured with the Hobbs classification (9), as cure (lack of varices), improvement (varices < 0.5 cm) and failure (varices > 0.5 cm). Clinical follow-up with Doppler evaluation was performed after 5 years. Postoperative complications were assessed by observation: hematomas (> 2 cm) and lesions of the saphenous nerve (paresthesia and pain); and the duration of convalescence (return to work) was noted. Statistical analysis was carried out with SPSS version 14.0 using the chi square test for the categorical variables and Student's t for the continuous variables. Significance was considered as  $p = 0.05$ .

## Results

Until December 31, 1994 the only procedure performed in our department for this condition was saphenous stripping (872 operations). These cases were therefore excluded from our study due to lack of comparative data.

Between January 1, 1995 and December 31, 2000, 311 procedures were carried out: 223 stripping and 88 CHIVA. US evaluation of venous hemodynamics was carried out preoperatively in all cases. Patients were homogeneous for age, sex, BMI and CEAP classification ( $p=ns$ ). A cure was achieved in 71 (30.9%) stripping procedures and 12 (13.6%) CHIVA procedures; this difference was statistically significant ( $p < 0.05$ ) (Fig. 1). The procedure was considered a failure in 106 (47.5%) patients undergoing stripping and 59 (67%) undergoing

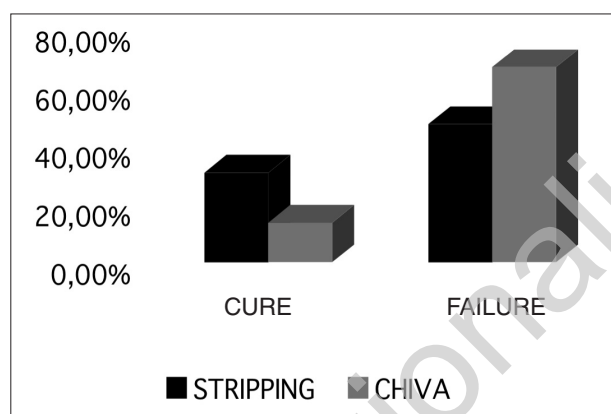


Fig. 1 - Results of first period 1995-2000.

CHIVA; this difference was statistically significant ( $p < 0.05$ ) (Fig. 1).

Between January 1, 2001 and December 31, 2005 we performed 394 procedures: 186 stripping and 208 CHIVA. US evaluation of venous hemodynamics was carried out preoperatively in all cases. The patients were homogeneous for age, sex, BMI and CEAP classification ( $p=ns$ ). A cure was achieved in 55 (29.5%) stripping procedures and 92 (44.2%) CHIVA procedures; this difference was statistically significant ( $p < 0.05$ ) (Fig. 2). The procedure was considered a failure in 87 (46.7%) patients undergoing stripping and in 63 (30.2%) patients undergoing CHIVA; again, this difference was statistically significant ( $p < 0.05$ ) (Fig. 2).

The 1281 stripping procedures performed caused 21 (1.6%) lesions of the saphenous nerve and 78 (6%) subcutaneous hematomas. Neither of these were found with the CHIVA method. The average convalescence was 3 days after stripping and 1 day after CHIVA.

## Discussion

Saphenous vein stripping is a simple, fast, safe, and standardized procedure for the treatment of varicose veins (5-10). It involves the interruption of the femoral-saphenous junction, stripping of the great saphenous vein (GSV), multiple removal of the tributary veins of the saphena and ligation of the extrafascial perforating veins. However, the recurrence rate is high, with neovascularization being the most common cause (11). In many cases, there is no detectable location for the reflux, which is caused by the lack of the drainage previously performed by the saphenous trunk. Treatment of such cases is complex (12).

The CHIVA method is a different approach to the treatment of varices of the lower limbs. Its goal is to maintain the integrity of the superficial venous system and its

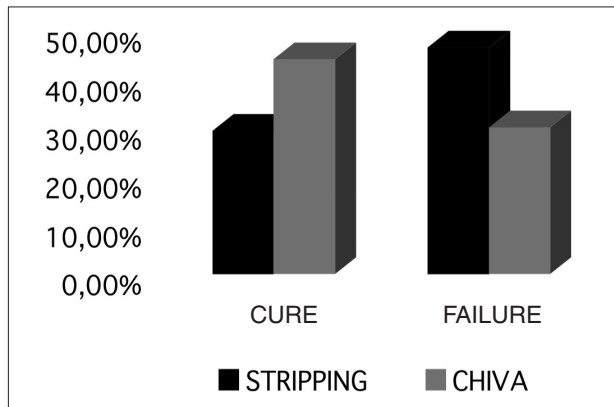


Fig. 2 - Results of second period 2001-2005.

functions (cutaneous and subcutaneous tissue drainage). In practice, it involves the interruption of the hydrostatic pressure responsible for reflux, eliminating shunts (abnormal flow circuits consisting of various points of reflux and return that create a ring-like blood flow, or loop) (13,14). The column pressure fragmentation and emptying of the superficial venous system by the musculo-venous pump causes a reduction in the diameter of the great saphenous vein and the varicose veins, while enabling them to continue drainage towards the deep venous system, albeit through a reverse flow (13,14). The surgeon identifies the shunts (abnormal flow) in the venous compartments (in both the deep and superficial venous systems and between the saphenous vein and its tributaries, with reflux and return that create a ring-like blood flow – i.e., loop). These loops can be identified by Doppler ultrasonography mapping and interrupted through ligation at the origin of the reflux, while conserving the point of return in order to reduce possible recurrences (6).

Approximately 90% of patients with varicose veins have a type 1 or 3 shunt (15). In type 1 (30%), the blood moves away from the deep venous system towards the GSV (femoral-saphenous junction), returning to the deep venous system through a perforating vein. Reflux may also be found in a tributary vein of the GSV. This type of shunt can be corrected with CHIVA 1 through ligation of the femoral-saphenous and the tributary-

saphenous junctions, with no stripping of the saphenous or varicose vein (16).

In type 3 (60%), the blood flows from the deep venous system to the GSV, returning to the deep venous system through a perforating vein on the refluxing tributary vein. This shunt can be corrected with the two-step CHIVA 2 technique. The first step consists of the ligation of the refluxing tributary vein on the GSV followed by removal of 2-4 cm of its proximal tract. If this stimulates the development of a type 1 shunt (a new re-entry through perforating vein from the saphenous vein to the deep system), a second step becomes necessary: ligation of the femoral-saphenous junction (16). This outcome can be predicted beforehand through evaluation of valvular competence (closing time <0.5 s).

With CHIVA, there is a demonstrable reduction in recurrences at 5-10 years compared to traditional stripping (10,12,16,17). Furthermore, recurrences are mainly due to reflux in the GSV due to the incompetence of a tributary vein, easily manageable with ligation and removal (12). Finally, as CHIVA is a minimally invasive technique, there are fewer complications and convalescence time is reduced (18,19).

In this retrospective study, the results achieved by an expert operator in the second observation period 2001-2005 fully confirm the literature data. However the success of CHIVA necessarily requires a lack of reflux in the deep venous system and above all accurate ultrasound mapping of venous hemodynamics, which provides a more precise indication and improves the outcome of the procedure. The results of an imperfectly performed CHIVA are in fact much worse than those of traditional stripping (10,16). Our study confirms this too, given the worse results achieved in our learning period from 1995 to 2000 with CHIVA performed by an inexperienced operator.

## Conclusions

Significant training and adequate experience of vascular surgery and ultrasound mapping are required to perform CHIVA successfully. Achieving good results with this method is much more challenging than with traditional stripping, which is a repeatable, easier and standardized technique.

## References

1. Evans CJ, Allan PL, Lee AJ, et al. Prevalence of venous reflux in the general population on duplex scanning: the Edinburgh vein study. *J Vasc Surg* 1998;28:767-776.
2. Bergan JJ, Schmid-Schonbein GW, Coleridge Smith PD, et al. Chronic venous disease. *Minerva Cardioangiol.* 2007;55(4):488-498.
3. Michaela JA, Brazier JE, Campbell WB, et al. Randomized clinical trial comparing surgery with conservative treatment for uncomplicated varicose vein. *BR J Surg* 2006;93:175-181.
4. Perrin MR, Guex JJ, Vaughan Ruckley C, et al; REVAS group. Recurrent varices after surgery, a consensus document. *Cardio-vasc Surg* 2000;8:223-245.

5. Perkins JM. Standard varicose vein surgery. *Phlebology*. 2009;24(suppl 1):34-41.
6. Franceschi C. Théorie et pratique de la cure conservatrice et hémodynamique de l'insuffisance veineuse en ambulatoire. Precy-sous-thil, France: Edition de l'Armancon 1988.
7. Porter JM, Moneta GL. Reporting standards in venous disease: an update. International Consensus Committee on Chronic Venous Disease. *J Vasc Surg* 1995;21:635-645.
8. Eklof B, Rutherford RB, Bergan JJ, et al; for the American venous forum International ad hoc committee for revision of the CEAP Classification. Revision of the CEAP classification for chronic venous disorders: consensus statement. *J Vasc Surg* 2004;40:1248-1252.
9. Hobbs JT. Surgery or sclerotherapy for varicose veins: a random trial. *Arch Surg* 1974;109:793-796.
10. Pares JO, Juan J, Tellez R, et al. Varicose vein surgery: stripping versus the CHIVA method: a randomized controller trial. *Ann Surg*. 2010;251(4):624-31.
11. Winterborn RJ, Foy C, Earnshaw JJ. Causes of varicose vein recurrence: late results of a randomized controlled trial of stripping the long saphenous vein. *J Vasc Surg* 2004;40:634-639.
12. Carandina S, Mari C, De Palma M, et al. Varicose vein stripping vs Haemodynamic correction (CHIVA); a long term randomized trial. *Eur J Vasc Endovasc Surg* 2008;35:230-237.
13. Criado E, Juan J, Fontcuberta J, et al. Haemodynamic surgery for varicose veins: rationale, and haemodynamic basis. *Phlebology* 2003;18:158-161
14. Juan J, Escribano JM, Criado E, et al. Haemodynamic surgery for varicose veins: surgical strategy. *Phlebology* 2005;20:2-13.
15. Franceschi C: Shunt classification, in Franceschi C, Zamboni P (eds.): Principles of venous hemodynamics. New York, Nova Biomedical Books, 2009, pp 55-64.
16. Mowatt-Larssen E, Shortell C. CHIVA. *Semin Vasc Surg* 2010;23:118-122.
17. Maeso J, Juan J, Escribano JM, et al. Comparison of clinical outcome of stripping and CHIVA for treatment of varicose veins in the lower extremities. *Ann Vasc Surg* 2001;15(6):661-665.
18. Sam RC, Silverman SH, Bradbury AW. Nerve injuries and varicose vein surgery. *Eur J Vasc Endovasc Surg* 2004;27:113-120.
19. Blomgren L, Johansson G, Bergqvist D. Quality of life after surgery for varicose veins and the impact of preoperative duplex: results based on a randomized trial. *ANN Vasc Surg* 2006;20:30-34.