

*Acta Microbiologica et Immunologica Hungarica*, 62 (3), pp. 267–274 (2015)  
DOI: 10.1556/030.62.2015.3.4

# AUTOSOMAL RECESSIVE HYPER IgM SYNDROME ASSOCIATED WITH ACTIVATION-INDUCED CYTIDINE DEAMINASE GENE IN THREE TURKISH SIBLINGS PRESENTED WITH TUBERCULOSIS LYMPHADENITIS – CASE REPORT

TURKAN PATIROGLU<sup>1,3</sup>, H. HALUK AKAR<sup>1\*</sup>,  
MIRJAM VAN DER BURG<sup>2</sup> and EKREM UNAL<sup>3</sup>

<sup>1</sup>Erciyes University School of Medicine, Department of Pediatric Immunology,  
Kayseri, Turkey

<sup>2</sup>Department of Erasmus MC, University Medical Center Rotterdam,  
Rotterdam, the Netherlands

<sup>3</sup>Erciyes University School of Medicine, Department of Pediatric Hematology and Oncology,  
Kayseri, Turkey

(Received: 2 February 2015; accepted: 4 April 2015)

The hyper-immunoglobulin M (HIGM) syndrome is a heterogeneous group of genetic disorders characterized by recurrent infections, decreased serum levels of immunoglobulin G (IgG) and IgA, and normal/increased serum levels of IgM. Herein, we describe three Turkish siblings with HIGM syndrome who had a homozygous missense mutation (c.70C>T, p.Arg24Trp) in the activation-induced cytidine deaminase gene which results in autosomal recessive HIGM syndrome. Two of the siblings, sibling 1 and sibling 3, presented with cervical deep abscess and cervical tuberculosis lymphadenitis, respectively.

**Keywords:** hyper-immunoglobulin M syndrome, activation-induced cytidine deaminase gene, tuberculosis lymphadenitis

## Introduction

Patients with hyper-immunoglobulin M (HIGM) syndrome incline to recurrent infections, lymphoid hyperplasia, autoimmune, and inflammatory disorders. This syndrome can be inherited as X-linked, autosomal recessive (AR), or occasionally dominant mutations (AD). The main defect results from mutations

\*Corresponding author; E-mail: [himmelakar@gmail.com](mailto:himmelakar@gmail.com)

in the B-cell signaling genes, which are required for class switch recombination (CSR) and somatic hypermutation (SHM) [1]. At least six molecular defects associated with X-linked (*CD40* ligand and the nuclear factor  $\kappa$ B essential modulator (*NEMO* genes), AR [*CD40*, activation-induced cytidine deaminase (*AID*) / or as known activation-induced cytidine deaminase (*AICDA*), uracil-DNA glycosylase (*UNG*) genes], and AD [inhibitor of NF- $\kappa$ B (*I $\kappa$ B $\alpha$* ) gene] have been reported as causing HIGM syndrome [2]. The *AID* gene mutations are the most frequent causative aberration in the AR HIGM patients. Defective gene product, AID protein, leads to the impairment of CSR and SHM generation [3–4]. More than 40 different mutations have been identified in the *AID* gene in patients with HIGM syndrome [5]. Herein, we report three Turkish siblings who had a homozygous missense mutation in *AID* gene. One of them, sibling 1, presented with cervical deep abscess. The other one, sibling 3, presented with cervical tuberculosis lymphadenitis.

### Clinical Reports

In this study, we describe three siblings (two males, one female). There was second degree consanguinity between parents. The laboratory findings (elevated IgM, decreased IgG and IgA) were consistent with HIGM syndrome. A homozygous missense mutation (c.70C>T, p.Arg24Trp) was found in exon 2 in the *AID* gene. After the genetic diagnosis, hematopoietic stem cell transplantation (HSCT) was planned for the patients (Table I).

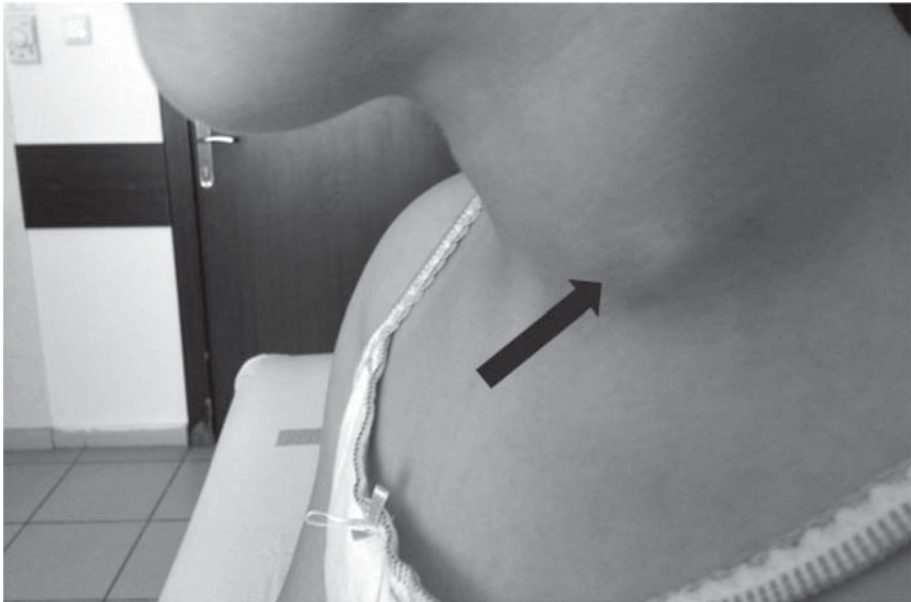
#### Sibling 1

An 11-year-old girl was admitted with left cervical mass to the Department of Pediatric Emergency Unit. Physical examination revealed 3×3 cm fluctuated, hyperemic, mobile, and painful mass in left sternocleidomastoid muscle (SCM) posterolateral region. Also, she had cervical, bilateral inguinal multiple millimetric mobile lymphadenopathies, and enlarged tonsils. Her growth parameters were normal. Cervical ultrasound showed 14×40×42 mm lobulated mass which is consistent with abscess in left supraclavicular area and multiple cervical lymphadenopathies (Fig. 1). *Staphylococcus aureus* was cultured from the drained abscess material. Tbc was investigated because of her brother experienced Tbc lymphadenitis. The results of draining materials for tuberculosis were negative. No acid-fast bacilli were seen nor cultured, Tbc polymerase chain reaction (PCR) and PPD were negative. Clinical improvement was observed with cefazolin and IVIG

**Table I.** Patient characteristics

Patients	Gender	Current age (years)	Onset age of clinic (years)	Diagnosis age (years)	IgM* (md/dL)	IgG** (mg/dL)	IgA*** (mg/dL)	Clinic	Genetic
Sibling 1	Female	11	4	10	2200	120	6.1	Recurrent upper and lower respiratory infections, recurrent deep cervical abscess, lymphoid tissue hyperplasia	Homozygous missense mutation in exon 2 in AID gene (c.70C>T, p.A.rg24Trp)
Sibling 2	Male	8	3	7	1750	104	6.1	Recurrent upper respiratory infections, lymphoid tissue hyperplasia, tonsillo-adenoidectomy	
Sibling 3	Male	7	2	6	633	130	6.1	Recurrent upper respiratory infections, lymphoid tissue hyperplasia, cervical <i>Tbc lymphadenitis</i>	

\*IgM aged normal range, 30–187 md/dL; \*\*IgG aged normal range, 579–1610; \*\*\*IgA aged normal range, 27–198 mg/dL; Tbc, tuberculosis

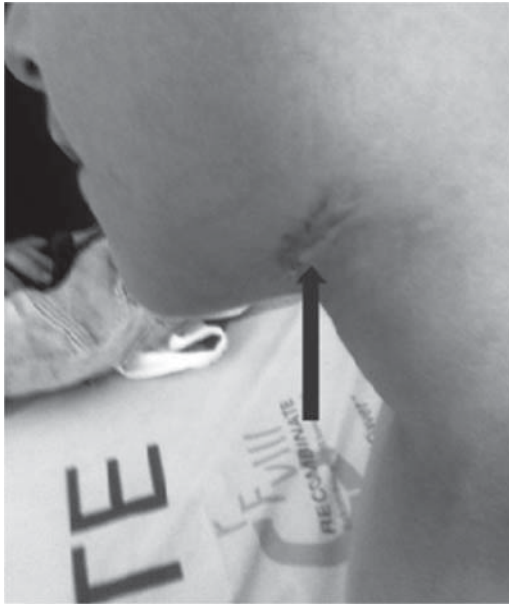

**Figure 1.** Cervical deep abscess in patient 1

therapy in two weeks. It was learned from the anamnesis, her medical problems started at 4 years of age with recurrent otitis, sinusitis, and pneumonia. She was treated lots of antibiotics cures. She was interned three times due to pneumonia. In her last two years of life, she experienced two times recurrent cervical painful mass which was spontaneously draining as in presented to our clinic. After genetic diagnosis AR HIGM syndrome, monthly IVIG infusion and the trimethoprim-sulfamethoxazole (TMP-SMX) prophylaxis for *Pneumocystis jiroveci* pneumonia (PcP) was started.

### *Sibling 2*

Second sibling was an 8-year-old boy. His problems started at 3 years of age with recurrent upper respiratory infections such as otitis media and sinusitis. He underwent tonsillo-adenoidectomy when he was 5 years old due to recurrent otitis media. Also he had frequent courses of treatments with antibiotics as in other siblings. The same prophylaxis regimen (monthly IVIG and TMP-SMX for PcP) was initiated as in sibling 1.



**Figure 2.** Sequelae of tuberculous lymphadenitis in patient 3

### *Sibling 3*

A 7-year-old boy was referred to the Department of Pediatric Immunology because of further diagnostic work-up with the other siblings. His medical problems started at 2 years of age with recurrent upper respiratory tract infections. At the age of 5 years, he was admitted to hospital with cervical mass. Physical examination revealed an anterior cervical 3×2 cm fluctuated, painful mass and cervical multiple millimetric lymphadenopathies. Cervical ultrasound showed 34×18 mm lobulated heterogenic abscess formation mass in left submandibular area and 20×17×30 mm in view of the heterogeneous solid mass (conglomerated lymphadenopathy) in anterior left SCM region and multiple millimetric cervical lymphadenopathies. Histopathologic examination showed chronic non-caseating granulomatous inflammation in the cervical mass biopsy. Acid-fast bacilli were seen. Also, Tbc was cultured from the biopsy material with BACTEC automated system. It was learned that the family lives with the grandfather who experienced lung Tbc disease 5 years ago. He had been treated with anti-tuberculosis treatment for one year. Clinical improvement was seen with triple antituberculosis treatment in one year (Fig. 2). Also, the same prophylaxis regimen (monthly IVIG and TMP-SMX for PcP) was started to the patient.

## Discussion

X-linked HIGM syndrome is the most common form of HIGM, which is caused by mutations in *CD40L* and *NEMO* genes, presents recurrent infections such as PcP and *Cryptosporidium* infections [6]. The *AID* gene encodes AID protein consists of 198 amino acids. In SHM and CSR, the role of *AID* gene has not yet been clearly elucidated. For this, in the medical literature, two molecular mechanisms have been presumed as DNA deamination and RNA-editing hypothesis [7–9]. Patients with AR HIGM syndrome usually have normal B lymphocyte counts as in the presented patients. However, in contrast to the X linked patients, B cells are not able to switch from IgM secreting cells to the IgG, IgA, and IgE secreting cells even though CD40 antibody in the patients with AR HIGM syndrome. Namely in the patients with AR HIGM syndrome, there is a really intrinsic B cell abnormality. Patients with AR HIGM syndrome usually have lymphoid hyperplasia, recurrent respiratory and gastrointestinal infections with bacterial agents. These patients usually do not have susceptibility to opportunistic infections such as PcP. Also, these patients less likely have neutropenia according to the X-linked patients with HIGM syndrome [10–11]. Neutropenia was not observed in the presented siblings. The AR HIGM syndrome results from the *AID* gene mutations might be complicated autoimmune and inflammatory disorders including polyarthritis, autoimmune hepatitis, hemolytic anemia, immune thrombocytopenia [12]. In the presented patients, autoimmune manifestation was not observed up to date. In patients with AR HIGM syndrome, also the diagnosis of HIGM may be delayed to after first decade of life as in sibling 1. The high levels of IgM antibodies ensure effective protection against some infectious agents in the patients with AR HIGM syndrome [5]. Thus, infections are not enough frequent and severe as in the presented patients to reveal a suspicion of immunodeficiency disease at early ages [10]. Likewise in the all presented siblings, the diagnosis of the AR HIGM syndrome was identified after the age of 5 years. Patients with X-linked HIGM syndrome often present opportunistic infections such as PcP, *Cryptosporidium species*, *Toxoplasma gondii*, and *Mycobacteria species*. Almost 40% of opportunistic infections results from PcP in the patients with HIGM syndrome [13]. Tbc has been reported as 9–28% in the patients with X linked HIGM syndrome [14–15]. In contrast to the patients with X linked HIGM syndrome, the patients with AR HIGM syndrome caused by mutations in *AID* gene do not have opportunistic infections. It has been explained with AR HIGM syndrome is a pure B-cell deficiency disease [5]. In the medical literature, to our knowledge, Tbc infections have been reported in only one patient with AR HIGM as Tbc osteomyelitis [16]. In our patients, sibling 3 presented with Tbc lymphadenitis.

As mentioned above, recurrent infections are mainly bacterial and mostly are observed as pneumonia in the *AID* gene deficient patients. In these patients, other sites of infection are the skin, lymph nodes, gastrointestinal tract, and central nervous system such as meningitis and encephalitis [3, 12]. In the medical literature, also, infections as abscess formation have been reported in only X-linked HIGM patients [11, 17]. To our knowledge, deep abscess have been reported rarely in the patients with AR HIGM syndrome [16]. Sibling 1 presented with recurrent cervical deep abscess.

In conclusion, *AID* gene deficient patients have an increased risk of recurrent, severe infections leading to chronic sinopulmonary infections such as sinusitis, bronchiectasis, and lymphoid hyperplasia. Also, autoimmune and inflammatory disorders can be observed in the follow up of patients with AR HIGM syndrome. In addition to these informations, in the presented sibling 1 and 3, recurrent deep cervical abscess and cervical Tbc lymphadenitis were observed, respectively.

### Conflict of Interest

The authors declare that they have no conflict of interest.

### References

1. Stavnezer, J., Guikema, J. E., Schrader, C. E.: Mechanism and regulation of class switch recombination. *Annu Rev Immunol* **26**, 261–292 (2008).
2. Lee, W. I., Huang, J. L., Ye, K. W., Yang, M. J., Lai, M. C., Chen, L. C., Ou, L. S., Yao, T. C., Lin, S. J., Jaing, T. H., Chen, S. H., Hsieh, M. Y., Yu, H. H., Chien, Y. H., Shyur, S. D.: Clinical features and genetic analysis of Taiwanese patients with the hyper IgM syndrome phenotype. *Pediatr Infect Dis J* **32**, 1010–1016 (2013).
3. Davies, E. G., Thrasher, A. J.: Update on the hyper immunoglobulin M syndromes. *Br J Haematol* **149**, 167–180 (2010).
4. Erdos, M., Durandy, A., Marodi, L.: Genetically acquired class-switch recombination defects: The multi-faced hyper-IgM syndrome. *Immunol Lett* **97**, 1–6 (2005).
5. Mahdavian, S. A., Hirbod-Mobarakeh, A., Wang, N., Aghamohammadi, A., Hammarström, L., Masjedi, M. R., Pan-Hammarström, Q., Rezaei, N.: Novel mutation of the activation-induced cytidine deaminase gene in a Tajik family: Special review on hyper-immunoglobulin M syndrome. *Expert Rev Clin Immunol* **8**, 539–546 (2012).
6. Winkelstein, J. A., Marino, M. C., Ochs, H., Fuleihan, R., Scholl, P. R., Geha, R., Stiehm, E. R., Conley, M. E.: The X-linked hyper-IgM syndrome: Clinical and immunologic features of 79 patients. *Medicine* **82**, 373–384 (2003).
7. Shinkura, R., Tian, M., Smith, M., Chua, K., Fujiwara, Y., Alt, F. W.: The influence of transcriptional orientation on endogenous switch region function. *Nat Immunol* **4**, 435–441 (2003).

8. Shivarov, V., Shinkura, R., Doi, T., Begum, N. A., Nagaoka, H., Okazaki, I. M., Ito, S., Nonaka, T., Kinoshita, K., Honjo, T.: Molecular mechanism for generation of antibody memory. *Philos Trans R Soc Lond B Biol Sci* **364**, 569–567 (2009).
9. Xu, Z., Pone, E. J., Al-Qahtani, A., Park, S. R., Zan, H., Casali, P.: Regulation of aicda expression and AID activity: Relevance to somatic hypermutation and class switch DNA recombination. *Crit Rev Immunol* **27**, 367–397 (2007).
10. Minegishi, Y., Lavoie, A., Cunningham-Rundles, C., Bedard, P. M., Hebert, J., Cote, L., Dan, K., Sedlak, D., Buckley, R. H., Fischer, A., Durandy, A., Conley, M. E.: Mutations in activation-induced cytidine deaminase in patients with hyper IgM syndrome. *Clin Immunol* **97**, 203–210 (2000).
11. Shah, I., Rahangdale, A., Bhatnagar, S.: Liver abscesses and hyper IgM syndrome. *J Family Med Prim Care* **2**, 206–208 (2013).
12. Quartier, P., Bustamante, J., Sanal, O., Plebani, A., Debré, M., Deville, A., Litzman, J., Levy, J., Ferman, J. P., Lane, P., Horneff, G., Aksu, G., Yalçın, I., Davies, G., Tezcan, I., Ersoy, F., Catalan, N., Imai, K., Fischer, A., Durandy, A.: Clinical, immunologic and genetic analysis of 29 patients with autosomal recessive hyper-IgM syndrome due to Activation-Induced Cytidine Deaminase deficiency. *Clin Immunol* **110**, 22–29 (2004).
13. Montella, S., Maglione, M., Giardino, G., Di Giorgio, A., Palamaro, L., Mirra, V., Ursini, M. V., Salerno, M., Pignata, C., Caffarelli, C., Santamaria, F.: Hyper IgM syndrome presenting as chronic suppurative lung disease. *Ital J Pediatr* **38**, 45 (2012).
14. Madkaikar, M., Gupta, M., Chavan, S., Italia, K., Desai, M., Merchant, R., Radhakrishnan, N., Ghosh, K.: X-linked hyper IgM syndrome: Clinical, immunological and molecular features in patients from India. *Blood Cells Mol Dis* **53**, 99–104 (2014).
15. Cabral-Marques, O., Klaver, S., Schimke, L. F., Ascendino, E. H., Khan, T. A., Pereira, P. V., Falcai, A., Vargas-Hernández, A., Santos-Argumedo, L., Bezrodnik, L., Moreira, I., Seminario, G., Di Giovanni, D., Raccio, A. G., Porras, O., Weber, C. W., Ferreira, J. F., Tavares, F. S., de Carvalho, E., Valente, C. F., Kuntze, G., Galicchio, M., King, A., Rosário-Filho, N. A., Grota, M. B., dos Santos Vilela, M. M., Di Gesu, R. S., Lima, S., de Souza Moura, L., Talesnik, E., Mansour, E., Roxo-Junior, P., Aldave, J. C., Goudouris, E., Pinto-Mariz, F., Berrón-Ruiz, L., Staines-Boone, T., Calderón, W. O., del Carmen Zarate-Hernández, M., Grumach, A. S., Sorensen, R., Durandy, A., Torgerson, T. R., Carvalho, B. T., Espinosa-Rosales, F., Ochs, H. D., Condino-Neto, A.: First report of the hyper-IgM syndrome registry of the Latin American Society for Immunodeficiencies: Novel mutations, unique infections, and outcomes. *J Clin Immunol* **34**, 146–156 (2014).
16. Shah, I.: Hyper IgM syndrome with tuberculous osteomyelitis and scrofuloderma. *Indian Pediatr* **42**, 952–953 (2005).
17. Tsai, H. Y., Yu, H. H., Chien, Y. H., Chu, K. H., Lau, Y. L., Lee, J. H., Wang, L. C., Chiang, B. L., Yang, Y. H.: X-linked hyper-IgM syndrome with CD40LG mutation: Two case reports and literature review in Taiwanese patients. *J Microbiol Immunol Infect* **48**, 113–118 (2015).