

*Acta Veterinaria Hungarica* 63 (2), pp. 215–222 (2015)  
DOI: 10.1556/004.2015.019

## VASCULAR LESIONS AND PNEUMONIA IN A PIG FETUS INFECTED BY PORCINE CIRCOVIRUS TYPE 2

Levente SZEREDI<sup>1\*</sup>, Attila CSÁGOLA<sup>2</sup>, Ádám DÁN<sup>1</sup> and László DENCSE<sup>1</sup>

<sup>1</sup>National Food Chain Safety Office, Veterinary Diagnostic Directorate, Tábornok u. 2, H-1143 Budapest, Hungary; <sup>2</sup>Department of Microbiology and Infectious Diseases, Faculty of Veterinary Science, Szent István University, Budapest, Hungary

(Received 15 October 2014; accepted 17 February 2015)

Porcine circovirus type 2 (PCV2) associated reproductive disease was diagnosed in a herd containing only gilts. A single case of abortion occurred and no other disorder was evident in the herd. PCV2 antigen and/or DNA were detected in two aborted fetuses. One of the fetuses, revealing both PCV2 DNA and antigen, presented multinucleated giant cells, severe vascular lesions (intramural oedema, fibrinoid necrosis, mild lympho-histiocytic vasculitis, fibrin thrombi) and mild non-suppurative inflammation in the lungs. Other abortifacient infections were not found. This is the only report of PCV2-induced abortion in Hungary since 1999, when PCV2-associated disease was first discovered in the country.

**Key words:** Swine, abortion, porcine circovirus type 2 (PCV2), polymerase chain reaction (PCR), immunohistochemistry, vascular lesions

Porcine circovirus type 2- (PCV2-) associated disease (PCVAD) can be manifested as a systemic disease (postweaning multisystemic wasting syndrome; PMWS), as part of the porcine respiratory disease complex (PRDC), as an enteric disease, as porcine dermatitis and nephropathy syndrome (PDNS), or in the form of reproductive disorders (Opriessnig et al., 2007). The last mentioned disorders include early termination of pregnancy, increased number of mummified fetuses, stillbirth or the birth of weak pigs (Madson and Opriessnig, 2011). PCV2 was shown to cause subclinical intrauterine infection in sows (Gerber et al., 2012). This can make it difficult to diagnose PCV2-associated reproductive disease by polymerase chain reaction (PCR), which is a sensitive and widely used method. Recently the following characteristics or methods have been suggested for the diagnosis of PCV2-associated reproductive disease: (1) the presence of clinical signs on the farm, (2) characteristic histological lesions in affected fetal tissues, (3) detection of PCV2 antigen or DNA in fetal tissues using immunohistochemistry (IHC) or *in situ* hybridisation (ISH) (Madson and Opriessnig, 2011). Subclinical intrauterine PCV2 infection is identified by the detection of viral

---

\*Corresponding author; E-mail: [szeredil@nebih.gov.hu](mailto:szeredil@nebih.gov.hu); Phone: 0036 (1) 460-6305; Fax: 0036 (1) 222-6071

DNA or antibodies in fetal tissues, pre-suckle serum or thoracic fluid without the presence of microscopic lesions or indications of reproductive failure (Madson and Opriessnig, 2011).

PCV2 infection associated with PMWS was first detected in Hungary in 1999 (Kiss et al., 2000). The infection was later found to be associated with PDNS (Molnár et al., 2002) as well as PRDC (Szeredi et al., 2013). PCV2-associated reproductive disease has not yet been reported in this country. In this paper we describe the first natural case of PCV2-induced abortion in Hungary.

## Materials and methods

### *Gross pathological, histological and immunohistochemical examinations*

Seven aborted fetuses (approximately 80 days of age according to their crown to rump length) and fetal membranes originating from a single gilt were submitted for examination from a farm of 300 gilts. The farm was free from Aujeszky's disease, leptospirosis, porcine respiratory and reproductive syndrome (PRRS) and *Brucella* infections, and did not use any PCV2 vaccine. After gross pathological examination, fetal lungs, liver and kidney were collected and fixed in 10% neutral buffered formalin from two fetuses. The remaining five fetuses were mummified and showed severe autolysis preventing further laboratory examinations. Formalin-fixed and paraffin-embedded tissue sections of 4 µm thickness were stained with haematoxylin and eosin (HE). Serial tissue sections were used for IHC in order to detect PCV2 as described by Szeredi et al. (2012).

### *Bacteriological and serological examination*

Bacterial cultures were made from the stomach contents and the fetal membranes. The samples were cultured on duplicates of nutrient, bromothymol blue-lactose-sucrose (BLS, modified Drigalski) and 5% sheep blood agar plates and incubated aerobically for 48 h. To culture *Brucella* spp., sheep blood agar plates were incubated in an atmosphere containing 10% CO<sub>2</sub> for 6 days.

Thoracic fluid was collected and examined for the presence of porcine parvovirus (PPV) antibodies by indirect ELISA. Serum samples of the aborted gilt and serum samples of eight other gilts from the herd were submitted as well and were tested for *Brucella abortus*, Aujeszky's disease virus, PRRS virus (PRRSV) and PPV antibodies by indirect ELISA and for *Leptospira pomona* antibodies by microscopic agglutination test.

### *Polymerase chain reaction (PCR) and sequencing*

Pooled tissue samples (spleen, thymus, ileum, lungs, heart, liver and kidney) were collected from two fetuses for the detection of PRRSV, PCV2 as well

as PPV1, PPV2, PPV3 and PPV4. The viral nucleic acid was extracted with the innuPREP Virus DNA/RNA Kit (Analytik Jena, Biometra, Germany) according to the user's manual. The PCRs and sequencing were carried out using previously described methods (PCV2: Cságola et al., 2006; PPV1: Soares et al., 1999; PPV2, PPV3, PPV4: Cságola et al., 2012; PRRSV: Oleksiewicz et al., 1998).

## Results

### *Gross pathological, histological and immunohistochemical examinations*

On macroscopic examination, one of the two fetuses showed moderate autolysis, and a few fibrin deposits were evident in the abdominal cavity. The other fetus was not affected by autolysis and showed no alterations.

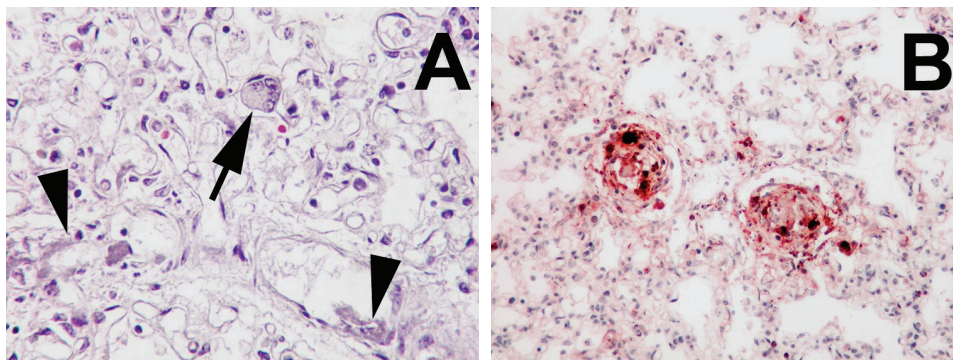
Microscopically, moderate to severe autolysis was present in the fetus presenting gross pathological alterations. Tissue lesions were observed only in the lungs presenting mild lympho-histiocytic infiltration in the alveolar wall, moderate interlobular oedema, and scant multinucleated giant cells situated in the capillary and alveolar lumen (Fig. 1A). Additionally, intramural oedema, fibrinoid necrosis and mild lympho-histiocytic intramural and perivascular inflammatory cell infiltrations were found in several blood vessels, which frequently contained fibrin thrombi as well (Fig. 1A). Moderate to severe autolysis without apparent tissue lesions was evident in the liver and kidney. In this fetus, a large amount of PCV2 antigen was detected in all organs examined, especially in the blood vessel walls and, in the areas surrounding them, in different cell types including endothelial cells, myoepithelial cells of the tunica media, and macrophages (Figs 1B, 2A, 2B). Single immunostained cells including sinus and capillary endothelial cells and macrophages were evenly distributed in the whole tissue section in all fetal organs (Fig. 2A). No histological lesions or PCV2 antigen was found in the other fetus.

### *Bacteriological and serological examination*

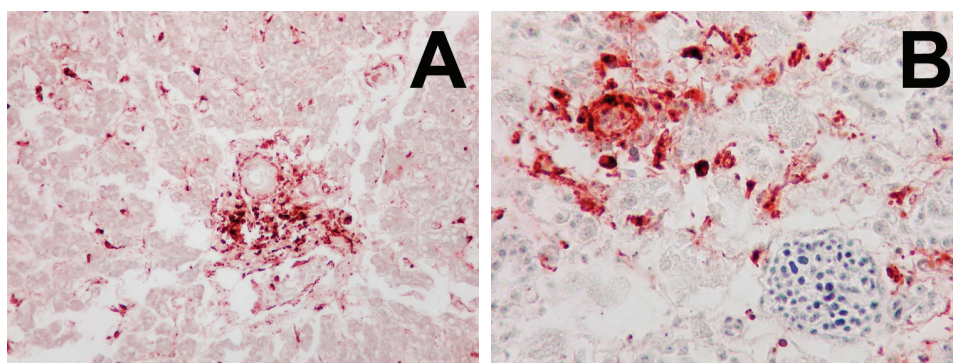
No bacterial pathogens were cultured from any of the fetuses. PPV antibodies were detected in a titre of 1:3472 to 1:9424 in all sows' serum, while the fetal fluids remained negative. The serological examinations were negative for all other infections in all the gilts examined.

### *Polymerase chain reaction (PCR) and sequencing*

PCV2b was found in both of the fetuses. The determined full length PCV2b sequence was deposited in GenBank (accession number: KJ946351). No PRRSV or PPVs were detected in any of the fetuses by PCR.



*Fig. 1.* Tissue samples of aborted pig fetus. *A.* Lungs. Mild lympho-histiocytic infiltration in the alveolar wall, presence of multinucleated giant cell in a capillary lumen (arrow), and multifocal fibrinoid necrosis in blood vessels (arrowheads). Haematoxylin and eosin (HE),  $\times 400$ .  
*B.* Lungs. Large amount of PCV2 antigen in the blood vessels and around them. Immunohistochemistry (IH),  $\times 200$



*Fig. 2.* Tissue samples of aborted pig fetus. *A.* Liver. Large amount of PCV2 antigen in the blood vessels and around them, and strong immunostaining in endothelial cells and macrophages in the sinusoids. Advanced autolytic changes are evident. IH,  $\times 200$ . *B.* Kidney. Large amount of PCV2 antigen in the blood vessels and around them. Moderate autolytic changes are present. IH,  $\times 200$

## Discussion

All criteria for the diagnosis of PCV2-associated reproductive disease were evident in this study (Madson and Opriessnig, 2011). Only gilts were kept on the affected farm. This is a common history of PCV2-induced abortion cases. Such herds are likely to be seronegative and can easily be infected with PCV2 (West et al., 1999). Dam-associated homologous anti-PCV2 antibodies were supposed to be at least partially protective against intrauterine PCV2 infection and the development of reproductive failure (Madson and Opriessnig, 2011). In-

terestingly, only a single case of abortion and no further reproductive disorders were detected in this herd. The time of fetal PCV2 infection seemed to be important in inducing abortion. Inoculation of fetuses at 57 days of gestation was associated with gross pathological alterations and systemic infection, with high amounts of PCV2 DNA being detected in all organs examined. In contrast, fetuses inoculated at 75 or 92 days of gestation showed no macroscopically visible lesions and no systemic infection could be found in them (Sanchez et al., 2003). Based upon the approximate age of the fetuses (80 days) and the presence of five already mummified fetuses, we suppose that intrauterine infection must have occurred in the second third of pregnancy in the present case. The infection can spread from one fetus to another, and not all the pigs are infected with PCV2 at the time of abortion. Therefore, sampling 4–6 fetuses per litter, including mummified fetuses, was recommended (Madson and Opriessnig, 2011). The importance of examining multiple fetuses per litter was supported also in this study, in which PCV2-induced disease was detected only in one fetus, while in the other fetus subclinical PCV2 infection was diagnosed.

Gross pathological lesions rarely occur in PCV2-infected fetuses. They include cardiac dilatation with regions of pallor, pulmonary, subcutaneous or mesocolonic oedema, hydrothorax, ascites, hepatomegaly, lymphadenopathy and cerebral as well as petechiation in the spleen (Madson and Opriessnig, 2011). In the present study, the presence of a few fibrin deposits in the abdominal cavity was the only macroscopic alteration in one of the fetuses. The heart was not affected and was not further examined by either histology or IHC. In previous studies, the myocardium and the liver were shown to contain the highest amounts of PCV2, and the most consistent tissue lesions were found in the myocardium (West et al., 1999; Brunborg et al., 2007). The amount of PCV2 was reported to diminish with increased fetal age, and the virus is known to accumulate in the lymphoid organs around parturition (Sanchez et al., 2003). Other authors have found that mild non-suppurative pneumonia is the only microscopic lesion in both natural and experimental cases of PCV2-induced abortion, and that the lymphoid organs are the most appropriate tissues for the detection of PCV2 by ISH or IHC (Kim et al., 2004; Park et al., 2005). In this study, microscopic lesions were found only in the lungs, where multinucleated giant cells and prominent vascular lesions were detected first, with the parallel presence of non-suppurative pneumonia. The presence of multinucleated giant cells in pig fetuses has so far been described only in the lymphoid organs (Opriessnig and Langohr, 2012) and vascular lesions have been reported only in growing and adult pigs with PMWS or PRDC (Opriessnig et al., 2006; Correa et al., 2007; Seeliger et al., 2007; Langohr et al., 2010; Szeredi et al., 2012; Resendes and Segalés, 2014). The presence of large amounts of PCV2 antigen in and around the blood vessels of different fetal organs suggests that the vascular system may be important in the pathogenesis of fetal PCV2 infection as well.

Some reports suggest that PCV2-associated reproductive disease is rare under natural conditions, whereas other authors have found that 12% to 27.1% of aborted fetuses and stillborn piglets are infected with PCV2 (Kim et al., 2004; Ritzmann et al., 2005; Maldonado et al., 2005; Madson and Opriessnig, 2011; Nathues et al., 2011; Handke et al., 2012). The archived records from the authors' institution support the former finding. Between 2004 and 2013, a total of 264 aborted fetuses from 199 sows or gilts were tested for PCV2 by PCR at the Veterinary Diagnostic Directorate, Central Agricultural Office, Budapest, and 10 cases (5%) originating from 10 different farms were found positive. Only one of these ten cases, presented in this study, was diagnosed as a PCV2-induced abortion. The fetal organs of the other 9 cases were negative for PCV2 by IHC, and no tissue lesions characteristic of PCV2 infection were evident. Two of the 9 cases were induced by bacterial infections (*Leptospira* spp., *Staphylococcus* spp.), while in the remaining 7 cases of abortion no infections were identified. The results indicate subclinical PCV2 infection of the fetuses in these nine cases.

In conclusion, PCV2-induced pig abortion is reported here for the first time in Hungary. The vascular system seems to be important in the pathogenesis of fetal PCV2 infection. The records from the past 10 years and the occurrence of a single abortion case in this affected herd indicate that the importance of PCV2 infection in swine abortion is rather low in Hungary.

### Acknowledgements

The excellent technical assistance of Mrs Ágnes Mészáros is gratefully acknowledged. This research was funded by OTKA PD/100405, a KTIA-AIK grant of the Hungarian Government.

### References

- Brunborg, I. M., Jonassen, C. M., Moldal, T., Bratberg, B., Lium, B., Koenen, F. and Schönheit, J. (2007): Association of myocarditis with high viral load of porcine circovirus type 2 in several tissues in cases of foetal death and high mortality in piglets. A case study. *J. Vet. Diagn. Invest.* **19**, 368–375.
- Correa, A. M. R., Zlotowski, P., de Barcellos, D. E. S. N., da Cruz, C. E. F. and Driemeier, D. (2007): Brain lesions in pigs affected with postweaning multisystemic wasting syndrome. *J. Vet. Diagn. Invest.* **19**, 109–112.
- Cságola, A., Kecskeméti, S., Kardos, G., Kiss, I. and Tuboly, T. (2006): Genetic characterization of type 2 porcine circoviruses detected in Hungarian wild boars. *Arch. Virol.* **151**, 495–507.
- Cságola, A., Lőrincz, M., Cadar, D., Tombác, K., Biksi, I. and Tuboly, T. (2012): Detection, prevalence and analysis of emerging porcine parvovirus infections. *Arch. Virol.* **157**, 1003–1010.
- Gerber, P. F., Garrocho, F. M., Lana, A. M. and Lobato, Z. I. (2012): Fetal infections and antibody profiles in pigs naturally infected with porcine circovirus type 2 (PCV2). *Can. J. Vet. Res.* **76**, 38–44.

- Handke, M., Engels, M., Prohaska, S., Keller, Ch., Brugnera, E., Sydler, T. and Sidler, X. (2012): Infection related fertility disorders in Swiss pig breeding farms at the end of the postweaning multisystemic wasting syndrome (PMWS) epizooty [in German]. *Schweiz. Arch. Tierheilk.* **154**, 437–444.
- Kim, J., Jung, K. and Chae, C. (2004): Prevalence of porcine circovirus type 2 in aborted foetuses and stillborn piglets. *Vet. Rec.* **155**, 489–492.
- Kiss, I., Kecskeméti, S., Tuboly, T., Bajmóczy, E. and Tanyi, J. (2000): New pig disease in Hungary: postweaning multisystemic wasting syndrome caused by circovirus. *Acta Vet. Hung.* **48**, 469–475.
- Langohr, I. M., Stevenson, G. W., Nelson, E. A., Lenz, S. D., HogenEsch, H., Wei, H. and Pogranichniy, R. M. (2010): Vascular lesions in pigs experimentally infected with porcine circovirus type 2 serogroup B. *Vet. Pathol.* **47**, 140–147.
- Madson, D. M. and Opriessnig, T. (2011): Effect of porcine circovirus type 2 (PCV2) infection on reproduction: disease, vertical transmission, diagnostics and vaccination. *Anim. Health Res. Rev.* **12**, 47–65.
- Maldonado, J., Segalés, J., Martínez-Puig, D., Calsamiglia, M., Riera, P., Domingo, M. and Artigas, C. (2005): Identification of viral pathogens in aborted fetuses and stillborn piglets from cases of swine reproductive failure in Spain. *Vet. J.* **169**, 454–456.
- Molnár, T., Glávits, R., Szeredi, L. and Dán, Á. (2002): Occurrence of porcine dermatitis and nephropathy syndrome in Hungary. *Acta Vet. Hung.* **50**, 5–16.
- Nathues, H., Tegeler, R., Grummer, B. and Grosse Beilage, E. (2011): Infectious agent detection in reproductive disorders in swine herds. Retrospective evaluation of diagnostic laboratory examinations [in German]. *Tierarztl. Prax. Ausg. G. Grosstiere Nutztiere* **39**, 155–161.
- Oleksiewicz, M. B., Bøtner, A., Madsen, K. G. and Storgaard, T. (1998): Sensitive detection and typing of porcine reproductive and respiratory syndrome virus by RT-PCR amplification of whole viral genes. *Vet. Microbiol.* **64**, 7–22.
- Opriessnig, T. and Langohr, I. (2012): Current state of knowledge on porcine circovirus type 2-associated lesions. *Vet. Pathol.* **50**, 23–38.
- Opriessnig, T., Janke, B. H. and Halbur, P. G. (2006): Cardiovascular lesions in pigs naturally or experimentally infected with porcine circovirus type 2. *J. Comp. Pathol.* **134**, 105–110.
- Opriessnig, T., Meng, X. J. and Halbur, P. G. (2007): Porcine circovirus type 2-associated disease: update on current terminology, clinical manifestations, pathogenesis, diagnosis, and intervention strategies. *J. Vet. Diagn. Invest.* **19**, 591–615.
- Park, J. S., Kim, J., Ha, Y., Jung, K., Choi, C., Lim, J. K., Kim, S. H. and Chae, C. (2005): Birth abnormalities in pregnant sows infected intranasally with porcine circovirus 2. *J. Comp. Pathol.* **132**, 139–144.
- Resendes, A. R. and Segalés, J. (2014): Characterization of vascular lesions in pigs affected by porcine circovirus type 2-systemic disease. *Vet. Pathol.* DOI: 10.1177/0300985814540542.
- Ritzmann, M., Wilhelm, S., Zimmermann, P., Etschmann, B., Bogner, K. H., Selbitz, H. J., Heinitzi, K. and Truyen, U. (2005): Prevalence and association of porcine circovirus type 2 (PCV2), porcine parvovirus (PPV) and porcine reproductive and respiratory syndrome virus (PRRSV) in aborted fetuses, mummified fetuses, stillborn and nonviable neonatal piglets [in German]. *Dtsch. Tierarztl. Wochenschr.*, **112**, 348–351.
- Sanchez, R. E. Jr., Meerts, P., Nauwynck, H. J. and Pensaert, M. B. (2003): Change of porcine circovirus 2 target cells in pigs during development from fetal to early postnatal life. *Vet. Microbiol.* **95**, 15–25.
- Seeliger, F. A., Brüggemann, M. L., Krüger, L., Greiser-Wilke, I., Verspohl, J., Segalés, J. and Baumgartner, W. (2007): Porcine circovirus type 2-associated cerebellar vasculitis in postweaning multisystemic wasting syndrome (PMWS)-affected pigs. *Vet. Pathol.* **44**, 621–634.

- Soares, R. M., Durigon, E. L., Bersano, J. G. and Richtzenhain, L. J. (1999): Detection of porcine parvovirus DNA by the polymerase chain reaction assay using primers to the highly conserved nonstructural protein gene, NS-1. *J. Virol. Methods* **78**, 191–198.
- Szeredi, L., Dán, Á., Solymosi, N., Cságola, A. and Tuboly, T. (2012): Association of porcine circovirus type 2 with vascular lesions in porcine pneumonia. *Vet. Pathol.* **49**, 264–270.
- Szeredi, L., Deim, Z. and Jánosi, Sz. (2013): Examination of the occurrence of pathogens and pathological lesions of lung samples collected from pigs died presenting respiratory clinical symptoms [in Hungarian, with English abstract]. *Magyar Állatorvosok Lapja* **135**, 293–302.
- West, K. H., Bystrom, J. M., Wojnarowicz, C., Shantz, N., Jacobson, M., Allan, G. M., Haines, D. M., Clark, E. G., Krakowka, S., McNeilly, F., Konoby, C., Martin, K. and Ellis, J. A. (1999): Myocarditis and abortion associated with intrauterine infection of sows with porcine circovirus 2. *J. Vet. Diagn. Invest.* **11**, 530–532.