

Migrating Focal Seizures and Myoclonic Status in *ARV1*-Related Encephalopathy

Francesca Darra, FnMD, Tommaso Lo Barco, MD, Roberta Opri, PhD, Elena Parrini, PhD, Claudia Bianchini, PhD, Elena Fiorini, MD, Alessandro Simonati, MD, Bernardo Dalla Bernardina, MD, Gaetano Cantalupo, MD, and Renzo Guerrini, MD, FRCP

Correspondence
Dr. Darra
francesca.darra@univr.it

Neurol Genet 2021;7:e593. doi:10.1212/NXG.0000000000000593

Abstract

Objective

To report longitudinal clinical, EEG, and MRI findings in 2 sisters carrying compound heterozygous *ARV1* mutations and exhibiting a peculiar form of developmental and epileptic encephalopathy (DEE). Neuropathologic features are also described in one of the sisters.

Methods

Clinical course description, video-EEG polygraphic recordings, brain MRI, skin and muscle biopsies, whole-exome sequencing (WES), and brain neuropathology.

Results

Since their first months of life, both girls exhibited severe axial hypotonia, visual inattention, dyskinesic movements, severe developmental delay, and slow background EEG activity. Intractable nonmotor seizures started in both at the eighth month of life, exhibiting the electroclinical characteristics of epilepsy of infancy with migrating focal seizures (EIMFS). In the second year of life, continuous epileptiform EEG activity of extremely high amplitude appeared in association with myoclonic status, leading to severely impaired alertness and responsiveness. Repeated brain MRI revealed progressive atrophic changes and severe hypomyelination. WES identified a compound heterozygous in the *ARV1* gene [(p.Ser122Glnfs*7) and (p.Trp163*)] in one patient and was subsequently confirmed in the other. Both sisters died prematurely during respiratory infections. Postmortem neuropathologic examination of the brain, performed in one, revealed atrophic brain changes, mainly involving the cerebellum.

Conclusions

This report confirms that biallelic *ARV1* mutations cause a severe form of DEE and adds epilepsy with migrating focal seizures and myoclonic status to the spectrum of epilepsy phenotypes. Considering the potential role of human *ARV1* in glycosylphosphatidylinositol (GPI) anchor biosynthesis, this severe syndrome can be assigned to the group of inherited GPI deficiency disorders, with which it shares remarkably similar clinical and neuroimaging features. *ARV1* should be considered in the genetic screening of individuals with EIMFS.

MORE ONLINE

▶ Video

From the Child Neuropsychiatry Unit(F.D.), Department of Surgical Sciences, Dentistry, Gynecology and Pediatrics University of Verona; Child Neuropsychiatry Unit(T.L.B.), Department of Surgical Sciences, Dentistry, Gynecology and Pediatrics University of Verona; PhD Program in Clinical and Experimental Medicine (T.L.B.), University of Modena and Reggio Emilia; Pediatric Unit (R.O.), Department of Surgical Sciences, Dentistry, Gynecology and Pediatrics University of Verona; Pediatric Neurology (E.P.), Neurogenetics and Neurobiology Unit and Laboratories, Meyer Children's Hospital, University of Florence; Pediatric Neurology (C.B.), Neurogenetics and Neurobiology Unit and Laboratories, Meyer Children's Hospital, University of Florence; Child Neuropsychiatry Unit (E.F.), Azienda Ospedaliera Universitaria Integrata di Verona; Neurology (Child Neurology and Neuropathology) (A.S.), Department of Neuroscience, Biomedicine and Movement, University of Verona; CREP (Research Center for Pediatric Epilepsies) (B.D.B.), Azienda Ospedaliera Universitaria Integrata di Verona; and Pediatric Neurology (R.G.), Neurogenetics and Neurobiology Unit and Laboratories, Meyer Children's Hospital, University of Florence, Italy.

Go to [Neurology.org/NG](https://www.neurology.org/NG) for full disclosures. Funding information is provided at the end of the article.

The Article Processing Charge was funded by the authors.

This is an open access article distributed under the terms of the Creative Commons Attribution-NonCommercial-NoDerivatives License 4.0 (CC BY-NC-ND), which permits downloading and sharing the work provided it is properly cited. The work cannot be changed in any way or used commercially without permission from the journal.

Glossary

DEE = developmental and epileptic encephalopathy; EIMFS = epilepsy of infancy with migrating focal seizure; ER = endoplasmic reticulum; GPI = glycosylphosphatidylinositol; WES = whole-exome sequencing.

The *ARVI* gene encodes for Acyl-CoA cholesterol acyl transferase-related enzyme 2 required for viability 1 (*ARVI*), which is a highly conserved protein located in the endoplasmic reticulum membrane. Although extensive functional studies in yeasts and mice have explored the consequences of *ARVI* mutations,¹⁻⁴ the association of biallelic mutations of this gene with human disease is limited to a few individuals exhibiting early infantile epileptic encephalopathy, with intractable seizures and severe developmental delay.⁵⁻⁸

In 1 patient, the epilepsy phenotype featured drug-resistant multifocal clustered seizures, disorganized background EEG activity, and modified hypsarrhythmia⁵; in the remaining children, details on the epileptic encephalopathy were not provided.

We describe 2 sisters carrying compound heterozygous *ARVI* mutations and exhibiting an early-onset epileptic encephalopathy with peculiar electroclinical features.

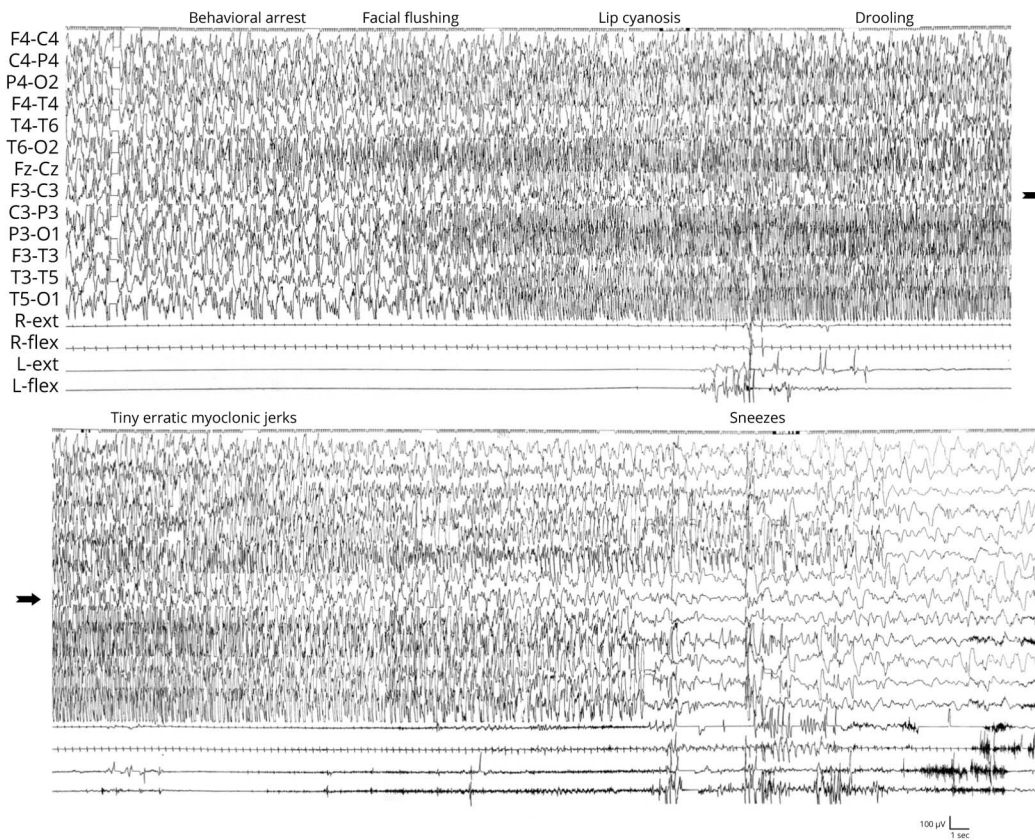
Case Description

Patient 1

Patient 1 is a first-born girl with nonconsanguineous parents who was delivered by elective C-section at 36 + 5 gestational weeks. Her birth weight was 2650 g (50th percentile), length 46 cm (25th percentile), head circumference 32.7 cm, (40th percentile), and Apgar Index 8/9.

At 4 months, hypotonia was noticed, with dyskinetic movements, opisthotonus posturing, and absence of eye tracking.

Figure 1 Patient 1. Focal Seizure With a Migrating Pattern



Top: note on the right hemisphere the progressive onset of an ictal discharge of fast polyspike waves involving mainly the temporo-parietal regions related to psychomotor arrest and flushing. A few seconds later, a similar discharge independently appears on the left parieto-temporal region, associated with increasing lip cyanosis and drooling. Bottom: a few seconds later, erratic mild myoclonic jerks appear involving mainly the face. At the end of the left-sided ictal event, the child sneezes; the seizure lasts a few more seconds on the right hemisphere.

At 6 months, severe axial hypotonia, abnormal movements, and absent eye fixation persisted. EEG showed slow high-amplitude background activity ($>400 \mu\text{V}$), replaced 1 month later by subcontinuous high-amplitude multifocal spikes and waves on both hemispheres.

From age 8 months, multiple per-day focal nonmotor seizures started, with unresponsiveness, chewing automatisms, and perioral cyanosis, lasting less than a minute. Despite treatment with valproate, at age 12 months, seizures increased in frequency, appearing at times in clusters, showing multifocal origin and involving either hemisphere with a migrating pattern (figure 1), prompting repeated intensive care unit admissions. Transition from focal seizures to hemiclonic status was often seen, especially during fever (figure 2). Polygraphic EEG recordings revealed an unusual pattern of myoclonic status featuring subcontinuous rhythmic or arrhythmic spikes and slow waves of very high amplitude, associated with reduced responsiveness and erratic myoclonus predominating in the arms and face. During sleep, myoclonus disappeared, but the abnormal EEG pattern remained subcontinuous (figure 3A).

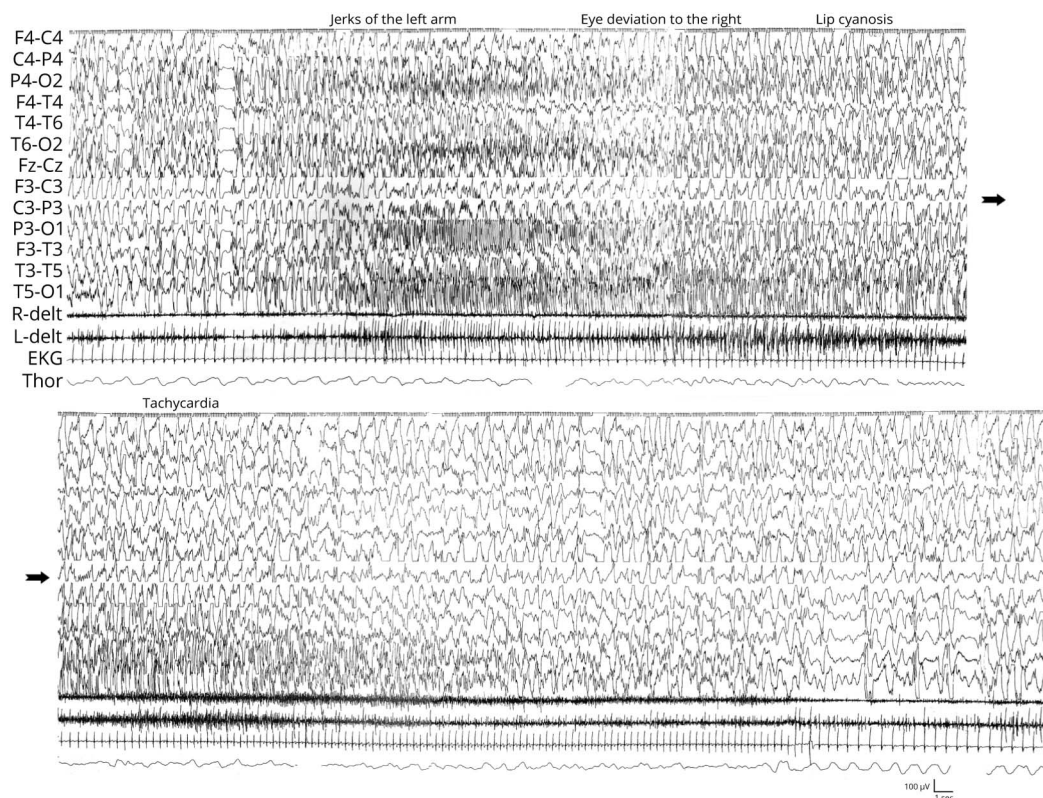
Myoclonic status and clustered multifocal seizures persisted despite several pharmacologic trials (including phenobarbital,

phenytoin, ethosuximide, levetiracetam, carbamazepine, and hydrocortisone). Only the ketogenic diet reduced seizure frequency for 10 consecutive months, from several per-day to monthly clusters triggered by fever, remission of myoclonic status episodes, and improved awareness.

By age 3 years, head growth dropped to below the third percentile, and the overall clinical picture worsened because of almost continuous focal seizures and myoclonic status (figure 3B), with recurrent respiratory infections, leading to demise at 4 years 2 months due to bronchopneumonia during status epilepticus. No clinical or electrocardiographic signs of cardiomyopathy were noticed.

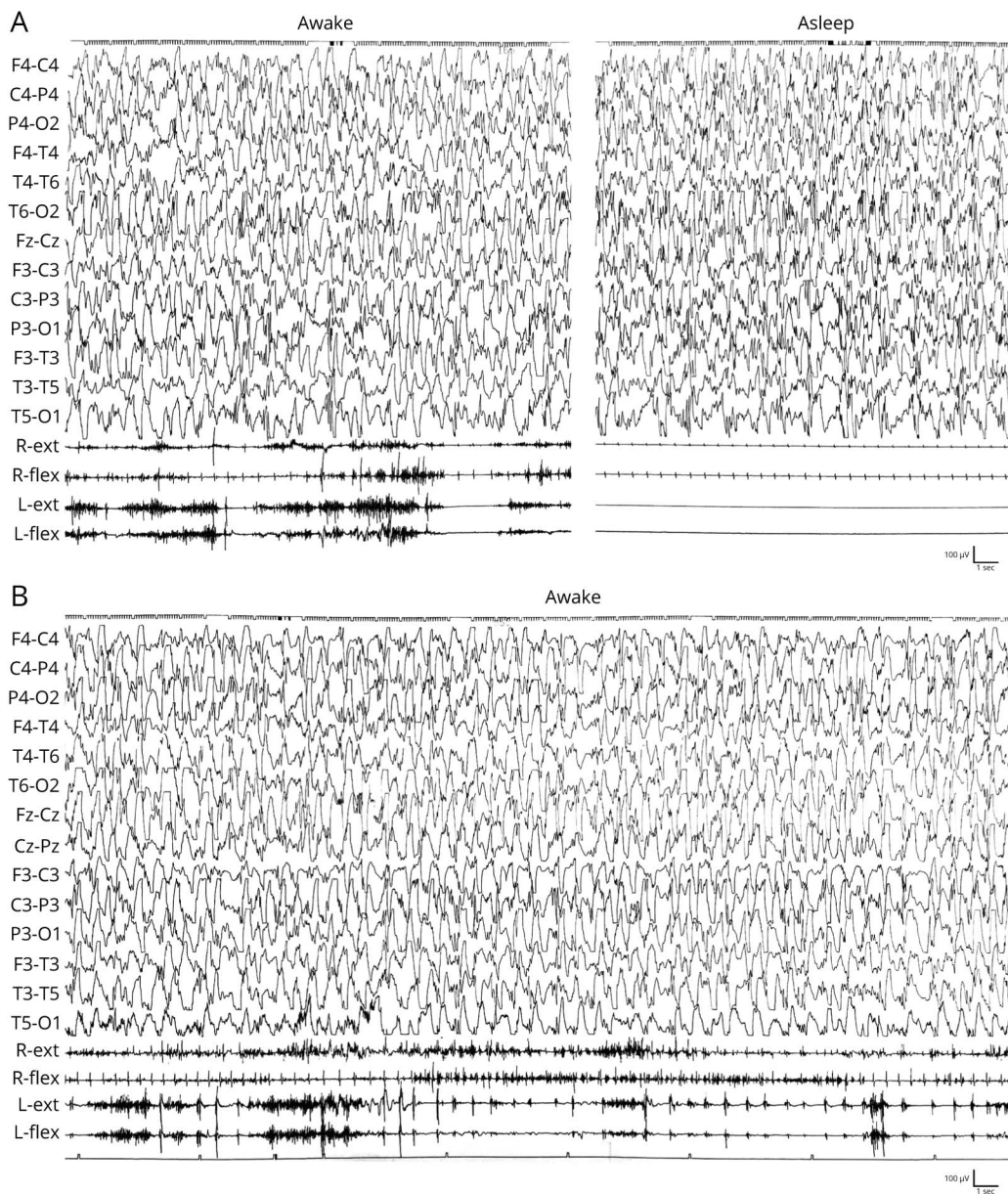
Extensive biological and metabolic investigations on urine, blood and CSF, karyotype, Comparative Genomic Hybridization array (CGH-array), histologic and ultrastructural examination of skin and muscle biopsy, and study of mitochondrial respiratory chain enzymes were all unrevealing. Eye fundus, sensitive evoked potential (SEP), and ERG persisted in normal limits, whereas visual evoked potentials (VEP) progressively extinguished. Brain MRI, performed at 4 months, showed a thin corpus callosum (figure 4A). A second MRI, at 24 months, showed mild brain atrophy, mainly involving the right temporal

Figure 2 Patient 1. Hemiclonic Seizure



On the top: during an ictal discharge of polyspikes and waves with intermixed fast activity involving the right centro-parietal region, associated with rhythmic jerks of the left arm, a similar ictal discharge independently involves the left temporo-occipital region and is associated with eye deviation to the right, lip cyanosis, and intense tachycardia. On the bottom: cyanosis and tachycardia resolve only at the end of the left temporal discharge, which lasts longer than that involving the right hemisphere.

Figure 3 Patient 1. Myoclonic Status



(A) Note on the EEG during wakefulness, subcontinuous, diffuse high-amplitude spike waves intermingled with polyspikes, synchronous, and asynchronous on the hemispheres, associated with subcontinuous erratic myoclonic jerks, partially masked by dyskinetic movements. During sleep, continuous EEG discharges persist in the absence of recognizable physiologic elements, whereas motor manifestations disappear. (B) Note on the EEG the continuous SW of very high amplitude, involving both hemispheres, accompanied on EMG channels by rhythmic but bilaterally asynchronous myoclonic activity.

lobe, hypomyelination, and cerebellar atrophy, more severely affecting the vermis (figure 4B–D).

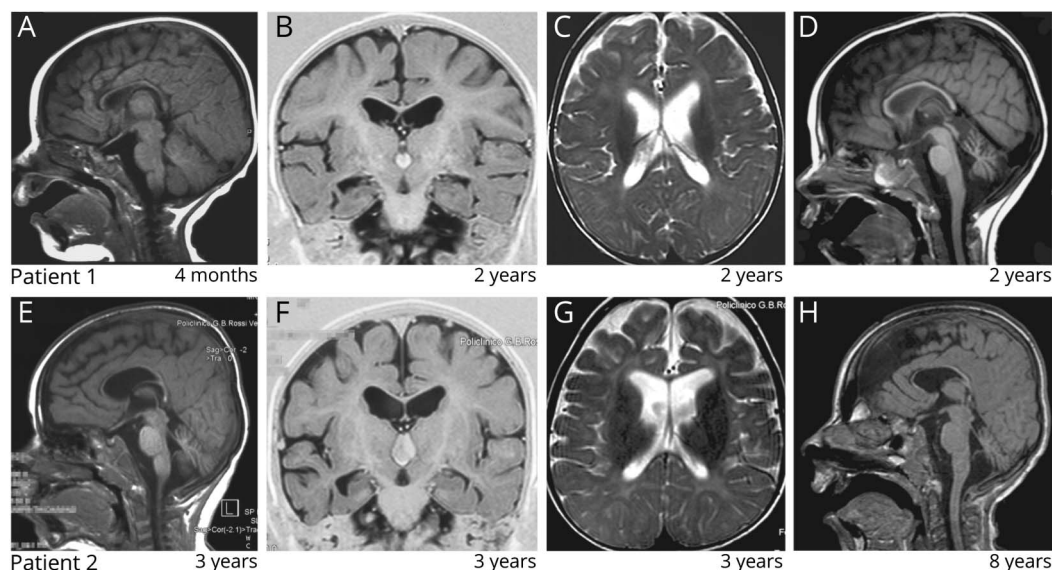
Postmortem examination identified the cause of death with acute respiratory distress syndrome and a hypertrophic cardiomyopathy with subvalvular stenosis. Brain neuropathology documented cerebral atrophy, more severe in the right temporal lobe, with concomitant Ammon horn sclerosis and abnormal morphology of the parahippocampal gyrus. The corpus callosum was thin and the cerebellum atrophic, with reduced cortical thickness, especially in the vermis. The cytoarchitectonic organization of the cerebral cortex was normal, whereas

severe and diffuse loss of Purkinje cells was present in the cerebellar cortex, with dystrophic dendrites in the molecular layer, cell rarefaction in the inner granular layer, and Bergmann gliosis. There was, in addition, an abnormal organization of the dentate gyri bilaterally, with mild gliosis. Subcortical gray nuclei, brainstem, and the spinal cord were normal.

Patient 2

Patient's one younger sister was born at 37 gestational weeks, following an uneventful pregnancy; at birth, her weight was 3,210 g (75° percentile), and head circumference was 34.7 cm (75° percentile).

Figure 4 MRI Findings of Two Patients



Patient 1: (A) Sagittal T1W section showing a thin corpus callosum. (B) Coronal T1W section showing signs of mild atrophy mainly involving the right temporal lobe, which shows gyral simplification and a dilated temporal horn. (C) T2W axial section showing high signal intensity of the white matter, consistent with hypomyelination. (D) Sagittal T1W section showing atrophy of the cerebellar vermis. Patient 2: (E) Sagittal T1W section showing a thin corpus callosum and a mildly atrophic cerebellar vermis. (F) Coronal T1W image showing signs of mild atrophy mainly involving the right temporal lobe, which shows enlarged sulci and a dilated temporal horn. (G) T2W axial section showing high signal intensity of the white matter, consistent with hypomyelination. (H) Sagittal T1W section showing more severe atrophy of the cerebellar vermis.

Severe axial hypotonia, with opisthotonos posturing and jitteriness, resulting in a hypotonic-dyskinetic quadriplegia was already apparent at 4 months (figure 5A). Visual pursuit was poor; ocular fundus examination, VEPs, and SEPs were normal. Head growth slowed down to around the 3rd percentile before age 2 years.

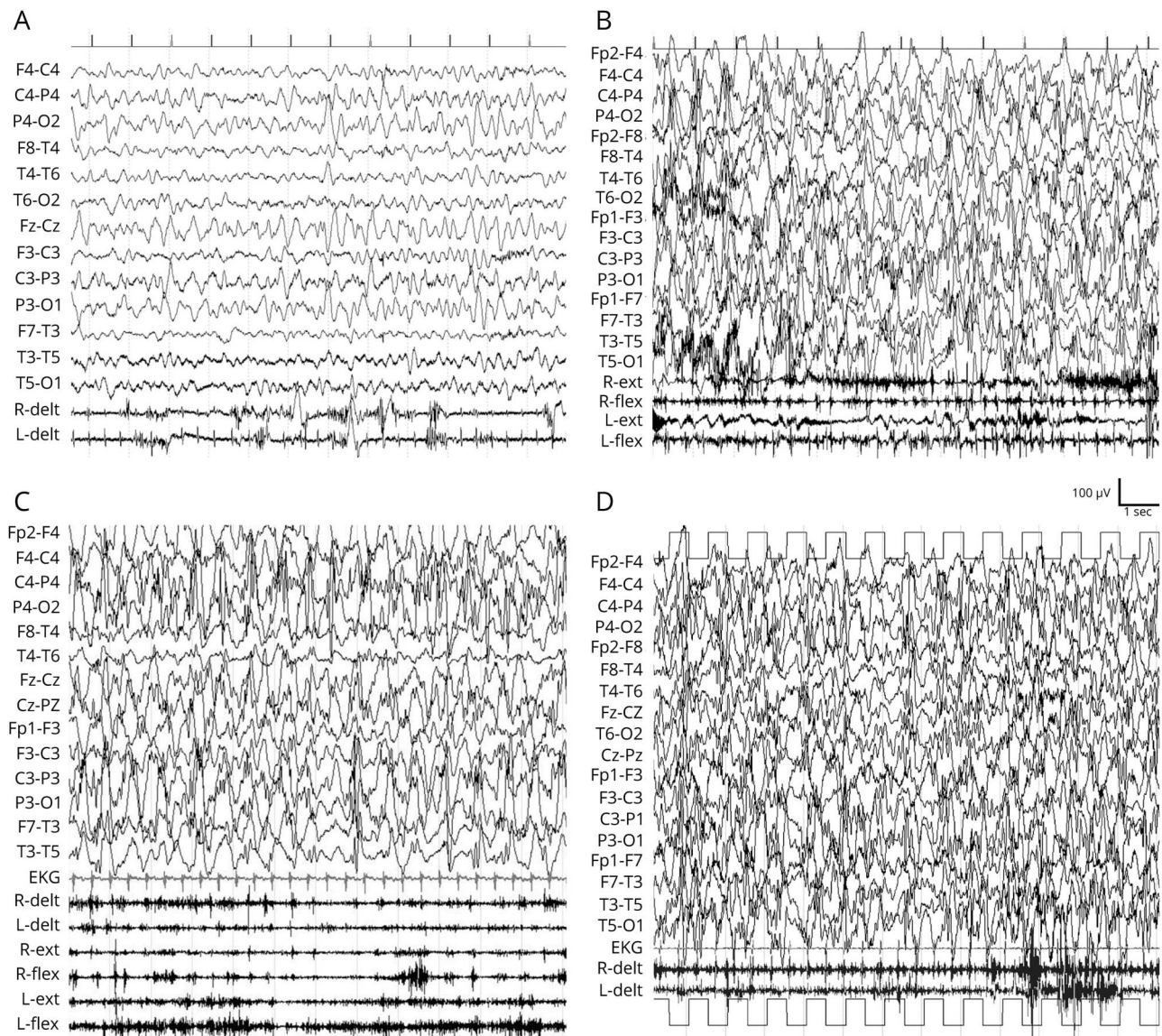
From age 8 months, the girl exhibited multiple seizures per day. Video-EEG recordings captured focal ictal activity arising independently from the centro-temporal-parietal regions of either hemisphere (video 1) causing psychomotor arrest, apnea, cyanosis, deviated gaze, and lasting 30–60 seconds. Prolonged focal motor seizures triggered by fever at times evolved as hemiclonic status epilepticus. Interictal EEG activity was of high amplitude (>400 μ V), intermingled with multifocal discharges. Phenobarbital was ineffective; the ketogenic diet, started at 11 months, determined a temporary reduction in seizure frequency. Seizures remained uncontrolled, and at 18 months, polygraphic EEG recordings documented the same peculiar myoclonic status epilepticus observed in this patient's sister (figure 5B). Dilated cardiomyopathy with partial hemodynamic decompensation was diagnosed. ECG documented I- and II-degree atrioventricular block, and physical examination showed hepatosplenomegaly.

During follow-up, head growth slowed down to below the 3rd percentile. The frequency of focal seizures decreased to one cluster per month, mostly during fever; myoclonic status remained unchanged (figures 5C,5D) until demise, at age 9 years during pneumonia.

Brain MRI, performed at 7 months, showed a thin corpus callosum. A new MRI, at age 3 years, showed a mildly atrophic cerebellar vermis, a small right hippocampus, and hypomyelination (figure 4E–G). At age 8 years, atrophic changes were more obvious, mainly involving the cerebellum (figure 4H).

Whole-exome sequencing, performed in patient 2 at age 8 years, identified compound heterozygous mutations in the *ARV1* gene (NM_022786.3), c.363_364del (p.Ser122Glnfs*7) inherited from the mother, and c.489 G > A (p.Trp163*) inherited from the father. Sanger sequencing, performed in a DNA sample from formalin-fixed paraffin-embedded brain tissue of patient 1, confirmed both mutations. The p.Ser122Glnfs*7 mutation is present in the gnomAD control database (gnomad.broadinstitute.org/) with a frequency of 4/250,498 alleles and is not reported in the Human Gene Mutation Database (HGMD) (portal.biobase-international.com/hgmd/pro/start.php). The p.Trp163* mutation is not present in the gnomAD control database (gnomad.broadinstitute.org/) and in the HGMD mutation database (portal.biobase-international.com/hgmd/pro/start.php). Both mutations introduce a premature stop codon in the mRNA and are predicted to elicit a rapid degradation of the *ARV1* mRNA through nonsense-mediated mRNA decay. The MutationTaster (mutationtaster.org/) tool predicts both mutations to be disease causing. We classified both mutations as pathogenic according to the international guidelines of the ACMG Laboratory Practice Committee Working Group.⁹

Figure 5 Patient 2. Abnormal Background Activity and Myoclonic Status



(A) Note on the EEG the unusually slow and high-amplitude poorly modulated theta-delta activity on the parieto-occipital regions and on the EMG the abnormal dyskinetic movements. (B) Note on the EEG continuous, diffuse, high-amplitude (about 400 μ V) epileptiform activity associating polyspike-waves and a diffuse very fast activity related to continuous rhythmic jerks. This electroclinical picture remains unchanged throughout the evolution (C) up to 9 years (D).

Data Availability

The data that support the findings of this study are available on request from the corresponding author. The data are not publicly available because of privacy or ethical restrictions.

Discussion

These 2 sisters were compound heterozygous for the p.Ser122Glnfs*7 and the p.Trp163* truncating mutations and exhibited severe clinical features that overlap with those described in patients with *ARV1*-related encephalopathy, all harboring homozygous variants. Indeed, both truncating

ARV1 mutations found in our patients are predicted to result in loss of function, the molecular mechanism known to be associated with *ARV1* deficiency, both in humans and mice.^{5,8}

ARV1, mapping to 1q42.2, encodes for a transmembrane protein of endoplasmic reticulum (ER) implied in sterol homeostasis in eukaryotic cells, with a role in sterol transport between the ER and plasmatic membrane.³ As already stated,⁵ because of its implication in glycosylphosphatidylinositol (GPI)-anchor synthesis,^{10,11} ER stress induced by accumulation of immature GPI-anchored proteins or aberrant lipid metabolism may be responsible for the diseases associated with *ARV1* deficiency.¹¹

Evidence of a genetic syndrome resulting from deficiency of ARV1 in humans is currently based on the description of 14 patients from 5 families, all harboring homozygous variants. The overall common reported clinical features include severe developmental delay and intractable seizures with onset in the first year of life in all and seizure onset within the 6th months in 50%. Additional clinical features included poor head control (10/14), hypotonia (8/14), visual impairment (9/14), and dystonia (6/14). Seven patients died prematurely because of respiratory infections or aspiration pneumonia, mostly during status epilepticus (1–5 years). Six remaining patients were still alive at last follow-up, between age 2 years 5 months and 18 years.^{5–8} Progressive deceleration of head growth is reported in 5 patients and mild-moderate dilated cardiomyopathy in 2.⁷

Reported MRI findings include cerebellar atrophy in 3 individuals, delayed myelination in 2, a thin corpus callosum in 1, and a hyperintense signal on T2-weighted with restricted diffusion in the cerebral central tegmental tract in one.^{5,7,8} No MRI abnormalities were observed in 2 individuals aged 7 months and 3 years, respectively.^{7,8} Overall, reported clinical features are similar to those observed in our patients, who harbored compound heterozygous variants.

In the 2 sisters we describe, severe axial hypotonia, dystonic/dyskinetic movements, poor visual contact, and head growth deceleration were already manifested a few weeks after birth and, from the third to the fourth month of life, subcontinuous myoclonic jerks intermingled to dyskinetic movements appeared. The associated electroclinical picture was quite distinctive, consisting of intractable migrating focal motor and nonmotor seizures^{12,13} and a peculiar myoclonic status mainly involving the face and upper limbs, resembling the electroclinical syndrome known as myoclonic status of nonprogressive epileptic encephalopathies.^{14,15} The overall neurologic condition progressively worsened, leaving both girls severely hypotonic, with almost continuous abnormal movements, poor eye contact, absent speech, profound intellectual disability, and recurrent respiratory infections. The older girl was affected by dilated cardiomyopathy, and her sister exhibited left ventricular hypertrophy, which was documented at autopsy not to be associated with abnormalities of the myocardial tissue.

Brain MRI findings in both patients documented malformative characteristics in association with progressive cerebellar atrophy. The association of these findings favors the hypothesis of a GPI-anchor–related disorder, which plays a key role in embryogenesis, neurogenesis, and synaptic formation.¹⁶ To additionally support this hypothesis, the core symptoms of patients with ARV1 deficiency reported previously⁵ and in our study, are also seen in inherited GPI deficiency conditions.^{17–20} Of note, migrating focal seizures,

dilated cardiomyopathy, and fever sensitivity can also be found in both of these conditions.^{21,22}

This report confirms the evidence for an autosomal recessive early-onset developmental and epileptic encephalopathy (DEE) caused by biallelic ARV1 mutations in humans and describes the first family with compound heterozygous mutations. It also suggests that ARV1 mutations should be considered a possible cause of epilepsy of infancy with migrating focal seizures.

Considering the potential role of human ARV1 in GPI-anchor biosynthesis, this genetic syndrome could be considered in the group of inherited GPI deficiency disorders.^{19,20,22,23}

This syndrome epitomizes difficulties in sharply parting the category of the DEEs from that of the progressive neurologic disorders at the early stages of clinical diagnosis. Such dichotomous classification is obviously unsatisfactory when applied to peculiar clinical features such as those reported in this study, in which the combination of severe neurologic impairment and almost continuous epileptic activity makes it difficult to identify the main determinants of clinical presentation. The DEE category in this context is more a tentative broad category awaiting diagnostic finalization.

Study Funding

No targeted funding reported.

Disclosure

The authors report no disclosures. Go to [Neurology.org/NG](https://www.neurology.org/NG) for full disclosures.

Publication History

Received by *Neurology: Genetics* August 16, 2020. Accepted in final form March 23, 2021.

Appendix Authors

Name	Location	Contribution
Francesca Darra, FNMD	University of Verona, Italy	Major role in the acquisition of data; designed and conceptualized the study; analyzed the data; and drafted the manuscript for intellectual content
Tommaso Lo Barco, MD	University of Verona, Italy	Acquisition of data; analyzed the data; drafted the manuscript for intellectual content; and prepared figures
Roberta Opri, MD	University of Verona, Italy	Interpreted the data and revised the manuscript for intellectual content
Elena Parrini, PhD	AOU Meyer, Firenze, Italy	Performed genetic test; interpreted genetic data; and revised the manuscript for intellectual content
Claudia Bianchini, PhD	AOU Meyer, Firenze, Italy	Performed genetic test; interpreted genetic data; and revised the manuscript

Continued

Appendix (continued)

Name	Location	Contribution
Elena Fiorini, MD	AOUI Verona, Italy	Acquisition of data and revised the manuscript
Alessandro Simonati, MD	University of Verona, Italy	Acquisition of data and performed neuropathologic examination
Bernardo Dalla Bernardina, MD	University of Verona, Italy	Major role in the acquisition of data; contributed to conceptualize the study; analyzed the data; and revised the manuscript
Gaetano Cantalupo, MD	University of Verona, Italy	Acquisition of data; analyzed the data; contributed to prepare figures; and revised the manuscript
Renzo Guerrini, MD FRCP	AOU Meyer, Firenze, Italy	Performed genetic test; interpreted genetic data; analyzed the data; contributed to draft the manuscript for intellectual content; and revised the manuscript for intellectual content

References

1. Tinkelenberg AH, Liu Y, Alcantara F, et al. Mutations in yeast *ARV1* alter intracellular sterol distribution and are complemented by human *ARV1*. *J Biol Chem*. 2000; 275(52):40667-40670.
2. Shechtman CF, Henneberry AL, Seimon TA, et al. Loss of subcellular lipid transport due to *ARV1* deficiency disrupts organelle homeostasis and activates the unfolded protein response. *J Biol Chem*. 2011;286(14):11951-11959.
3. Georgiev AG, Johansen J, Ramanathan VD, Sere YY, Beh CT, Menon AK. *Arv1* regulates PM and ER membrane structure and homeostasis but is dispensable for intracellular sterol transport. *Traffic*. 2013;14(8):912-921.
4. Lagor WR, Tong F, Jarrett KE, et al. Deletion of murine *Arv1* results in a lean phenotype with increased energy expenditure. *Nutr Diabetes*. 2015;5(10):e181.
5. Palmer EE, Jarrett KE, Sachdev RK, et al. Neuronal deficiency of *ARV1* causes an autosomal recessive epileptic encephalopathy. *Hum Mol Genet*. 2016;25(14):3042-3054.
6. Alazami AM, Patel N, Shamseldin HE, et al. Accelerating novel candidate gene discovery in neurogenetic disorders via whole-exome sequencing of prescreened multiplex consanguineous families. *Cell Rep*. 2015;10(2):148-161.
7. Segel R, Aran A, Gulsuner S, et al. A defect in GPI synthesis as a suggested mechanism for the role of *ARV1* in intellectual disability and seizures. *Neurogenetics*. 2020;21(4):259-267.
8. Davids M, Menezes M, Guo Y, et al. Homozygous splice-variants in human *ARV1* cause GPI-anchor synthesis deficiency. *Mol Genet Metab*. 2020;130(1):49-57.
9. Richards S, Aziz N, Bale S, et al. Standards and guidelines for the interpretation of sequence variants: a joint consensus recommendation of the American College of Medical Genetics and Genomics and the association for molecular pathology. *Genet Med*. 2015;17(15):405-424.
10. Kajiwara K, Watanabe R, Pichler H, et al. Yeast *ARV1* is required for efficient delivery of an early GPI intermediate to the first mannosyltransferase during GPI assembly and controls lipid flow from the endoplasmic reticulum. *Mol Biol Cell*. 2008;19(5):2069-2082.
11. Ikeda A, Kajiwara K, Iwamoto K, et al. Complementation analysis reveals a potential role of human *ARV1* in GPI anchor biosynthesis. *Yeast*. 2016;33(2):37-42.
12. Coppola G, Plouin P, Chiron C, Robain O, Dulac O. Migrating partial seizures in infancy: a Malignant disorder with developmental arrest. *Epilepsia*. 1995;36(10):1017-1024.
13. Caraballo RH, Fontana E, Darra F, et al. Migrating focal seizures in infancy: analysis of the electroclinical patterns in 17 patients. *J Child Neurol*. 2008;23(5):497-506.
14. Dalla Bernardina B, Fontana E, Darra F. Myoclonic status in nonprogressive encephalopathies. *Adv Neurol*. 2005;95(50 suppl 5):59-70.
15. Caraballo RH, Cersósimo RO, Espeche A, Arroyo HA, Fejerman N. Myoclonic status in nonprogressive encephalopathies: study of 29 cases. *Epilepsia*. 2007;48(1):107-113.
16. Um JW, Ko J. Neural glycosylphosphatidylinositol-anchored proteins in synaptic specification. *Trends Cell Biol*. 2017;27(12):931-945.
17. Nguyen TTM, Murakami Y, Sheridan E, et al. Mutations in *GPAA1*, encoding a GPI transamidase Complex protein, cause developmental delay, epilepsy, cerebellar atrophy, and osteopenia. *Am J Hum Genet*. 2017;101(5):856-865.
18. Knaus A, Kortüm F, Kleefstra T, et al. Mutations in *PIGU* impair the function of the GPI transamidase Complex, causing severe intellectual disability, epilepsy, and brain anomalies. *Am J Hum Genet*. 2019;105(2):395-402.
19. Tarailo-Graovac M, Sinclair G, Stockler-Ipsiroglu S, et al. The genotypic and phenotypic spectrum of *PIGA* deficiency. *Orphanet J Rare Dis*. 2015;27(10):23.
20. Kato M, Saito H, Murakami Y, et al. *PIGA* mutations cause early-onset epileptic encephalopathies and distinctive features. *Neurology*. 2014;82(18):1587-1596.
21. Burgess R, Wang S, McTague A, et al. The genetic landscape of epilepsy of infancy with migrating focal seizures. *Ann Neurol*. 2019;86(6):821-831.
22. Bayat A, Knaus A, Pendziwiat M, et al. Lessons learned from 40 novel *PIGA* patients and a review of the literature. *Epilepsia*. 2020;61(6):1142-1155.
23. Vetro A, Pisano T, Chiaro S, et al. Early infantile epileptic-dyskinetic encephalopathy due to biallelic *PIGP* mutations. *Neurol Genet*. 2020;6(1):e387.