


Clinical Notes

Intestinal obstruction caused by a clamped persistent omphalomesenteric duct in congenital hernia into the umbilical cord

Zlatan Zvizdic,¹ Emir Milisic¹ and Semir Vranic^{2,3} ¹*Clinic of Pediatric Surgery, University Clinical Center Sarajevo, Sarajevo, Bosnia and Herzegovina* ²*College of Medicine,*³*Biomedical and Pharmaceutical Research Unit, QU Health, Qatar University, Doha, Qatar***Key words** hernia into the umbilical cord, iatrogenic, intestinal obstruction, persistent omphalomesenteric duct, umbilical clamp.

A congenital hernia into the umbilical cord (CHUM) is often misinterpreted as a mild form of omphalocele. Herniated content in CHUM can be either the solitary intestinal loop or persistent omphalomesenteric duct (POMD) with the potential for traumatic injury in a case of inadequate examination of the umbilical cord and its clamping in the delivery room.¹

Herein, we report a case of a male newborn with a functional bowel obstruction due to peritonitis caused by necrosis of iatrogenically clamped POMD in the CHUM. A 2-day-old full-term male infant was referred to the emergency department with a 1 day history of bilious vomiting, a gradual increase in abdominal distension, and absence of passage of meconium. The infant was born at 38 weeks' gestation with a birthweight of 2,885 g. The baby was born following an uncomplicated pregnancy and a normal spontaneous vaginal delivery. The Apgar scores were eight at both 1 and 5 min. On physical examination, his abdomen was slightly distended by an umbilical ligation clip placed approximately 2.5 cm from the enlarged base of the umbilical cord (Fig. 1a). The stump of the umbilical cord was thickened and red. The baby was pale and dehydrated. An abdominal radiograph showed dilated small bowel loops due to small bowel obstruction (Fig. 1b). After resuscitation, a surgical exploration via a circumumbilical incision revealed a clamped POMD in the umbilical cord. The top of the POMD was crushed by the umbilical cord clamp (Fig. 1c). The POMD was resected at its base on the ileal loop. The ileal loop was closed transversely using 5-0 Vicryl by single-layer extra mucosal-interrupted sutures. The postoperative recovery was uneventful at a follow up of 8 years.

Evaluation of the umbilical cord is a routine part of every newborn examination in the delivery room. Any suspected

Correspondence: Semir Vranic, MD PhD, College of Medicine, QU Health, Qatar University, PO Box 2713, Doha, Qatar. Email: semir.vranic@gmail.com or svranic@qu.edu.qa

Received 18 September 2020; revised 22 December 2020; accepted 7 January 2021.

abnormal thickening of the base of the umbilical cord or any other malformations found should be further evaluated by a neonatologist or pediatric surgeon.

Congenital hernia into the umbilical cord is a type of ventral abdominal wall defect in which the bowel usually herniates into the base of normally inserted umbilical cord through a patent umbilical ring. The condition results from a failure of return of intestine loops following the physiological gut herniation around 10–12 weeks of gestation. Due to similar morphologic features, characterized by coverage of eviscerated abdominal contents with a sac comprising outer amnion and inner peritoneal lining, CHUM may be easily misdiagnosed as a small omphalocele. Unlike an omphalocele, CHUM has an intact abdominal wall with adequate muscle development and a complete umbilical ring covered by a small cuff of skin about ~2.5 cm.² Congenital hernia into the umbilical cord is usually not linked to chromosomal abnormalities but cases of trisomy 13 associated with CHUM have been reported in the literature.³ However, if missed, this condition can lead to intestinal damage by a low-placed umbilical cord clamp as it is shown in our illustrative case. Although very rare, similar complications have been reported in the literature.¹ The prevention of inadvertent bowel injury during cord clamping at delivery is possible with increased awareness and knowledge regarding CHUM.^{2,4} Primary prevention includes the prenatal sonographic CHUM detection characterized by intestinal protrusion only into the base of the hernia.⁵ The most important preventive measure if the umbilical cord is broad based is the umbilical cord clamping at a safe distance from the basis (at least 5 cm from the abdominal wall).²

In conclusion, a careful inspection of the umbilical cord of all newborns in the delivery room is essential to identify any clinically relevant umbilical abnormality (e.g., a persistence of CHUM with POMD). This would prevent any iatrogenic gut injury during umbilical cord clamping. Although these complications are rare, they should be kept in mind when performing umbilical cord clamping.

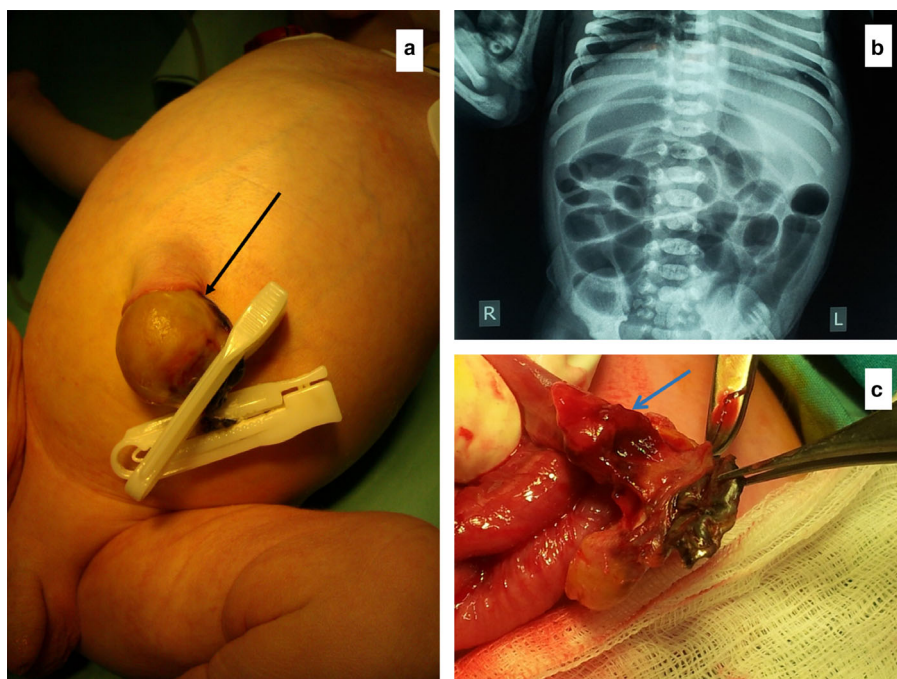


Fig. 1 (a) An umbilical ligation clip placed approximately 2.5 cm from the enlarged base of the umbilical cord (black arrow indicates congenital hernia into the umbilical cord); (b) Abdominal X-ray in the supine position on the second day of life showing dilated loops of small bowel caused by a mechanical small bowel obstruction; (c) Surgery demonstrating the capitated and crushed patent omphalomesenteric duct (blue arrow) by the umbilical cord clamp.

Acknowledgments

Open access funding provided by the Qatar National Library.

Disclosure

The authors declare no conflict of interest.

Author contributions

Z.Z. and S.V. drafted the initial manuscript. Z.Z. and E.M. treated the patient and contributed to the acquisition of clinical data and images. S.V. supervised the manuscript. All authors approved the final version of the manuscript.

Informed consent

Written informed consent was obtained from legally authorized representatives (father) for anonymized patient information to be published in this article.

References

- 1 van Tuil C, Saxena AK, Willital GH. Look twice before you clamp: decapitation of an omphaloenteric duct. A case report. *Med. Princ. Pract.* 2006; **15**(2): 156–8.
- 2 Waqas Ali S, Arain A. Large hernia of umbilical cord misdiagnosed as omphalocele. *J. Neonatal. Surg.* 2015; **4**: 36.
- 3 Nakamura K, Aoki S, Ishihara T, Nakayama K, Kanasaki H, Kyo S. Trisomy 13 with prenatally diagnosed congenital cystic adenomatoid malformation and hernia of the umbilical cord: A case report. *J. Obstet. Gynaecol.* 2017; **37**: 373–4.
- 4 Raju R, Satti M, Lee Q, Vettrano I. Congenital hernia of cord: an often misdiagnosed entity. *BMJ Case Rep.* 2015; **2015**: bcr2015209642.
- 5 Haas J, Achiron R, Barzilay E, Yinon Y, Bilik R, Gilboa Y. Umbilical cord hernias: prenatal diagnosis and natural history. *J. Ultrasound Med.* 2011; **30**(12): 1629–32.