



Europace (2012) **14**, 599–604
doi:10.1093/europace/eur353

TECHNICAL ISSUES

Usefulness of electroanatomical mapping during transseptal endocardial left ventricular lead implantation

Valentina Kutya¹, Béla Merkely¹, Szabolcs Szilágyi¹, Endre Zima¹, Attila Róka², Ákos Király¹, István Osztheimer¹, Levente Molnár¹, Gábor Széplaki¹, and László Gellér^{1*}

¹Semmelweis University, Heart Center, Városmajor utca 68, Budapest H-1122, Hungary; and ²Hospital of St. Raphael, New Haven, CT, USA

Received 14 August 2011; accepted after revision 14 October 2011; online publish-ahead-of-print 22 December 2011

Aim

Failure rate to implant left ventricular (LV) lead transvenously is 4–8% in cardiac resynchronization therapy (CRT) patients. Epicardial lead placement is an alternative method and if not applicable case reports and small series showed the feasibility of endocardial LV lead implantation. Electroanatomical mapping might be a useful tool to guide this procedure.

Methods and results

Four patients had undergone endocardial LV lead implantation after unsuccessful transvenous implantation or epicardial LV lead dysfunction using the transseptal approach. Electroanatomical mapping was used to mark the location of the transseptal puncture. This location point guided the mapping catheter from the subclavian access and facilitated positioning of the LV lead at the adjacent latest activation area of the left ventricle detected by activation mapping. Endocardial active fixation LV leads were successfully implanted in all patients with stable electrical parameters immediately after implantation and over a mean follow-up of 18.3 months (lead impedance 520 ± 177 vs. 439 ± 119 Ω and pacing threshold 0.8 ± 0.2 V, 0.5 ms vs. 0.6 ± 0.1 V, 0.5 ms, respectively). Patients were maintained on anticoagulation therapy with a target international normalized ratio of 3.5–4.5 and did not show any thromboembolic, haemorrhagic events, or infection. Echocardiography showed significant improvement of LV systolic function with marked improvement of the functional status.

Conclusions

Electroanatomical mapping is a useful technical tool to guide endocardial LV lead implantation. It helps to identify the location of the transseptal puncture and the use of activation mapping might facilitate location of the optimal lead positions during CRT.

Keywords

Endocardial • Left ventricular lead • Electroanatomical mapping guidance

Introduction

Cardiac resynchronization therapy (CRT) is an effective non-pharmacological treatment modality in patients with symptomatic congestive heart failure (HF) refractory to medical therapy, left ventricular (LV) dysfunction and wide QRS.^{1–3} The standard approach is to implant the LV lead transvenously in one tributary of the coronary sinus (CS). However, even with innovative lead technology lead placement fails in 4–8%.^{2,4} Most frequent reasons are CS occlusion, dissection, abnormal ostium of the CS,

coronary vein stenosis, lead instability, high threshold, or phrenic nerve stimulation.^{2,5,6} Epicardial lead placement is an alternative method which includes minimal-invasive thoracoscopy or lateral thoracotomy, and usually requires general anaesthesia.⁷ When epicardial LV lead implantation is contraindicated or at higher risk, LV endocardial lead implantation might be considered.⁸

Cardiac resynchronization therapy is typically delivered with an LV lead in a lateral or posterolateral position^{1–3} and is placed in the middle or distal portion of the side branch to ensure a stable position. In contrast, when using the endocardial transseptal

* Corresponding author. Tel: +36 20 365 83 30; fax: +36 1 458 68 42, Email: laszlo.geller@kardio.sote.hu

Published on behalf of the European Society of Cardiology. All rights reserved. © The Author 2011. For permissions please email: journals.permissions@oup.com.

approach, the LV lead position is independent of the coronary venous anatomy. The major difficulty of this method is to locate the transeptal puncture site performed with a transfemoral approach from the subclavian access and to find the optimal position of the LV lead within the LV cavity.

Electroanatomical mapping involves visualizing cardiac structures and gathering data of the electrical activation of the heart. This method is widely used to guide ablation procedures in the left atrium (LA) as well as in the right ventricle and left ventricle.⁹ With the use of activation mapping we can record the activation sequence of the heart. Electroanatomical mapping might be a useful tool to guide endocardial LV lead implantation for CRT.

Patients

Four patients had undergone endocardial LV lead implantation at our hospital between November 2007 and May 2010 guided by electroanatomical mapping. Indications for CRT were in accordance with the current guidelines.¹⁰ Patient characteristics are listed in Table 1. All patients had left bundle branch block (LBBB) or paced rhythm with LBBB-like morphology.

Cardiac resynchronization therapy was attempted or performed either transvenously or epicardially as a first procedure. Patient 1 had an epicardial LV lead dysfunction, the second operation was contraindicated, and the patient was referred for endocardial LV lead implantation. Patients 2 and 4 had unsuccessful transvenous LV lead implantation. Patient 3 had LV lead dysfunction after successful transvenous LV lead implantation. In Patients 2 and 3, mini-thoracotomy was contraindicated because of multiple comorbidities and a subsequent higher risk of surgical intervention. Patients 1 and 4 did not give their consent for epicardial surgical LV lead implantation. All patients had given informed consent prior to the procedure.

Pre-implant echocardiography and tissue Doppler imaging revealed severely depressed LV function and dyssynchronous activation pattern with a significant delay of the lateral ($n = 3$) and the posterolateral wall ($n = 1$). Mitral regurgitation was evaluated by colour Doppler imaging using a semi-quantitative method (grade I–IV).

Methods

The LV endocardial lead implantation was performed using a combined femoral and subclavian approach guided by electroanatomical mapping. The first step of the procedure was to introduce the CARTO Quick Star catheter (Biosense Webster, Diamond Bar, CA, USA) through the right femoral vein to capture the anatomical map of the right atrium and the right ventricle and the activation sequence of the right ventricle. The transeptal puncture was performed with the guidance of fluoroscopy and intracardiac echocardiography including continuous monitoring of the arterial pressure. Intravenous heparin was given after the transeptal puncture (5000 IU); in case of long-lasting procedures it was administered repeatedly to maintain an ACT level of 250 ms.

After successful transeptal puncture, Quick Star catheter was introduced into the transeptal sheath and the puncture point of the septum was marked on the CARTO map (Biosense Webster) with a pink dot, while the corresponding region was marked with white

Table 1 Patient characteristics and follow-up

Pt no.	Gender	Age (years)	Aetiology of cardiomyopathy	QRS (ms)	NYHA functional class	LVEF (%)	Follow-up (months)	NYHA at FU	LVEF (%) FU	MR grade before implantation (I–IV)	MR grade after implantation (I–IV)
1	Female	56	Non-ischaemic	160	III	24	27	II	38	IV	IV
2	Male	71	Ischaemic	165	III	35	21	I	44	III–IV	II–III
3	Male	45	Ischaemic	200	III–IV	24	12	II	33	II	II–III
4	Female	58	Non-ischaemic	190	III–IV	28	6	II	48	III–IV	II

Pt, patient; NYHA, New York Heart Association functional class; LV, left ventricular; CS, coronary sinus; LVEF, left ventricular ejection fraction; MR, mitral regurgitation; FU, follow-up.

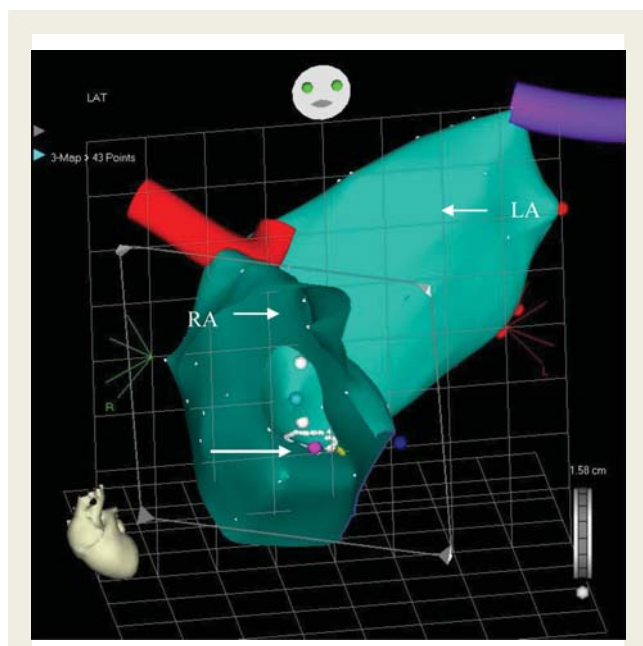


Figure 1 Patient 1. CARTO image, antero-posterior projection. The location of the transeptal puncture is indicated with a single white arrow on the CARTO map.

small dots (Figure 1). After removal of the Quick Star catheter, a guide-wire (0.035 inch \times 260 cm) was inserted into the LA and advanced into the left upper pulmonary vein and an angioplasty balloon (6 mm \times 20 mm Maverick, Boston Scientific, Natick, MA, USA) was inserted into the LA on the previously positioned guide-wire. The transeptal sheath was withdrawn into the right atrium and the balloon was positioned across the septal puncture site. It was inflated 3 times with 12 atmospheres for 5 seconds before its removal. The transeptal sheath was then positioned into the right atrial cavity.

The Quick Star deflectable catheter was introduced again into the LA and advanced into the LV cavity via the right femoral vein. Left atrial and LV anatomical and activation maps were recorded (Figure 2). The latest activation of the left ventricle was localized at the lateral wall in three patients and at the posterolateral wall in one patient.

An 11 F-long sheath (SCOUT Pro 8 Fr, Biotronik GmbH&Co, Berlin, Germany) was introduced via the left subclavian vein. The Quick Star catheter was advanced into the sheath and directed to the location of the previously marked transeptal puncture site applying CARTO map guidance.

The long sheath was forced through the interatrial septum into the LA and further into the left ventricle over the deflectable Quick Star catheter. When the sheath did not go through the site of the puncture, angioplasty balloon (6 mm \times 20 mm Maverick, Boston Scientific, Natick, MA, USA) was positioned to the puncture site through the previously applied guide-wire from the femoral access and it was inflated and deflated again, as needed. The Quick Star catheter was used to relocate the LV segment with the latest activation. When the latest activation site was found, the Quick Star catheter was withdrawn into the sheath and the sheath was pushed against the LV wall to ensure stable position. Active fixation LV leads were fixed at the basal or mid-basal portion of the left ventricle in all patients where the longest delays were detected on the activation map. Using the long

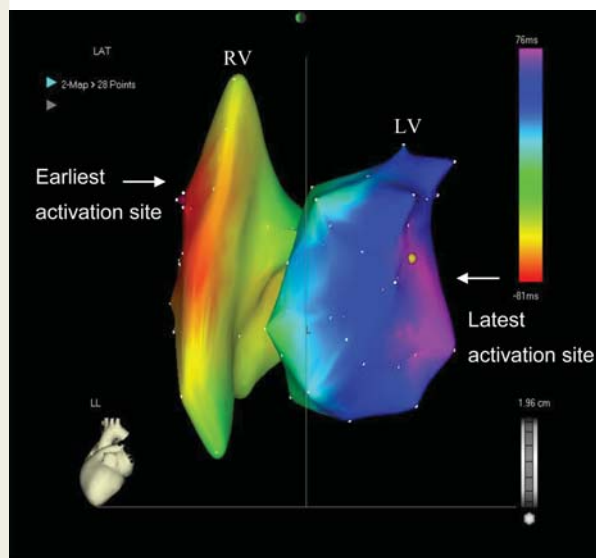


Figure 2 Patient 1. CARTO image, left lateral projection. Right and the LV activation map: the earliest activation site is the right ventricular anteroseptal region; the latest site is the mid-basal part of the posterolateral wall.

sheath pushed against the LV wall to have a stable support facilitated the position of the LV lead close to the mitral valve. Standard bipolar screw-in leads were used in all patients (Medtronic 5076–65 cm, Medtronic, Minneapolis, MN, USA, $n = 4$). The LV lead was connected to the CRT device placed in the left pectoral area. The atrial lead was implanted in the right atrial appendage in all patients. The right ventricular lead was positioned in the right ventricular septum (Figure 3A and B).

Data are presented as mean \pm standard deviation. Changes in LV pacing threshold, LV pacing impedance at implantation, and at last patient visit were analysed using paired *t*-test. New York Heart Association (NYHA) functional class and mitral regurgitation were analysed using the Wilcoxon's signed rank test, as appropriate. Statistical significance was considered at $P < 0.05$. Statistical analyses were performed using GraphPad Prism software (GraphPad Software Inc., La Jolla, CA, USA).

Results

LV endocardial leads were successfully implanted in all patients. Cardiac resynchronization therapy pacemaker was implanted in one patient (Stratos LV-T, Biotronik GmbH&Co, Berlin, Germany), while three patients received CRT-D devices (Cognis, Boston Scientific, Miami, FL, USA, $n = 1$; Concerto, Medtronic, $n = 1$; Atlas HF, St Jude, Sylmar, CA, USA, $n = 1$). Electrical parameters during device implantation were as follows: LV signal amplitude 8.5 ± 3.0 mV, LV pacing threshold 0.78 ± 0.18 V, impulse width of 0.5 ms, and LV lead impedance 520 ± 177 Ω . No phrenic nerve stimulation occurred at 10 V, 0.5 ms with rapid LV pacing (100 b.p.m.). The procedure times were 186, 165, 96, and 145 min, and fluoroscopy times were 45, 42, 23, and 32 min, respectively (Figure 4).

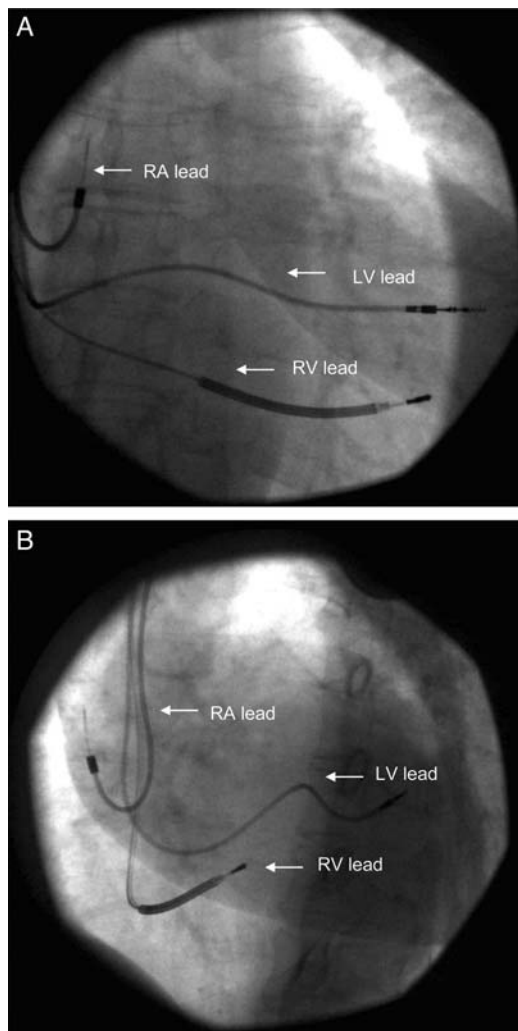


Figure 3 Patient 4. Typical final lead positions in right-anterior oblique projection and in left-anterior oblique projection. RA lead, right atrial lead is positioned in the right atrial appendage; RV lead, right ventricular lead is positioned in the right ventricular apical septum; LV lead, LV lead is positioned in the mid-basal portion of the lateral wall.

In all patients, the international normalized ratio was maintained between 3.5 and 4.5 as for those with mechanical valve prostheses and high thrombotic risk. Neither pericardial fluid nor intracardiac thrombi were observed during echocardiography in the early post-operative period or during follow-up. Neither major haematoma nor significant post-procedural bleeding occurred. During the mean follow-up of 18.3 months, stable sensing and pacing parameters were found. The mean LV pacing threshold was 0.6 ± 0.1 V at impulse width of 0.5 ms ($P = 0.44$), LV lead impedance was $439 \pm 119 \Omega$ ($P = 0.12$).

We did not observe lead dysfunction, insulation failure, or dislocation of the LV lead. There were no signs of lead infection during the follow-up period. Heart failure symptoms improved at least one NYHA class in all patients, LV systolic function improved

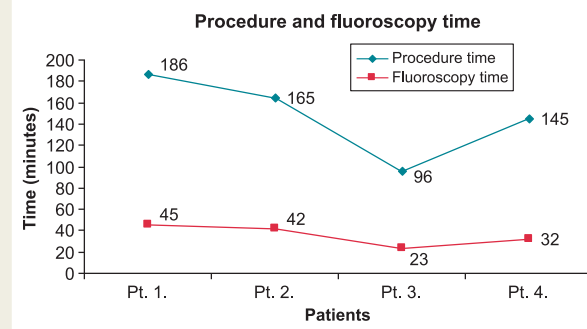


Figure 4 Procedure and fluoroscopy time.

significantly from a mean LV ejection fraction of 28 ± 5.2 to $41 \pm 6.6\%$ ($P = 0.015$). The grade of mitral regurgitation did not change significantly during the follow-up period ($P = 0.28$) (Table 1). Small left–right shunt was detected in all patients immediately after the procedure. We did not observe residual left–right shunts by trans-thoracal echocardiography; no embolism, cyanosis, right-heart failure was observed during the follow-up. No thromboembolic or haemorrhagic events occurred.

Discussion

Difficulties may be encountered when attempting LV lead placement during CRT. If transvenous LV lead placement via the CS is not possible and epicardial approach is contraindicated, LV endocardial lead implantation is an alternative method in selected patients. Early case reports and small series showed the safety and feasibility of this procedure. No report has shown the feasibility of electroanatomical mapping guidance during endocardial LV lead implantation, yet.

The first successful endocardial LV lead implantation was reported by Jais et al.¹¹ in 1998 was performed via the right jugular vein after a transfemoral interatrial septal puncture. Leclercq et al.¹² described three cases of LV lead placement applying a transeptal approach from the right jugular vein. Van Gelder et al.⁸ and Nuta et al.¹³ developed a new technique, performing the transeptal puncture via the femoral vein and positioning the LV electrode from the subclavian vein into the LV cavity through the interatrial septum and the mitral valve. In our study, we used the latter approach; however, electroanatomical mapping technique was used additionally to enhance proper LV lead placement and facilitating the LV lead implantation from a subclavian access. The implantation time and also the fluoroscopy time was less than expected.

There are potential advantages of endocardial LV lead placement compared with epicardial pacing. Endocardial LV lead position is not limited by the anatomy of the CS. Experimental¹⁴ and clinical¹⁵ observations also suggested that endocardial pacing is more physiologic than epicardial pacing. Garrigue et al.¹⁶ and Jais et al.¹⁷ reported better haemodynamic results with higher aortic and mitral time velocity integral, improvement of LV fractional shortening and reduction of regional electromechanical delay in patients with endocardial LV pacing. In our patient

cohort, we also reported significant improvement of the LV systolic function and a marked improvement of the patient's functional status during the long-term follow-up.

The drawbacks of this approach include the risk of transseptal catheterization, the current lack of appropriate implantation tools and the possible need for lifetime anticoagulation, as previously reported.⁸ However, anticoagulation is indicated in the majority of these patients due to severe LV systolic dysfunction and/or the presence of atrial fibrillation. Long-term follow-up data regarding thromboembolic or haemorrhagic complications were so far not available. Our study showed that during 1.5-year follow-up no haemorrhagic or thromboembolic events occurred.

Using the transseptal CRT approach, the LV lead crosses the atrial septum, mitral valve and is actively fixed to the LV endocardial surface. It is controversial whether mitral regurgitation might be worsened with this technique: however, we did not observe any worsening of mitral regurgitation or echocardiographic evidence of the mitral valve being partially kept open. The risk of infective endocarditis might be increased,¹⁸ but no data of more frequent endocarditis are currently available in this patient population. We did not observe any lead infection during the follow-up period.

Transseptal punctures are associated with iatrogenic atrial septal defects and concomitant left–right shunts.¹⁹ It is important to evaluate this in patients with LV leads crossing the atrial septum. In our study cohort, small left–right shunt was detected in all patients immediately after the procedure. During follow-up, we did not observe residual left–right shunts; however, it was diagnosed using two-dimensional transthoracic echocardiography, and transoesophageal echocardiography was not performed. We used an 8F sheath for the transseptal puncture during the procedure. Several earlier studies indicated that using 8F sheaths for transseptal punctures create iatrogenic atrial septal defects.¹⁹ The incidence of atrial septal defects is as high as 87% immediately after the procedure, while it is decreasing over time. At 6-month follow-up, only 21% of iatrogenic atrial septal defects persisted.²⁰ Residual septal defects are well tolerated and not associated with increased risk of embolism, cyanosis or right-heart failure.¹⁹ We do not have additional information about the impact of balloon dilatation on the incidence and persistence of atrial septal defects in this patient population undergoing transseptal CRT implantation. We assume that using balloon dilatation in this highly mobile region of the atrial septum facilitates more easy penetration in the short term while it is not associated with larger atrial septal defects in the long term, therefore not expected to be clinically relevant. In the future, serial transoesophageal echocardiography studies are needed to further evaluate this.

Clinical studies showed appropriate positioning of the LV lead to be of high importance to increase the number of CRT responders.^{21,22} Recent studies also demonstrated that an 'individually' based LV pacing approach compared with conventional CS pacing, echo-guided or lateral area strategy might result in better short-term haemodynamic response in non-ischaemic cardiomyopathy patients.²³ The authors reported a benefit of endocardial pacing. Our study also emphasizes the positive effects of endocardial pacing.

Spragg *et al.*²⁴ recently found that electroanatomical mapping with colour-coded dP/dt_{max} response is a feasible approach to identify LV endocardial sites with the highest peak of LV pressure increase (dP/dt_{max}). Although only acute haemodynamic response was evaluated in this study, optimal LV pacing site was more often found in a basal location (in 8 of 11 patients). In our study, electroanatomical activation mapping was used to identify the latest activation area to find optimal LV lead position for CRT. Functional assay (dP/dt_{max}) might be an alternative approach to guide LV lead implantation and the two approaches may give discordant results.²⁴ However, there is no direct comparison or long-term data available yet.

Singh *et al.*²⁵ showed that clinical benefit from CRT was similar with LV leads along the anterior, lateral or posterior wall in mildly symptomatic HF patients. However, LV leads positioned in the apical region were associated with subsequent worse outcome. Our study also supported the hypothesis that basal, mid-basal LV lead position might be associated with a favourable echocardiographic and clinical improvement during a mean follow-up of 1.5 years.

An alternative approach is reported to implant the LV lead transapically with a minimally invasive surgical technique. This technique has the advantage of avoiding mitral valve crossing, but bears a higher surgical and post-operative risk compared with our new approach.²⁶ However, our small cohort does not allow a real comparison with other techniques.

Because of the technical complexity of this technique, this approach remains a rare exception in CRT candidates and indicated only if transvenous implantation is not successful. More patients and longer follow-up are needed to provide additional data of this approach.

Limitations of the report

This report includes four patients who had undergone electroanatomical mapping-guided transseptal endocardial LV lead implantation. One of the major limitations of this report is the few patients included, which did not allow us to compare this technique with the standard approach. The mean follow-up of 18.3 months is relatively short; however, earlier studies reported even shorter follow-up periods. With this technique, the position of the LV lead cannot be tracked within the LV cavity using the CARTO electroanatomical mapping system.

Conclusion

We report successful electroanatomical mapping-guided LV endocardial lead implantation in four patients after unsuccessful transvenous or epicardial LV lead placement. Electroanatomical mapping to implant LV endocardial leads is proven to be useful in shortening the procedure and fluoroscopy time by identifying the location of the transseptal puncture. Activation map might help to identify the optimal LV lead position for CRT. No major complications such as bleeding, thromboembolism, or infections were observed. Pacing parameters remained stable over long-term follow-up. Clinical symptoms of HF and cardiac function improved significantly. We conclude that transseptal endocardial LV lead implantation

guided by electroanatomical mapping might be a feasible method for CRT if transvenous LV lead placement is not possible. More data are needed to assess the safety and long-term efficacy of this new approach.

Conflict of interest: V.K. has received consultant fees/honoraria from Biotronik and Servier and research support from Boston Scientific. B.M. has received consultant fees/honoraria from Biotronik, Boston Scientific, Medtronic, and St. Jude Medical, and serves in the speakers bureau of Boehringer Ingelheim. L.G. has received consultant fees/honoraria from Biotronik, Medtronic, St. Jude Medical, and Johnson & Johnson. E.Z. has received consultant fees and honoraria from Boston Scientific, Innomed, Biotronik, Medtronic, and St. Jude Medical for lectures, training, and participation in clinical trials. I.O. has received consultant fees/honoraria from Biotronik, Medtronic, Boston Scientific, and St. Jude Medical. A.R., G.S., A.K., S.S. and L.M. have nothing to disclose.

Funding

The scientific work was granted by a grant from the National Development Agency of Hungary.

References

1. Abraham WT, Fisher WG, Smith AL, Delurgio DB, Leon AR, Loh E et al. Cardiac resynchronization in chronic heart failure. *N Engl J Med* 2002;**346**:1845–53.
2. Bristow MR, Saxon LA, Boehmer J, Krueger S, Kass DA, De Marco T et al. Cardiac-resynchronization therapy with or without an implantable defibrillator in advanced chronic heart failure. *N Engl J Med* 2004;**350**:2140–50.
3. Cleland JG, Daubert JC, Erdmann E, Freemantle N, Gras D, Kappenberger L et al. The effect of cardiac resynchronization on morbidity and mortality in heart failure. *N Engl J Med* 2005;**352**:1539–49.
4. Gras D, Bocker D, Lunati M, Wellens HJ, Calvert M, Freemantle N et al. Implantation of cardiac resynchronization therapy systems in the CARE-HF trial: procedural success rate and safety. *Europace* 2007;**9**:516–22.
5. Meisel E, Pfeiffer D, Engelmann L, Tebbenjohanns J, Schubert B, Hahn S et al. Investigation of coronary venous anatomy by retrograde venography in patients with malignant ventricular tachycardia. *Circulation* 2001;**104**:442–7.
6. Higgins SL, Hummel JD, Niazi IK, Giudici MC, Worley SJ, Saxon LA et al. Cardiac resynchronization therapy for the treatment of heart failure in patients with intraventricular conduction delay and malignant ventricular tachyarrhythmias. *J Am Coll Cardiol* 2003;**42**:1454–9.
7. Koos R, Sinha AM, Markus K, Breithardt OA, Mischke K, Zarse M et al. Comparison of left ventricular lead placement via the coronary venous approach versus lateral thoracotomy in patients receiving cardiac resynchronization therapy. *Am J Cardiol* 2004;**94**:59–63.
8. van Gelder BM, Scheffer MG, Meijer A, Bracke FA. Transseptal endocardial left ventricular pacing: an alternative technique for coronary sinus lead placement in cardiac resynchronization therapy. *Heart Rhythm* 2007;**4**:454–60.
9. Hameedullah I, Chauhan VS. Clinical considerations for allied professionals: understanding and optimizing three-dimensional electroanatomic mapping of complex arrhythmias – part 1. *Heart Rhythm* 2009;**6**:1249–52.
10. Dickstein K, Vardas PE, Auricchio A, Daubert JC, Linde C, McMurray J et al. 2010 Focused Update of ESC Guidelines on device therapy in heart failure: an update of the 2008 ESC Guidelines for the diagnosis and treatment of acute and chronic heart failure and the 2007 ESC guidelines for cardiac and resynchronization therapy. Developed with the special contribution of the Heart Failure Association and the European Heart Rhythm Association. *Europace* 2010;**12**:1526–36.
11. Jais P, Douard H, Shah DC, Barold S, Barat JL, Clementy J. Endocardial biventricular pacing. *Pacing Clin Electrophysiol* 1998;**21**(Part 1):2128–31.
12. Leclercq F, Hager FX, Macia JC, Mariottini CJ, Pasquie JL, Grolleau R. Left ventricular lead insertion using a modified transseptal catheterization technique: a totally endocardial approach for permanent biventricular pacing in end-stage heart failure. *Pacing Clin Electrophysiol* 1999;**22**:1570–75.
13. Nuta B, Lines I, MacIntyre I, Haywood GA. Biventricular ICD implant using endocardial LV lead placement from the left subclavian vein approach and transseptal puncture via the transfemoral route. *Europace* 2007;**9**:1038–40.
14. Fish JM, Di Diego JM, Nesterenko V, Antzelevitch C. Epicardial activation of left ventricular wall prolongs QT interval and transmural dispersion of repolarization: implications for biventricular pacing. *Circulation* 2004;**109**:2136–42.
15. Fish JM, Brugada J, Antzelevitch C. Potential proarrhythmic effects of biventricular pacing. *J Am Coll Cardiol* 2005;**46**:2340–47.
16. Garrigue S, Jais P, Espil G, Labeque JN, Hocini M, Shah DC et al. Comparison of chronic biventricular pacing between epicardial and endocardial left ventricular stimulation using Doppler tissue imaging in patients with heart failure. *Am J Cardiol* 2001;**88**:858–62.
17. Jais PSF, Laborderie J, Reuter S, Bordachar P, Hsu LF, Sanders P et al. Tailored endocardial left ventricular pacing is superior to coronary sinus in heart failure patients needing cardiac resynchronization. *Heart Rhythm* 2006;**3**:S247.
18. Musci M, Siniawski H, Pasic M, Grauhan O, Weng Y, Meyer R et al. Surgical treatment of right-sided active infective endocarditis with or without involvement of the left heart: 20-year single center experience. *Eur J Cardiothorac Surg* 2007;**32**:118–25.
19. McGinty PM, Smith TW, Rogers JH. Transseptal left heart catheterization and the incidence of persistent iatrogenic atrial septal defects. *J Interv Cardiol* 2011;**24**:254–63.
20. Rillig A, Meyerfeldt U, Kunze M, Birkemeyer R, Miljak T, Jackle S et al. Persistent iatrogenic atrial septal defect after a single-puncture, double-transseptal approach for pulmonary vein isolation using a remote robotic navigation system: results from a prospective study. *Europace* 2010;**12**:331–6.
21. Butter C, Auricchio A, Stellbrink C, Fleck E, Ding J, Yu Y et al. Effect of resynchronization therapy stimulation site on the systolic function of heart failure patients. *Circulation* 2001;**104**:3026–9.
22. Dekker AL, Phelps B, Dijkman B, van der Nagel T, van der Veen FH, Geskes GG et al. Epicardial left ventricular lead placement for cardiac resynchronization therapy: optimal pace site selection with pressure-volume loops. *J Thorac Cardiovasc Surg* 2004;**127**:1641–7.
23. Derval N, Steendijk P, Gula LJ, Deplagne A, Laborderie J, Sacher F et al. Optimizing hemodynamics in heart failure patients by systematic screening of left ventricular pacing sites: the lateral left ventricular wall and the coronary sinus are rarely the best sites. *J Am Coll Cardiol* 2010;**55**:566–75.
24. Spragg DD, Dong J, Fetis BJ, Helm R, Marine JE, Cheng A et al. Optimal left ventricular endocardial pacing sites for cardiac resynchronization therapy in patients with ischemic cardiomyopathy. *J Am Coll Cardiol* 2010;**56**:774–81.
25. Singh JP, Klein HU, Huang DT, Reek S, Kuniss M, Quesada A et al. Left ventricular lead position and clinical outcome in the Multicenter Automatic Defibrillator Implantation Trial-Cardiac Resynchronization Therapy (MADIT-CRT) Trial. *Circulation* 2011;**123**:1159–66.
26. Kassai I, Mihalcz A, Foldesi C, Kardos A, Szili-Torok T. A novel approach for endocardial resynchronization therapy: initial experience with transapical implantation of the left ventricular lead. *Heart Surg Forum* 2009;**12**:E137–140.