



Contents lists available at ScienceDirect

Journal of Equine Veterinary Science

journal homepage: www.j-evs.com



Case Report

Systemic Granulomatous Disease in a Hungarian Warmblood Gelding

Orsolya Kutasi, DVM, Leticia Moroski, Sara Gal, Zsófia Bognár, Imre János, Ferenc Kiss, and Ottó Szenci

Equine Department and Clinic, Faculty of Veterinary Science, Szent István University, Úllő, Hungary

ARTICLE INFO

Article history:

Received 13 May 2013

Received in revised form 3 January 2014

Accepted 8 January 2014

Available online xxxx

Keywords:

Horse

Granulomatous disease

Herpesvirus

Spleen

Pulmonary fibrosis

ABSTRACT

An 8-year-old Hungarian warmblood gelding used for show jumping was evaluated because of poor performance and chronic weight loss. On admission, oral and gastroesophageal ulcerations and malabsorption were detected. Results of thoracic radiography, ultrasonography, bronchoalveolar lavage cytology, and positive polymerase chain reaction for equine herpesvirus 5 raised the possible diagnosis of equine multinodular pulmonary fibrosis. However, abdominal ultrasonography revealed inhomogeneous spleen with many different sized well-demarcated hypochoic areas, which suggested further differential diagnoses such as tuberculosis, neoplasias, immune mediated diseases, systemic granulomatous disease (SGD), or toxicoses. The horse was euthanized at the owner's request because of the poor condition and possible grave prognosis. Histopathology findings were characteristic of SGD, which is a rare disorder of horses characterized by skin lesions, weight loss, and granulomatous inflammation of multiple organ systems. The lack of skin lesions in this case is an unusual finding. Systemic granulomatous disease is hypothesized to be induced by multiple conventional antigens that are not cleared from affected tissues. Equine herpesvirus 5 might have triggered the granulomatous reactions in this particular case.

© 2014 Elsevier Inc. All rights reserved.

1. Introduction

Systemic granulomatous disease (SGD) is a rare disorder of horses characterized by skin lesions, weight loss, and granulomatous inflammation of multiple organ systems [1–3]. Previously, the disorder was known as equine sarcoidosis because it resembles the systemic noncaseating granulomatous disease, sarcoidosis, seen in humans. Equine sarcoidosis is divided according to several aspects. Based on the extension of the disease “generalized”, “partially generalized” and “localized” forms are distinguished [4]. Other classification specify the following forms: (1) the scaling and crusting form; (2) the nodular

form; and (3) the localized form, in which hyperkeratotic, crusted, alopecic plaques mainly affect the limbs in a systemically healthy horse [3,5]. Concurrent with the first two forms, granulomatous inflammation of one or more internal organs can occur, giving rise to the additional clinical signs of weight loss, inappetence, and low-grade fever. In human sarcoidosis, the lungs are most commonly affected; in horses, previously described cases mainly presented with dermal lesions, although there are two equine cases described in the literature without any skin involvement [2,6]. Although the etiology is uncertain in humans, sarcoidosis is thought to be an exaggerated T helper 1 (Th1) lymphocyte immune response to a persistent antigenic stimulus in the affected organs [1,5], and a genetic component has also been identified [2,7,8]. A T-cell-mediated immune response is also suspected in horses [5,7]. In the following case, the diagnosis was established post-mortem. The signs were unusual for equine sarcoidosis,

* Corresponding author at: Orsolya Kutasi, DVM, Equine Department and Clinic, Clinic for Large Animals, Faculty of Veterinary Science, Szent Istvan University, Úllő 225, Hungary.

E-mail address: kutasi.orsolya@aotk.szie.hu (O. Kutasi).

because there were no skin lesions despite of the widespread internal generalized granulomatosis. Thoracic ultrasonographic and radiographic examination together with the broncholaveolar cytologic findings and positive EHV-5 polymerase chain reaction (PCR) complicated the establishment of the final diagnosis because of suggesting the likelihood of equine multinodular pulmonary fibrosis (EMPF).

2. Case Description

2.1. History

An 8-year-old Hungarian warmblood gelding used for show jumping was admitted to the Large-Animal Clinic of Szent Istvan University for diagnosis of poor performance and chronic weight loss for the preceding 2 years. Before six months, the horse had exhibited a staphylococcal dermatitis in the right hock region, which was treated with acupuncture by the referring vet. One month previously, ulcers were detected in the mouth of the animal. The horse was regularly dewormed and vaccinated against equine influenza, herpesvirus, West Nile virus, and tetanus.

2.2. Clinical Examination

On admission, the animal had excellent appetite but was in poor body condition with a body weight of 550 kg (2 of 9 according to Henneke et al [9]). On initial examination, the gelding was bright and alert and had a resting pulse rate of 44 per minute, respiratory rate of 20 breaths per minute, and body temperature of 38.0°C. The skin and hooves were intact, but inspection of the oral cavity revealed deep ulcers of 0.5–3 cm in diameter on the mucus membranes of the lips and sides of the tongue (Fig. 1). Moderately enlarged nonpainful lymph nodes were palpable. The horse also displayed bilateral serous nasal discharge, moderate dyspnea, and mild wheezes on auscultation of the right ventral thoracic area. There were no other remarkable findings on physical examination.

2.3. Laboratory Findings

Complete blood cell count revealed anemia (red blood cell count: 4.81×10^{12} cells/L, reference range [rr]: $6.0\text{--}10.4 \times 10^{12}$ cells/L; hematocrit: 22%, rr: 27%–43%) and neutrophilia with a right shift (10×10^9 cells/L, rr: $2.9\text{--}8.5 \times 10^9$ cells/L). Increased fibrinogen (5.28 g/L, rr: 1.0–4.0 g/L) and globulin (58 g/L, rr: 26–40 g/L) levels, decreased albumin level (17 g/L, rr: 26–41 g/L), and increased lactate dehydrogenase activity (734.6 IU/L, rr: 112–456 IU/L) were measured [10]. Further laboratory tests revealed partial malabsorption (137% and 132% on repeated glucose absorption test), negative antinuclear antibody test, and increased α_1 , β_2 , and γ fractions on electrophoresis.

2.4. Further Diagnostic Procedures

Esophageal and gastric ulcerations (grade 3, according to the Equine Gastric Ulcer Council consensus [9]) were found on gastroscopy. Abdominal ultrasonographic examination

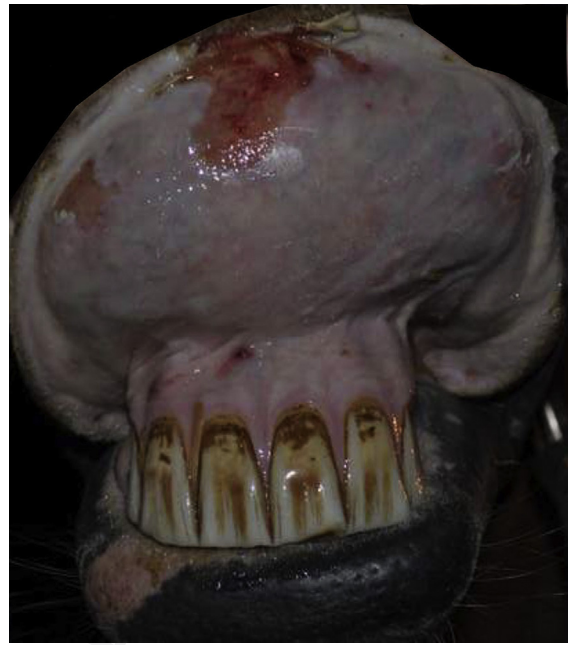

Fig. 1. Deep ulcers on the mucus membrane of the lips. Similar ulcerations were visible in the lower third of the esophagus.

showed a normal amount of free abdominal fluid and normal intestinal movements and wall thickness. The spleen was found to be normal in size but inhomogeneous with multiple well-demarcated hypoechoic areas of various sizes and blurred hyperechogenic areas (Fig. 2A and B). Abdominocentesis yielded an increased amount of clear light-yellow fluid with a protein content of 1.3 g/dL (rr: <2.5), white blood cell count of 1.05×10^9 cells/L (rr: $<5 \times 10^9$ cells/L), and unremarkable cytology [10]. Respiratory tract endoscopy revealed scant whitish mucus in the trachea and a blunted carina. Thoracic ultrasonographic examination revealed diffuse comet-tail echoes and small subpleural hypoechoic regions on both sides together with a mildly increased amount of anechoic fluid (Fig. 2C). There was a moderate mixed nodular–interstitial pattern together with a diffuse bronchial pattern on thoracic radiographs. Tracheal lavage cytology showed mucopurulent inflammation, and *Streptococcus zooepidemicus* was cultured. Bronchoalveolar lavage (BAL) sampling was performed with the following results: neutrophilia (57%) and moderate hemosiderophagia. No microorganisms were observed. Polymerase chain reaction for equine herpesvirus 5 (EHV-5) yielded a positive result, and PCR for mycoplasma and Ziehl–Neelsen stain for mycobacteria was negative. Histopathological examination of biopsy samples of abnormal mucus membrane in the oral cavity revealed superficial ulcerative stomatitis, hyperplastic epithelium with circumscribed necrosis and neutrophil infiltration and areas of spongiosis, and lymphoplasmocytic perivascularitis.

Biopsy samples were obtained from the spleen with ultrasound guidance and blindly from the rectum. The spleen showed increased red blood cell content, megakaryocytes, and lymphocytes of various sizes and scant lymphoblasts and plasma cells. Histopathology results

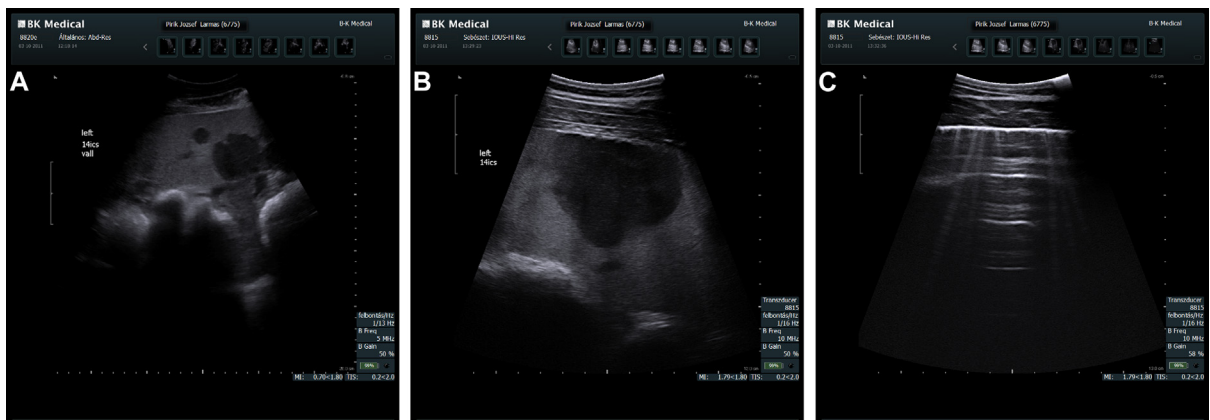


Fig. 2. Ultrasonographic appearance of the spleen in the 14th intercostal space (A, B) with different sized well-demarcated hypoechoic areas using a 5 MHz probe and the lung on the right side in the 10th intercostal space (C) showing comet-tail echoes and pleural roughening using a 10 MHz probe.

of repeated spleen and rectum biopsies proved to be nondiagnostic.

On the basis of the findings of oral and gastroesophageal ulcerations and malabsorption, and the results of splenic ultrasonography, the differential diagnoses were established as follows: tuberculosis; neoplasias, for example lymphoma; immune-mediated diseases, for example systemic lupus erythematosus; multisystemic eosinophilic epitheliotropic disease; and SGD; and toxicoses, for example hairy vetch, arsenic, aluminum, iodine, and silicon. Primary or concurrent EMPF was suspected because of pulmonary involvement with positive EHV-5 PCR and severe weight loss.

The horse was euthanized at the owner's request because of the poor condition and possible grave prognosis.

2.5. Gross Pathology

Necropsy revealed markedly swollen and firm lymph nodes generally, with moderately moist cut surface and

diminished structure. There were multiple, different sized, whitish-gray nodules in the spleen ranging from few mm to 5 cm in diameter. The centers of the larger nodules were sunken (Fig. 3A). Similar but smaller whitish-gray nodules were also visible on the surface of the liver and lungs (Fig. 3B). Ulcerations could be found in the oral cavity, esophagus, and stomach. In the femoral bones, the normal bone marrow architecture was focally damaged and displaced by a greyish-white tissue mass (Fig. 3C).

2.6. Histopathology and Electron Microscopy

For routine histopathology, samples from mesenteric lymph nodes, spleen, liver, lungs, and bone marrow were fixed in 10% neutral buffered formalin and were subsequently embedded in paraffin using an automatic tissue processor (Shandon Citadel 2000; Thermo Scientific). Bone marrow samples were briefly decalcified before processing in Shandon TBD-2 Decalcifier solution (Thermo Scientific). Paraffin blocks were cut at 4 μ m and were stained with

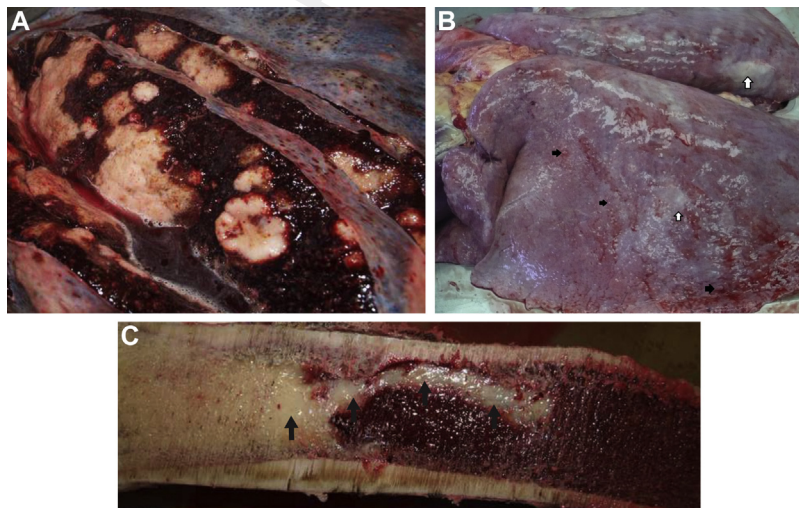


Fig. 3. (A) Multiple homogeneously whitish-gray and firm, well-demarcated nodules on the cut surface of the spleen. (B) Whitish-gray nodules of smaller size are also visible on the surface of the lungs (bold arrows) along with multifocal pleural thickenings (open arrows). (C) Longitudinal cross section of the femoral bone shows loss of normal bone marrow architecture, displaced by an irregular greyish tissue mass (black arrows).

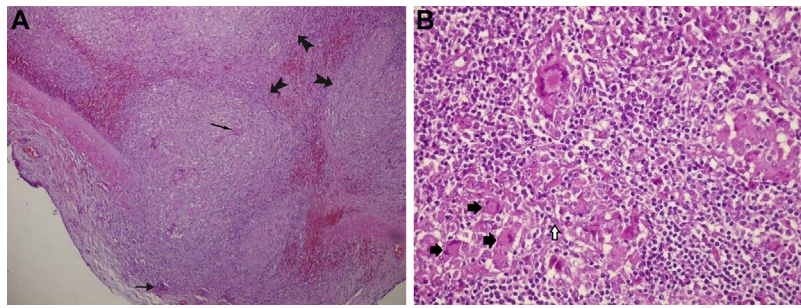


Fig. 4. (A) Hematoxylin and eosin stained section of spleen demonstrating granulomas (thick arrows) with central multinucleated giant cells (thin arrows) and mixed inflammatory cells infiltrating the splenic capsule and (B) section of a mesenteric lymph node showing loss of normal architecture and granulomatous proliferation with large number of multinucleated giant cells (thick arrows) and histiocytes (open arrow).

hematoxylin and eosin in an automatic staining device (Shandon Varistain 24-4; Thermo Scientific).

For ultrastructural examinations, tissue samples from mesenteric lymph nodes and spleen were fixed in glutaraldehyde, embedded in epon resin and were cut to semi- and ultrathin sections, stained with 0.1% buffered toluidine blue (semithin) and with uranyl acetate and lead citrate (ultrathin) and were examined using a JEOL JEM 1011B electron microscope.

Routine histopathology revealed the presence of random, confluent, unencapsulated foci of nonnecrotizing granulomas distributed in the splenic parenchyma. In the centers of these granulomas, Langhans- and foreign-body-type giant cells were surrounded by macrophages, epithelioid macrophages, and lymphocytes (Fig. 4A). In some places the inflammatory cells infiltrated the splenic capsule as well. Lymph nodes showed multifocal to diffuse histiocytic proliferation (Fig. 4B). Liver, lungs, and bone marrow samples contained granulomatous lesions similar to those described in the spleen. Infectious agents could not be detected by Ziehl-Neelsen, Grocott, or Giemsa stains, and by periodic acid-Schiff reaction of tissue sections from the organs previously mentioned.

Examination of semi- and ultrathin sections did not reveal the presence of intracellular organisms in the lymph node and splenic tissue samples studied.

2.7. Bacteriology

Routine aerobic and anaerobic bacteriological culture of the splenic nodules and mesenteric lymph nodes yielded no bacterial growth.

3. Discussion

The presented case was not usual for SGD. The horse did not show any skin lesion, the most typical sign of SGD. However, other extraordinary findings could be noticed, such as the significant spleen and bone marrow involvement, severe oral and esophageal ulceration, and the confusing diagnostic imaging findings of the lungs with the positive EHV-5 PCR from the BAL sample.

Most reports on SGD describe no age, breed, or gender predilection. Our patient was a gelding; in a single study, geldings were clearly overrepresented [5]. Systemic

granulomatous disease has not previously been identified in a Hungarian warmblood.

Although the horse had excellent appetite, it showed chronic weight loss that had accelerated in the last month. Other authors also describe wasting despite high-energy intake, possibly as a result of granulomatous inflammation of the gastrointestinal tract with subsequent malabsorption [5]. This is the first SGD case where malabsorption was clearly demonstrated with repeated glucose absorption tests. Ulcerations of the oral cavity, esophagus, and gastrointestinal tract could have explained the clinical findings, but further underlying causes had to be excluded, such as endoparasitosis, chronic bacterial infections, intestinal neoplasias, other infiltrative bowel diseases, congestive heart failure, and tuberculosis. Ulceration of the mucocutaneous junctions and tongue was also a feature of a previously described SGD case [6]. Ulceration of the gastrointestinal tract characterizes granulomatous enteritis as well, where histopathological changes are similar to those in SGD [12]. In generalized sarcoidosis, gastrointestinal involvement suggests a poor prognosis [5].

A similar presentation of oral and esophageal ulcerations was detected in a foal in which EHV-2 was the suspected cause [13] and in a horse in which EHV-5 was found to be associated with EMPF [14]. A previous report described a case of granulomatous skin disease displaying electron microscopic and PCR findings consistent with EHV-2 [15]. Although we did not test our oral and gastrointestinal specimens for the presence of gammaherpesvirus, positive EHV-5 PCR on BAL specimens proved the pulmonary presence of the virus, which possibly could emerge in all other tissues. Chronic weight loss is also one of the typical clinical signs in EMPF caused by EHV-5 [16].

On hematology, characteristic findings of SGD are chronic inflammatory changes of right shift, anemia, and increased fibrinogen and globulin levels [1,3,5]. The right shift and nonregenerative anemia in our case might also have been caused by bone marrow involvement—the bone marrow was largely obliterated by granulomatous inflammation. The spleen is a common site of extramedullary hematopoiesis when blood cell formation in the bone marrow is inadequate, and this was reflected in the biopsy sample results of the spleen. None of the spleen or rectal biopsy samples was representative of the final SGD diagnosis. Rectal biopsy samples have been reported to reflect intestinal pathology in only 50% of cases [17]. Spleen

biopsies are also of limited value if there are focal pathologic changes. Lymphoma or granuloma was suspected from spleen ultrasonographic findings [18]. Systemic granulomatous disease rarely affects the spleen, but mycobacteria have an affinity for the lymphatic system, spleen, liver, and lung [19,20]. Mycobacteria were recently demonstrated with PCR in a severe case of SGD where, interestingly, Ziehl–Neelsen staining was negative for the pathogen [21]. Mycobacteria also have been described to cause chronic oral ulceration [19]. We attempted to demonstrate mycobacterial infection on histopathologic samples with special staining, PCR, and electron microscopy but obtained negative results. Histopathology of granulomas in mycobacterial infections and SGD are similar, and tuberculosis can be differentiated from the latter on the basis of the presence or absence of the organism and additional granulation tissue. Lymphohistiocytic infiltration, macrophages, and typical Langhans-type multinucleated giant cells characterize both diseases.

Diagnostic imaging findings of the lungs and results of BAL cytology together with the positive EHV-5 PCR elicited a possible diagnosis of primary or concurrent EMPF or some other causative or contributing role of chronic herpesvirus infection. Although it is very likely that with the histologic evaluation of a lung biopsy sample, a definite diagnosis would have been established antemortem and EMPF could have been excluded.

Equine herpesvirus 5 belongs to the gammaherpesvirinae subfamily, together with EHV-2 and human Epstein–Barr virus (EBV). The gammaherpes viral genes are capable of modulating cellular signals such that cell proliferation and viral replication occur at the appropriate times in the viral life cycle [22]. Regular EHV-5 infection has been demonstrated in EMPF cases to induce a milieu of Th2 cytokines resulting in extensive fibrosis, similar to the pathology caused by EBV in human idiopathic pulmonary fibrosis [23]. Interestingly, SGD is a Th1-mediated disease, but EHV-2, another gammaherpesvirus, was proved to induce this type of exaggerated immune response in a dermatologic case [13]. Further, another gammaherpesvirus, asinine herpesvirus 5 (AHV-5), caused pyogranulomatous pneumonia in a mare [24]. Multinucleated giant cells and macrophages are also characteristic findings in EMPF histopathology [3,23]. In human pulmonary sarcoidosis, pathologic changes can range from predominantly granulomatous inflammation with minimal chronic changes through to extensive fibrosis with few granulomas. It is likely that acute granulomatous and chronic fibrotic pulmonary sarcoidosis represent separate immunopathogenic processes [8]. Gammaherpesviruses might induce different immune responses depending on the viral life cycle and immunogenetic background of the host.

Bronchoalveolar lavage fluid of humans with pulmonary sarcoidosis reveals increased cellularity with lymphocytes and macrophages. Macrophages and neutrophils together with scant multinucleated giant cells and lymphocytes were detected in an equine case of granulomatous pneumonia caused by AHV-5 [24]. Increased numbers of polymorphonuclear cells are found in the BAL fluid of human patients with sarcoidosis when there is radiological evidence of established fibrosis, and the degree of neutrophil

alveolitis correlates with severity [8]. Neutrophilia and hemosiderophagia in the pulmonary fluid are typical findings in EMPF with fibrosis and lung tissue destruction [23]. There is no previous description of BAL cytology in equine SGD. Cytology results of this case resembled EMPF rather than human or equine pulmonary granulomatous disorders, although secondary fibrosis does also ensue in the latter cases. The radiographic and ultrasonographic findings were more characteristic of mild to moderate pulmonary fibrosis.

Septic bronchitis caused by *S. zooepidemicus* is a typical secondary bacterial invasion of the lower airways. General immunosuppression caused by SGD or herpesvirus infection could have been the underlying disorder resulting in this alteration. Airway inflammation because of various etiologies commonly alters ciliary clearance mechanisms, mucus quality, and cellular protective mechanisms, which results in bacteria of the pharyngeal cavity reaching the lower airways.

Similar to most previously described cases, the etiologic agent was not clearly identified in our case [5,6,25]. We cannot exclude the role of EHV-5 in inducing generalized granulomatosis in this particular case. Gammaherpesvirus AHV-5 has been implicated in both granulomatous pneumonia and EMPF [24,26]. Unfortunately, EHV-5 PCR was not performed on histologic slides, but there were no intranuclear inclusion bodies in macrophages or giant cells. Electron microscopic examination did not demonstrate any intracellular causative agent. In herpesvirus infections, studies have demonstrated a potential “hit and run” effect. In vitro experiments have revealed that viral DNA does not persist long in the infected cell, and viral proteins, although transiently expressed, cannot be detected [25]. Previous studies have repeatedly failed to find evidence of EHV-1, EHV-2, or mycobacteria in infected tissues, but this does not preclude these as potential etiological agents in cases of SGD in particular [5,25].

Similar findings of systemic granulomatosis are caused by hairy vetch (*Vicia villosa*) toxicosis in horses and other species [21]. Although hairy vetch is grown in Hungary, it is not generally used in horse forage and this particular horse had not been in contact with the plant. All staining techniques applied for fungi, bacteria, and mycobacteria proved to be negative. On the basis of the findings of this and previous cases, we hypothesize that SGD is most likely induced by multiple conventional antigens that are not cleared from affected tissues.

Systemic granulomatous disease should be considered as a differential diagnosis in horses with chronic weight loss even if typical dermal lesions are absent. This case description also represents the fact that even fitting clinical signs, results of further diagnostic imaging and laboratory examinations and a positive EHV-5 PCR from BAL do not lead to the final diagnosis of EMPF.

Uncited reference


[11].

References

- [1] Axon JE, Robinson P, Lucas J. Generalised granulomatous disease in a horse. Aust Vet J 2004;82:48–51.

- 588 [2] Peters M, Graf G, Pohlenz J. Idiopathic systemic granulomatous
589 disease with encephalitis in a horse. *J Vet Med A Physiol Pathol Clin*
590 *Med* 2003;50:108–12.
- 591 [3] Reijerkerk EP, Veldhuis Kroeze EJ, Sloet van Oldruitenborgh-
592 Oosterbaan M. Equine sarcoidosis. *Sarcoidosis Vasc Diffuse Lung Dis*
593 *2009;26:20–3.*
- 594 [4] Sloet van Oldruitenborgh-Oosterbaan M, Grinwis GC. Equine
595 sarcoidosis: clinical signs, diagnosis, treatment and outcome of 22
596 cases. *Vet Dermatol* 2013;24:218–24.
- 597 [5] Spiegel IB, White SD, Foley JE, Drazenovich NL, Ihrke PJ, Affolter VK.
598 A retrospective study of cutaneous equine sarcoidosis and
599 its potential infectious aetiological agents. *Vet Dermatol* 2006;17:
600 51–62.
- 601 [6] Schwarzwald CC, Stewart AJ, Morrison CD, Bonagura JD. Cor
602 pulmonale in a horse with granulomatous pneumonia. *Equine Vet Educ*
603 *2006;18:182–7.*
- 604 [7] Sellers RS, Toribio RE, Blomme EA. Idiopathic systemic granuloma-
605 tous disease and macrophage expression of PTHrP in a miniature
606 pony. *J Comp Pathol* 2001;125:214–8.
- 607 [8] Conron M, Du Bois RM. Immunological mechanisms in sarcoidosis.
608 *Rev Clin Exp Allergy* 2001;31:543–54.
- 609 [9] Henneke DR, Potter GD, Kreider JR, Yeates BF. Relationship between
610 condition score, physical measurements and body fat percentage in
611 mares. *Equine Vet J* 1983;15:371–2.
- 612 [10] Kahn CM, Line S. The Merck veterinary manual. 10th ed. New York:
613 Merck; 2010.
- 614 [11] Recommendations for the diagnosis and treatment of equine gastric
615 ulcer syndrome (EGUS): the equine gastric ulcer council. *Equine vet*
616 *Educ* 1999;11:262–72.
- 617 [12] Cimprich RE. Equine granulomatous enteritis. *Vet Pathol* 1974;11:
618 535–47.
- 619 [13] Vengust M, Baird JD, van Dreumel T, Ackerley C, Bienzle D. Equid
620 herpesvirus 2-associated oral and esophageal ulceration in a foal.
621 *J Vet Diagn Invest* 2008;20:811–5.
- 622 [14] Poth T, Niedermaier G, Hermanns W. Equine multinodular pulmo-
623 nary fibrosis in association with an EHV-5 infection in 5 horses.
624 *Wiener Tierärztliche Monatsschrift* 2009;96:203–8.
- 625 [15] Sledge DG, Miller DL, Styer EL, Hydrick HA, Baldwin CA. Equine
626 herpesvirus 2-associated granulomatous dermatitis in a horse. *Vet*
627 *Pathol* 2006;43:548–52.
- 628 [16] Schwarz B, Klang A, Bezdekova B, Sárdi S, Kutasi O, van den
629 Hoven R. Equine multinodular pulmonary fibrosis (EMPF) in 5
630 horses. *Acta Vet Hung* 2013;61. in press.
- 631 [17] Lindberg R, Nygren A, Persson SG. Rectal biopsy diagnosis in horses
632 with clinical signs of intestinal disorders: a retrospective study of
633 116 cases. *Equine Vet J* 1996;28:275–84.
- 634 [18] Chaffin MK, Schmitz DG, Brumbaugh GW, Hall DG. Ultrasonographic
635 characteristics of splenic and hepatic lymphosarcoma in three
636 horses. *J Am Vet Med Assoc* 1992;201(5):743–7.
- 637 [19] Thorel MF, Huchzermeyer H, Weiss R, Fontaine JJ. *Mycobacterium*
638 *avium* infections in animals. Literature review. *Vet Res* 1997;28:439–47.
- 639 [20] Kriz P, Jahn P, Bezdekova B, Blahutkova M, Mrlik V, Slana I, et al.
640 *Mycobacterium avium* subsp. *hominissuis* infection in horses.
641 *Emerg Infect Dis* 2010;16:1328–9.
- 642 [21] Oliveira-Filho JP, Monteiro LN, Delfiol DJ, Sequeira JL, Amorim RM,
643 Fabris VE, et al. *Mycobacterium* DNA detection in liver and skin of a
644 horse with generalized sarcoidosis. *J Vet Diagn Invest* 2012;24(3):
645 596–600.
- 646 [22] Blake N. Immune evasion by gammaherpesvirus genome mainte-
647 nance proteins. *J Gen Virol* 2010;91:829–46.
- 648 [23] Schwarz B, Gruber A, Benetka V, Rütgen B, Schwendenwein I,
649 Leidinger E, et al. Concurrent T cell leukaemia and equine multi-
650 nodular pulmonary fibrosis in a Hanoverian Warmblood mare.
651 *Equine Vet Educ* Volume 2012;24:187–92.
- 652 [24] De Witte FG, Frank N, Wilkes RP, Novak JM. Association of asinine
653 herpesvirus-5 with pyogranulomatous pneumonia in a mare. *J Vet*
654 *Intern Med* 2012;26:1064–8.
- 655 [25] White SD, Foley JE, Spiegel IB, Ihrke PJ. Lack of detectable equine
656 herpesviruses 1 and 2 in paraffin-embedded specimens of equine
657 sarcoidosis. *J Vet Intern Med* 2009;23:623–5.
- 658 [26] Back H, Kendall A, Grandón R, Ullman K, Treiberg-Berndtsson L,
659 Ståhl K, et al. Equine multinodular pulmonary fibrosis in association
660 with asinine herpesvirus type 5 and equine herpesvirus type 5: a
661 case report. *Acta Vet Scand* 2012;25:54–7.

AUTHOR QUERY FORM






 ELSEVIER	Journal: YJEVS	Please e-mail or fax your responses and any corrections to:
	Article Number: 1693	E-mail: corrections.esi@elsevier.tnq.co.in Fax: +31 2048 52789

Dear Author,

Please check your proof carefully and mark all corrections at the appropriate place in the proof (e.g., by using on-screen annotation in the PDF file) or compile them in a separate list. Note: if you opt to annotate the file with software other than Adobe Reader then please also highlight the appropriate place in the PDF file. To ensure fast publication of your paper please return your corrections within 48 hours.

For correction or revision of any artwork, please consult <http://www.elsevier.com/artworkinstructions>.

Any queries or remarks that have arisen during the processing of your manuscript are listed below and highlighted by flags in the proof.

Location in article	Query / Remark: Click on the Q link to find the query's location in text Please insert your reply or correction at the corresponding line in the proof
	If there are any drug dosages in your article, please verify them and indicate that you have done so by initialing this query
Q1	Please provide professional degrees (e.g., PhD, MD) for the missing authors.
Q2	Please check the affiliation provided for all the authors and correct if necessary. Also provide Department name for affiliation if necessary.
Q3	Please check the edits made to the sentence "Six months previously..." and correct if necessary 
Q4	Please note that "/L" has been changed to "cells/L" throughout the file for better clarity. Please check and correct if necessary 
Q5	Please provide geographical location for the manufacturer "Thermo Scientific, USA" 
Q6	Ref 11 is not cited in the text. Please provide citation. Also provide the authors for this reference 
Q7	Please confirm that given names and surnames have been identified correctly. 
	<div style="border: 1px solid black; padding: 5px; display: inline-block;"> <p style="color: red; margin: 0;">Please check this box or indicate your approval if you have no corrections to make to the PDF file</p> <div style="display: inline-block; border: 1px solid black; width: 40px; height: 40px; vertical-align: middle; margin-left: 20px;"></div> </div>

Thank you for your assistance.