

Canadian Journal of Cardiology 30 (2014) 1249.e9–1249.e11 [www.onlinecjc.ca](http://www.onlinecjc.ca)Case Report 

# Ablation of the Epicardial Substrate in the Right Ventricular Outflow Tract in a Patient With Brugada Syndrome Refusing Implantable Cardioverter Defibrillator Therapy

Gábor Széplaki, MD, PhD, Emin Evren Özcan, MD, István Osztheimer, MD, Tamás Tahin, MD, Béla Merkely, MD, PhD, DSc, and László Geller, MD, PhD

*Heart and Vascular Center, Semmelweis University Budapest, Budapest, Hungary***ABSTRACT**

Brugada syndrome is associated with a high risk of sudden cardiac death. Currently, the cornerstone of therapy is implantation of an implantable cardioverter defibrillator (ICD). Recently, a novel approach to preventively ablate the substrate located in the anterior epicardial region of the right ventricular outflow tract showed promising results by reducing the number of ventricular fibrillation episodes in patients with ICD. Here we report on a patient with Brugada syndrome who refused ICD therapy in whom a successful epicardial right ventricular outflow tract substrate ablation was performed. In some special cases, ablation therapy might be considered as the sole therapeutic option for these patients.

**RÉSUMÉ**

Le syndrome de Brugada est associé à un risque élevé de mort cardiaque subite. Actuellement, la pierre angulaire du traitement est l'implantation d'un défibrillateur cardiovertteur implantable (DCI). Récemment, une nouvelle approche pour procéder de manière préventive à l'ablation du substrat localisé dans la région épicaudique antérieure de la chambre de chasse du ventricule droit a montré des résultats prometteurs en réduisant le nombre d'épisodes de fibrillation auriculaire chez les patients portant un DCI. Nous rapportons ici le cas d'un patient souffrant du syndrome de Brugada qui a refusé le traitement par DCI chez qui une ablation du substrat épicaudique de la chambre de chasse du ventricule droit a été réussie. Dans certains cas particuliers, le traitement par ablation pourrait être considéré comme la seule option thérapeutique chez ces patients.

A 31-year-old male patient with recurrent short lasting paroxysmal palpitations, once leading to syncope, was referred to our Electrophysiology Department for evaluation. Apart from congenital hypoplasia of both upper and lower extremities he had no known disease in his medical history and physical examination did not reveal any other abnormalities. His family history of sudden cardiac death (SCD) was unknown because he was adopted in infancy. Twelve-lead resting electrocardiogram (ECG) showed a type II Brugada pattern, with a characteristic “saddle back” pattern ST segment elevation most prominently in V<sub>2</sub> and V<sub>3</sub> and a negative T-wave in lead V<sub>1</sub> without fragmentation or inferolateral early repolarization (Fig. 1). Echocardiography and routine laboratory tests were normal. A 24-hour Holter ECG recording revealed short runs of atrial ectopy only.

During the electrophysiology study, atrial fibrillation developed during catheter positioning, which terminated spontaneously. No other supraventricular or ventricular arrhythmia was inducible by pacing manoeuvres (2 extrasystoles with a coupling interval until refractoriness or reaching 200 ms at 550, 400, and 330 ms base drive, respectively). Then ajmaline with a dose of 1 mg/kg of body weight was given intravenously over 10 minutes and we recorded a > 0.2 mV ST segment elevation in V<sub>2</sub> and evolution of a type I Brugada pattern (Fig. 1), however, no arrhythmia could be induced after the drug test. On the second day of observation a spontaneous type I Brugada pattern was recorded on his resting ECG (Fig. 1).

According to the results and history, the patient (spontaneous type I ECG, unknown family history, and syncope) was diagnosed with Brugada syndrome and classified as moderate risk for SCD. Implantable cardioverter defibrillator (ICD) therapy was offered to the patient.<sup>1</sup> He refused the implantation of an ICD although the potential life-threatening consequences of that decision was adequately explained to him and he understood the potential consequences.

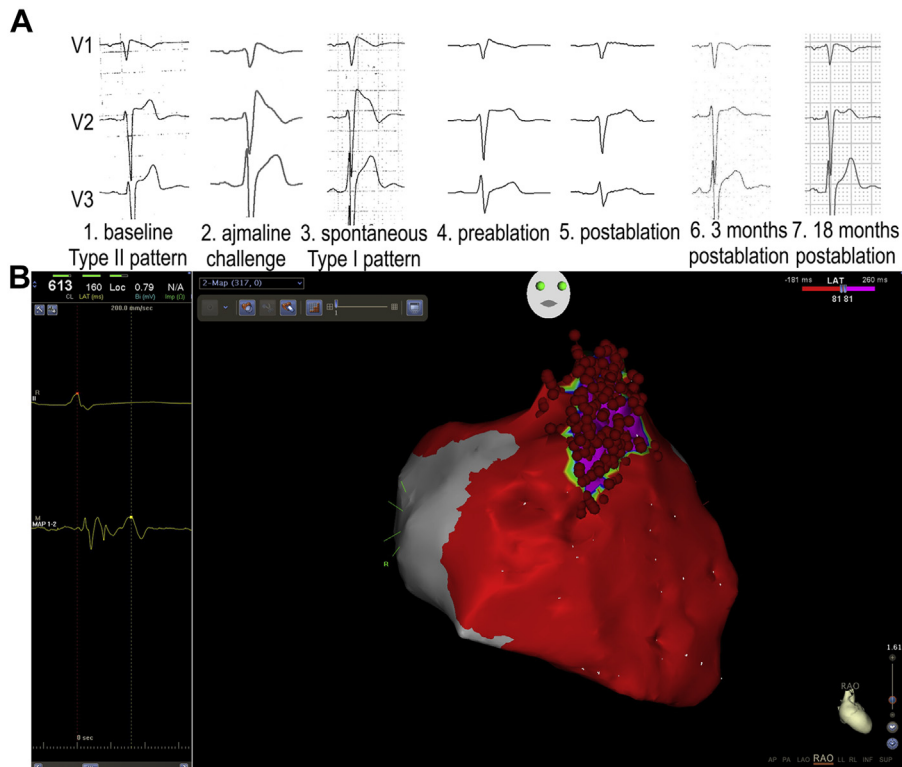
Epicardial ablation of the substrate at the right ventricular outflow tract (RVOT) was shown to reduce the risk of ventricular fibrillation (VF) in Brugada syndrome patients

Received for publication February 13, 2014. Accepted May 22, 2014.

Corresponding author: Dr László Geller, Heart and Vascular Center, Semmelweis University Budapest, 68 Városmajor St, Budapest H-1122, Hungary. Tel.: +3614586810; fax: +3614586818.

E-mail: [laszlo.geller@gmail.com](mailto:laszlo.geller@gmail.com)

See page 1249.e11 for disclosure information.



**Figure 1.** (A) Electrocardiograms of the Brugada patient showing recordings of the precordial V<sub>1</sub>-V<sub>3</sub> leads: (1) baseline type II pattern; (2) ajmaline challenge; (3) spontaneous type I pattern; (4) before ablation; (5) after ablation; (6) 3 months after ablation; and (7) 18 months after ablation. Note the diminishment of the Brugada pattern after substrate ablation. (B) Substrate map and ablation points (red dots) at the epicardial right ventricular outflow tract (right panel) and a typical intracardiac substrate potential at Map 1-2 channel (left panel). The purple area indicates the fragmented late potential area, and the red area indicates healthy epicardial tissue without fragmentation or late potentials.

living with an ICD.<sup>2,3</sup> After obtaining permission from the local ethical committee we offered to perform the procedure to the patient, clearly explaining that there is currently no literature data available on the outcome in patients who do not have an implanted ICD. The patient accepted the ablation therapy.

In conscious sedation, first pericardial access was obtained using fluoroscopy-guided subxyphoidal puncture and a steerable sheath (Agilis EPI; St Jude Medical) was introduced. Than another steerable sheath (Agilis NXT medium curve; St Jude Medical) was introduced to the right heart side. The first endocardial substrate mapping of the right ventricle was performed (CARTO 3; Biosense Webster), where no real late potentials were recorded. The next epicardial substrate mapping of the right ventricle was performed and we found and marked an extensive area of fragmented and late potentials in the anterior RVOT (Fig. 1). Epicardial ablation was performed by an irrigated tip catheter (ThermoCool; Biosense Webster) in the marked area (maximum 35 W, total ablation time: 28 minutes). Finally, remapping of the epicardial surface of the RVOT was done to prove the complete diminishment of fragmented and late potentials. A slight change in the ST-T segments of the V<sub>1</sub>-V<sub>3</sub> leads could be immediately detected (Fig. 1). No complications occurred during the procedure; the total procedure time was 191 minutes, and fluoroscopy, 22 minutes. At the 3- and 18-month follow-ups, the Brugada pattern disappeared from the 12-lead resting ECG (Fig. 1),

the patient was completely asymptomatic, and no arrhythmia was detected at the control 24-hour Holter monitoring. An ajmaline test performed with the previously described protocol and the ECG placed at high precordial leads at 18 months after ablation (Fig. 1). His resting ECG showed a type II pattern, which did not change after administration of ajmaline, thus ablation prevented this response.

Brugada syndrome is associated with a high risk of SCD and the cornerstone of therapy is currently implantation of an ICD.<sup>1,4</sup> Radiofrequency catheter ablation was first described to abolish the triggers of VF in these patients,<sup>5</sup> however, it can be applied only in selected cases, when triggering premature ventricular complexes are present at the time of the procedure. The novel approach to preventively ablate the substrate located in the anterior epicardial region of the RVOT showed promising results by reducing the number of VF episodes in Brugada syndrome patients with ICD therapy.<sup>2,3</sup> It is well known that ablation of any arrhythmogenic substrate can prevent the development of a later episode of an arrhythmia. Based on these data, preventive ablation of the “Brugada substrate” might be beneficial. However at present there are no data available that indicate that prophylactic ablation is able to replace ICD therapy. Nevertheless, in some special cases like this, ablation therapy might be considered the sole therapeutic option. To our knowledge, this is the first description of substrate ablation in a patient with Brugada syndrome who did not receive an ICD. Further studies are

needed to assess the clinical value and future of this promising procedure.

### Funding Sources

The work was supported by the János Bolyai Research Scholarship of the Hungarian Academy of Sciences (G.Sz., L.G.).

### Disclosures

The authors have no conflicts of interest to disclose.

### References

1. Antzelevitch C, Brugada P, Borggrefe M, et al. Brugada syndrome: report of the second consensus conference: endorsed by the Heart Rhythm Society and the European Heart Rhythm Association. *Circulation* 2005;111:659-70.
2. Shah AJ, Hocini M, Lamaison D, et al. Regional substrate ablation abolishes Brugada syndrome. *J Cardiovasc Electrophysiol* 2011;22:1290-1.
3. Nademanee K, Veerakul G, Chandanamattha P, et al. Prevention of ventricular fibrillation episodes in Brugada syndrome by catheter ablation over the anterior right ventricular outflow tract epicardium. *Circulation* 2011;123:1270-9.
4. Perrin MJ, Gollob MH. Genetics of cardiac electrical disease. *Can J Cardiol* 2013;29:89-99.
5. Haissaguerre M, Extramiana F, Hocini M, et al. Mapping and ablation of ventricular fibrillation associated with long-QT and Brugada syndromes. *Circulation* 2003;108:925-8.