

Studia Ecologiae et Bioethicae
UKSW
11(2013)2

JACEK TOMCZYK

Instytut Ekologii i Bioetyki, UKSW, Warszawa

Preliminary report on human remains from Tell Masaikh (MK 15) Season 2010*

Key words: the middle Euphrates valley, osteology, pathology

SUMMARY

The manuscript presents the results of anthropological work in Tell Masiakh, conducted in 2010 season. Unfortunately the 15th season of excavation was conducted only in Tell Masaikh. The second site (Terqa) was closed for the excavation. The human remains were studied in an excavation house in Tell Ashara, and some samples were prepared for further analyses in specialist laboratories (histological, radiological and molecular examinations). In sum, the remains of 70 individuals were examined: 18 (2 males, 2 females, the sex of the rest is unknown) come from Tell Masaikh from this season, 52 were found at Tell Masaikh and Tell Ashara in the previous seasons (2008, 2009).

From over twenty three years French-Syrian archaeological expedition, guided by Prof. Olivier Rouault (University Lyon 2 – Lumière)

* The research was financed by the Ministry of Science and Higher Education (Poland) in years 2009–2011, grant No. N303 319837.

and Prof. Marii Grazi Masetti-Rouault (Ecole Pratique des Hautes Etudes, Paris), research the Middle Euphrates Valley (Syria). Tell Ashara (ancient Terqa), situated on the right bank of the Middle Euphrates, around sixty kilometres north of Mari ($34^{\circ}55'20''\text{N}$ $40^{\circ}34'05''\text{E}$). The second archaeological site – Tell Masaikh – is located on the left bank of the Euphrates, some 6 km upstream of Terqa ($34^{\circ}58'23''\text{N}$ $40^{\circ}33'13''\text{E}$). Since 2001, the projects have also involved research on human remains. The anthropological researches are conducted in complex, it means that the human remains were studied in an excavation house in Tell Ashara, and some samples were prepared for further analyses in specialist laboratories. Our histological analyses are conducted in two independent research centres (Department of Patomorphology, Specialist Hospital in Siedlce, Poland and Department of Descriptive and Clinical Anatomy, Medical University of Warsaw, Poland) in order to obtain two independent sets of results. Radiological examinations are performed in the Institute of Nuclear Medicine and Magnetic Resonance, Brudnowski Hospital, Warsaw (Poland). Genetic analyses are conducted in Molecular Biology Dept. Medical University of Lodz (Poland) by the team of Prof. Henryk Witas.

As in previous seasons, bones and teeth are described with the use of a questionnaire based on *Standards of Data Collection* (Buikstra, Ubelaker 1994). The sex of the individuals was determined on the basis of the Phenice method which assesses morphological indicators of the pelvic bone. Moreover, our analysis was based on the morphological assessment of the skull (according to the Scoring System for Sexually Dimorphic Cranial Features). The age of the individuals was assessed on the basis of changes in the morphology of the pubis using the Suchey-Brooks System (1990) and changes observed on the auricular surface.

Unfortunately the 15th season (September 2010) of excavation was conducted only in Tell Masaikh. The second site (Terqa) was closed for the excavation.

Apart from new burials, small amounts of human bones excavated in previous years and mixed with animal remains were studied. In sum,

the remains of 70 individuals were examined: 18 (2 males, 2 females, the sex of the rest is unknown) come from Tell Masaikh from this season, 52 were found at Tell Masaikh and Tell Ashara in the previous seasons (2008, 2009). The samples from Tell Masaikh and Tell Ashara were dated to the Early Bronze (2800–2600 BC), Old Babylonian (1850–1750 BC), Neo-Assyrian (900–700 BC), Roman (200–400 AD), Islamic (600–1200 AD) and Modern (1850–1950 AD) periods. In both sites, the skeletons were in an average state of preservation. The tables below present the preliminary general description of these skeletons.

No	ENT#	Chronology	Sex	Age	SP	EH	CR	Comment
MK 15M7	323	Islamic	?	~0.5	5	-	-	
MK 15G8	323	Islamic	?	~0.5	4			
MK 15M8	323	Islamic	?	1.5-2.0	5			
MK 15M6	323	Islamic	?	1.5-2.5	3			
MK15G13	323	Islamic	?	Adult	1			
MK 15H13	323	Islamic	?	Adult	2			See below text
MK 15G23	22	Islamic	?	~8	5	-	-	
MK 15G24	24	Islamic	F	30-35	4	+	+	<i>Cribra orbitalia</i> ; Schmorls' nodes on Th vertebrae; apertura septalis
MK 15L26	27	Islamic	F	~30?	1	-		
MK 15G30	36	Islamic	M	18-19	4	+		<i>Cribra orbitalia</i> ; Schmorls' nodes on L vertebrae
MK 15L31	30	N. Assyrian	?	Adult	1			
MK 15G43	04	Islamic	?	Adult	1			
MK 15G47	107	N. Assyrian?	?	Adult	1			
MK 15G50	45	Islamic	?	Adult	2			
MK 15L58	58	Islamic	?	~8	4	+	+	<i>Cribra orbitalia</i> ; suspected tuberculosis – abscess cavity on the Th vertebrae (Fig.3)

MK 15G60			?	Juvenis	2			
MK 15L61			?	Adult	2			
MK 15G67			M	30-35	4	+	-	

Tab. 1. Human remains from Tell Masaikh (2010).

ENT#archeological number SP – state of preservation (1 – very poor, 2 – poor, 3 – average, 4 – good, 5 – very good); EH – enamel hypoplasia, CR – caries (+ present, - absent); Chronology: Islamic (600-1200AD). L. Roman (200–400 AD), Neo-Assyrium (900–700 BC).

No	ENT#	Chronology	Sex	Age	Skull	Upper limb	Lower limb	Central part	Comment
MK 13G103	91	N. Assyrian	?	Adult		+	+		
MK 13G120	75	L. Roman	?	Adult		+	+		
MK 13G124	107	N. Assyrian	?	Adult			+		
MK 13G137	126	Islamic	?	Inf II		+	+		
MK 13G158	127	Modern	?	0.5-1		+	+	+	
MK 13G187	170	Islamic	F	~50	+	+	+	+	See below text
MK 13G193(1)	174	Islamic	?	12-15	+	+	+	+	Suspected <i>ostemyelitis</i> on the axis (Fig.4)
MK 13G193(2)	174	Islamic	F?	20-25	+			+	<i>Cribra orbitalia</i>
MK 14G13	23	Islamic	?	Adult			+		
MK 14G16	25	N. Assyrian	?	Adult		+			
MK 14EN18	17	N. Assyrian?	?	Inf I		+	+		
MK 14EN37	39	Islamic	F?	30-40	+	+			
MK 14EN48	61	N. Assyrian	?	Inf I				+	
MK 14G56	36	N. Assyrian	?	Adult			+		
MK 14G84	89	L. Roman	?	Adult		+			

Tab. 2. Human skeletal elements found with the animal bones, Tell Masaikh (season 2008 and 2009).

ENT#archeological number SP – state of preservation (1 – very poor, 2 – poor, 3 – average, 4 – good, 5 – very good); EH – enamel hypoplasia, CR – caries (+ present,

Preliminary report on human remains from Tell Masaikh (MK 15)

- absent); Chronology: Modern (1850-1950AD); Islamic (600-1200AD); Neo-Assyrian (900-700BC); L. Roman (200–400 AD). Upper limb: humerus, ulna, radius, limbs; Lower limb: femur, tibia, fibula, limbs; Central part: vertebrae, ribs, sternum, clavicle, scapula, iliac, ischis, pubic.

No	ENT#	Chronology	Sex	Age	Skull	Upper limb	Lower limb	Central part	Comment
TQ 28F198	1583	Old Babil	?	Adult		+			
TQ 28F223	1543	2650–2450	?	Adult		+		+	
TQ 28F207		Islamic	?	Inf II		+	+		
TQ 28F246		?	?	Adult				+	
TQ28F258		2650–2450	?	Adult					Only tooth
TQ 28F277		2650–2450	?	Adult					Only tooth
TQ 28F282	1596	2650–2450	?	Adult			+		
TQ 28F290	1615	265–2450	?	~1		+	+		
TQ 28F332	1632	Islamic	?	Adult	+	+	+		
TQ 29F11	1672	Islamic	?	Adult			+		
TQ 29F14	1675	Islamic	?	Adult	+			+	
TQ 29F18	1675	Islamic	?	Adult			+	+	
TQ 29F19	1674	?	?	Adult			+		
TQ 29F20	1678	Islamic	?	Adult		+			
TQ 29F27	1681	Islamic	?	Adult				+	
TQ 29F34	1681	Islamic	?	Adult			+		
TQ 29F50	1685	2800–2650	?	Adult			+		
TQ 29F53	1688	Islamic	?	Adult			+		
TQ 29F54	1688	Islamic	?	Adult			+		
TQ 29F55	1672	Islamic	?	Adult			+		
TQ 29F57	1681	Islamic	?	Adult			+		
TQ 29C59	1695	Islamic	?	Adult			+		Only tooth
TQ 29F61	1688	Islamic	M	Adult		+	+		
TQ 29F65	1696	Islamic	?	Inf I		+	+	+	

TQ 29F66	1698	Islamic	?	Adult	+	+	+	+	
TQ 29F67	1686	Islamic	?	Adult		+			
TQ 29F71	1717	Old Babil	?	Adult	+		+	+	
TQ 29F74	1688	Islamic	?	Adult		+		+	
TQ 29F80	1710	Islamic	M?	~40	+	+		+	
TQ 29C90	1720	?	?	~0.5	+	+	+	+	Suspected <i>hematogenous ostemyelitis</i> (Fig.5)
TQ 29F93	1688	Islamic	?	Adult	+	+		+	
TQ 29F112	1692	Islamic	?	Adult				+	
TQ 29F122	1750	Islamic	?	Adult		+	+		
TQ 29F158	1688	Islamic	?	Adult					Only tooth
TQ 29F163	1688	Islamic	?	Adult		+			
TQ 29F167	1780	Islamic	?	Adult					Only tooth
TQ 29K304	7	?	?	Adult			+		

Tab. 3. Human skeletal elements found with the animal bones, Terqa (season 2008 and 2009).

ENT#archeological number. Chronology: Islamic (600-1200AD), Old Babilon (1850–1750 BC). Upper limb: humerus, ulna, radius, limbs; Lower limb: femur, tibia, fibula, limbs; Central part: vertebrae, ribs, sternum, clavicle, scapula, iliac, isch., pubic.

During the last season we have found a strongly defective adult skeleton (preserved in fragments of bones of lower limb) – MK 15H13. It was impossible to determine the sex and the age of this individual. Nevertheless, we pay attention to the proximal epiphysis of fibula (*caput fibulae*) where there was a pathological change in the region of surfaces to part of tibia (*facies articularis capitis fibulae*). In this area we can observe a big niche (26x6mm). The interior of the niche is made of a single bone, likewise to the walls around it, though they do not show a big bulge. Small reconstruction of the cortical bone can be observed on the surfaces around the niche. It does not exert visible irregularity in the medullary cavity. On the basis of the macro- and microscopic

examination (radiological and histological) we believed that the one most likely disease was a serious traumatic changes with a secondary infection with suppurative inflammation. The infection probably started in the knee region. The gate of infection was probably the trauma of breaking the skin and soft tissue. We suppose that the infection confined to the site of infection, as evidenced by healed edges of the bone cavity. The result of inflammation was the bone resorption (*ostitis rarefaciens*) which deepened the medial surface of the fibula. Subsequently, there has been a superstructure and the deterioration of the edges of the niche. It proves that it was a healed wound (Fig.1).

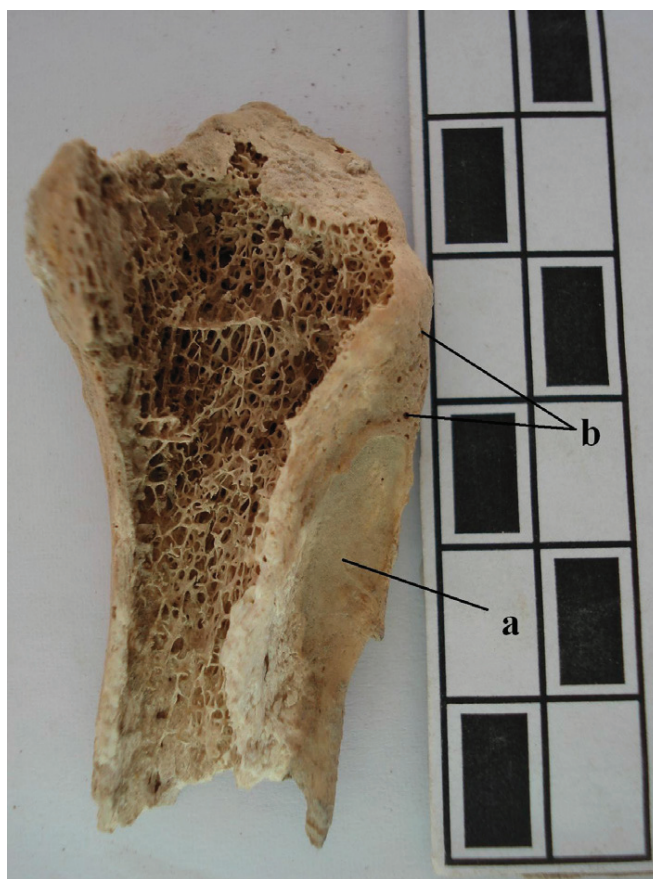


Fig.1. The proximal epiphysis of fibula: a – niche with sharpened edges, b – bone reconstruction around the niche.

The skeletal analysis of particular cases provides a glimpse into the health norm of the past populations. A very interesting case from Tell Masaikh was labeled MK 13G187. The skeleton was recognized as adult

(>45), probably female. The diagnosis of the sex is based on the skull (e.g. expression of nuchal crest, supraorbital margins and glabella) and the measurement of some bones (e.g. vertical diameter of humeral head, diameter of the femoral head). One of the most common areas which indicate physical activity is the tuberosity for the insertion of the deltoid muscle onto the humerus. This structure is strong and distinct. Both bones of the forearm are massive with a number of evidence for physical overload of this region. The caput of radius is deep, radial tuberosity and edges around distal epiphysis are strong with scarcely elevated margins. This led us to the conclusion that movements of the wrist had to be significant. Large exostosis, located on the ulnar olecranon processes, reflects heavy use of the lower insertion of the tendon for *triceps brachii* – the main elbow extender. *Crista musculi supinatoris* is well developed, which proves that the supinator muscle was also unusually pronounced. The top of the iliac crest (and iliac tuberosity) is extremely advanced and flat. This region is connected with *musculus gluteus medius*. It is the main abductor of the thigh. The development of this surface is thus connected with well-developed muscles. Both articular faces on the femur are well developed. Moreover, it is interesting that a “wide bony lip” (osteophytosis) was found around the condyles. The etiology of these changes has been attributed to mechanical loading, which is another strenuous motion. There is a small enthesophyte on the medial surface on the right femur. The proximal epiphysis of tibia is well developed with scarcely elevated margins around the both condyles. The damages of knee joints could be due to physical overload (e.g. long-term kneeling). The damages are observed also on the sternum (manubrium and corpus) (Fig. 2).



Fig.2. Manubrium with the perforation of the anterior and posterior cortex.

The bodies of lumbar vertebrae are characterized by a considerable compression with the osseous block. In this case we suspected tuberculosis. MTB is caused by a group of closely related bacterial species called the *M. tuberculosis* complex. Other bacterial species are widespread in the environment but members of the MTB complex are obligate pathogens. The principal cause of human tuberculosis is *M. tuberculosis*. In this case infection occurs via droplet infection. Humans can also become infected by *M. bovis*. The main sources of infection are milk, dairy products and meat from an infected animal. But it is estimated that *M. bovis* is responsible only for about 6% of human tuberculosis cases (Hardie, Watson 1992). MTB relates to people of all ages, although in most cases the archaeological material concerns, for obvious reasons, the skeletons of juveniles (Ortner 2003, 2008; Stone et al. 2009). MTB is a social disease and the most common predisposing factors are poverty and associated malnutrition, overcrowding, poor hygiene and the sharing of living accommodation with animals (San-

tos, Roberts 2001; Stone et al. 2009). The vertebral column is affected in approximately 50% of cases of skeletal tuberculosis, followed by other weight bearing joints such as the hip and knee, elbow and wrist. Quite often the location of MTB is the manubrium. Any bone can become infected, but the skull is infrequently affected, except in children. Skeletal lesions in MTB tend to be more destructive than formative. But the bone formation can be very extensive, and in some cases the margins of destructive changes will exhibit at least some sclerosis. Bone tuberculosis has, first of all, an osteolytic character with a small bone-forming tendency around pathologically changed foci because mycobacterial toxins hamper the activity of osteogenic cells. Tuberculous foci located within the long bone epiphysis are most often cone-shaped and their base is directed towards the articular surface. In cases of spinal tuberculosis, vertebral bodies and also intervertebral discs are usually the first foci of infection. Hypostatic abscesses are characteristic of spinal tuberculosis. Vertebral bodies can accrete, creating an osseous block. However, our macroscopic observations are not yet confirmed – either by radiological or molecular diagnosis.

This same diagnosis was proposed to a child from Tell Masiakh (MK 15L58), dated on Islamic period. In this case we found the abscess cavity on the Th vertebrae (Fig.3).

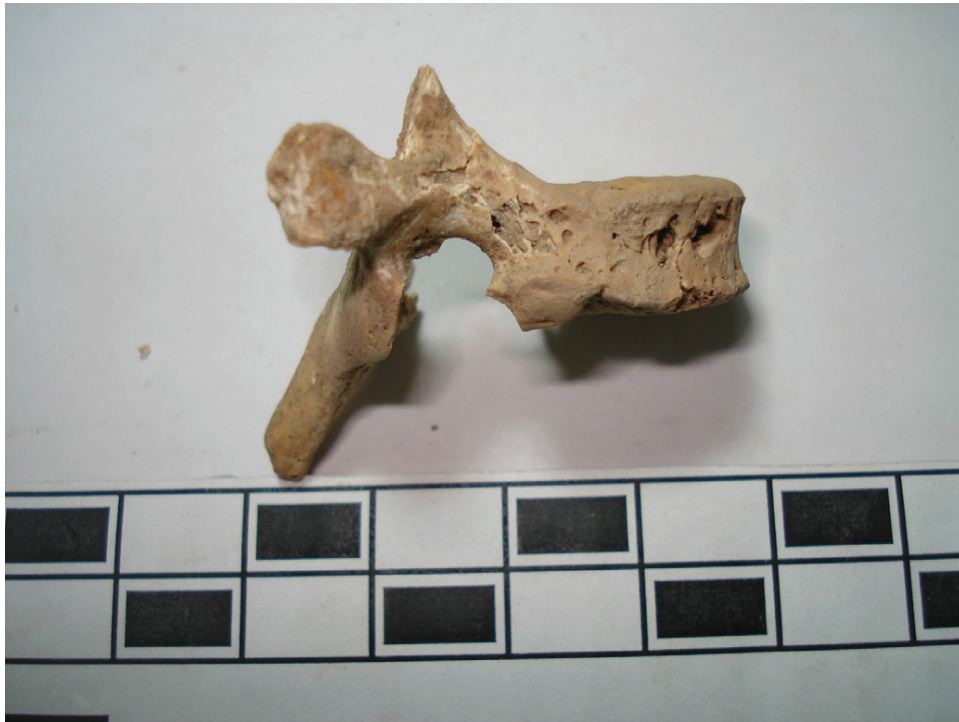

Fig.3. The lytic focus with minimal remodeling – lateral view of Th4 (MK 15L58).



Fig.4. Suspected *ostemyelitis* on axis (MK 12G193.1).

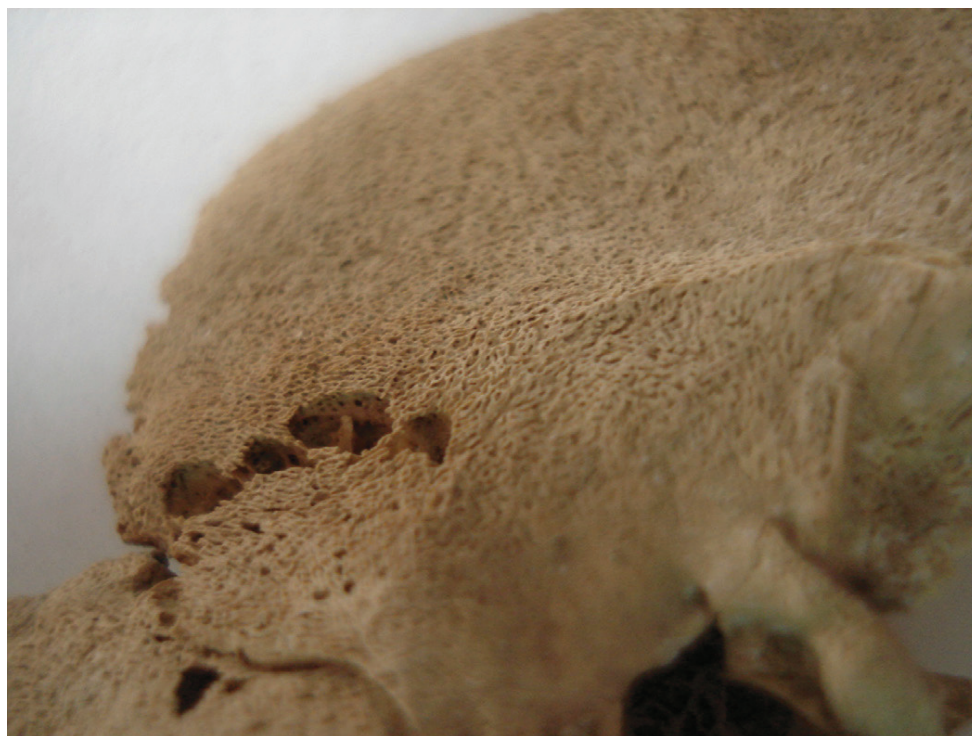

Fig.5. Temporal bone with suspected *hematogenous osteomyelitis* (TQ 29C90).

Bibliography

- Buikstra J.E., Ubelaker D.H. (eds.), 1994, *Standards for data collection from human skeletal remains*. "Arkansas Archeological Survey Research Series" No. 44.
- Brooks S.T., Suchey J.M., 1990, *Skeletal age determination based on the os pubis: a comparison of the Acsádi-Nemeskéri and Suchey-Brooks methods*. *Human Evolution* 5, 227–238.
- Hardie R.M., Watson J.M., 1992, *Mycobacterium bovis in England and Wales: past, present and future*. *Epidemiology and Infection* 109, 23–33.
- Ortner D.J., 2003, *Identification of pathological conditions in human skeletal remains*. Academic Press, London.
- Ortner D.J., 2008, *Differential diagnosis of skeletal lesions in infectious disease*. In: Pinhasi R., Mays S. (eds.), *Advances in human palaeopathology*. John Wiley&Sons, Ltd., Chichester, pp. 191–214.
- Santos A.L., Roberts C.A., 2001, *A picture of tuberculosis in young Portuguese people in the early 20th century: a multidisciplinary study of the skeletal and historical evidence*. *American Journal of Physical Anthropology* 115, 38–49.
- Stone A.C., Wilbur A.K., Buikstra J.E., Roberts C.A., 2009, *Tuberculosis and leprosy in perspective*. *Yearbook of Physical Anthropology* 52, 66–94.