

© Thieme Medical Publishers 333 Seventh Avenue, New York, NY 10001, USA.

Publisher's version is available at the following link:

<https://www.thieme-connect.com/DOI/DOI?10.1055/s-0034-1375297>

Semin Thromb Hemost 2014; 40(04): 431-443

DOI: 10.1055/s-0034-1375297

**Complement Factor H-Antibody-associated hemolytic uremic syndrome:
Pathogenesis, Clinical Presentation and Treatment.**

Johannes Hofer, M.D.,¹ Thomas Giner, M.D.,¹ Mihály Józsi, Ph.D.²

¹Department of Pediatrics I, Innsbruck Medical University, Anichstr. 35, A-6020
Innsbruck, Austria

²MTA-ELTE "Lendület" Complement Research Group, Department of Immunology,
Eötvös Loránd University, Pázmány Péter s. 1/c, 1117 Budapest, Hungary

Key words:

Complement factor H – Complement factor H antibodies – atypical hemolytic uremic
syndrome - Complement Related Diseases – Transplantation

Address for Correspondence

Johannes Hofer, MD,

Innsbruck Medical University, Department of Pediatrics I

Anichstrasse 35

6020 Innsbruck, Austria

+4351250482459

johannes.hofer@i-med.ac.at

www.hus-online.at

Abstract:

The presence of circulating autoantibodies, primarily to complement factor H (CFH-Ab) in plasma characterizes the autoimmune form of atypical hemolytic uremic syndrome (aHUS). This acquired form of aHUS defines a distinct subgroup of aHUS patients, which requires diagnostic and treatment approaches in part different from those of the genetically defined forms. The mechanisms leading to CFH-Ab production and disease onset are not completely understood, but CFH-Ab HUS seems to be secondary to a combination of genetic predisposition and environmental factors. Early diagnosis of this specific aHUS entity is important, as prompt induction of plasma exchange and concomitant immunosuppression leads to a favourable outcome. Nevertheless, information on clinical features and outcome in children is limited. Here, we review the literature on the biological and clinical features of CFH-Ab HUS and discuss therapeutic options.

Introduction

Hemolytic uremic syndrome (HUS) generally indicates a multisystemic disease process, characterized by Coombs-negative (except for pneumococcal-HUS) hemolytic anemia, thrombocytopenia and acute renal failure.

Atypical HUS (aHUS) represents a heterogeneous group of disorders not associated with infection by Shiga toxin producing *E.coli* (eHUS) [1]. Prognosis is poor with high risk of recurrence and about 50% of cases progress to end-stage renal failure [2,3]. Atypical HUS can occur in all age groups, with sporadic and familial presentations [4]. It has been shown that dysregulation of the complement alternative pathway (AP) is the major pathophysiological mechanism leading to aHUS [5]. Overactivation of the complement system leads to endothelial damage and microvascular thrombosis [6]. This is facilitated by mutations in genes coding for complement proteins (complement factor H (CFH) [7-12], membrane cofactor protein (MCP) [13-15], factor I (CFI) [16-18], factor B [19], C3 [20] or thrombomodulin [21]), or by antibodies against the complement regulatory proteins CFH and CFI [22-24].

CFI antibodies were described in three aHUS patients in one single study [24]. However, their functional significance and disease causing and/or promoting potential remained unclear as two of those patients had additional functionally significant mutations in CFH [24].

Antibodies against the alternative complement pathway regulator CFH (CFH-Ab) have been reported in aHUS patients [22,23]. These antibodies are able to induce functional CFH deficiency [22,23,25]. Interestingly, several studies [23,26-31] established a specific relationship between deficiency of factor H-related protein 1 (CFHR1) and the generation of CFH-Ab as discussed in detail later in this article. Data on clinical and biological features are available in the form of several case

reports, small case series and only two bigger cohorts [22,23,26-43]. However, clear data and prospective trials to determine the optimal treatment modalities are lacking. CFH-Ab are not only described in the setting of aHUS but also in post hematopoietic stem cell transplant (HSCT) thrombotic microangiopathy (TMA). One out of 3 patients with TMA following allogeneic HSCT developed CFH-Ab, potentially as a form of “autoimmune” reaction to genotypic differences between recipient and donor [44,45]. Moreover, CFH-Ab may play a significant role in a subgroup of patients with membranoproliferative glomerulonephritis (MPGN). Goodship et al. [46] described two patients with MPGN with a high titre of functionally significant CFH-Ab and suggested that antibody depleting therapy may have a role in such patients and that screening for CFH-Ab should be undertaken in all patients with MPGN. Similarly, in a patient with dense deposit disease, CFH-Ab in context with monoclonal gammopathy was described [47,48]. In addition, CFH-Ab are described in the setting of systemic lupus erythematoses (6.7%), rheumatoid arthritis (9.2% - 16.5%) and thrombosis patients positive for the lupus anticoagulants test (9.4%) [49].

Strikingly, Dhillon et al. [50] found, by using an autoantibody threshold derived from the mean+2 SD of samples of blood donor control subjects, that CFH-Ab are present in at least 1% of healthy blood donors. Zadura et al. [49] describe up to 4% of healthy individuals as CFH-Ab positive. Nevertheless, those CFH-Ab in healthy individuals show different characteristics than most of those described in CFH-Ab aHUS [49,50]. In this review we summarize and discuss the existing experimental and clinical data on this particular autoimmune form of aHUS.

Detection and types of CFH-Ab

The established method to identify CFH-Ab HUS uses ELISA with purified CFH immobilized on microtiter plates and anti-human IgG antibody for detection of

autoantibody binding [22,51]. Thus, the assay that is now commonly used measures free (i.e., not in complex with CFH in patient plasma) autoantibodies of the IgG isotype. In a few studies, further analyses were performed and the majority of analyzed patients had IgG3 and/or IgG1 autoantibodies [22,23,29,52]. In addition, in three patients, IgA class autoantibodies were found together with IgG [53].

Depending on the amount and affinity of circulating autoantibodies, a substantial part of the antibodies is in complex with CFH. These immune complexes can be detected using anti-CFH polyclonal or monoclonal antibodies (mAb) as capture antibodies in ELISA [29]. The mAb should be carefully chosen to bind to a different domain than the autoantibody to avoid false negative results. The titer of CFH-Ab complexes correlates better with disease severity than the free antibody titer [34].

It should be noted that because of individual differences among the patients regarding the exact epitope, isotype and affinity of the autoantibodies, the antibody titers cannot be directly compared between patients and a clear cut-off for the level of disease-causing antibodies cannot be established. The course of titer changes in single patients is, however, informative and useful during follow-up in making decisions on treatment.

It is also important to keep in mind that, when determining the CFH antigen level in the patients, the autoantibodies may interfere with the measurement if they bind to the same site on CFH as the monoclonal antibody used in the CFH ELISA [29,53], thus resulting in false low CFH levels.

Genetics of CFH-Ab HUS

As in many autoimmune diseases, genetic factors increase the susceptibility for developing aHUS. The presence of CFH-Ab is strongly associated with the lack of the *CFHR1* gene and protein. Absence of CFHR1 is most often due to a genomic deletion, including the *CFHR3* and *CFHR1* genes, because of nonallelic homologous recombination. The gene cluster on the long arm of chromosome 1 (1q32) that comprises the *CFH* and the five *CFHR* genes in tandem arrangement is prone to rearrangements and misalignments, since these genes arose via several segmental duplications.

The *CFHR3-CFHR1* deletion is common in the normal population, with varying frequencies in the different ethnic groups (e.g., ~2% in Caucasians and ~16% in certain African populations, up to ~33% in Nigerians) [54,55]. The *delCFHR3-CFHR1* occurs in ~84% of those aHUS patients with CFH-Ab [23,26,27,30,31]. Thus, the development of CFH-Ab is not universally associated with homozygous *CFHR1* deletion, and a significant autoantibody response to CFH can develop in the presence of normal CFHR1 [27,31,53].

In addition, CFHR1-deficiency caused by mutation in *CFHR1*, *CFHR1-CFHR4* deletion, and combined *CFHR3-CFHR1* and *CFHR1-CFHR4* deletions have been identified in autoantibody positive patients [26,27,31]. The common feature of these various gene deletions is the frequent homozygous deletion of the *CFHR1* gene. CFH-Ab are also described in patients with additional *CFH*, *C3*, *MCP* and *CFI* mutations [27].

At the moment, there is only speculation regarding the association of *CFHR1* deletion with CFH-Ab. Since the C-terminal domains of the two proteins are almost identical, it is likely that CFHR1 expression is needed to induce/maintain tolerance against CFH. Because the *CFHR1* deletion is rather common among healthy individuals, other

genetic factors, such as specific HLA alleles, are likely to be additional predisposing factors to autoimmune aHUS.

Environmental factors in CFH-Ab HUS

In addition to genetic factors, environmental factors are apparently important in the pathogenesis of CFH-Ab HUS. An infectious event often precedes the manifestation of CFH-Ab HUS, although no specific pathogen has been identified [34,35]. Possibly CFH acquisition by invading pathogens, a common complement evasion strategy [56], may increase the likelihood of break of tolerance to CFH in the context of infection particularly in *CFHR1*-deficient individuals.

A recent report describing CFH-Ab HUS in Indian patients revealed that among this population the autoantibody-associated form is clearly more frequent (~56%) [35] compared with previously reported European patient cohorts (~6-25%) [22,23,27,31]. This suggests that either the different genetic background of the various ethnic groups influences disease manifestation or this is due to environmental factors (such as infections), life style differences (such as difference in diet, hygiene and the gut microbiom), or the concurrence of these factors. In the same study [35], 4 of 21 asymptomatic siblings with homozygous deletion of *CFHR1* showed high antibody titers without any clinical signs of complement activation. This is a striking finding and a further follow up of those siblings with CFH-Ab monitoring and further characterization of the CFH-Ab is of high importance for our understanding of this aHUS disease group, as this finding may question the pathophysiologic role of CFH-Ab in a subgroup of HUS patients. Further studies are required to define the role of additional genes and/or environmental influences in the pathogenesis of CFH-Ab HUS.

Binding sites of the autoantibodies

Several research groups analyzed the binding sites of the autoantibodies in different patient cohorts. In all of these studies, a major autoantibody-binding site was identified in the C-terminal SCRs 19-20 of CFH [25,27,29,52]. SCRs 19-20 of CFH are responsible for target discrimination, such as recognition and binding to host cells expressing surface-associated glycosaminoglycans (Figure 1). Additional binding sites in SCRs 8-11 [23], SCRs 1-4 and SCRs 8-15 [27] were reported in a few patients. In a few cases, antibody binding only to SCRs 1-4 or 8-15 was found and some autoantibodies bound only to full-length CFH but not to the tested fragments [27]. Recently, analysis of serum samples from the acute phase of the disease revealed polyclonal antibodies binding to several parts of CFH, in many cases including the N-terminal complement regulatory domains, and also the C-terminal recognition domains and the middle part of the molecule [52].

In addition to CFH, autoantibodies often cross-react with CFHR1 [27,52,53], due to the sequence homology of CFHR1 to CFH, and some antibodies also recognize CFHR2 [52]. In contrast, no autoantibody cross-reactivity with CFHR3 and CFHR4 was reported [53].

Effects of the autoantibodies on CFH function

The functional effect of the autoantibodies was studied using IgG fractions derived from the plasma of patients. Patient-IgG caused impaired binding of CFH to its ligands C3b, C3c, C3d, and pentraxin 3 (PTX3) [25,52,57]. As a consequence, autoantibodies inhibited the complement regulatory activity of CFH [22,52,57]. In addition, hemolysis assays using CFH-Ab positive patients' plasma and non-sensitized sheep erythrocytes demonstrated reduced protection of these host-like

cells from complement-mediated lysis due to inhibition of CFH [25,29,52,53]. These functional effects suggest a pathogenic role of the autoantibodies in CFH-Ab HUS.

Regarding CFHR1, besides impairing the interaction of CFHR1 with PTX3, no effect on CFHR1 function was reported [57]. However, CFHR1 may act as a decoy and neutralize the autoantibodies [53].

Clinical and laboratory characteristics of CFH-Ab HUS patients

CFH-Ab HUS has been reported mainly but not exclusively in children [34]. Looking at the pediatric cohorts, the age of onset is significantly different from the age usually reported in pediatric aHUS, which occurs primarily before the age of 2 years (70%) [2], whereas CFH-Ab HUS onset in pediatric cases peaks between 5-12 years with a mean age around 8 years [27,31,34,35].

Table 1 summarizes the data of the 6 biggest CFH-Ab HUS cohorts [27,31,34,35,58,59] published so far regarding the clinical aspects of CFH-Ab HUS. The presented data make clear that CFH-Ab HUS is a severe, multisystemic disease with a highly relapsing disease course. Moreover, all studies show significant percentages of patients presenting with gastrointestinal symptoms and/or diarrhoea, thus, resembling eHUS [1]. In addition, all studies highlight the importance of infectious triggers, even infections with enterohaemorrhagic *Escherichia coli* may be a trigger of CFH-Ab HUS (Innsbruck HUS study group, personal observation).

In general, CFH-Ab HUS is characterized by a highly relapsing course (27-58%, Table 1) especially in the first two years after disease onset (Innsbruck HUS study group, unpublished data) with progression to end-stage renal disease (ESRD) in 20–35% and a mortality rate of 10% [34]. In the published cohorts, dialysis rates from 17-74% are described (Table 1). Together with chronic kidney disease (CKD) and

ESRD, arterial hypertension is the most frequent complication in patients with CFH-Ab HUS (13-100%; Table 1).

Extrarenal complications in CFH-Ab positive HUS during the first flare of disease are common, although CNS involvement was found in a significantly lower percentage than in CFH-Ab negative patients in 3 cohorts (11%/17%/23% vs. 38%) [31,34,59], the biggest published cohort describes initial CNS involvement in 40% [35] of the CFH-Ab HUS patients.

Acute and chronic cardiovascular events, such as cardiac insufficiency [34], myocarditis [26], ischemic changes and gangrene in fingers and toes [60], have been reported in about 10% of aHUS patients with either adult [58] or pediatric onset [2]. Particularly patients with CFH mutations [58] or CFH-Ab [26,34,60] seem to be susceptible to develop cardiovascular disorders.

The presence of CFH-Ab was found to be associated with a lower platelet nadir at disease onset compared to CFH-antibody negative patients [31,34]. Initial presentation of Stx-negative HUS with severe thrombocytopenia in about 6-10 year old patients is especially suspicious for CFH-Ab HUS [31]. The platelet nadir is close to the mean platelet nadir in ADAMTS13 activity deficient thrombotic thrombocytopenic purpura patients, which may lead to diagnostic difficulties [31].

Plasma C3 concentration is decreased in 23 to 67% of patients with CFH-Ab HUS (Table 1), and is lower in patients with high titers of anti-CFH IgG than in those with moderate titers [34]. CFH plasma concentration was decreased at disease onset in 22% of patients studied by Dragon-Durey et al., and it did not correlate with anti-CFH IgG titers [34].

CFH-Ab titers were significantly higher during disease activity than during remission, but may increase again when an adequate triggering event is present [31,34,35]. Thus, repeated measurements in these patients are recommended to recognize a

possible recurrence as early as possible. Due to a high variability between patients, CFH-Ab titers can only be interpreted individually [31,34,35]. Moreover, CFH-Ab titers may spontaneously decline over time [27,31,34,35] and may even disappear in several patients without specific treatment (Innsbruck HUS study group, personal observation).

To date, the influence on the clinical presentation and further disease development of additional mutations, the role of the homozygous CFHR1/3 deletion (up to 10% of CFH-Ab patients do not show this deletion), the different CFH-Ab binding sites, the presence of polyclonal CFH-Ab and the role of the free vs. bound CFH-Ab fraction remains unclear and urgently needs further studies.

Therapy of CFH-Ab HUS

Up to now, there are no consensus guidelines on the treatment of CFH-Ab HUS. As for all other aHUS forms, the rationale behind different treatment strategies is the normalization of AP regulation. Thus, plasma exchange (PE) using fresh frozen plasma (FFP) or virus inactivated pooled plasma, to remove the antibodies and enhance the CFH pool, is still the first line induction treatment in CFH-Ab HUS, although strategies including the use of the complement C5 blocker eculizumab are emerging (discussed in the next section).

However, antibody titer often reincreases after PE cessation and relapses of HUS frequently occur. On the other hand, complications of ongoing plasma therapy are multiple, especially primary and secondary treatment failure, allergic reactions and vascular access-related infections or thrombosis reduce disease prognosis and quality of life significantly [61]. Thus, patients with CFH-Ab HUS may benefit from a PE-free maintenance strategy. One major goal for an adequate maintenance therapy is the prevention of ongoing CFH-Ab production and thus disease recurrences.

Therefore, initiation of maintenance immunosuppressive/immunoregulatory treatment is recommended, using steroids, azathioprine, mycophenolate mofetil (MMF), intravenous cyclophosphamide, anti-CD20 and/or intravenous immunoglobulins (IVIG) [28,31-43]. The duration of plasma therapy (PT), in particular applied as PE and the choice of the immunosuppressive drug are presently not standardized. Both should be guided by the evolution of CFH-Ab titer. High antibody titer is correlated with the risk of relapses, which in turn increase the risk of renal sequelae [31,34,35]. In the largest reported series [34,35] induction therapy using PE directly followed by early maintenance therapy using immunosuppressants had a favourable outcome. Table 2 summarizes published case series and case reports regarding treatment and outcome of CFH-Ab HUS patients, excluding the two biggest cohorts [34,35], discussed in detail below. The summary of published case series shows the heterogeneity of therapeutic strategies used. Nevertheless, PE is the preferred therapy option at disease onset and the majority of patients received a maintenance therapy. Patients with conservative therapy (no PT, complement targeting or immunosuppressive treatment) alone and patients without an initial maintenance therapy showed a high rate of ESRD (Table 2).

From the French cohort [34] consisting of 45 CFH-Ab HUS patients treatment modalities and the outcome of 30 CFH-Ab HUS patients were documented. Six of the thirty patients were treated conservatively with the following disease evolution of the first flare: 1/6 without sequelae, 1/6 with CKD, 2/6 with late relapses (>1 month after onset and >15 days after remission), 1/6 with ESRD and 1/6 without any signs of remission. 6/30 patients were treated with plasma infusion (PI) as induction therapy, five of those presenting with late relapses and one with therapy resistance. Fifteen of the 30 patients were treated with PE initially, one without any sequelae, three with CKD, six with late recurrences, one with initial ESRD, three were treatment resistant

and one patient died. Three out of thirty received PE plus immediate immunosuppression, 2 using oral prednisolone and cyclophosphamide, one using MMF; none of those patients showed any sequelae, all responded to therapy and showed complete remission. IVIG was administered in 15 patients but did not show any benefit in the published cohort. However, IVIG were administered in combination with PE or steroids and details of timing and dosage were not discussed. In one out of two patients use of rituximab during recurrence was successful, in the other it failed to show any benefit.

The biggest published CFH-Ab HUS cohort [35] so far, describes 138 CFH-Ab HUS patients, including information on therapy and outcome. One hundred and five of the 138 patients were treated with PE initially, 15 received 2-10 PI; for 26 patients with high CFH-Ab titers and/or delayed hematologic remission IVIG was given additionally. In 87 patients immunosuppression as induction therapy was started 27 ± 21 days after disease onset. All of those patients received oral prednisolone, in 49 patients combined with cyclophosphamide and in 18 patients combined with rituximab. A further maintenance immunosuppression regimen was given to 47 patients, all receiving oral prednisolone, in 18 patients in combination with MMF and in 8 patients in combination with azathioprine.

Combined therapy with PE and induction immunosuppression showed significant improved renal survival rates compared to patients not receiving combined treatment. (83% vs 46% at 6 months and 71% vs 33% at last follow up). Furthermore, maintenance therapy with immunosuppressive agents significantly lowered probability of disease relapse.

Irrespective of the different therapeutic strategies, a relapse-free survival was documented in 89% after 6 months, 85% after 12 months and 73% at last follow up. After 3 months 8% showed CKD stage I with normal urine analysis, 43% CKD stage I

with hypertension, hematuria and/or proteinuria, 20% showed CKD stages II-III and 30% CKD stages IV-V. Determinants of adverse outcome were a high peak creatinine, high CFH-Ab titers at onset, low C3, delayed hematologic remission, need for prolonged dialysis, acute cortical necrosis in the biopsy and time to PE \geq 17 days. The authors concluded that delayed initiation of PE (2-3 weeks beyond onset) predicted adverse outcomes. Differences between types of immunosuppression were not investigated in this study. Maintenance immunosuppressive therapy reduced the risk of relapses by 91%. The use of immunosuppression prevented one relapse in about 5 patients (number needed to treat), thus maintenance immunosuppression appeared to be a more feasible and successful strategy for preventing relapses, than prolonged/chronic PE.

All in all, this study demonstrated the long term benefits of an early induction therapy using PE and immunosuppressive agents followed by an immunosuppression-based maintenance regimen.

However, CFH-Ab patients with additional mutations in complement regulatory proteins other than CFHR1/3 are thought to be at a higher risk for ongoing complement activation and disease activity despite an early and adequate immunosuppressive regimen [27,39]. Until now we lack data on the effect of additional mutations on CFH-Ab HUS patients' therapy and outcome.

Eculizumab in CFH-Ab patients

Eculizumab was shown to effectively block the terminal complement cascade by preventing the cleavage of C5 whose pivotal role in complement-HUS pathogenesis was demonstrated in murine models [62,63]. Eculizumab is approved for the use in atypical HUS, its safety and efficacy was shown in two clinical trials, recently published [64]. Most recent reviews come to different conclusions concerning the use

of eculizumab in CFH-Ab HUS patients and do not address the threefold possibility for applying eculizumab, i.e., the possible use for induction during acute phase, for maintenance therapy or during relapses [65-67].

Noone et al. [39] report the successful use of eculizumab in two patients with CFH-Ab HUS and a homozygous CFHR1/3 deletion without additional complement mutations. The first patient presented with a PI dependent course, and was switched in stable condition to eculizumab therapy 4 years after initial disease presentation. CFH-Ab titers remained low despite ongoing signs of complement activation, creatinine showed a stable course and there were no signs of disease recurrence, as already documented under PI maintenance therapy. Thus this case lacks evidence for a disease improving effect of eculizumab, despite demonstrating a safe weaning from chronic PI under eculizumab four years after disease onset. The second patient (homozygous CFHR1/3 deletion, no additional complement mutations) showed a PE responsive disease course and was switched to eculizumab 16 days after disease onset due to allergic reactions. Four days after eculizumab initiation his C3, creatinine and platelets normalized. During the further disease course C3 decreased again and stayed low. For this patient follow-up data of only 11 weeks are presented, which is a limitation for the interpretation of the therapeutic effect.

Whether eculizumab is reasonable as induction therapy replacing PE for CFH-Ab HUS patients is still under debate; initial abdication of eculizumab in the treatment of CFH-Ab HUS may even nowadays be justified, as aggressive PE, followed by maintenance therapy with immunosuppression was shown to be a good treatment option for CFH-Ab associated HUS patients [28,31-43]. On the other hand, for CFH-Ab HUS patients with additional complement regulatory protein mutations eculizumab therapy for induction and maintenance may be of benefit compared to an exclusive immunosuppressive strategy [27,39].

Although only very few data on the use of eculizumab in CFH-Ab HUS patients exist thus far [39,65-68], in contrast to data on PE combined with immunosuppression, its use as initial induction therapy or during recurrences may be justified in patients with CFH-Ab and additional complement mutations and for patients where initial PE is not feasible or patients do not respond. The use of eculizumab as maintenance option is questionable.

Controlled studies comparing the combination of early PT and immunosuppression with eculizumab based therapeutic strategies are urgently needed. In addition, other complement inhibitors are being developed, such as those inhibiting complement at the level of C3 [69], which may be another treatment option in the future.

Figure 2 details the authors recommendation for the therapy of CFH-Ab HUS patients based on the data presented in this review.

Transplantation and CFH-Ab

The risk of post-transplant recurrence in patients with CFH-Ab HUS is not well documented. Altogether 17 CFH-Ab HUS patients undergoing 25 renal transplantations are reported in the literature [26,27,32-35,40,41,58,70] (Table 3). HUS recurrence was described for six grafts, leading to graft loss in three. Two grafts (from 1 patient) were lost due to chronic allograft nephropathy.

For 8/25 transplantations a specific prophylactic pre-transplant treatment was performed, 7 of eight renal transplantations (RT) showed a favourable outcome without recurrence and a TMA episode was observed in one graft, showing a favourable outcome after initiation of eculizumab therapy.

It is suggested that recurrence can be expected if a high CFH-Ab titer persists at the time of transplantation, thus a pre transplant procedure to reduce CFH-Ab is reasonable and, on the basis of the above mentioned data, recommended. Those

prophylactic therapies should include PE at least prior to transplantation; whether further prophylactic interventions are necessary (rituximab, IVIG) remains unclear and has to be decided on an individual basis. Nevertheless, recurrence free transplantation was achieved in patients with CFH-Ab without any specific treatment as well (Table 3). However, pre-transplant screening of CFH-Ab titers was not available in these cases.

The evaluation of post-transplant recurrence risk is hampered by the fact that a significant proportion of CFH-Ab HUS patients carries mutations in CFH, CFI, MCP or C3 [27] and that up to now it is unclear whether patients with CFH-Ab HUS and homozygous CFHR1/3 deletions (in some publications denoted as DEAP HUS patients [40,71]) behave different than patients with CFH-Ab without such a deletion. Six out of 9 transplanted CFH-Ab HUS patients showed a homozygous CFHR1/3 deletion. Four out of 10 transplanted CFH-Ab HUS patients who underwent further genetic screening showed alterations: C3 mutation (n=1), CFH mutation (n=1), CFH variant (n=1) and CFI polymorphism (n=1) (Table 3). Thus, the available data in the literature do not allow a final conclusion on that issue. Nevertheless, it seems reasonable to treat patients with CFH-Ab HUS and additional mutations, especially CFH mutations, as high-risk patients.

Recently published recommendations [65,70], point towards a differentiation of CFH-Ab HUS patients prior to renal transplant in low, moderate and high-risk patients concerning recurrence after renal transplantation. Patients with low risk of recurrence are those with long term negative CFH-Ab titers and without additional complement mutations. Those patients are currently not thought to benefit from a prophylactic therapy before renal transplant. Patients with persistent low CFH-Ab titers and without additional mutations are recommended to be treated with either prophylactic PE or prophylactic eculizumab, the decision depends on the availability of an

adequate vascular access and/or the availability of eculizumab. It remains to be shown whether CFH-Ab HUS patients with high CFH-Ab titers but without additional complement mutations belong to the high-risk group. For CFH-Ab HUS patients with additional mutations we recommend prophylactic eculizumab therapy prior and immediately after transplantation. The optimal time point for weaning of eculizumab remains to be determined and depends on the clinical presentation of the patient, the graft, CFH-Ab titers and complement activation split products. To address the latter we recommend monitoring of C3, preferably activation split products such as C3d, or SC5b-9. It is likely that on the long run the immunosuppressive regimen for transplanted children may be sufficient for an ongoing inhibition of CFH-Ab production; nevertheless, the transplant procedure itself may serve as a strong trigger for complement activation, but also for CFH-Ab production.

Concluding remarks

Early and accurate CFH-Ab testing using appropriate assays is the key step, as early induction of plasma exchange and concomitant immunosuppression lead to a favourable outcome in those patients.

Although there is no sufficient data on the use of eculizumab in CFH-Ab HUS patients thus far, its use as initial induction therapy or during recurrences may be justified in patients with CFH-Ab and additional complement mutations and for patients where initial PE is not feasible or patients are not responding. Eculizumab for maintenance therapy in CFH-Ab patients in general is not indicated.

Acknowledgements

The work of J.H. is supported by the “Tiroler Wissenschaftsfond” and the “Österreichische Nationalbank” (Grant: 12711)

The work of M.J. is supported by the “Lendület” program of the Hungarian Academy of Sciences (Grant LP2012-43).

Conflict of interest

J.H. received honorarium from Alexion Pharmaceuticals Inc. and served on advisory boards.

Abbreviations

CFH, complement factor H; CFH-Ab, complement factor H antibodies; CFHR, complement factor H related protein; CFI, complement factor I; CKD, chronic kidney disease; CNS, central nervous system; EHEC, enterohaemorrhagic Escherichia coli; ESRD, endstage renal disease; FFP, fresh frozen plasma; HSCT, hematopoietic stem cell transplant; HUS, hemolytic uremic syndrome; aHUS, atypical HUS; eHUS, (Enterohemorrhagic) E. coli-induced HUS; IVIG, intravenous immunoglobulins; mAb, monoclonal antibodies; MCP, membrane cofactor protein; MMF, mycophenolate mofetil MPGN, membranoproliferative glomerulonephritis; PE, plasmaexchange; PI, plasma infusion; PT, PE and/or PI; PTX, pentraxine; RT, renal transplantation; SCR, short consensus repeats; TMA, thrombotic microangiopathy;

References:

1. Wuerzner R, Riedl M, Rosales A et al.: Treatment of enterohemorrhagic *Escherichia coli*-induced hemolytic uremic syndrome. *Semin Thromb Hemost.* 2014. Current issue
2. Sellier-Leclerc AL, Fremeaux-Bacchi V, Dragon-Durey MA et al.: Differential impact of complement mutations on clinical characteristics in atypical hemolytic uremic syndrome. *J Am Soc Nephrol* 18:2392-2400, 2007
3. Zimmerhackl LB, Scheiring J, Prufer F et al.: Renal transplantation in HUS patients with disorders of complement regulation. *Pediatr Nephrol* 22:10-16, 2007
4. Constantinescu AR, Bitzan M, Weiss LS et al.: Non-enteropathic hemolytic uremic syndrome: Causes and short-term course. *Am J Kidney Dis* 43:976-982, 2004
5. Noris M, Mescia F, Remuzzi G.: STEC-HUS, atypical HUS and TTP are all diseases of complement activation. *Nat Rev Nephrol.* 8(11):622-33, 2012
6. Riedl M, Fakhouri F., Le Quintrec M. et al.: Role of complement-targeting therapy in spectrum of thrombotic microangiopathy. *Semin Thromb Hemost.* 2014. Current issue
7. Caprioli J, Bettinaglio P, Zipfel PF et al.: The molecular basis of familial hemolytic uremic syndrome: Mutation analysis of factor H gene reveals a hot spot in short consensus repeat 20. *J Am Soc Nephrol* 12:297-307, 2001
8. Caprioli J, Castelletti F, Bucchioni S et al.: Complement factor H mutations and gene polymorphisms in haemolytic uraemic syndrome: the C-257T, the A2089G and the G2881T polymorphisms are strongly associated with the disease. *Hum Mol Genet* 12:3385-3395, 2003
9. Dragon-Durey MA, Fremeaux-Bacchi V, Loirat C et al.: Heterozygous and homozygous factor H deficiencies associated with hemolytic uremic syndrome or

membranoproliferative glomerulonephritis: Report and genetic analysis of 16 cases. *J Am Soc Nephrol* 15:787-795, 2004

10. Perez-Caballero D, Gonzalez-Rubio C, Gallardo ME et al.: Clustering of missense mutations in the C-terminal region of factor H in atypical hemolytic uremic syndrome. *Am J Human Gen* 68:478-484, 2001

11. Richards A, Buddles MR, Donne RL et al.: Factor H mutations in hemolytic uremic syndrome cluster in exons 18-20, a domain important for host cell recognition. *Am J Human Gen* 68:485-490, 2001

12. Warwicker P, Goodship THJ, Donne RL et al.: Genetic studies into inherited and sporadic hemolytic uremic syndrome. *Kidney Int* 53:836-844, 1998

13. Fremeaux-Bacchi V, Moulton EA, Kavanagh D et al.: Genetic and functional analyses of membrane cofactor protein (CD46) mutations in atypical hemolytic uremic syndrome. *J Am Soc Nephrol* 17:2017-2025, 2006

14. Noris M, Brioschi S, Caprioli J et al.: Familial haemolytic uraemic syndrome and an MCP mutation. *Lancet* 362:1542-1547, 2003

15. Richards A, Kemp EJ, Liszewski MK et al.: Mutations in human complement regulator, membrane cofactor protein (CD46), predispose to development of familial hemolytic uremic syndrome. *Proc Nat Acad Sci USA* 100:12966-12971, 2003

16. Fremeaux-Bacchi V, Dragon-Durey MA, Blouin J et al.: Complement factor I: a susceptibility gene for atypical haemolytic uraemic syndrome. *J Med Genet* 41:e84, 2004

17. Kavanagh D, Kemp EJ, Mayland E et al.: Mutations in complement factor I predispose to development of atypical hemolytic uremic syndrome. *J Am Soc Nephrol* 16:2150-2155, 2005

18. Kavanagh D, Richards A, Noris M et al.: Characterization of mutations in complement factor I (CF1) associated with hemolytic uremic syndrome. *Mol Immunol* 45:95-105, 2008
19. de Jorge EG, Harris CL, Esparza-Gordillo J et al.: Gain-of-function mutations in complement factor B are associated with atypical hemolytic uremic syndrome. *Proc Nat Acad Sci USA* 104:240-245, 2007
20. Fremeaux-Bacchi V, Goodship T, Regnier CH et al.: Mutations in complement C3 predispose to development of atypical haemolytic uraemic syndrome. *Mol Immunol* 44:3923, 2007
21. Delvaeye M, Noris M, De VA et al.: Thrombomodulin mutations in atypical hemolytic-uremic syndrome. *N Engl J Med* 36:345-357, 2009
22. Dragon-Durey MA, Loirat C, Cloarec S et al.: Anti-factor H autoantibodies associated with atypical hemolytic uremic syndrome. *J Am Soc Nephrol* 16:555-563, 2005
23. Józsi M, Licht C, Strobel S et al.: Factor H autoantibodies in atypical hemolytic uremic syndrome correlate with CFHR1/CFHR3 deficiency. *Blood*. 111:1512-1514, 2008
24. Kavanagh D, Pappworth IY, Anderson H, Hayes CM, Moore I, Hunze EM, et al. Factor I autoantibodies in patients with atypical hemolytic uremic syndrome: disease-associated or an epiphenomenon? *Clin J Am Soc Nephrol*. 7(3):417-26, 2012
25. Józsi M, Strobel S, Dahse HM et al.: Anti-factor H autoantibodies block C-terminal recognition function of factor H in hemolytic uremic syndrome. *Blood* 110:1516-1518, 2007
26. Abarrategui-Garrido C, Martínez-Barricarte R, López-Trascasa M et al.: Characterization of complement factor H-related (CFHR) proteins in plasma reveals

novel genetic variations of CFHR1 associated with atypical hemolytic uremic syndrome. *Blood* 114:4261-4271, 2010

27. Moore I, Strain L, Pappworth I et al.: Association of factor H autoantibodies with deletions of CFHR1, CFHR3, CFHR4, and with mutations in CFH, CFI, CD46, and C3 in patients with atypical hemolytic uremic syndrome. *Blood* 115:379-387, 2010

28. Lee BH, Kwak SH, Shin JI et al.: Atypical hemolytic uremic syndrome associated with complement factor H autoantibodies and CFHR1/CFHR3 deficiency. *Pediatr Res.* 66:336-340, 2009

29. Strobel S, Hoyer PF, Mache CJ et al.: Functional analyses indicate a pathogenic role of factor H autoantibodies in atypical haemolytic uraemic syndrome. *Nephrol Dial Transplant* 25:136–144, 2010

30. Dragon-Durey MA, Blanc C, Marliot F et al.: The high frequency of complement factor H related CFHR1 gene deletion is restricted to specific subgroups of patients with atypical haemolytic uraemic syndrome. *J Med Genet.* 46:447-450, 2009

31. Hofer J, Janecke AR, Zimmerhackl LB et al.: Complement factor H-related protein 1 deficiency and factor H antibodies in pediatric patients with atypical hemolytic uremic syndrome. *Clin J Am Soc Nephrol.* 8(3):407-15, 2013

32. Kwon T, Dragon-Durey MA, Macher MA et al.: Successful pre-transplant management of a patient with anti-factor H autoantibodies-associated haemolytic uraemic syndrome. *Nephrol Dial Transplant* 23: 2088–2090, 2008

33. Le Quintrec M, Zuber J, Noel LH et al.: Anti-Factor H autoantibodies in a fifth renal transplant recipient with atypical hemolytic and uremic syndrome. *Am J Transplant* 9: 1223–1229, 2009

34. Dragon-Durey MA, Sethi SK, Bagga A et al.: Clinical features of anti-factor H autoantibody-associated hemolytic uremic syndrome. *J Am Soc Nephrol.* 21:2180-2187, 2010

35. Sinha A, Gulati A, Saini S et al.: Prompt plasma exchanges and immunosuppressive treatment improves the outcomes of anti-factor H autoantibody-associated hemolytic uremic syndrome in children. *Kidney Int.* doi: 10.1038/ki.2013.373, 2013
36. Boyer O, Balzamo E, Charbit M et al.: Pulse cyclophosphamide therapy and clinical remission in atypical hemolytic uremic syndrome with anti-complement factor H autoantibodies. *Am J Kidney Dis* 55:923-927, 2010
37. Sana G, Dragon-Durey MA, Charbit M et al.: Long-term remission of atypical HUS with anti-factor H antibodies after cyclophosphamide pulses. *Pediatr Nephrol.* 29(1):75-83, 2014
38. Reusz GS, Szabó AJ, Réti M et al.: Diagnosis and classification of hemolytic uremic syndrome: the Hungarian experience. *Transplant Proc.* 43(4):1247-1249, 2011
39. Noone D, Waters A, Pluthero FG et al.: Successful treatment of DEAP-HUS with eculizumab. *Pediatr Nephrol.* 2013
40. Skerka C, Zipfel PF, Müller D et al.: The autoimmune disease DEAP-hemolytic uremic syndrome. *Semin Thromb Hemost.* 36(6):625-32, 2010
41. Waters AM, Pappworth I, Marchbank K et al.: Successful renal transplantation in factor H autoantibody associated HUS with CFHR1 and 3 deficiency and CFH variant G2850T. *Am J Transplant.* 10(1):168-72, 2010
42. Kim JJ, McCulloch M, Marks SD et al.: The clinical spectrum of hemolytic uremic syndrome secondary to complement factor H autoantibodies *Clin Nephrol.* 2013
43. Uslu-Gökceoğlu A, Doğan CS, Comak et al.: Atypical hemolytic uremic syndrome due to factor H autoantibody. *E Turk J Pediatr.* 55(1):86-9, 2013
44. Jodele S, Licht C, Goebel J et al.: Abnormalities in the alternative pathway of complement in children with hematopoietic stem cell transplant-associated thrombotic

microangiopathy. *Blood*. 19;122(12):2003-7, 2013

45. Ricklin D, Cines DB: TMA: beware of complements. *Blood*. 122(12):1997-9, 2013

46. Goodship TH, Pappworth IY, Toth T et al.: Factor H autoantibodies in membranoproliferative glomerulonephritis. *Mol Immunol*. 52(3-4):200-6, 2012

47. Sethi S, Sukov WR, Zhang Y et al.: Dense deposit disease associated with monoclonal gammopathy of undetermined significance. *Am J Kidney Dis*. 56(5):977-82, 2010

48. Nozal P, Strobel S, Ibernón M et al.: Anti-factor H antibody affecting factor H cofactor activity in a patient with dense deposit disease. *Clin Kidney J* 5: 133–136, 2012

49. Foltyn Zadura A, Zipfel PF, Bokarewa MI et al.: Factor H autoantibodies and deletion of Complement Factor H-Related protein-1 in rheumatic diseases in comparison to atypical hemolytic uremic syndrome. *Arthritis Res Ther*. 15;14(4):R185, 2012

50. Dhillon B, Wright AF, Tufail A et al.: Complement factor h antibodies and age-related macular degeneration. *Invest Ophthalmol Vis Sci*. 51(11):5858-63, 2010

51. Dragon-Durey MA, Blanc C, Roumenina LT et al.: Anti-factor h autoantibodies assay. *Methods Mol Biol*. 1100:249-56, 2014

52. Blanc C, Roumenina LT, Ashraf Y et al.: Overall neutralization of complement factor H by autoantibodies in the acute phase of the autoimmune form of atypical hemolytic uremic syndrome. *J Immunol*. 189(7):3528-37, 2012

53. Strobel S, Abarategui-Garrido C, Fariza-Requejo E et al.: Factor H-related protein1 neutralizes factor H auto antibodies in autoimmune hemolytic uremic syndrome. *Kidney Int*. 80:397-404, 2011

54. Hageman GS, Hancox LS, Taiber AJ et al.: Extended haplotypes in the complement factor H (CFH) and CFH-related (CFHR) family of genes protect against

age-related macular degeneration: characterization, ethnic distribution and evolutionary implications. *Ann Med.* 38(8):592-604, 2006

55. Holmes LV, Strain L, Staniforth SJ et al.: Determining the population frequency of the CFHR3/CFHR1 deletion at 1q32. *PLoS One.* 16;8(4):e60352, 2013

56. Kraiczy P, Wurzner R. Complement escape of human pathogenic bacteria by acquisition of complement regulators. *Mol Immunol.* 43(1-2):31-44, 2006

57. Kopp A, Strobel S, Tortajada A et al.: Atypical hemolytic uremic syndrome-associated variants and autoantibodies impair binding of factor h and factor h-related protein 1 to pentraxin 3. *J Immunol.* 15;189(4):1858-67, 2012

58. Noris M, Caprioli J, Bresin E et al.: Relative role of genetic complement abnormalities in sporadic and familial aHUS and their impact on clinical phenotype. *Clin J Am Soc Nephrol* 5:1844-1859, 2010

59. Geerdink LM, Westra D, van Wijk JA et al.: Atypical hemolytic uremic syndrome in children: complement mutations and clinical characteristics. *Pediatr Nephrol.* 27(8):1283-91, 2012

60. Malina M, Gulati A, Bagga A et al.: Peripheral gangrene in children with atypical hemolytic uremic syndrome. *Pediatrics* 131, e331-335, 2013

61. Loirat C, Garnier A, Sellier-Leclerc AL et al.: Plasma therapy in atypical hemolytic uremic syndrome. *Semin Thromb Hemost* 36(6):673-81, 2010

62. de Jorge EG, Macor P, Paixão-Cavalcante D et al.: The development of atypical hemolytic uremic syndrome depends on complement C5. *J Am Soc Nephrol.* 22(1):137-45, 2011

63. Dubois EA, Cohen AF: Eculizumab. *Br J Clin Pharmacol.* 2009 Sep;68(3):318-9.

64. Legendre CM, Licht C, Muus P et al.: Terminal complement inhibitor eculizumab in atypical hemolytic-uremic syndrome. *N Engl J Med.* 6;368(23):2169-81, 2013

65. Zuber J, Le Quintrec M, Sberro-Soussan R et al.: New insights into postrenal transplant hemolytic uremic syndrome. *Nat Rev Nephrol.* 7(1):23-35, 2011
66. Campistol JM, Arias M, Ariceta G et al.: An update for atypical haemolytic uraemic syndrome: diagnosis and treatment. A consensus document. *Nefrologia.* 18;33(1):27-45, 2013
67. Zuber J, Fakhouri F, Roumenina LT et al.: Use of eculizumab for atypical haemolytic uraemic syndrome and C3 glomerulopathies. *Nat Rev Nephrol.* 8(11):643-57, 2012
68. Ardissino G, Tel F, Testa S, Marzano AV, Lazzari R, Salardi S, et al. Skin Involvement in Atypical Hemolytic Uremic Syndrome. *Am J Kidney Dis.* 2013
69. Hebecker M, Alba-Domínguez M, Roumenina LT et al.: An engineered construct combining complement regulatory and surface-recognition domains represents a minimal-size functional factor H. *J Immunol.* 15;191(2):912-21, 2013
70. Zuber J, Le Quintrec M, Morris H et al.: Targeted strategies in the prevention and management of atypical HUS recurrence after kidney transplantation. *Transplant Rev* 27(4):117-25, 2013
71. Zipfel PF, Mache C, Muller D, Licht C, Wigger M, Skerka C, et al. DEAP-HUS: deficiency of CFHR plasma proteins and autoantibody-positive form of hemolytic uremic syndrome. *Pediatr Nephrol.* 25(10):2009-19, 2010

Legends to tables and figures

Table 1 title: Summary of clinical data of the six biggest CFH-Ab HUS cohorts published.

Table 1 legend: Card.: cardiac complications; CNS: central nervous system; D+: diarrhea positive; GIT: gastrointestinal Symptoms; Hypert.: arterial hypertension; Mut.: mutations; N: number; n/a: not applicable; Panc.: pancreas; Rec.: recurrence; Ref.: reference; RTI: respiratory tract infection; Vasc.: vascular defects; y: years

Table 2 title: Current therapy reports on CFH-Ab HUS patients. Excluding references 35 and 36, which are discussed in detail in the text.

Table 2 legend: AZA: azathioprine; CKD: chronic kidney disease; CNS: central nervous system; conservative treatment: no complement targeted therapy, PT or IS; CPH: cyclophosphamide; CyA: cyclosporine A; ECU: eculizumab; ESRD: end-stage renal disease; IS: immunosuppression; IVIG: intravenous immunoglobulins; MTP: methylprednisolone; MMF: mycophenolate mofetil; N: number; n/a: not applicable; PE: plasma exchange; PI: plasma infusion; Pred.: prednisolone; PT: plasma therapy (PE and/or PI); Rec.: recurrence; Ref.: reference; RTX: rituximab; TMA: thrombotic microangiopathy; TX transplantation;

Table 3 title: Cases of transplanted CFH-Ab HUS patients and their outcome reported in the current literature.

Table 3 legend: ATG: anti thymocyte globuline; AZA: azathioprine; CFHR: complement factor H related protein; conservative treatment: no complement targeted therapy, PT or Immunosuppression; CyA: cyclosporine A; ECU: eculizumab; ESRD: end-stage renal disease; Gen.: genetics; IVIG: intravenous immunoglobulins; MMF: mycophenolate mofetil; n/a: not applicable; nTx: number of transplantations;

p.c: personal communication; PE: plasma exchange; PI: plasma infusion; polym.: polymorphism; Pred.: prednisolone; PT: plasma therapy; rec.: recurrence; Ref.: reference; RTX: rituximab; sequ.: sequencing; TMA: thrombotic microangiopathy; Tx: transplantation;

Figure 1 title: Schematic structure of factor H and representation of CFH binding to C3b.

Figure 1 legend: The schematic structure of complement factor H (CFH). (A) CFH is composed of 20 short consensus repeat (SCR) domains, of which the four N-terminal domains (SCRs 1-4) mediate the complement inhibiting effect of CFH and the two C-terminal domains (SCRs 19-20) mediate CFH binding to host cells. (B) Schematic representation of CFH binding to C3b deposited on a host cell surface.

Figure 2 title: Recommendation for the treatment of CFH-Ab HUS.

Figure 2 legend: ECU: eculizumab; PE: plasma exchange; IS: immunosuppression; At onset of suspected aHUS the underlying cause is unclear. Thus, the current recommendations point towards an early implementation of eculizumab therapy till the diagnosis is made. Alternatively, early PE therapy is possible. If CFH-Ab screening is positive two treatment options are reasonable. On the one hand a further ECU therapy with additional IS therapy (this treatment arm will be preferred for patients where ECU was already started before CFH-Ab diagnosis) and on the other hand a further PE therapy with additional IS agents. For patients with PE resistance (no hematological response after 5 daily sessions) or complications a switch to ECU is recommended. Although no evidence based data are available, it is reasonable that ECU or PE therapy can be stopped/weaned after reaching complete or hematologic remission. However, a further maintenance immunosuppression is

important combined with an individual CFH-Ab titer follow up. The duration of an optimal maintenance therapy remains to be determined. If CFH-Ab titers are persistently at a low range or negative and the patient had no signs of recurrence, weaning of IS therapy after 1-2 years on an individual basis seems reasonable. The optimal kind of IS is currently not established. We recommend the initiation of mycophenolate mofetil (MMF) with an AUC goal of $>40\text{mg/lh}$. If MMF fails to be sufficient, addition of oral prednisolone or a switch to Cyclophosphamide plus oral prednisolone is preferred.

Figure 1:

A



B

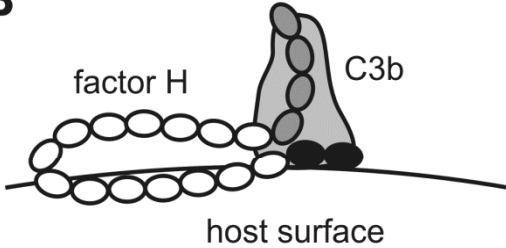
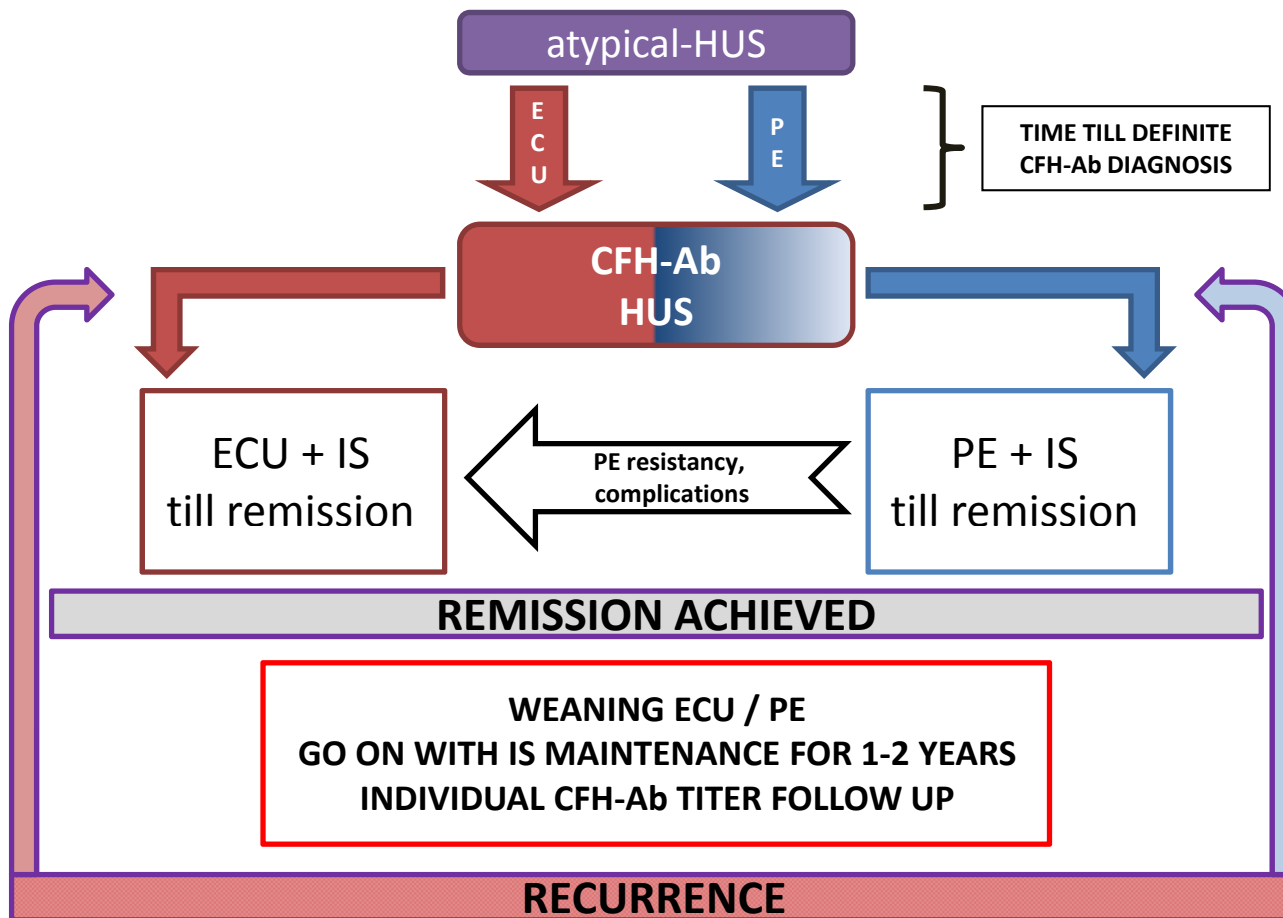


Figure 2:



Tables 1-3:

Ref	N (mean age)	Prodromes			Symptoms at onset							Dialysis	Mean Platelet Count/ μ l	Low C3	Mean CFH-Ab titer in AU/ml	Rec	Mut. (n/n)
		GIT	D+	RTI	Hypert.	Olig/ Anuria	CNS	Liver/ Panc.	Hemat- uria	Protein -uria	Vasc. Card.						
35	138 (8y)	n/a	9%	n/a	66%	42%	40%	57%/n/a	41%	59%	1.4% N=2	30%	62000	62%	7054	27%	n/a
34	45 (9y)	84%	53%	n/a	68%	28%	23%	50%/23%	27%	n/a	6.7% N=3	57%	56000	58%	11564	58%	0/26
31	25 (8 y)	87%	13%	42%	59%	50%	11%	n/a	n/a	n/a	n/a	74%	30000	41%	1342	n/a	1/8
27	13 (8y)	n/a	n/a	n/a	n/a	n/a	n/a	n/a	n/a	n/a	n/a	n/a	n/a	23%	n/a	n/a	5/13
58	10 (n/a)	n/a	13%	50%	13%	n/a	n/a	n/a	n/a	n/a	n/a	n/a	n/a	43%	n/a	37%	2/10
59	6 (n/a)	83%	n/a	50%	100%	50%	17%	n/a	n/a	n/a	n/a	17%	50000	67%	n/a	50%	2/6

Ref	N	Treatment at Onset	Maintenance	For Recurrence	Outcome at last follow up (years) – Transplantation (TX)
42	3	PE	none	1/3 – treated with PE + IS	Complete remission
39	1	MTP Pulse + oral Pred. – no Remission - 9 weeks after onset change to PE+PI	None till 1 st rec. After 1 st rec.: PI – sustained remission over 4y, switched to ECU after 4y	1 st : 2 weeks after remission PI + oral Pred	Complete remission
	1	PP – complete remission	PP – allergic reaction – PP switched to ECU	No rec.	Complete remission
36,37	1	PE+PI - remission	None till 2 nd rec, oral Pred. after 2 nd rec.	1 st : PE+RTX, 3 months later: 2 nd : PE+CPH+Pred.	Complete remission (6y)
	1	PI – no remission PE + 2 CPH pulses - remission	Oral Pred over 6 months	No rec.	Complete remission (4y)
	2	PE + 2 CPH pulses - remission	Oral Pred over 6 months	No rec.	Complete remission (4 months and 4y)
43	1	PE - remission	None till 1st rec., after 1st rec: oral Pred. + AZA + PI; AZA switched to CyA and to MMF	1st rec.: 1 month after remission: PE – no remission – PE+MTP Pulse+CPH	CKD IV after 20 months CNS-Sequelae
41	1	PE – partial remission	none	PE for rec. after 8 weeks - ESRD	ESRD after 8 weeks; succesfully transplanted after 74 weeks with basiliximab, Pred. and MMF; Favorable outcome with negative CFH-Ab titers 6 ½ y after Tx
59	3	PE – partial remission	PT	PE	3/3 Hypertension
	1	PE – partial remission	none	n/a	1/1 Hypertension
	2	Conservative	none	Conservative	1/2 death
27	3	PE	PE	2 rec. under PE in one, 3 rec. in another and multiple relapses in the third patient	Complete remission (2, 3 and 6y)
	10	Conservative	none	Conservative	6/10 with ESRD, 3/10 transplanted; Transplanted patients without Rec. ; Complete remission at last follow up in 4 patients (3-11 y)
58	8	3/8 PE + Steroids – 2 remissions	n/a	n/a	75% of TMA episodes responsive to PT, 25% complete remission, 50% partial remission; after 3y 1/8 in complete remission and 2/8 in partial remission; 1/8 transplanted – with graft lost due to rec.; 5/8 ESRD or death after 3y
26	7	5/7 PE 2/7 Conservative	5/7: none 1/7: PI+oral Pred 1/7: AZA	n/a	Complete remission in 3/7 after 11y (PE, no maintenance), 8y (PE, maintenance with PI and oral Pred.), and 10y (PE, maintenance with AZA); 3/7 ESRD (2 with conservative treatment 1 with PE alone) 1/7 Death (myocarditis at initial episode)
68	1	ESRD before treatment PE – hematologic remission	none	1 rec. including nonspecific skin vasculopathy – treated with Ecu - remission	ESRD Hematologic remission after 1st rec.
32,33	2	Conservative	None	None	1: ESRD after onset – 5 times transplanted; before last Tx diagnosis of CFH-Ab; Succesfully last transplant under PI and PE 2: ESRD 2 month after onset; oral Pred. + AZA + RTX+PE prior Tx, PE for 4 months after Tx – no rec. 2 years after Tx

28	1	PE – ongoing hemolysis at day 18 + IVIG and start with oral Pred.	After 1 st rec.: Oral Pred. + AZA	1 st rec. at day 58: PE	Complete remission
	2	PE	PI+oral Pred.	None	Complete remission (1y)
40	1	PI – partial remission with ESRD	None	No rec.	ESRD – successfully transplanted after publication
	1	Conservative	After 1 st rec.: PE+MMF	1st rec.: 3 weeks after onset – treated with PE and RTX - ESRD	ESRD – successfully transplanted
29	1	PE – remission	None till 2 nd rec. After 2 nd rec.: RTX + MMF – no remission; further PE + CPH + Immunadsorption - ESRD	1st rec.: 4 month after remission – treated with PE 2 nd rec.: 3 months after remission – treated with PI without success - PE	ESRD
	1	PE – remission	Oral Pred. + MMF	No rec.	Complete remission (2y)
	1	PE - remission	PI	No rec.	CRI III 7.5y after onset

Ref	N (Age onset /1 st Tx)	Gen.	nTx	Disease course prior Tx	Treatment prior Tx	Tx	Outcome
35	3 (n/a)	n/a	1	n/a	4-6 sessions PE (n=2) Perioperative IVIG+RTX (n=2)	Living-related (n=2) Cadaveric (n=1)	At 6-15 months post Tx all patients with satisfactory graft function and CFH-Ab levels between 180-430 AU/ml
27	1 (10/12)	CFHR1/3 C3 mutation	1	Initially conservative treatment followed by ESRD	n/a	n/a	3 years after Tx no rec.
	1 (6/11)	No CFHR1/3 no further mutation	1	Initially conservative treatment followed by ESRD	n/a	n/a	2 years after Tx no rec.
	1 (10/12)	CFHR1/3 CFH mutation	1	Initially conservative treatment followed by ESRD	n/a	n/a	6 years after Tx no rec.
34	1 (n/a)	n/a	1	n/a	PE + RTX	n/a	Favorable after 8 months
	2 (n/a)	n/a	1	n/a	n/a	n/a	Tx with undiagnosed CFH-Ab; both with post-Tx recurrence; CFH-Ab disappeared in both 42 months and 50 months after Tx
26	1 (4/6)	Homozygous CFHR1 def. No further mutations	1	Initially conservative treatment followed by ESRD	n/a	n/a	At the age of 20 years still functioning graft, no comments on recurrences
	1 (3/4)	No deletions or mutations	1	Initially conservative treatment followed by ESRD	n/a	n/a	Functioning graft at last follow up (8 months after Tx)
32	1 (10/12.5)	CFH sequ. normal Rest n/a	1	Initially conservative treatment followed by ESRD	oral Pred. + AZA (failed to decrease CFh-Ab titer) - RTX+PE prior Tx (CFH-Ab became undetectable)	PE for 4 months after Tx; Is with: basiliximab, Pred., CyA (switched to Tac- at month 18 post Tx), MMF	no rec. And favorable outcome 2 years after Tx
33	1 (6/7)	CFHR1/3	5	Initially conservative treatment followed by ESRD	before last transplant diagnosis of CFH-Ab; Successful last transplant under PI and PE	5 times transplanted; Retrospectively CFH-Ab positive already before 4th transplant;	1 st Tx lost due to recurrence 15 days after Tx; 2 nd and 3 rd Tx lost after 13 and 11y due to chronic allograft nephropathy; 4 th graft lost after 1y due to TMA; 5 th graft with favorable outcome at last follow up (4y)
70	1 (6/n/a)	CFHR1/3	5	n/a	Incomplete response to prophylactic PE ;	n/a	5 y post 5 th Tx TMA lesions in biopsy performed because of decrease in renal function; start with ECU followed by stabilization of serum creatinine ;
41	1 (9/11)	CFHR1/3 CFH variant G2850T	1	PE followed by recurrence – again PE followed by ESRD	2h prior Tx Basiliximab	Cadaveric; 4 days post Tx again Basiliximab; IS with Pred. And MMF	6 ½ years after Tx favorable outcome with negative CFH-Ab titers
58	1 (n/a)	n/a	1	n/a	n/a	n/a	Graft loss due to recurrence
40	1 (12/14)	CFHR1/3 FI polym.	1	PI – partial remission with ESRD	IVIG, PE, ATG	Living related; Pred. (1year), Tac., MMF	Favorable outcome 3y after Tx, CFH-Ab detectable at low titer (p.c Hofer J.)