

August 2013
Brain

[Ferumoxytol and Stroke: Assessing CNS Vascular Disease](#)

Manninger SP, Muldoon LL, Nesbit G, et al. [An Exploratory Study of Ferumoxtran-10 Nanoparticles as a Blood-Brain Barrier Imaging Agent Targeting Phagocytic Cells in CNS Inflammatory Lesions](#). *AJNR Am J Neuroradiol* 2005;26:2290-300.



Edit Dósa

Ultrasmall superparamagnetic iron oxide (USPIO) nanoparticles may have benefit over gadolinium-based contrast agents (GBCA) for neuroimaging. Using ferumoxtran-10 in patients with brain tumors, we demonstrated that delayed (24 hours) changes in MR signal intensity in the brain are not due to tumor cells but rather the intracellular endocytosis of iron oxide particles in reactive cells that are mainly at the tumor margin and necrotic regions. This finding led us to investigate the utility of MRI with ferumoxtran-10 in other neurologic conditions that are associated with reactive cells, including demyelinating, cerebrovascular, and hematopoietic malignant CNS lesions, with the goal of identifying which lesion type(s) should be investigated in more focused trials. We observed that MRI with ferumoxtran-10 showed different size and location of lesions in primary CNS lymphoma and in other CNS inflammatory disorders than imaging with GBCA. In some cases, ferumoxtran-10—in other cases, GBCA—showed more intense or different volumes of enhancement. Ferumoxtran-10 did not enhance as well in multiple sclerosis as it did in other inflammatory lesions or tumors, which may be indicative of different blood-brain barrier defects or phagocytic cell specificity in these different lesions.

Subsequent studies used the FDA-approved USPIO ferumoxytol in patients with intracerebral neoplasms (largely glioblastoma).^{1,2} We have carefully evaluated MRI sequences and timing in the same patients scanned on 3 consecutive days (day 1: GBCA; day 2: ferumoxytol; day 3: follow-up for ferumoxytol with no additional contrast) at various magnetic field strengths up to 7T. We have found that ferumoxytol is safe and effective for imaging CNS neoplasms and inflammatory lesions. Direct comparison of GBCA and ferumoxytol for tumor imaging showed greater signal intensity changes on T1WI with GBCA compared to delayed ferumoxytol ($P < .0001$), but there was no significant difference in lesion enhancement volumes, particularly in untreated glioblastoma. Ferumoxytol-induced signal changes were noted in areas with no gadoteridol enhancement in 6 patients.^{1,2} T2WI obtained 24–72 hours

after ferumoxytol showed hypointensity (signal dropout) associated with nanoparticle accumulation in 26 of 49 patients¹ and 16 of 26 patients² in 2 reports. Delayed signal changes after ferumoxytol may also be important in the diagnosis of CNS inflammatory disorders and primary CNS lymphoma.³

My main interest involves the visualization of CNS vascular malformations with USPIO. Vascular malformations may have variable degrees of inflammation that may be relevant clinically. Arteriovenous malformations may demonstrate increased expression of inflammatory cytokines, and macrophages are frequently present within resected surgical specimens of AVM (including up to 30% of unruptured AVM) and cavernous malformation. Postferumoxytol susceptibility-weighted images revealed capillary telangiectasias and cavernomas that were completely unnoticeable on the no-contrast and post-GBCA images.⁴ We also demonstrated additional tributary veins in all patients with developmental venous anomalies (Figure 1). Hasan et al⁵ showed that ferumoxytol given to patients with AVM could be visualized as T2 hypointense signal within the AVM nidus and vascular walls. Histology confirmed macrophage staining within vessel walls in one of these cases. Because ferumoxytol is taken up by phagocytic leukocytes and, in particular, by macrophages, it could prove useful for monitoring inflammation within “at risk” AVMs or cavernomas at higher risk of rupture. The superiority of ferumoxytol compared to GBCA for detection of intracranial vascular malformations may be on the basis of superior intravascular contrast with T2*-weighted sequences, in addition to inflammatory cellular uptake. Our future goal is to investigate the use of ferumoxytol as a macrophage-imaging agent in the visualization of inflammatory cells within and around AVMs.

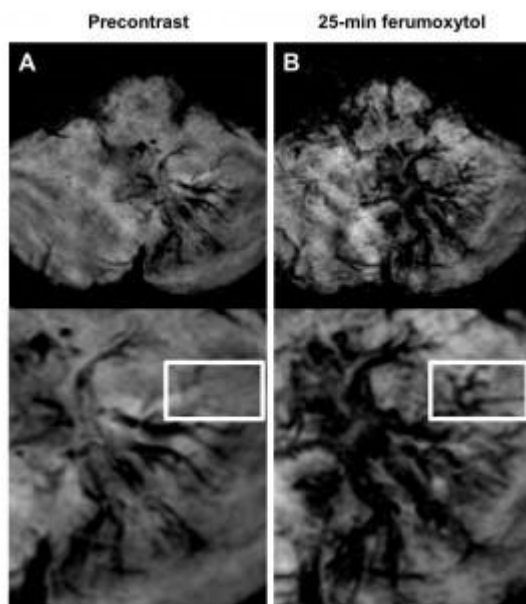


Figure 1. Developmental venous anomaly. Axial susceptibility-weighted images obtained before (A) and 25 minutes after ferumoxytol administration (B). Although the left cerebellar lesion is visible on both the pre- and post-ferumoxytol susceptibility-weighted images, the ferumoxytol scan demonstrates additional tributary veins (*rectangle*) compared with the precontrast sequence. Published in Dósa et al, *Stroke* 2011.⁴

With more than 10 years of experience behind us, we believe that USPIO-enhanced MRI offers a number of potential advantages over conventional GBCA-enhanced MRI in the diagnostic workup of CNS lymphoma and inflammatory intracranial neoplastic mimics. First,

USPIO-enhanced MRI may give different or additional areas of enhancement that may offer improved surgical targeting opportunities. This may be particularly true for T2-weighted enhanced scans with USPIO, which may offer an alternative sampling site for biopsy to conventional postcontrast T1WI with gadolinium. Second, ferumoxytol, in contrast to ferumoxtran-10, can be administered via rapid IV bolus injection and can be used for dynamic imaging in addition to anatomic imaging. Ferumoxytol-based dynamic susceptibility-weighted contrast-enhanced perfusion MRI may offer discrimination of inflammatory diseases, such as demyelination, from neoplastic disorders. Third, USPIO can be used safely in patients with renal failure who cannot receive gadolinium.¹⁻³

However, every coin has two sides; the USPIO-enhanced MRI has limitations as well. These limitations include the following: 1) requirement for at least 2 consecutive days of imaging to obtain anatomic “enhanced” scans similar to GBCA-enhanced MRI, 2) ferumoxytol-based DSC perfusion MRI, similar to GBCA-based DSC perfusion MRI, alone remains unable to discriminate between malignant lymphoid and glial neoplasms, and 3) the potential for USPIO enhancement rarely to persist up to several months after injection may result in confusion for hemorrhage.

References

1. Hamilton BE, Nesbit GM, Dósa E, et al. [Comparative analysis of ferumoxytol and gadoteridol enhancement using T1- and T2-weighted MRI in neuroimaging](#). *AJR Am J Roentgenol* 2011;197:981–88. doi: 10.2214/AJR.10.5992
2. Dósa E, Guillaume DJ, Haluska M, et al. [Magnetic resonance imaging of intracranial tumors: intra-patient comparison of gadoteridol and ferumoxytol](#). *Neuro Oncol* 2011;13:251–60. PMID: 21163809. doi: 10.1093/neuonc/noq172
3. Farrell BT, Hamilton BE, Dósa E, et al. [Using iron oxide nanoparticles to diagnose CNS inflammatory diseases and PCNSL](#). *Neurology* 2013 Jun 14. [Epub ahead of print]. doi: 10.1212/WNL.0b013e31829bfd8f
4. Dósa E, Tuladhar S, Muldoon LL, et al. [MRI using ferumoxytol improves the visualization of central nervous system vascular malformations](#). *Stroke* 2011;42:1581–88. doi: 10.1161/?STROKEAHA.110.607994
5. Hasan DM, Amans M, Tihan T, et al. [Ferumoxytol-enhanced MRI to image inflammation within human brain arteriovenous malformations: a pilot investigation](#). *Transl Stroke Res* 2012;3(Supplement 1):166–73. doi: 10.1007/s12975-012-0172-y