




# An anatomical study of the dorsal and ventral nasal conchal bullae and middle nasal conchae in normal Shetland ponies: Computed tomographic anatomical and morphometric findings

Kerstin Gerlach<sup>1</sup>  | Ingrid Vervuert<sup>2</sup> | Claudia Gittel<sup>1,3</sup> | Lisa Köhler<sup>1</sup> |  
Nane Schmidt<sup>1</sup> | Karsten Winter<sup>4</sup> | Dagmar Berner<sup>5</sup>  | Antonia Troillet<sup>1</sup> |  
Ellen Schulz-Kornas<sup>6,7</sup> 

<sup>1</sup>Department for Horses, Faculty of Veterinary Medicine, Veterinary Teaching Hospital, University of Leipzig, Leipzig, Germany

<sup>2</sup>Institute of Animal Nutrition, Nutrition Diseases and Dietetics (IAND), Veterinary Teaching Hospital, University of Leipzig, Leipzig, Germany

<sup>3</sup>Queen's Veterinary School Hospital, University of Cambridge, Cambridge, England

<sup>4</sup>Institute of Anatomy, Veterinary Teaching Hospital, University of Leipzig, Leipzig, Germany

<sup>5</sup>Royal Veterinary College, Equine Referral Hospital, University of London, London, UK

<sup>6</sup>Max Planck Institute for Evolutionary Anthropology, Max Planck Weizmann Center for Integrative Archaeology and Anthropology (MPWC), Leipzig, Germany

<sup>7</sup>Department of Cardiology, Endodontology and Periodontology, Veterinary Teaching Hospital, University of Leipzig, Leipzig, Germany

## Correspondence

Kerstin Gerlach, Department for Horses, Faculty of Veterinary Medicine, Veterinary Teaching Hospital, University of Leipzig, Leipzig, Germany.  
Email: [gerlach@vetmed.uni-leipzig.de](mailto:gerlach@vetmed.uni-leipzig.de)

## Abstract

Equine paranasal sinuses are susceptible to inflammation. Insufficient drainage through the nasal passages and meatus may lead to the accumulation of inspissated purulent discharge. Particularly in ponies, these anatomical structures are suspected to be relatively small. To date, there are no reports considering the morphology of nasal conchal bullae in small horse breeds such as Shetland ponies. The aim of the present study was to evaluate the size of the conchal bullae and the medial nasal conchae of Shetland ponies and their relation to the skull dimension using computed tomography. Reconstructed images of healthy adult heads of Shetland ponies were used. Linear skull measurements as well as two cranial indices of the head dimensions were taken. Length, width and height of the dorsal and ventral conchal bullae and the medial nasal conchae were measured in relation to the skull and compared with the data of skulls of large breed horses. The anatomical proportions of pony heads were characterized by a smaller cranial index and a greater nasal index than those of large breed horses. Shetland ponies showed a longer cranial length compared with the nasal length. Heads are consistently smaller, and the relationship of the bullae to the head length was also smaller than those measured in large breed horses. A negative correlation between the head and bullae size was found. In conclusion, this study suggests that Shetland ponies have distinguishing proportions of the head. These findings are relevant for clinical examination and surgical treatment of equine sinus disease in those breeds.

## KEYWORDS

computed tomography, dorsal conchal bulla, Shetland pony, skull, ventral conchal bulla

## 1 | INTRODUCTION

The conchal sinuses are parts of the paranasal sinus system in horses. They are often involved in paranasal sinus diseases such as infections, neoplasia and cysts in clinical cases of sinus diseases. In

48% of all patients, the conchofrontal sinus was involved, and in 78% of all patients, the ventral conchal sinus was involved (Dixon et al., 2012). Furthermore, the nasal conchal bullae showed involvement in 23% of clinical cases of paranasal sinus diseases (Dixon et al., 2015).

This is an open access article under the terms of the Creative Commons Attribution-NonCommercial-NoDerivs License, which permits use and distribution in any medium, provided the original work is properly cited, the use is non-commercial and no modifications or adaptations are made.

© 2020 The Authors. *Anatomia, Histologia, Embryologia* published by Wiley-VCH GmbH.

In large breed horses, conformation of the skull (Evans & McGreevy, 2006) as well as the conchal sinuses and bullae (Finnegan et al., 2011; Froydenlund et al., 2015; Liuti et al., 2016; Giavotto & Barakzai, 2017) as well as the sinonasal communication (Tatarniuk et al., 2010; Brinkschulte et al., 2014) were already described, including measurements of skull dimensions. In contrast, the size and dimensions of conchal sinuses and bullae in smaller breeds like ponies are rarely reported and there is a lack of knowledge concerning this area of research. In order to diagnose and treat ponies with suspected paranasal sinus diseases, the normal anatomy has to be understood. Furthermore, diagnostic and surgical instruments used for large breed horses may be inadequate for smaller breeds. The morphology of the dorsal and ventral conchal bullae in Shetland ponies and their relation to skull size has not been described so far in the literature. Moreover, there is a lack of established methods for evaluating skull morphology in small equine breeds.

The first aim of the present study was to evaluate the skull morphology of adult Shetland ponies and compare these findings with data from large breed horses received from studies using clinical computed tomography (CT). Secondly, dimensions of the dorsal and ventral conchal bullae and the middle nasal conchae in Shetland ponies should be established by means of their linear parameters and relationships to the head length. Understanding the distinguishing features in ponies from large breed horses may help to develop new diagnostic and surgical instruments and strategies in future.

## 2 | MATERIAL AND METHODS

### 2.1 | Ponies

Heads of 15 ( $n = 15$ ) healthy adult Shetland ponies of both sexes (nine geldings, five mares, one unknown) aged seven to 13 years (mean age 9.2 years) were examined by computed tomography. The average weight of the 14 living ponies was 119 kg (standard deviation 18.8 kg). The ponies were not registered in a studbook. The height at withers was within the expected range for Shetland ponies of between 87 and 107 cm.

Thirteen ponies participated in two approved clinical studies without clinical signs of a paranasal sinus disease (nasal discharge, abnormal skulls swelling, dental disorder) (No. TVV 05/15 and 32/15). One pony was presented as a clinical case, also without signs of a paranasal sinus disease. One additional head was examined *post-mortem* without sinus disease. This pony was euthanized for reasons unrelated to the study. All 14 *in vivo* examinations were performed in dorsal recumbency under general anaesthesia. A descriptive, prospective cross-sectional study design was used.

### 2.2 | Computed tomography (CT)

CT was performed using a multi-detector row CT unit (Mx8000 IDT 16 CT scanner, Philips Medical Systems DMC GmbH, Hamburg,

Germany). CT settings used were as follows: tube voltage of 120 kVp, tube current (200 mAs), 0.75-s tube rotation time, pitch (0.438) and 1 mm slice thickness. Computed tomographic images were reconstructed using a window width  $-500$  HU (Hounsfield units) and window level, 2000 HU (kernel smoother).

## 2.3 | Measurements of head and bullae

### 2.3.1 | Skull measurements

Three-dimensional (3-D) reconstructed images (Philips CT software) were positioned at right angles to bony palate and dorsal projections (Figure 1) by the same person (KG) and measured by another person (LK). In the present study, skull length 1, cranial length, nasal length and zygomatic width (Figure 1) were measured in accordance with Evans and McGreevy (2006). To evaluate and compare the osseous skull parts regarding their size, we used the following three indices: skull index (zygomatic width  $\times 100$ /skull length 1), cranial index (cranial width  $\times 100$ /cranial length 1) and nasal index (zygomatic width  $\times 100$ /nasal length). Evans and McGreevy (2006) defined skull length 1 from the lateral dorsal nasal cartilages to the external occipital protuberance and zygomatic width as being measured at the level of the nasal palpebral commissure. The measuring point of zygomatic width divides the skull length into cranial and nasal length. In order to evaluate skull proportions, measured head lengths and bullae dimensions were compared with the measured length 2 from the occiput to the rostral aspect of the premaxilla (Froydenlund et al., 2015).

### 2.3.2 | Bullae linear dimensions

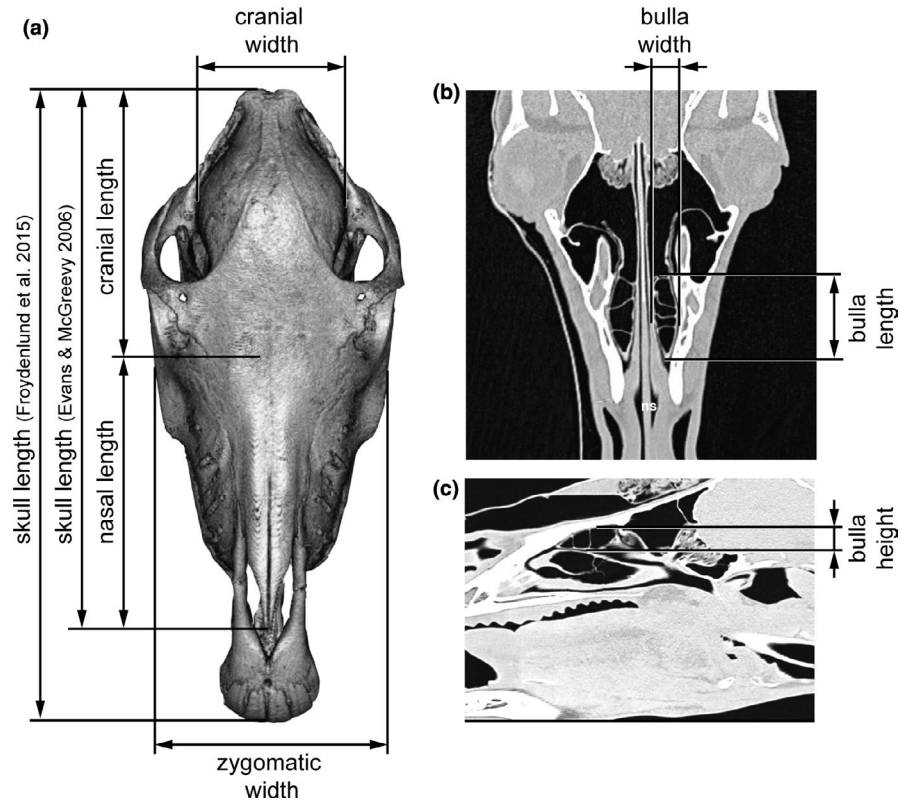
The dorsal CT images were reconstructed parallel to the hard palate. The sagittal images were arranged parallel to the nasal septum by the same person (KG), using multiplanar reconstruction (MPR). These images (Figure 1b,c) were used to measure the nasal conchal bullae and middle nasal conchae with the Picture Archiving Communication System, curaSmartClient Dicom Viewer (curasystems GmbH, Ettlingen, Germany) in agreement with two examiners (NS and KG). The means and ranges were calculated for each linear measurement in accordance with large breed horses (Liuti et al., 2016).

The vertically oriented septae in the bullae were counted.

## 2.4 | Data analysis

Statistical analysis was performed by using IBM® SPSS® Statistics (version 22; IBM Corp.; Armonk, NY, USA). Data were tested for normal distribution using the Shapiro-Wilk test. Group comparisons between the right and left bullae measurements were performed using the *t* test for paired samples (normally distributed data) and Wilcoxon-signed rank test (non-normally distributed data).

**FIGURE 1** Overview anatomical structures and measurements: (a) dorsal multiplanar 3D CT reconstruction of the pony skull with measured length and width distances, (b) dorsal CT reconstruction with the section of the dorsal bulla (ns = nasal septum) and (c) sagittal CT reconstruction indicating the height of the dorsal bulla



Correlations between the length measurements were calculated using Spearman's rank correlation coefficient, which can be interpreted as follows:  $0.8 \leq |r| \leq 1.0$  very strong,  $0.6 \leq |r| < 0.8$  strong,  $0.4 \leq |r| < 0.6$  moderate,  $0.2 \leq |r| < 0.4$  weak and  $0.0 \leq |r| < 0.2$  very weak; ( $|r|$  represents the absolute value of the correlation coefficient). Significance for all tests was set at  $p < .05$ .

Considering different conformations of the skull by evaluating the relationship between bullae dimensions, 'adjusted' measurements of the bullae rostrocaudal and dorsoventral dimensions were calculated by dividing the individual bulla length by the skull length 2 and multiplying by 100 (Froydenlund et al. 2015). The entire middle nasal conchae were evaluated by applying the same method.

For example:

Dorsal conchal bulla (DCB) adjusted length measure = (DCB length/head length)  $\times$  100.

### 3 | RESULTS

#### 3.1 | Morphological measurements of the skull

The craniometric measurements of Shetland Pony skulls were evaluated. Descriptive statistics for the skull measurements are shown in Table 1. A skull length 1 of 322.29 mm to the nasal bone, a skull

**TABLE 1** Descriptive data for skull measurements (modified Evans & McGreevy, 2006), skull length 2 (Froydenlund et al., 2015) ( $N = 15$ )

Skull measurements	Mean (Minimal-Maximal) (mm)	SD (mm)
Skull length 1 occiput to nasal bone (Evans & McGreevy, 2006)	322.29 (302.05–357.35)	15.85
Skull length 2 occiput to praemaxilla (Froydenlund et al., 2015)	367.75 (350.65–391.5)	12.01
Cranial length Occiput to zygomatic bone at the level of nasal palpebral commissure	166.51 (155.65–185.55)	8.20
Nasal length zygomatic bone at the level of nasal palpebral commissure to the nasal bone	158.66 (138.30–204.75)	15.69
Cranial length/nasal length	1.06 (0.86–1.25)	0.10
Cranial width from the depressions caudal to the zygomatic process of the temporal bones in either side of the head	95.61 (88.10–101.65)	3.60
Zygomatic width Zygomatic bones at the level of the nasal palpebral commissure	145.72 (140.65–151.85)	3.34
Skull index zygomatic width $\times$ 100/skull length 1	45.30 (41.84–48.96)	2.19
Cranial index cranial width $\times$ 100/cranial length 1	57.71 (50.55–61.54)	2.87
Nasal index zygomatic width $\times$ 100/nasal length 1	92.57 (73.02–104.74)	8.28

Abbreviations: mm, millimetre; SD, standard deviation.

length 2 of 367.75 mm to the premaxilla and a zygomatic width of 145.72 mm were obtained. The short skull length 1 was used to calculate the skull index.

### 3.2 | Bullae measurements

Mean values of linear dimensions for the two conchal bullae and the middle nasal conchae are presented in Table 2. There was no significant difference between both sides. Therefore, mean values were used for further analyses (Table 2).

The dorsal conchal bulla was easier to define and was the largest bulla (DCB > VCB).

The middle nasal concha showed smaller dimensions in comparison with the two nasal bullae.

### 3.3 | Number of septae

The median number of septae within the DCB was two (range 1–3) and for the VCB one (range 0–2).

### 3.4 | Relationship between skull and bullae dimensions

There was a negative correlation between the skull, the dorsal and ventral nasal bullae lengths and the length of the middle nasal concha (Table 3, Figures 2–4).

## 4 | DISCUSSION

### 4.1 | Morphological proportion of the pony skull

It is well known that Shetland ponies have smaller heads and shorter skulls than Standardbreds, Arabians and Thoroughbreds (Evans &

McGreevy, 2006). The skull is also shorter as described in donkeys and regional breeds like Chinese ponies (Jie 1995; Zhu et al., 2014). Our data confirm that absolute skull length distinction and skull measurements (cranial length, nasal length, cranial width and zygomatic width) are shorter in Shetland ponies in comparison with the large breed horses and donkeys.

However, the proportions and dimensions of skulls are distinct. It is known that dimensions of the mammalian skull vary proportionally relative to size. Such a pattern is a typical example of allometric changes among closely related species (Bininda-Emonds et al. 2003; Goswami 2006; Porto et al. 2009; Klingenberg 2013). In domesticated taxa, this phenomenon has been described for wolves and dogs (Curth et al. 2017). Lower magnitudes of module integration have been described in feral and domesticated horses as well (Heck et al. 2018). The horse's cranium is composed of six developmental modules. The magnitude of integration in domesticated horse skulls is lower than in wild equids (Heck et al. 2018). Modularity and integration have often been linked to evolution (Goswami, 2006).

Our data provide evidence that such a pattern also occurs in ponies. In contrast to large breed horses, Shetland ponies demonstrated a relatively longer cranium than nasal length, clearly indicated by the cranial length/nasal length quotient in ponies of 1.06 and 0.96 in large breed horses. In three popular equine breeds (Standardbred, Thoroughbred and Arabian), the nasal part is longer relative to the cranial length (Evans & McGreevy, 2006). The proportions of the Shetland pony skulls in our dataset are more similar to Arabian breeds (Evans & McGreevy, 2006) and donkeys (Zhu et al. 2014). The skull of the Shetland ponies was wider, and this being indicated by a skull index of 45.3, greater than that of 34.5 in larger horses (Evans & McGreevy, 2006). Our results show that the skull index is higher, the cranial index is smaller and the nasal index is larger compared with large breed horses (Evans & McGreevy, 2006). It can be derived that horses and donkeys have a longer nasal part than Shetland ponies (Zhu et al., 2014; Froydenlund et al., 2015). Due to the wider head, the nasal index was much higher in the studied pony population (92.57 compared to 66.51 of large breed horses). Also, a significantly greater nasal

**TABLE 2** Mean values of the dorsal and ventral and middle nasal conchae measurements subdivided by 'head side' (modified Liuti et al., 2016) (N = 15)

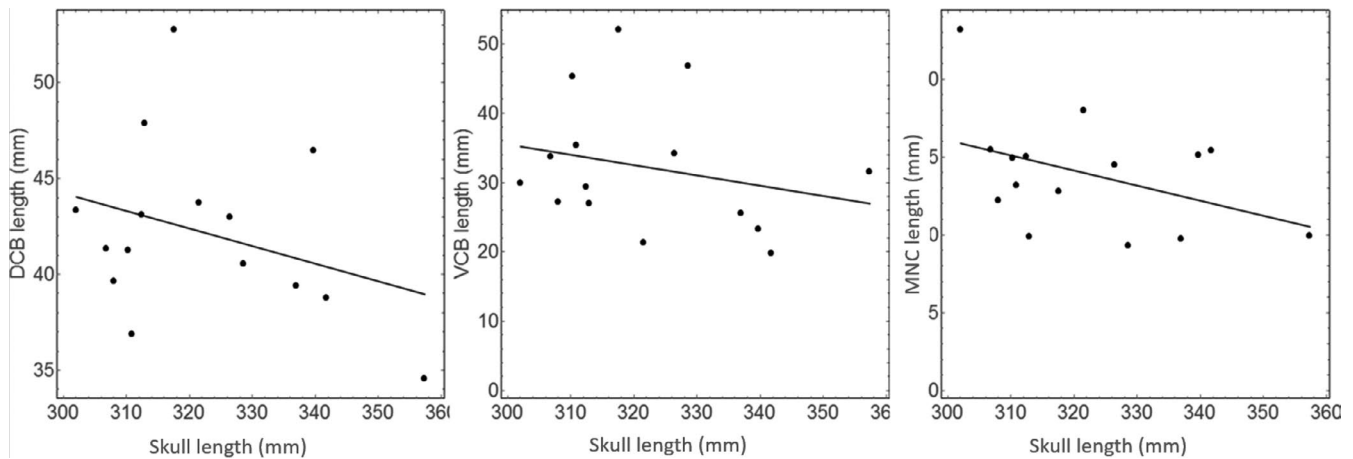
Bullae measurements (mm)	Right mean (Minimal-Maximal)	Left mean (Minimal-Maximal)	Total mean right and left (Minimal-Maximal)	SD	p-value
DCB mean length	43.49 (34.13–54.96)	40.88 (31.22–50.55)	42.18 (34.71–52.76)	4.50	.950
DCB mean width	13.24 (7.43–21.05)	13.63 (7.43–19.25)	13.44 (6.97–21.05)	2.85	.370
DCB mean height	17.96 (11.5–22.01)	18.21 (11.50–22.01)	17.71 (11.97–21.35)	2.64	.164
VCB mean length	31.81 (18.92–50.10)	32.56 (14.94–54.01)	32.18 (19.81–52.06)	9.48	.150
VCB mean width	9.08 (3.89–16.31)	8.65 (4.77–13.35)	8.86 (5.42–13.90)	2.55	.312
VCB mean height	12.43 (5.61–19.79)	12.51 (4.26–20.15)	12.54 (5.97–19.76)	3.15	.636
MNC mean length	14.19 (6.81–25.47)	13.63 (8.73–25.47)	13.91 (9.29–23.18)	3.65	.697
MNC mean width	6.21 (2.64–9.98)	6.98 (3.97–11.69)	6.60 (4.22–9.45)	1.33	.496
MNC mean height	5.98 (3.11–8.10)	6.88 (3.92–10.34)	6.43 (3.89–9.08)	1.49	.964

Abbreviations: DCB, dorsal conchal bulla; mm millimetre; MNC, middle nasal conchae; SD: standard deviation; VCB, ventral conchal bulla.

**TABLE 3** Correlation coefficients between head and bullae length and mean absolute dimensions of the dorsal conchal bulla (DCB) and the ventral conchal bulla (VCB) and the middle nasal concha (MNC) and their adjusted dimensions in relation to the head length from occiput to praemaxilla (Froydenlund et al., 2015) ( $N = 15$ )

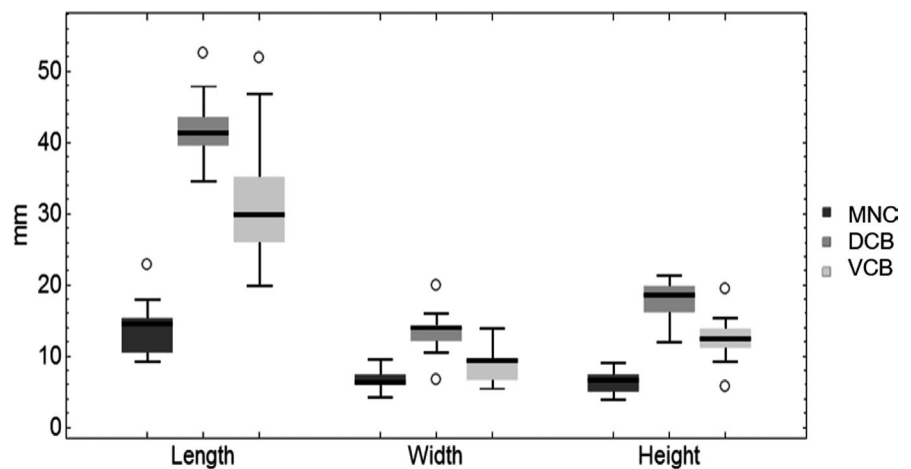
	Correlation coefficient	$p$ -value	Mean of measurements (mm)		Percentage of head length, adjusted measurement (%)	
			Length	Height	Length	Height
DCB	-0.26	.348	42.2	17.7	11.5	4.8
VCB	-0.38	.160	32.2	12.5	8.7	3.4
MNC	-0.10	.732	13.91	6.43		

DCB: dorsal conchal bulla; VCB: ventral conchal bulla, MNC: middle nasal conchae; mm: millimetre.



**FIGURE 2** Scatter plots of lengths of the dorsal (DCB) and the ventral conchal bullae (VCB) and the length of the middle nasal concha (MNC) from left to right depending on the skull length measurement (occiput to praemaxilla, in accordance with Evans & McGreevy 2006) ( $N = 15$ )

**FIGURE 3** Box plots demonstrating ranges of mean length, width and height of the dorsal (DCB), ventral (VCB) conchal bullae and the middle nasal concha (MNC) of adult Shetland ponies ( $N = 15$ ). Central line = median, circles = outliers, whiskers show the minimum and maximum intervals, box = 25/75 percentile



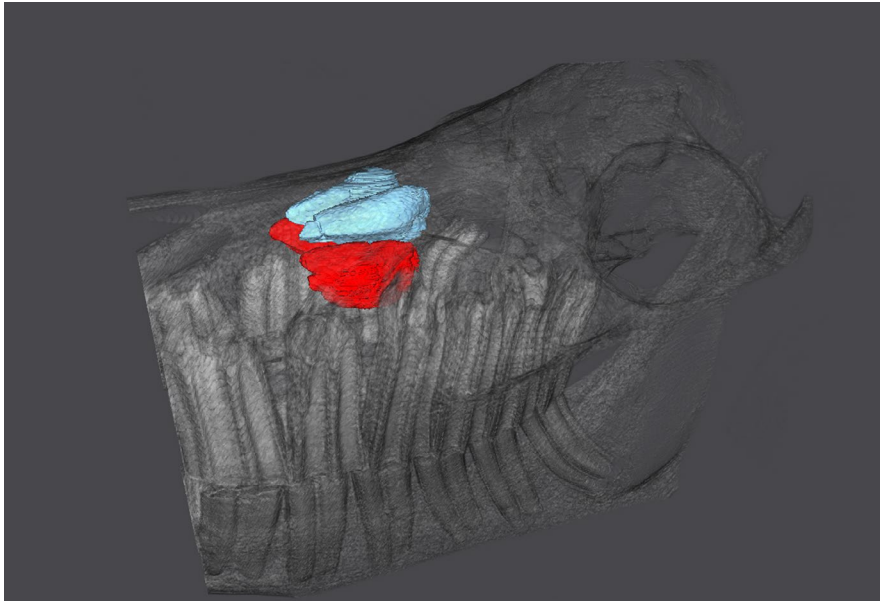
index was shown for Arabians. However, no difference was apparent between Thoroughbreds and Standardbreds (Evans & McGreevy, 2006). Donkeys and Shetland ponies have a shorter but wider skull than larger popular equine breeds (Table 4).

Giavotto and Barakzai (2017) found slight variations in the radiographic appearance of the bullae between horses and pony heads. They assumed different nasal profiles and a 'dome-shaped' head in ponies. Other authors described the nasal length as concave in

smaller breeds of ponies and as straight in larger breeds of ponies (Heck et al., 2018).

#### 4.2 | Limitations of the study

The interpretation of length measurements in the context of literature is limited as lengths may differ due to differently set length



**FIGURE 4** Slightly oblique three-dimensional reconstruction of a two-year-old pony head (14,230). Left is rostral. The nasal dorsal conchal bullae are blue, and the ventral conchal bullae are red

**TABLE 4** Skull indexes of Shetland ponies compared with studies measuring two different skull lengths

	Zhu et al. 2014 Donkeys	Evans & McGreevy 2006 Three popular breeds	Own study Shetland ponies	Jie 1995	
				Horses	Ponies
Skull index 1 (zygomatic width x 100/skull length 1) Skull length 1 = occiput to nasal bone	43.8	34.2	45.3	-	-
Skull index 2 (zygomatic width x 100/skull length 2) Skull length 2 = occiput to praemaxilla	38,2	-	39,6	37,4	38,26

definitions; for example, while Evans and McGreevy (2006) only determined the length up to the Os nasale, other authors measured the rostral aspect of the premaxilla (Froydenlund et al., 2015). To overcome this limitation, we measured both distances in the present study, called skull lengths 1 and 2. Additionally, the findings were not pathologically substantiated. This implies that sinus morphology could not be related to any pathological condition. The adult cohort of the examined ponies provides first evidence for adult ponies only. Nevertheless, the close relationship of the bullae with paranasal sinuses is of clinical importance in different age groups. Indeed, it would be highly promising to conduct sinus morphology research on an ontogenetic series.

### 4.3 | Bullae measurements and correlations of head and bullae

Bullae sizes are generally smaller than in large breed horses as expected. The dorsal bullae are greater than the ventral ones as previously described (Froydenlund et al., 2015; Liuti et al., 2016). The mean rostrocaudal lengths were found to be equivalent to 11.5% and 8.7% of mean head lengths. This is a smaller ratio than in large breed horses with 13.9% and 10.2%, respectively (Froydenlund et al., 2015). While in large breed horses, similar to Thoroughbreds,

the bullae sizes are positively associated with skull length (Liuti et al., 2016), in Shetland ponies, we found a negative correlation. We link such diverging results to the way the skull length measurements were taken. In contrast to Liuti et al., 2016, who defined head length from the caudal aspect of the orbit to the nasoincisive notch, we defined the length from the occiput to the premaxilla. No predefined measurements for the middle nasal conchae are found in the literature.

### 4.4 | Relations of head length and bullae sizes

With increasing skull size, the 15 ponies demonstrated proportionately small bullae. Additionally, the calculated coefficients were not significant in our study. However, this trend can be clearly seen in comparison with the measurements in large breed horses. When comparing our findings with those in the study by Froydenlund et al. (2015), it was noticeable that horses had a 1.5 times larger head in relation to ponies (561 mm versus 367 mm) and almost twice as long bullae compared with Shetland ponies (DCB: 78 mm and VCB: 29 mm versus MW DCB: 42.2 mm and VCB: 17.7 mm, respectively). The length of the bullae decreases with increasing head length due to allometric changes (Bininda-Emonds et al. 2003; Goswami 2006; Porto et al. 2009; Klingenberg 2013).

## 4.5 | Septae

Vertically oriented septae divide the bullae into several cellulae. The median number of septae within the DCB and VCB was not counted by Froydenlund et al. (2015); instead, they counted only the cellulae. Three septae form four cellulae, so that Shetland ponies count one less septum in comparison with larger horses (Froydenlund et al., 2015). Furthermore, Froydenlund et al. (2015) found up to seven cellulae in the DCB. These findings indicate the unique conformation of DCB and VCB in Shetland ponies.

In conclusion, this study suggests that Shetland ponies have distinguishing proportions of the skull not being comparable to the head and skull dimensions of large breed horses. Shetland ponies are characterized by a shorter nasal length and wider heads. These dimensions have now been evaluated in a larger number of ponies for the first time.

The CT examination proved suitable for comparing the size and relationship of the nasal bullae with the skull length.

Based on our study, we suppose that our results provide information on physiological head morphology. Determining the relationship of the nasal bulla to the sinus as well as the size of the openings may be relevant for further clinical applications. Also, as specific head dimensions in Shetland ponies differ from those of large breed horses, the necessity to adapt diagnostic instruments and therapeutic concepts to treat paranasal sinus diseases in Shetland ponies is warranted. Finally, to assure comparability in future studies, consistent measurements in anatomical studies are required.

### ACKNOWLEDGEMENTS

This project was partly funded by the Max Planck Weizmann Center for Integrative Archaeology and Anthropology (Track Leader Kornelius Kupczik, Max Planck Institute for Evolutionary Anthropology, Leipzig, Germany). We highly appreciate the continuous support given by Linda Schuchardt (MPWC), Julia Stuhlträger (MPWC), Sabine Kleemann (IAND), Dominique Blaue (IAND) and Carola Schedelbauer (IAND) in animal caretaking and pony handling.

### CONFLICT OF INTEREST

There are no actual or potential conflicts of interest.

### AUTHOR CONTRIBUTIONS

The study was designed and equally performed by the authors in all steps.

### ETHICS STATEMENT

This research was approved by the Ethics Committee for Animal Rights Protection of the Leipzig District Government (No. TVV 05/15 and 32/15) in accordance with German legislation on Animal Rights and Welfare.

### DATA AVAILABILITY STATEMENT

Raw data were generated at the Veterinary Teaching Hospital, Department for Horses, Faculty of Veterinary Medicine, University

of Leipzig, Leipzig, Germany. Derived data supporting the findings of this study are available from the corresponding author on request.

### ORCID

Kerstin Gerlach  <https://orcid.org/0000-0001-8802-7117>

Dagmar Berner  <https://orcid.org/0000-0001-6442-3449>

Ellen Schulz-Kornas  <https://orcid.org/0000-0003-1657-8256>

### REFERENCES

- Bininda-Emonds, O. R. P., Jeffrey, J. E., & Richardson, M. K. (2003). Is sequence heterochrony an important evolutionary mechanism in mammals? *Journal of Mammalian Evolution*, 10, 335–361. <https://doi.org/10.1023/B:JOMM.0000019775.39109.d2>
- Brinkschulte, M., Bienert-Zeit, A., Lüpke, M., Hellige, M., Ohnesorge, B., & Staszkyk, C. (2014). The sinonasal communication in the horse. Examinations using computerized three-dimensional reformatting renderings of computed-tomography datasets. *BMC Veterinary Research*, 10(72), 72–82. <https://doi.org/10.1186/1746-6148-10-72>
- Curth, S., Fischer, M. S., & Kupczik, K. (2017). Patterns of integration in the canine skull: An inside view into the relationship of the skull modules of domestic dogs and wolves. *Zoology*, 125, 1–9. <https://doi.org/10.1016/j.zool.2017.06.002>
- Dixon, P. M., Froydenlund, T., Luiti, T., Kane-Smyth, J., Horbal, A., & Reardon, R. J. M. (2015). Empyema of the nasal conchal bulla as a cause of chronic unilateral nasal discharge in the horse. 10 cases (2013–2014). *Equine Veterinary Journal*, 47(4), 445–449. <https://doi.org/10.1111/evj.12322>
- Dixon, P. M., Parkin, T. D., Collins, N., Hawkes, C., Townsend, N., Tremaine, W. H., Fisher, G., Ealey, R., & Barakzai, S. Z. (2012). Equine paranasal sinus disease: A long-term study of 200 cases (1997–2009): Ancillary diagnostic findings and involvement of the various sinus compartments. *Equine Veterinary Journal*, 44(3), 267–271. <https://doi.org/10.1111/j.2042-3306.2011.00420.x>
- Evans, K. E., & McGreevy, P. D. (2006). Conformation of the equine skull. A morphometric study. *Anatomia, Histologia, Embryologia*, 35(4), 221–227. <https://doi.org/10.1111/j.1439-0264.2005.00663.x>
- Finnegan, C. M., Townsend, N. B., Barnett, T. P., & Barakzai, S. Z. (2011). Radiographic identification of the equine ventral conchal bulla. *The Veterinary Record*, 169(26), 683–689. <https://doi.org/10.1136/vr.100112>
- Froydenlund, T. J., Dixon, P. M., Smith, S. H., & Reardon, R. J. M. (2015). Anatomical and histological study of the dorsal and ventral nasal conchal bullae in normal horses. *The Veterinary Record*, 177(21), 542–547. <https://doi.org/10.1136/vr.103408>
- Giavotto, A. E., & Barakzai, S. Z. (2017). Radiographic identification of the equine dorsal and ventral nasal conchal bullae. *Equine Veterinary Education*, 31(5), 264–270. <https://doi.org/10.1111/eve.12788>
- Goswami, A. (2006). Cranial Modularity Shifts during Mammalian Evolution. *The American Naturalist*, 168(2), 270–280. <https://doi.org/10.1086/505758>
- Heck, L., Wilson, A. B., Evin, A., Stange, M., & Sánchez-Villagra, M. R. (2018). Shape variation and modularity of skull and teeth in domesticated horses and wild equids. *Frontiers in Zoology*, 15(14), 14–27. <https://doi.org/10.1186/s12983-018-0258-9>
- Jie, D. W. (1995). The compare research of the skull of the pony and the horse in Yunnan. *Yunnan Journal of Animal Science and Veterinary Medicine*, 23(1), 22–25.
- Klingenberg, C. P. (2013). Cranial integration and modularity: Insights into evolution and development from morphometric data. *Hystrix, the Italian Journal of Mammalogy*, 24(1), 43–58. <https://doi.org/10.4404/hystrix-24.1-6367>
- Liuti, T., Reardon, R., Smith, S., & Dixon, P. M. (2016). An anatomical study of the dorsal and ventral nasal conchal bullae in normal horses.

- Computed tomographic anatomical and morphometric findings. *Equine Veterinary Journal*, 48(6), 749–755. <https://doi.org/10.1111/evj.12516>
- Porto, A., de Oliveira, F. B., Shirai, L. T., De Conto, V., & Marroig, G. (2009). The Evolution of Modularity in the Mammalian Skull I: Morphological Integration Patterns and Magnitudes. *Evolutionary Biology*, 36, 118–135. <https://doi.org/10.1007/s11692-008-9038-3>
- Tatarniuk, D. M., Bell, C., & Carmalt, J. L. (2010). A description of the relationship between the nasomaxillary aperture and the paranasal sinus system of horses. *Veterinary Journal*, 186(2), 216–220. <https://doi.org/10.1016/j.tvjl.2009.07.023>
- Zhu, L., Shi, X. D., Wang, J. J., & Chen, J. G. (2014). A Morphometric Study on the Skull of Donkey (*Equus asinus*). *International Journal of Morphology*, 32(4), 1306–1310. <https://doi.org/10.4067/S0717-95022014000400030>

**How to cite this article:** Gerlach K, Vervuert I, Gittel C, et al. An anatomical study of the dorsal and ventral nasal conchal bullae and middle nasal conchae in normal Shetland ponies: Computed tomographic anatomical and morphometric findings. *Anat Histol Embryol*. 2021;50:431–438. <https://doi.org/10.1111/ahe.12646>