

## REVIEW

# Nailfold capillaroscopy : a comprehensive review on common findings and clinical usefulness in non-rheumatic disease

Natalia Mansueto, Cinzia Rotondo, Addolorata Corrado, and Francesco Paolo Cantatore

*Department of Medical and Surgical Sciences - Rheumatology Unit, University of Foggia, Italy*

**Abstract :** Nailfold video-capillaroscopy (NVC) is a useful diagnostic tool, used to early detect abnormalities in micro-circulation, providing a qualitative description of microvascular anomalies in Raynaud's phenomenon. NVC role in the diagnosis of Systemic Sclerosis is well known. In other rheumatic conditions such as connective tissue diseases, vasculitis, and arthritis, the NVC anomalies are often included in a scleroderma like pattern. The use of NVC in non-rheumatic diseases (NRD), with remarkable microvascular damage, as diabetes, is not standardized yet, although several research studies are carrying on. The aim of this article is to provide a resume of published results in order to lay the groundwork for the employment of NVC both in the diagnosis and follow up of microvascular complication in NRD. Furthermore, we mention NVC findings in pathologies without well recognize microvascular damages in their pathogenesis : micro-vessels abnormalities may suggest a different point of view. *J. Med. Invest.* 68 : 6-14, February, 2021

**Keywords :** nailfold videocapillaroscopy, microcirculation, Raynaud's phenomenon, diabetes, glaucoma

## INTRODUCTION

Nailfold video-capillaroscopy (NVC) is a non-invasive diagnostic test used to study microvascular abnormalities, predominantly, in many rheumatological disorders, as connective tissue diseases (CTD). In particular, in systemic sclerosis (SSc), NVC allows detection of pathognomonic microvascular alterations and their activity phases, clustered in specific scleroderma patterns (early, active, and late) (1). The importance of NVC in SSc is evidenced by the inclusion of NVC scleroderma patterns among items in the new 2013 classification criteria for SSc. In addition, NVC is now considered a key finding in the very early stage of disease, in the clinical assessment and in the treatment management (2). In other CTD, as systemic lupus erythematosus, inflammatory myositis, undifferentiated connective tissue diseases and mixed connective tissue disease, although non-specific, the NVC patterns can provide a valid support for the diagnosis (3). This useful tool reproduces in vivo amplified images of skin microcirculation. NVC is a simple and reproducible test that can be assessed both in adults and in children (4). Moreover, NVC is used in diagnosis and follow-up of Raynaud's phenomenon (RP), an intense vasospasm of the small arteries, characterized by three phases, as ischemia, cyanosis and reperfusion (5). There are two different types of RP : primary RP (PRP), that does not underlie a pathology, and secondary RP (SRP) that is considered an early manifestation of a CTD, e.g. SSc. In patients with RP, NVC and other non-invasive methods, as laser techniques, may supplement clinical examination and provides a more accurately differential diagnosis that guide the correct treatment both in PRP than in SRP (6, 7). Furthermore, NVC

may be used to assess the effectiveness of pharmacological therapies (vasoactive drug and/or immunosuppressive treatments) in RP patients (8-11). The utility of NVC in non-rheumatic disease (NRD) is not well studied. Various diseases cause microvascular damage, that can be detected by using capillaroscopy. NVC allows to evaluate the measurements of individual capillaries (length, shape, and diameter of each capillary loop, the number of capillaries) and the dynamic parameters (blood flow velocity, using a software program) (12). Even if abnormal NVC findings are observed in up to 10% of healthy subjects, it has been observed that in SSc patients NVC features mirror microvascular changes, which play crucial roles in disease pathophysiology, and correlate with SSc duration and peculiar autoantibody profiles (13). SSc microvascular changes are due to endothelial cell dysfunction leading to their transition in to active myofibroblast, overproduction of vasoconstrictors (as endothelin 1), and decrease of serum levels vasodilators (as nitric oxide) (14). The sustained impairment of the microvascular tone causes opening of the endothelial junctions with the increase of micro-vessels permeability and progressive microvascular leak, inducing microhemorrhages and local edema in SSc patients (15). Microhemorrhages represent the consequence of capillaries loops damage, appearing frequently in the early stage of microvascular disease, and representing the 'bridge' between the presence of giant capillaries and desertification (16) (Fig.1).

Ectasia and giant capillaries, representing the early stage of peripheral microangiopathy and the initial response to aberrant perfusion, should be considered as the "red flags" for CTD not yet detected (17) (Fig. 2).

Tissue hypoxia, due to vessels abnormalities and poor blood

### List of abbreviation

AA = alopecia aerata, CTD = connective tissue disease, DM = diabetes mellitus, DR = diabetic retinopathy, HC = healthy control, HHT = hereditary hemorrhagic telangiectasia, HTG = high tension glaucoma, ILD = interstitial lung disease, IOP = intraocular pressure, KD = Kindler syndrome, NRD = non rheumatic disease, NTG = normal tension glaucoma, NVC = nailfold video-capillaroscopy, PAH = pulmonary arterial hypertension, POAG = primary open angle glaucoma, RA = rheumatoid arthritis, SCD = sickle cell disease, SH = systemic hypertension, SSc = systemic sclerosis, XFS = exfoliating syndrome

Received for publication March 24, 2020 ; accepted December 7, 2020.

Address correspondence and reprint requests to Natalia Mansueto, MD, Department of Medical and Surgical Sciences - Rheumatology Unit, University of Foggia, Italy, Ospedali Riuniti, Foggia viale Luigi Pinto 1, 71122, Italy.

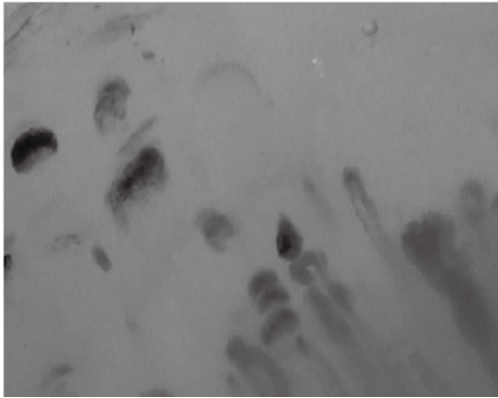


Figure 1. Nailbed hemorrhages (150x magnification ; HORUS videodermatoscope)

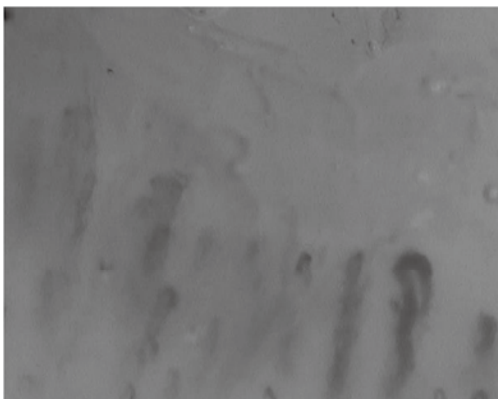


Figure 2. Enlarged capillary (150x magnification ; HORUS videodermatoscope)

flow, is a potent booster of vascular endothelial grow factor (VEGF), which has been shown to induce the formation of chaotic vessels, called neo-angiogenesis, and evidenced at NVC as meandering loop or bushy and branched capillaries organized in clusters (18). Tissue's chronic hypoxia led to irreversible microangiopathy, which is characterized at NVC by the presence of avascular areas, hallmarks of long-standing SSc disease and predictors of poor prognosis (19). Although some findings, such as tortuosity and elongated loops, are not included in "scleroderma pattern", it is interesting to find out why they appear in normal and pathological conditions (Fig. 3).

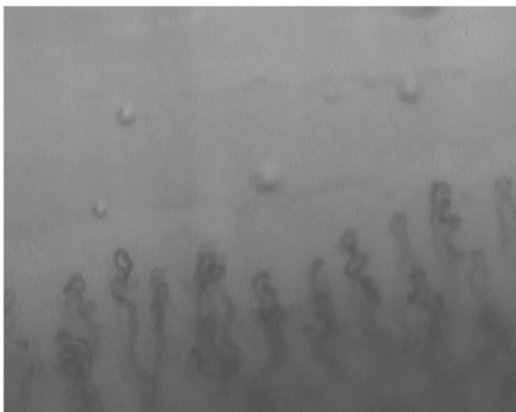


Figure 3. Tortuous capillaries (150x magnification ; HORUS videodermatoscope)

Tortuosity is not considered as a pathological feature, even if individual's capillaries have a tendency to become tortuous and dilated with age (20). Elongated loops are found in different pathologies, and seem to be more common in patients with rheumatoid arthritis (RA), not overlap with CTD (21). The reason why this finding were often found in RA is still unclear, even if it can be considered as an aspect of inter-individual variability (22). In this review we examine the most particular NVC findings in NRD, characterized by the involvement of microcirculation in their pathogenesis.

## METHOD

An extensive research was performed using PUBMED and GOOGLE SCHOLAR databases to identify studies. All studied published between 1990 and 2019 were included. The following "Key words" were used : "nailfold videocapillaroscopy" ; "micro-circulation" ; "microvascular damage". At this stage we considered the pathologies mentioned in more than one paper, and we directed literature research adding the most common pathologies to the keywords previous mentioned. We also included in our research the studies regarding rare pathologies, even if we found one single paper. For each key word we added : "and diabetes", "and glaucoma", "and sickle cell disease", "and dermatology disease", "and interstitial lung disease", "and pulmonary arterial hypertension", "and hereditary disorders", "and Alzheimer disease", "and psychiatric diseases". The research included studies covering all the NRD in which nailfold capillaroscopy was performed. Manual searching of references from potentially relevant articles was undertaken in order to include additional studies. Conference abstracts and texts not in English were excluded. In this revision were identified 41 papers that respected the inclusion and exclusion criteria selected. These were divided into different groups belonging to a specific medical branch or pathology, as diabetes, glaucoma, sickle cell disease, dermatology, cardiopulmonary, miscellaneous. In table 1 are described NVC abnormal findings in NRD in study and in SSc. Table 2 summarized all NVC findings in the key papers included in this review, relating to NVC fields of application.

## NAILFOLD CAPILLAROSCOPY IN DIABETES

Diabetes mellitus (DM) is a chronic endocrinopathy, defined as hyperglycemic condition, complicated by microvascular structural changes, as diabetic retinopathy (DR), nephropathy and neuropathy. These are worldwide recognized as the leading causes of mortality and morbidity. DR is the most common microvascular complication of DM, and it is considered the most frequent cause of preventable blindness. Endothelial dysfunction plays an important role in the development of microvascular damage in the DM earliest stage. Many diagnostic tools are used to assess microvascular damage, but the NVC is not widely used for this purpose. Bakirci S *et al.* performed NVC in 64 patients with DM type 2 to investigate whether the use of NVC could predict the outcome of DR as microvascular complication. No findings reached statistical significance, when patients with and without retinopathy were compared in term of NVC parameters, even if the rate of patients with tortuous capillaries, bleeding area, dilated and giant capillaries, and neo-angiogenesis was higher in the DR-positive group (23). Kuryliszyn-Moskal A *et al.* found that patients with type 1 DM, compared with healthy subjects, showed higher number of dilated and tortuous capillaries, and increased capillary density. Furthermore, patients with poor metabolic control had more capillaroscopic abnormalities (24).

**Table 1.** Main nailfold capillaroscopic findings in most common diseases.

	SSc	diabetes	glaucoma	dermatology	SCD	ILD	i-PAH	AD	RS
Tortuosity	V	V	V	V	-	-	-	V	-
Elongation	-	-	-	V	-	-	-	-	-
Ectasia	V	V	V	-	V	-	V	-	V
Hemorrhages	V	V	V	-	-	-	-	-	-
Avascular area	V	V	V	-	V	V	-	-	-
Angiogenesis	V	V	-	V	-	V	-	-	V
Giant capillaries	V	V	-	-	-	-	-	-	-

AD : Alzheimer disease ; ILD : interstitial lung disease ; i-PAH : idiopathic pulmonary hypertension ; RS : Rett syndrome ; SCD : sickle cell disease ; SSc : Systemic sclerosis ; V : yes.

**Table 2.** Common findings in nailfold-videocapillaroscopy in different fields of application.

Field of application	Works	Study group patients	Nailfold capillaroscopy findings
Diabetes	Bakirci S <i>et al.</i> (2018), Chang GH <i>et al.</i> (1997)	DR	Tortuosity, hemorrhages and neoangiogenesis
	Kurilla-Szym-Moskalet A <i>et al.</i> (2011)	DM type 1 vs HC	Ectasia and tortuosity
	Meyer MF <i>et al.</i> (2001)	DM vs HC	More abnormalities
	Barchetta I <i>et al.</i> (2011)	DM	Capillary ectasia and edema
	Lisco G <i>et al.</i> (2018)	DM vs HC	Tortuosity, avascular areas, capillaries with bizarre shape
Ophthalmology	Bozic M <i>et al.</i> (2010)	NTG vs HTG	More spirally formed capillaries
	Cousin CC <i>et al.</i> (2017)	XFS vs HC	High degree of tortuosity
	Philips S <i>et al.</i> (2019)	XFS vs HC	Limited range of resting peripheral blood flow
	Pasquale LR <i>et al.</i> (2015)	POAG vs HC	Ectasia, avascular areas and hemorrhages
	Kosior Jareka E <i>et al.</i> (2018)	NTG vs HC	Ectasia, bushy capillaries
	Park HY <i>et al.</i> (2011)	glaucoma	Relationship between nailfold hemorrhages and optic disc hemorrhages
	Gasser P <i>et al.</i> (1991)	NTG vs HC	Reduction of capillary blood flow
	Gomes BF <i>et al.</i> (2018)	SSc with Glaucoma vs SSc without glaucoma	No significant association between glaucoma diagnosis and capillaroscopic pattern
Hematology	Sapozhnikov M <i>et al.</i> (2019)	SCD vs HC	Lower capillaries number, dilated capillaries, more crossing type capillaries
Dermatology	Kamińska-Winciorek GM <i>et al.</i> (2006)	Rosacea	Meandering capillaries, elongation, angiogenesis
	Gerkowicz A <i>et al.</i> (2013)	AA	Branching capillaries, elongated loops, tortuosity
	Ganzetti G <i>et al.</i> (2011)	AA	Increase of new vessels and reduction of capillary loss after treatment
	Lima AS <i>et al.</i> (2016)	Leprosy	Bushy capillaries, ectasia
Cardiopulmonary	Corrado A <i>et al.</i> (2010)	ILD vs COPD	Reduction of capillary density, neo-angiogenesis
	Corrado A <i>et al.</i> (2017)	iPAH vs HC	Lower capillary density
	Penna GL <i>et al.</i> (2008)	SH	Lower blood flow velocity
	James MA <i>et al.</i> (2006)	SH	Higher capillary pressure
	Cheng C <i>et al.</i> (2013)	SH	Lower values of percent capillary recruitment
	Junqueira CLC <i>et al.</i> (2018)	SH vs HC	No differences
Miscellaneous	Aschwanden M <i>et al.</i> (2011)	GVHD vs HC	No differences
	Akay BN <i>et al.</i> (2010)	sGVHD vs lGVHD	neovascularization, hemorrhages, enlarged capillaries, avascular areas
	Dobrev HP <i>et al.</i> (2015)	Kindler syndrome	Reduction of capillary density, branched capillaries, giant capillaries
	Pasculli G <i>et al.</i> (2005)	HHT	Mega-capillaries
	Ingegnoli F <i>et al.</i> (2017)	Progeria	'scleroderma like' pattern
	Bianciardi G <i>et al.</i> (2013)	Rett syndrome	Branched capillaries, microvascular disorganization
	Cousin CC <i>et al.</i> (2018)	MCI vs HC	High degree of tortuosity
	De Martinis M <i>et al.</i> (2018)	Anorexia nervosa	Early scleroderma pattern
	Vuchetic JP <i>et al.</i> (2008)	Schizophrenia	High plexus visibility

AA : alopecia areata ; COPD : chronic obstructive pulmonary disease ; DM : diabetes mellitus ; DR : diabetic retinopathy, GHDV : graft versus host disease ; lGVHD : lichenoid graft versus host disease ; sGHDV : sclerodermoid graft versus host disease ; HC : healthy control ; HHT : hereditary hemorrhagic telangiectasia ; SH : systemic hypertension ; ILD : interstitial lung disease ; iPAH : idiopathic pulmonary arterial hypertension ; MCI : mild cognitive impairment ; NVC : nailfold videocapillaroscopy ; SCD : sickle cell disease.

Meyer MF *et al.* put in relationship capillaroscopic changes (as increased diameter, tortuosity, reduction in capillary number) in patients with DM (25). Barchetta *et al.* correlated microangiopathic lesions in the retinal vessels and changes in NVC finding, in patients with type 1 DM and those with type 2 DM, a healthy control group (HC) was included. They reported that patients with DM had capillary ectasia and nailfold edema compared to HC (26). In another study, the relation between microangiopathy, evaluated by ophthalmoscopy, and the presence of bushy capillaries and avascular areas at NVC was observed in DM patients (27). Chang CH *et al.* reported a correlation between DR and capillary abnormalities as tortuous capillaries, bushy capillaries and capillary enlargement; moreover these capillary changes were more common in patients with severe DM (28). Lisco G *et al.*, in their cross sectional and single-center study, examined by means of the NVC the prevalence of capillaroscopic patterns in both type 1 and type 2 DM; in addition they assessed the relationship between NVC abnormalities, level of glycemic control, and the presence of DM complication or DM comorbidities. In this study, NVC alterations, including tortuosity, ectasias, avascular areas, and capillaries with bizarre shapes were found to be more prevalent in DM patients than in HC. No additional differences in NVC abnormalities (such as bleeding, visibility of venous subpapillary plexus, and rarefaction areas) were found between diabetics and HC. Composite NVC patterns, defined as the presence of at least two DM nailfold alterations, were observed in both groups of patients with microvascular complication (such as retinopathy), and those with DM comorbidity (such as hypertension, dyslipidemia, and carotid atherosclerosis). All these findings suggest the existence of a “diabetic capillaropathy”, as described in several studies (26, 29, 30), suggesting a possible use of NVC to detect and predict DM related microvascular complications (31).

## NAILFOLD CAPILLAROSCOPY IN GLAUCOMA

Glaucoma is a severe ocular disease that causes progressive visual field loss due to the damage of ganglion retinal cells. The most common type of glaucoma is the primary open angle glaucoma (POAG), categorized in high-tension glaucoma (HTG) and normal-tension glaucoma (NTG) (32). Bozic M *et al.*, conducted a pilot study on the utility of NVC in NTG patients and HTG patients. Ophthalmologic examination and NVC were performed on 30 NTG patients and 30 HTG patients. NVC parameters evaluated in the study were capillary row density, capillary diameter, number of spiralized capillaries, permeability of the loops, and loop resistance. The number of spiraled capillaries was more intensively found in NTG patients. According to this finding, the authors hypothesized a possible role of microvascular damage in patients with glaucoma, especially in cases where intraocular pressure was not directly involved in nerve damage (33). Exfoliating syndrome (XFS) consists of production and deposition of fibrillar granular materials that may produce elevate intraocular pressure (IOP), optic nerve damage, and glaucoma. Cousin CC *et al.* studied nailfold capillaries morphology in XFS, founding a higher degree of tortuosity in XFS patients than in HC, although the clinical consequences in ocular microvasculature is unclear (34).

Philips S *et al.*, in their cross-sectional and clinic-based study, performed NVC in 111 participants, 30 with NTG, 30 with HTG, 30 with XFS and 21 HC. The aim of their study was to examine peripheral resting blood flow in patients with glaucoma, observing plasma gap blood movement in capillaries. They found a lower and limited range of resting peripheral blood flow in patients with XFS compared to HC. This limited range may

represent stiffened vasculature or impaired maximal flow in peripheral vasculature of XFS patients (35). Pasquale LR *et al.*, in their multicentric study, enrolled 199 patients with POAG and 124 HC. The NVC was performed on the fourth and the fifth finger of each subject's non dominant hand. The presence of hemorrhages, dilated capillary loops, and avascular areas were evaluated by NVC; data on demographic factors, family history of glaucoma, systemic disease and related were collected. They found that all capillary abnormalities, as dilated capillary loops, avascular zones, and hemorrhages were associated with POAG, but the number of this abnormalities was not associated with the severity of the disease. Just a positive correlation between the hemorrhages number and visual field loss severity was observed. These data support the hypothesis of extra-ocular capillary involvements in POAG patients (36). Kosior-Jarecka E *et al.* focused their attention on NTG patients. NVC was performed in 80 NTG patients and in 2 HC groups (58 young healthy and 50 age-matched volunteers). They observed that abnormal NVC pattern was more common in NTG than in young controls. Micro-bleedings were the most common findings in NTG patients. Dilated capillary loops and branching capillaries were more frequent in NTG patients than in age-matched HC. They also found an association between NVC abnormalities and disc hemorrhages and paracentral scotoma in glaucoma (37). Previously, Park HY *et al.* suggested that nailfold hemorrhages could be a marker of optic disc hemorrhages in patients with glaucoma. Furthermore, disc hemorrhages were also associated with nailfold capillaries loss, even if the association was stronger with nailfold hemorrhages. No more differences were found in NTG patients and POAG (38). Gasser P *et al.* evaluated blood flow velocity, a dynamic parameter, in 30 NTG patients, 30 HTG patients and 30 HC. Capillary blood flow velocity was significantly reduced in NTG patients. After cold provocation, 25 of 30 NTG patients, had a measurable blood standstill of more than 12 second, while only three of 30 HC had a measurable blood standstill. No morphological parameters showed significantly differences between the studied groups (39). These findings suggest the role of microvascular abnormalities in NTG patients, that could play an independent role in the pathogenesis of the disease. An interesting study, conducted by Gomes BF *et al.*, investigated the possible association between glaucoma and NVC pattern in 30 SSc patients. Up to 23% of SSc patients had glaucoma. No differences in NVC patterns were found between patients with and without glaucoma. Furthermore, no differences regarding intraocular pressure were found in patients with different severity of NVC patterns. The presence of glaucoma did not interfere with NVC pattern. The high prevalence of glaucoma in SSc patients, may suggest a possible role of systemic vascular damage in the pathogenesis of the disease (40).

## NAILFOLD CAPILLAROSCOPIC FINDING IN HEMATOLOGICAL DISEASE : SICKLE CELL DISEASE

Sickle cell disease (SCD) is a disorder characterized by repetitive vaso-occlusive crises causing microvascular obstruction, tissue ischemia and pain, with consequent chronic multi-organ ischemic sequelae. Sapozhnikov M *et al.* performed NVC in 71 SCD patients and 70 age matched HC. Capillary number was lower and the final capillary score (measure of capillary dropout inversely related to capillary density) was higher in the SCD group compared to HC. SCD group had a higher percentage of crossing type capillaries. On multivariate linear analyses, final capillary score was independently associated with SCD after adjusting for age, body mass index, and gender. Furthermore, SCD was associated with more dilated capillaries and lower capillary

density, but the similar number of hemorrhages. These changes appear unrelated to disease severity, frequency of sickle crises, and number of transfusions (41).

## NAILFOLD CAPILLAROSCOPY IN DERMATOLOGY : ROSACEA, ALOPECIA AREATA, AND LEPROSY

Rosacea is an inflammatory dermatosis with a reported prevalence of at least 10% in Caucasian adults. It affects facial skin causing facial erythema and/or papulopustular skin lesions. Kamińska-Winciorek GM *et al.* examined microcirculation by NVC in 16 female patients with rosacea. In this study, NVC abnormalities were found in all patients, in particular, meandering capillaries, elongations, and an increased number of capillaries were described. In the rosacea group, abnormalities of the color of the visual area were found in 14 cases (88%) with indistinct field of vision in 3 cases (19%). This result may suggest a possible use of NVC as diagnostic tool for the study of microvasculature architecture in rosacea (42).

Gerkowicz A *et al.* performed NVC in patients with alopecia areata (AA), a T-cell mediate autoimmune disease that leads to partial or total hair loss of scalp and body hair. Other AA clinical features include nail changes. Tortuous loops were the most common findings in patients with AA. In these patients, single tortuous loop was more frequent than multiple tortuous loops. Branching capillaries and features of neovascularization were frequently observed. None of the patients had an extremely elongated loop. These results confirmed the presence of two types of NVC images in patients with AA : in the first type, there were no abnormalities ; in the second type there were anomalies such as branching capillaries, dilated loops, and tortuosity. No differences among patients with different type of AA were found. Nail changes were not related with NVC findings. NVC abnormalities in these patients suggest a possible role of skin microcirculation dysfunction in patients with AA (43). Ganzetti G *et al.* performed NVC before and after dyphenilcyclopropenone treatment in AA patient. At 24 weeks, it was observed an increase of new vessels and a significant hair regrowth in the areas with more marked angiogenesis. A possible role of nailfold capillaroscopy in the follow up of alopecia before and after treatment it was suggested (44).

A study about NVC alterations in patients with Hansen's bacilli was carried out in order to investigate abnormalities in patients with leprosy and their relationship with clinical parameters. In this research, 60% of patients had some NVC abnormalities, such as micro-hemorrhages, dilated, bushy and corkscrew capillaries, although these changes were not specific for the disease manifestations. However, a large number of evidences marked the role of the interaction of Hansen's bacilli with endothelium in pathogenesis of the disease (45).

## NAILFOLD CAPILLAROSCOPIC FINDINGS IN CARDIOPULMONARY DISEASE

The role of NVC in the identification of SSc patients with an higher risk of the organ involvements, is well known and studied (19, 46, 47). Cardiopulmonary diseases, such as interstitial lung disease (ILD) and pulmonary arterial hypertension (PAH) are heterogeneous pathological conditions, frequently associated with SSc, although the idiopathic form is more severe and life-threatening. NVC is a simple and non-invasive tool that allows the early detection of local microvascular changes in CTD ; so, it was used to evaluate the possible presence of different NVC patterns among patients with cardiopulmonary diseases, both

idiopathic form and CTD related form. Different studies state the comparison between capillaroscopic findings in SSc patients with and without ILD (48, 49), suggesting a possible role of NVC in the early detection of lung involvement in CTD (50).

Patients with ILD often present lower capillary density and higher quantity of bushy/ramified capillaries (51, 52), while the presence of giant capillaries may be associated with reduced capacity of the lung for carbon monoxide (53). These data may support the hypothesis of a prognostic role for NVC, and a ILD physiopathology mechanism based on vascular damage (52). Corrado A *et al.* compared NVC findings in patients with idiopathic ILD and patients with SSc related disease (SSc-ILD). In this study, NVC was performed on 23 SSc-ILD, 20 patients with idiopathic ILD and 22 patients with chronic obstructive pulmonary disease to evidence the abnormalities among the groups. For each patient were evaluated : density of capillaries, capillary width, capillary length, presence of microhemorrhages and angiogenetic aspect, such as branched capillaries and avascular areas. The main findings of the study were the detection of minor capillaroscopic alterations in patients with idiopathic ILD compared to SSc-ILD patients. The density of capillaries was significant reduced, and neo-angiogenetic aspects were more diffused in idiopathic ILD patients than in patients with chronic obstructive pulmonary disease, matched for age, arterial oxygen saturation, and diffusing capacity of the lung for carbon monoxide (DLCO) values. These findings confirm the role of vascular damage in the ILD pathogenesis and put the accent on the role of NVC as a useful tool to diagnose CTD in patients that have lung's involvement as the onset manifestation (54).

As regards the patients with systemic hypertension (SH), most of the changes in peripheral resistance affect the microvascular network, and the functional characteristics of arterioles. Microvascular rarefaction has also been described in the early stages of SH. These findings had led to hypothesize that the microvascular network is not only one of the putative factors responsible for increased pressure but is also a key target of SH (55). To evaluate if capillary rarefaction persists despite treatment with angiotensin converting enzyme inhibitors, thiazide diuretics and/or beta-blockers, Penna GL *et al.* performed NVC in 28 well-controlled essential SH patients and 19 normotensive subjects, evaluating the functional capillary densities at baseline, during post-occlusive hyperemia and after venous congestion. SH patients showed lower mean functional capillary density at baseline, during post-occlusive reactive hyperemia, and during venous congestion responses. Mean capillary diameters were not different in SH group, but their red blood cell velocity at baseline was significantly lower. Regardless of the type of therapy used, SH patients showed microvascular abnormalities that reflect the increased of vascular resistance, a clinical feature of SH (56). It has not been fully clarified the difference between a common microcirculation aging process and micro-vessels abnormalities induced by SH in the elderly. James MA *et al.* studied capillary pressure, density, and skin microvascular function in elderly subjects (aged > 60 years) with untreated hypertension, elderly normotensive subjects, and young normotensive subjects. Capillary pressure was higher in both elderly groups compared with young normotensives, but capillary density did not differ among the three groups (57). Even Cheng C *et al.* evaluated the role of microvascular abnormalities in the pathogenesis of SH, validating the NVC, comparing its findings with forearm blood flow, a well-established measure of vascular function. In their study, typical values for capillary counts (capillaries/mm<sup>2</sup>) have been 55-80 for baseline, 65-90 for post-ischemic, and 90-105 for venous occlusion. Values for percent capillary recruitment, a new parameter introduced by Cheng C. *et al.* in order to enable direct comparison of the total number of actively perfused

(functional) capillaries between individuals, were lower among hypertensive than normotensive patients (58). Junqueira CLC *et al.* evaluated microcirculation by NVC in patients with resistant, or mild-to-moderate hypertension compared to normotensive patients. Functional capillary density (the number of capillaries with flowing red blood cells by unit tissue area) and capillary diameters showed no significant differences among the three groups (59).

PAH is a group of diseases characterized by elevated pulmonary arterial resistance leading to right heart failure. Both idiopathic form and secondary form (usually related to CTD and SSc) are described. Corrado A *et al.* in a recent study, compared capillaroscopic abnormalities in patients with idiopathic PAH and those with PAH secondary to SSc (SSc-PAH). In this study the presence of NVC anomalies were found in 38% of idiopathic PAH subjects, in particular, the capillary density was significantly lower in patients with idiopathic PAH than in HC. Furthermore, idiopathic PAH patients had a higher capillary width than HC. A more severe microangiopathy, characterized by higher rate of active/late scleroderma pattern, lower capillary density, and neo-angiogenesis, was found in SSc-PAH patients compared to SSc patients without PAH. These findings confirm that PAH patients (both idiopathic and SSc related forms) had more aggressive micro-vessels involvements and support the hypothesis of systemic microvascular involvement in idiopathic PAH which can be detected by NVC, although it is not clear if the systemic microcirculation anomalies are causal or consequential to PAH disease (60).

## NAILFOLD CAPILLAROSCOPY IN MISCELLANEOUS DISEASES : FROM HEREDITARY DISORDERS TO ALZHEIMER DISEASE

As useful and feasible diagnostic tool, NVC was performed in different diseases, in order to reach new knowledges in the pathogenesis, clinical involvements and treatment efficacy.

Aschwanden M *et al.* performed NVC in 11 patients with sclerodermoid graft-versus-host disease. All these patients received peripheral blood stem cells to treat their hematologic diseases. The role of vascular pathology in chronic graft versus host disease is less well understood. In this study nine patients showed a good visibility of the capillaries, with a uniform pattern. Rare hemorrhages were seen in three patients and just a patient showed enlarged capillaries (61). These results countered with those of Akay's study about NVC in patients with graft versus host disease. In the latter study severe capillaries abnormalities were found, probably due to the presence of RP in 17% of the patients enrolled (62).

Kindler syndrome (KS) is a type of hereditary epidermolysis bullosa characterized by skin fragility, photosensitivity and progressive poikilodermatous changes. Dobrev HP *et al.* reported the case of a 54-year old woman with KS. Pronounced alterations in finger capillaries, such as reduction in capillary density, neo-angiogenesis, branching capillaries, enlarged and giant capillaries was observed at NVC. These changes may be due to a mechanism that compensate the loss of capillaries caused by chronic finger trauma (63).

In hereditary hemorrhagic telangiectasia (HHT), a dominantly inherited disorder, cutaneous telangiectasias have been studied by skin biopsy and recently by NVC. Pasculli G *et al.* performed NVC in 88 patients with HHT : pseudo-mega-capillaries and mega-capillaries were found in six patients (7%) ; the other 82 patients, as well as HC, had normal NVC patterns (64).

Ingenoli F *et al.* showed a case of scleroderma like pattern in adult progeria (Werner syndrome). This patient was referred

to a Rheumatology Division for the suspicion of SSc because he suffered from large and deep ulcers on both legs. NVC showed a scleroderma like pattern and the genetic tests diagnosed Werner Syndrome. This clinical case demonstrates the possibility of NVC anomalies, such as dilated capillaries and tortuosity, in patient with a rare genetic disorder, suggesting microvascular damage as key point in the pathogenesis of the disease. To the best of our knowledge, this is the first report describing the NVC abnormalities in Werner syndrome (65).

Bianciardi *et al.* performed NVC in patients with Rett Syndrome, a neurobiological post-natal disease that represents the second common cause of mental retardation. Its non-neurological phenotype is characterized by cold and blue hands and feet : in these subjects NVC showed branched capillaries, dilated capillaries, and microarchitecture disorganization. These findings indicate the presence of previously unrecognized microvascular abnormalities in Rett syndrome (66).

Cerebrovascular disease (CVD) is highly associated with Alzheimer's disease (AD), but its role is not entirely understood. Cousin CC *et al.* studied NVC abnormalities in patients with AD and mild cognitive impairment in comparison to patients with normal cognition. In 56% of AD patients NVC showed an increase of capillary tortuosity, suggesting a role of microvascular changes in the pathogenesis of AD (67).

Few studies explored the role of microvascular changes in patients with psychiatric diseases such as schizophrenia and anorexia nervosa. RP has been described in anorexia nervosa with evidence of three different NVC patterns : normal, non-specific and early scleroderma pattern. This results underlined a correlation between RP in patients with anorexia nervosa and early scleroderma pattern at NVC, suggesting that patients with RP and anorexia have NVC pattern similar to patients suffering from CTD (68).

Vuchetich JP *et al.* performed NVC in patients with schizophrenia evaluating the nail plexus visibility. This study revealed that patients with a higher plexus visibility had significantly more negative symptoms and poorer social functioning (69).

## SUMMARY

Endothelial dysfunction plays an important role in the pathogenesis of microvascular complications in several diseases, such as diabetes mellitus, pulmonary disease (ILD and PAH), hematological diseases and CTD.

NVC is a safe and useful investigational tool that could assess an early detection of endothelial dysfunctions, allowing a qualitative description of the microvascular abnormalities. The most common diagnostic use of NVC is in the differentiation between primary and secondary RP. Nowadays, well recognized and standardized patterns (early, active, and late scleroderma patterns) are established in SSc patients (2). Although understudied, NVC abnormal findings, without specific pattern, could be related to clinical parameters in various pathologies. In diabetes mellitus, NVC could be used to early detect organ involvements and microvascular complications, to improve and potentiate the treatment management.

In glaucoma, sickle cell disease, Werner syndrome, and Rett syndrome, NVC seems to discover new etiopathogenetic pathways. In particular, in the Werner syndrome an association between scleroderma like pattern and the presence of deep ulcers are described, suggesting a severe microangiopathy (50).

In idiopathic ILD, idiopathic PAH, and SH the improvement of NVC findings could be useful to assess treatment efficacy.

Even though the NVC finding of tortuosity, elongation, ectasia, and hemorrhages could be common, but not standardized,



their presence in association with systemic disease could suggest an early endothelial dysfunction worthy of depth clinical assessment and therapeutic enhancement.

At the time, we need more studies to open new scenarios of NVC technique's application in NRD.

## FUNDING

The study had no financial support.

## COMPETING INTEREST

None

## DISCLOSURE STATEMENT

N. Mansueto had no disclosures

C Rotondo had no disclosures

A Corrado had no disclosures

FP Cantatore had no disclosures

## REFERENCES

- Cutolo M, Paolino S, Smith V : Nailfold capillaroscopy in rheumatology : ready for the daily use but with care in terminology. *Clin Rheumatol* 38 (9) : 2293-2297, 2019
- Ingegnoli F, Smith V, Sulli A, Cutolo M : Capillaroscopy in Routine Diagnostics : Potentials and Limitations. *Curr Rheumatol Rev* 14(1) : 5-11, 2018
- Cantatore FP, Corrado A, Covelli M, Lapadula G : Morphologic study of the microcirculation in connective tissue diseases. *Ann Ital Med Int* 15(4) : 273-81, 2000
- Ocampo-Garza SS, Villarreal-Alarcón MA, Villarreal-Treviño AV, Ocampo-Candiani J : Capillaroscopy : A Valuable Diagnostic Tool. *Actas Dermosifiliogr* 110(5) : 347-352, 2019
- Hughes M, Herrick AL : Raynaud's Phenomenon. *Best Pract Res Clin Rheumatol* 30(1) : 112-132, 2016
- Grattagliano V, Iannone F, Praino E, De Zio A, Riccardi MT, Carrozzo N, Maggi P, Lapadula G : Digital laser doppler flowmetry may discriminate "limited" from "diffuse" systemic sclerosis. *Microvasc Res* 80(2) : 221-6, 2010
- Ruaro B, Sulli A, Smith V, Pizzorni C, Paolino S, Alessandri E, Cutolo M : Microvascular damage evaluation in systemic sclerosis : the role of nailfold videocapillaroscopy and laser techniques. *Reumatismo* 69(4) : 147-155, 2017
- Ruaro B, Smith V, Sulli A, Pizzorni C, Tardito S, Patanè M, Paolino S, Cutolo M : Innovations in the Assessment of Primary and Secondary Raynaud's Phenomenon. *Front Pharmacol* April 16, 2019
- Caramaschi P, Volpe A, Pieropan S, Tinazzi I, Mahamid H, Bambara LM, Biasi D : Cyclophosphamide treatment improves microvessel damage in systemic sclerosis. *Clin Rheumatol* 28(4) : 391-5, 2009
- Guiducci S, Bellando Randone S, Bruni C, Carnesecchi G, Maresta A, Iannone F, Lapadula G, Matucci Cerinic M : Bosentan fosters microvascular de-remodelling in systemic sclerosis. *Clin Rheumatol* 31(12) : 1723-5, 2012
- Cutolo M, Zampogna G, Vremis L, Smith V, Pizzorni C, Sulli A : Longterm effects of endothelin receptor antagonism on microvascular damage evaluated by nailfold capillaroscopic analysis in systemic sclerosis. *J Rheumatol* 40(1) : 40-5, 2013
- Grassi W, De Angelis R : Capillaroscopy : questions and answers. *Clin Rheumatol* 26(12) : 2009, 2007
- Sulli A, Ruaro B, Smith V, Pizzorni C, Zampogna G, Gallo M, Cutolo M : Progression of nailfold microvascular damage and antinuclear antibody pattern in systemic sclerosis. *J Rheumatol* 40 : 634-9, 2013
- Cutolo M, Soldano S, Smith V : Pathophysiology of systemic sclerosis : current understanding and new insights. *Expert Rev Clin Immunol* 15 : 753-64, 2019
- Bruni C, Frech T, Manetti M, Rossi FW, Furst DE, De Paulis A, Rivellesse F, Guiducci S, Matucci-Cerinic M, Bellando-Randone S : Vascular Leaking, a Pivotal and Early Pathogenetic Event in Systemic Sclerosis : Should the door be closed? *Front Immunol* 9 : 2045-8, 2018
- Cutolo M, Sulli A, Secchi ME, Olivieri M, Pizzorni C : The Contribution of Capillaroscopy to the Differential Diagnosis of Connective Autoimmune Diseases. *Best Pract Res Clin Rheumatol* 21(6) : 1093-108, 2007
- Cortes S, Cutolo M : Capillaroscopic patterns in rheumatic diseases. *Acta Reumatologica Portuguesa* 32 : 29-36, 2007
- Beyer C, Schett G, Gay S, Distler O, Distler JH : Hypoxia in the pathogenesis of systemic sclerosis. *Arthritis Res Ther* 11 : 220, 2009
- Pizzorni C, Sulli A, Paolino S, Ruaro B, Smith V, Trombetta AC, Cutolo M : Progression of Organ Involvement in Systemic Sclerosis Patients with Persistent "Late" Nailfold Capillaroscopic Pattern of Microangiopathy : A Prospective Study. *J Rheumatol* 44(12) : 1941-1942, 2017
- Jones BF, Oral M, Morris CW, Ring EFJ : A proposed taxonomy for nailfold capillaries based on their morphology. *IEEE Transactions on Medical Imaging* 20(4) : 333-341, 2001
- Lamova SN, Muller-Ladner U : Capillaroscopic Pattern in Inflammatory Arthritis. *Microvasc Res* 83(3) : 318-22, 2012
- Cutolo M, Sulli A, Smith V : How to perform and interpret capillaroscopy. *Best Pract Res Clin Rheumatol* 27(2) : 237-248, 2013
- Bakirci S, Celik E, Acikgoz SB, Erturk Z, Tocoglu AG, Imga NN, Kaya M, Tamer A : The evaluation of nailfold videocapillaroscopy findings in patients with type 2 diabetes with and without diabetic retinopathy. *North Clin Istanbul* 6(2) : 146-150, 2018
- Kuryliszyn-Moskal A, Dubicki A, Zarzycki W, Zonnenberg A, Górska M : Microvascular abnormalities in capillaroscopy correlate with higher serum IL-18 and sE-selectin levels in patients with type 1 diabetes complicated by microangiopathy. *Folia Histochem Cytobiol* 49(1) : 104-10, 2011
- Meyer MF, Pfohl M, Schatz H : Assessment of diabetic alterations of microcirculation by means of capillaroscopy and laser-Doppler anemometry. *Med Klin (Munich)* 96(2) : 71-7, 2001
- Barchetta I, Riccieri V, Vasile M, Stefanantonio K, Comberiati P, Taverniti L, Cavallo MG : High prevalence of capillary abnormalities in patients with diabetes and association with retinopathy. *Diabet Med* 28(9) : 1039-44, 2011
- Maldonado G, Guerrero R, Paredes C, Ríos C : Nailfold capillaroscopy in diabetes mellitus. *Microvasc Res* 112 : 41-46, 2017
- Chang CH, Tsai RK, Wu WC, Kuo SL, Yu HS : Use of dynamic capillaroscopy for studying cutaneous microcirculation in patients with diabetes mellitus. *Microvasc Res* 53(2) : 121-7, 1997
- Cicco G, Cicco S : Hemorheological aspects in the microvasculature of several pathologies. *Adv Exp Med Biol* 599 : 7-15, 2007
- Uyar S, Balkarli A, Erol MK, Yesil B, Tokuç A, Durmaz D, Görar S, Çekin AH : Assessment of the Relationship

- between Diabetic Retinopathy and Nailfold Capillaries in Type 2 Diabetics with a Noninvasive Method : Nailfold Videocapillaroscopy. *J Diabetes Res* 2016 : 7592402, 2016
31. Lisco G, Cicco G, Cignarelli A, Garruti G, Laviola L, Giorgino F : Computerized Video-Capillaroscopy Alteration Related to Diabetes Mellitus and Its Complications. *Adv Exp Med Biol* 1072 : 363-368, 2018
  32. Friedman DS, Wolfs RC, O'Colmain BJ, Klein BE, Taylor HR, West S, Leske MC, Mitchell P, Congdon N, Kempen J : Eye Diseases Prevalence Research. Prevalence of open-angle glaucoma among adults in the United States. *Arch Ophthalmol* 122(4) : 532-8, 2004
  33. Božić M, Senčanić PH, Spahić G, Kontić D, Marković V, Marjanović I, Stojković M, Dorđević-Jocić J : Is nail fold capillaroscopy useful in normotensive and primary open angle glaucoma? A pilot study. *Curr Eye Res* 35(12) : 1099-104, 2010
  34. Cousins CC, Kang JH, Bovee C, Wang J, Greenstein SH, Turalba A, Shen LQ, Brauner S, Boumenna T, Blum S, Levkovitch-Verbin H, Ritch R, Wiggs JL, Knepper PA, Pasquale LR : Nailfold capillary morphology in exfoliation syndrome. *Eye (Lond)* 31(5) : 698-707, 2017
  35. Philip S, Najafi A, Tantraworasin A, Pasquale LR, Ritch R : Nailfold Capillaroscopy of Resting Peripheral Blood Flow in Exfoliation Glaucoma and Primary Open-Angle Glaucoma. *JAMA Ophthalmol* 137(6) : 618-625, 2019
  36. Pasquale LR, Hanyuda A, Ren A, Giovingo M, Greenstein SH, Cousins C, Patrianakos T, Tanna AP, Wanderling C, Norkett W, Wiggs JL, Green K, Kang JH, Knepper PA : Nailfold Capillary Abnormalities in Primary Open-Angle Glaucoma : A Multisite Study. *Invest Ophthalmol Vis Sci* 56(12) : 7021-7028, 2015
  37. Kosior-Jarecka E, Bartosińska J, Łukasik U, Wróbel-Dudzińska D, Krasowska D, Chodorowska G, Żarnowski T : Results of Nailfold Capillaroscopy in Patients with Normal-Tension Glaucoma. *Curr Eye Res* 43(6) : 747-753, 2018
  38. Park HY, Park SH, Oh YS, Park CK : Nail bed hemorrhage : a clinical marker of optic disc hemorrhage in patients with glaucoma. *Arch Ophthalmol* 129(10) : 1299-304, 2011
  39. Gasser P, Flammer J : Blood-cell velocity in the nailfold capillaries of patients with normal-tension and high-tension glaucoma. *Am J Ophthalmol* 111(5) : 585-8, 1991
  40. Gomes BF, Souza R, Valadão T, Kara-Junior N, Moraes HV, Santhiago MR : Is there an association between glaucoma and capillaroscopy in patients with systemic sclerosis? *Int Ophthalmol* 38(1) : 251-256, 2018
  41. Sapozhnikov M, Rehman M, Johnson C, Daich J, Saliccioli L, Gillette P, Lazar JM : Characterization of microvascular disease in patients with sickle cell disease using nailfold capillaroscopy. *Microvasc Res* 125 : 103877, 2019
  42. Kamińska-Winciorek GM, Brzezińska-Wcisło LA : Assessment of microcirculatory system with conventional capillaroscopy in patients with rosacea--preliminary study. *Wiad Lek* 59(9-10) : 618-22, 2006
  43. Gerkowicz A, Krasowska D, Pietrzak A, Michalak-Stoma A, Bartosińska J, Juskiewicz-Borowiec M, Chodorowska G : Videocapillaroscopic alterations in alopecia areata. *Biomed Res Int* 2013 : 160203, 2013
  44. Ganzetti G, Campanati A, Simonetti O, Cataldi I, Giuliodori K, Offidani AM : Videocapillaroscopic pattern of alopecia areata before and after diphenylcyclopropenone treatment. *Int J Immunopathol Pharmacol* 24(4) : 1087-91, 2011
  45. Lima AS, Pizzol VI, Fritsch S, Fonseca GP, Mulinari-Brenner FA, Muller CS, Ottoboni VC : Nailfold capillaroscopy in leprosy. *An Bras Dermatol* 91(5) : 686-687, 2016
  46. Markusse IM, Meijs J, de Boer B, Bakker JA, Schippers HPC, Schouffoer AA, Ajmone Marsan N, Kroft LJM, Ninaber MK, Huizinga TWJ, de Vries-Bouwstra JK : Predicting cardiopulmonary involvement in patients with systemic sclerosis : complementary value of nailfold videocapillaroscopy patterns and disease-specific autoantibodies. *Rheumatology (Oxford)* 56(7) : 1081-1088, 2017
  47. Cutolo M, Damjanov N, Ruaro B, Zekovic A, Smith V : Imaging of connective tissue diseases : Beyond visceral organ imaging? *Best Pract Res Clin Rheumatol* 30(4) : 670-687, 2016
  48. Smith V, Ricciari V, Pizzorni C, Decuman S, Deschepper E, Bonroy C, Sulli A, Piette Y, De Keyser F, Cutolo M : Nailfold capillaroscopy for prediction of novel future severe organ involvement in systemic sclerosis. *J Rheumatol* 40 : 2023-8, 2013
  49. Wu W, Jordan S, Becker MO, Dobrota R, Maurer B, Fretheim H, Ye S, Siegert E, Allanore Y, Hoffmann-Vold AM, Distler O : Prediction of progression of interstitial lung disease in patients with systemic sclerosis : the SPAR model. *Ann Rheum Dis* 77 : 1326-32, 2018
  50. Smith V, Distler O, Cutolo M : Might Nailfold Capillaroscopy Be a "Proxy" for Lung Involvement in Connective Tissue Diseases? *J Rheumatol* 46(9) : 1061-1063, 2019
  51. Castellví I, Simeón-Aznar CP, Sarmiento M, Fortuna A, Mayos M, Geli C, Diaz-Torné C, Moya P, De Llobet JM, Casademont J : Association between nailfold capillaroscopy findings and pulmonary function tests in patients with systemic sclerosis. *J Rheumatol* 42(2) : 222-227, 2015
  52. Caetano J, Paula FS, Amaral M, Oliveira S, Alves JD : Nailfold Videocapillaroscopy Changes Are Associated With the Presence and Severity of Systemic Sclerosis-Related Interstitial Lung Disease. *J Clin Rheumatol* 25(3) : e12-e15, 2019
  53. Guillen-del-Castillo A, Simeón-Aznar CP, Callejas-Moraga EL, Tolosa-Vilella C, Alonso-Vila S, Fonollosa-Pla V : Quantitative Videocapillaroscopy Correlates With Functional Respiratory Parameters : A Clue for Vasculopathy as a Pathogenic Mechanism for Lung Injury in Systemic Sclerosis. *Arthritis Res Ther* 20(1) : 281, 2018
  54. Corrado A, Carpagnano GE, Gaudio A, Foschino-Barbaro MP, Cantatore FP : Nailfold capillaroscopic findings in systemic sclerosis related lung fibrosis and in idiopathic lung fibrosis. *Joint Bone Spine* 77(6) : 570-4, 2010
  55. Vicaute E : Microcirculation and arterial hypertension. *Drugs* 59 : 1-10, 1999
  56. Penna GL, Garbero Rde F, Neves MF, Oigman W, Bottino DA, Bouskela E : Treatment of essential hypertension does not normalize capillary rarefaction. *Clinics (Sao Paulo)* 63(5) : 613-8, 2008
  57. James MA, Tullett J, Hemsley AG, Shore AC : Effects of aging and hypertension on the microcirculation. *Hypertension* 47(5) : 968-74, 2006
  58. Cheng C, Daskalakis C, Falkner B : Non-invasive assessment of microvascular and endothelial function. *J Vis Exp* 29(71) : e50008, 2013
  59. Junqueira CLC, Magalhães MEC, Brandão AA, Ferreira E, Cyrino FZGA, Maranhão PA, Souza MDGC, Bottino DA, Bouskela E : Microcirculation and biomarkers in patients with resistant or mild-to-moderate hypertension: a cross-sectional study. *Hypertens Res* 41(7) : 515-523, 2018
  60. Corrado A, Correale M, Mansueto N, Monaco I, Carriero A, Mele A, Colia R, Di Biase M, Cantatore FP : Nailfold capillaroscopic changes in patients with idiopathic pulmonary arterial hypertension and systemic sclerosis-related pulmonary arterial hypertension. *Microvasc Res* 114 : 46-51, 2017
  61. Aschwanden M, Halter JP, Walker UA, Staub D, Tichelli



- A, Daikeler T, Jaeger KA, Tyndall A : Nail fold capillaroscopy differs widely between systemic sclerosis and chronic graft vs host disease of the skin. *Rheumatology (Oxford)* 50(6) : 1168-9, 2011
62. Akay BN, Sanli H, Topcuoglu P, Arat M, Akyol A : Nailfold capillary abnormalities are prevalent in sclerodermoid graft-versus-host disease and readily detected with dermatoscopy. *Br J Dermatol* 162(5) : 1076-82, 2010
  63. Dobrev HP, Vutova NI : Nailfold capillaroscopic changes in Kindler syndrome. *Intractable Rare Dis Res* 4(4) : 214-6, 2015
  64. Pasculli G, Quaranta D, Lenato GM, Suppressa P, Lastella P, Guanti G, Sabbà C : Capillaroscopy of the dorsal skin of the hands in hereditary hemorrhagic telangiectasia. *QJM* 98(10) : 757-63, 2005
  65. Ingegnoli F, Crotti C : Nailfold scleroderma-like capillary abnormalities in Werner syndrome (adult progeria). *Vasc Med* 22(3) : 246-247, 2017
  66. Bianciardi G, Acampa M, Lamberti I, Sartini S, Servi M, Biagi F, Bocchi V, Hayek J, Pastorelli M : Microvascular abnormalities in Rett syndrome. *Clin Hemorheol Microcirc* 54(1) : 109-13, 2013
  67. Cousins CC, Alosco ML, Cousins HC, Chua A, Steinberg EG, Chapman KR, Bing-Canar H, Tripodis Y, Knepper PA, Stern RA, Pasquale LR : Nailfold Capillary Morphology in Alzheimer's Disease Dementia. *J Alzheimers Dis* 66(2) : 601-611, 2018
  68. De Martinis M, Sirufo MM, Ginaldi L : Raynaud's phenomenon and nailfold capillaroscopic findings in anorexia nervosa. *Curr Med Res Opin* 34(3) : 547-550, 2018
  69. Vuchetich JP, Liska JL, Dionisio DP, Stanwyck JJ, McGuire KA, Sponheim SR : Elevated nailfold plexus visibility aggregates in families and is associated with a specific negative symptom pattern in schizophrenia. *Psychiatry Res* 160(1) : 30-7, 2008