

REVIEW

A new surgical strategy for the intractable chronic low back pain due to type 1 Modic change using transforaminal full-endoscopic disc cleaning (FEDC) surgery under the local anesthesia : A case report and literature review

Koichi Sairyo, Toru Maeda, Kazuta Yamashita, Fumitake Tezuka, Masatoshi Morimoto, Kiyoshi Yagi, Kazuya Kishima, Kosuke Sugiura, Makoto Takeuchi, Yuji Yamada, Yoichiro Takata, and Toshinori Sakai

Department of Orthopedics, Tokushima University, Tokushima, Japan

Abstract : It has been reported that Modic change of the lumbar spine endplate includes three types: i.e. . edema or inflammation for type 1, fatty marrow change for type 2 and sclerotic change for type 3. Basically, type 1 Modic change may be related to the chronic low back pain. There are two kinds of the treatment for the type 1 Modic change to heal the pain : the anti-inflammatory drugs, and intra-discal injection of steroid. When the inflammatory change would be intractable, surgical intervention is needed. The gold standard for the surgical intervention is the segmental fusion of the affected level. The fusion surgery may cause the adjacent degeneration ; thus, motion preservation surgery is better, if possible. Our department started the motion preservation full-endoscopic intradiscal debridement surgery for this pathology, since some of the type 1 Modic change may be chronic discitis by *P. Acnes*. In this paper, we describe the first patient of type 1 Modic change who was successfully treated by the full-endoscopic intra-discal debridement and drainage under the local anesthesia. We named this procedure as transforaminal full-endoscopic disc cleaning surgery (FEDC). Finally, pathology, conservative and surgical intervention of Modic change was discussed. *J. Med. Invest.* 68: 1-5, February, 2021

Keywords : Type 1 Modic change, inflammation, *Propionibacterium acnes* (*P. acnes*), transforaminal full-endoscopic spinal surgery, disc cleaning

INTRODUCTION

In 1988, Modic *et al.* reviewed MRI findings of the degenerated disc disease and found that there were three types of the abnormal findings : i.e., type 1 for marrow edema or inflammation, type 2 for fatty marrow degeneration and type 3 for sclerotic change (1, 2). Among these 3 types, type 1 Modic change is reported to be related to chronic low back pain (3, 4). Modic type 1 changes was reported to be found in 35-40% of the low back pain population (5).

As a conservative treatment for the low back pain due to type 1 Modic change, intra-discal steroid injection was reported to be effective because its pathology was inflammation (6-8). Figure 1 demonstrates a case that was successfully treated by the intra-discal steroid. The inflammatory sign as hyper-intensive change on STIR-MRI on the left panel is disappeared after the treatment as shown on the right panel.

In 2001, Stirling *et al.* (9) proposed that chronic low back pain might be related infection, and proved that 19 among 36 intervertebral discs removed during surgery showed microorganisms. Most common microorganism was *Propionibacterium acnes* (*P. acnes*) in 16 cases among 19 (84%). Recently, *P. Acnes* infectious discitis is also reported to be one of the pathology of the chronic type 1 Modic change (10), although the significance is still in controversy (11). If there would be *P.acnes* infection as the pathology for type 1 Modic change, intra-discal steroid injection may be worsen the infection.

The surgical strategy for the infectious discitis is conservative treatment with antibiotics (12). If the infection is intractable, surgical management is indicated (12). The minimally invasive surgery would be percutaneous full-endoscopic debridement (13, 14) ; however, there would be no report of percutaneous full-endoscopic endoscopic debridement for the intractable type 1 Modic change. Here, we describe the first case who underwent percutaneous full-endoscopic endoscopic debridement for the intractable type 1 Modic change. Finally, we would like to review the treatment with some literature.

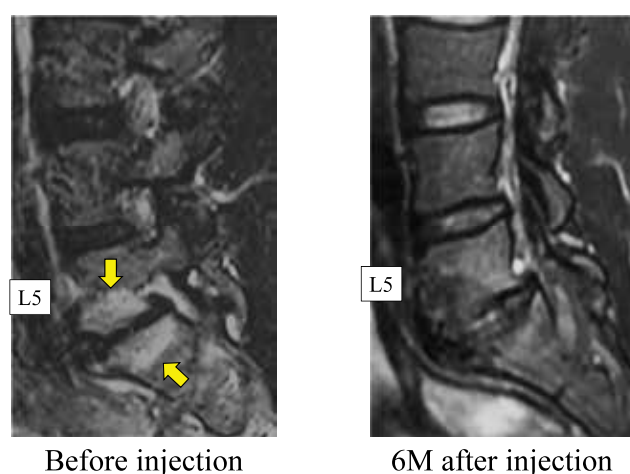


Figure 1. STIR-MRI before and after steroid injection
A case successfully treated by the intra-discal steroid. The inflammatory sign as hyper-intensive change on STIR-MRI on the left panel is disappeared after the treatment as shown on the right panel.

Received for publication August 2, 2020 ; accepted August 31, 2020.

Address correspondence and reprint requests to Koichi Sairyo, MD, PhD Professor and Chairman Department of Orthopedics, Tokushima University Graduate School 3-18-15 Kuramoto, Tokushima 770-8503, Japan and Fax : +81-88-633-0178.

A CASE REPORT

A 38 years old male visited us with complaining of chronic low back pain. He had been suffering from the pain more than 4 years. All the time, he was feeling pain in visual analog scale (VAS) being 2 out of 10 at least. When he moved a lot, the pain increased to 8 out of 10 in VAS. In this 4 years, he could never forget the pain.

In physical examination, he complained the strong low back pain in flexion. Tenderness was noticed on the L5 and S1 spinous process. Regarding the neurological examination, motor and sensory function was normal. Tension sign of femoral and sciatic nerve was also normal. Figure 2 demonstrates MRIs at the first presentation at our clinic. In bone marrow surrounding L5/s disc space, low and high intensity combined area is seen on both T1 and T2 weighted images. Higher intense image is obvious on STIR-MRI. Thus, this Modic change is mainly type 1 inflammation with type 2 fatty marrow. Plain radiographs and CT scans is shown on Figure 3. Disc space is collapse at L5/s level on both of them. On CT scan, sclerotic change with small bony cyst is obvious.

First, conservative treatment was conducted including intra-venous injection of steroid. Also, we gave him oral NSAID for one year and antibiotics for three months. Because of the possibility of infectious discitis, we did not perform intra-discal steroid injection. These conservative treatment for 1 year was not

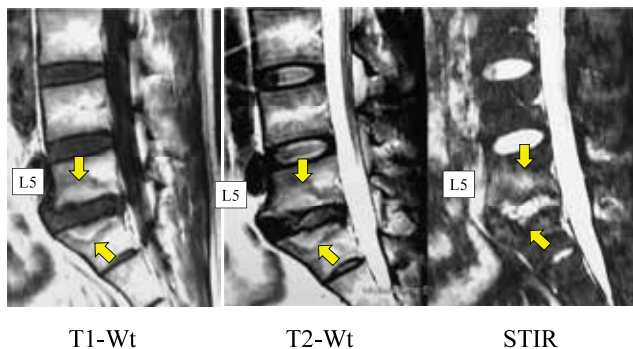


Figure 2. MRI at initial presentation
MRIs at the first presentation at our clinic. In bone marrow surrounding L5/s disc space, low and high intensity combined area is seen on both T1 and T2 weighted images. Hyper intense image is obvious on STIR-MRI. Thus, this Modic change is mainly type 1 inflammation with type 2 fatty marrow.

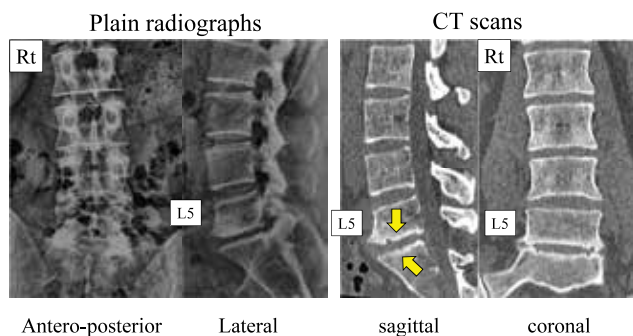


Figure 3. Plain radiographs and CT scan before surgery
Plain radiographs and CT scan at the initial presentation. Disc space is collapse at L5/s level on both of Plain radiographs and CT scan. On CT scan, sclerotic change with small bony cyst is obvious.

effective to lessen the low back pain ; thus, surgical intervention was recommended to him. As for the surgical intervention for the painful Modic change in the literature, intervertebral fusion surgery has been mainly reported (15, 16). Since this patient was very active on sports such as golfing, he asked us to avoid the fusion surgery. After written informed consent, percutaneous full-endoscopic discectomy and debridement was planned.

The detailed surgical procedure of the transforaminal full-endoscopic discectomy (TF-FED) is described in the literature (17). According to the technique, we conducted minimally invasive TF-FED and debridement under the local anesthesia with 8 mm skin incision. There was new vessels in the affected disc space ; then, it was coagulated using the radio-pulse bipolar. The endoscopic surgery was successfully completed without any surgical complications under local anesthesia.

After the surgery, he continued to take NSAID to lessen the inflammation. The low back pain decreased day by day, and the pain almost disappeared completely one week after the surgery, and he felt just discomfort at low back. The VAS for low back pain became zero two months after the surgery. Figure 4 demonstrates the time course of the STIR-MRI. The hyper signal surrounding the L5/s space decreased after the surgery.

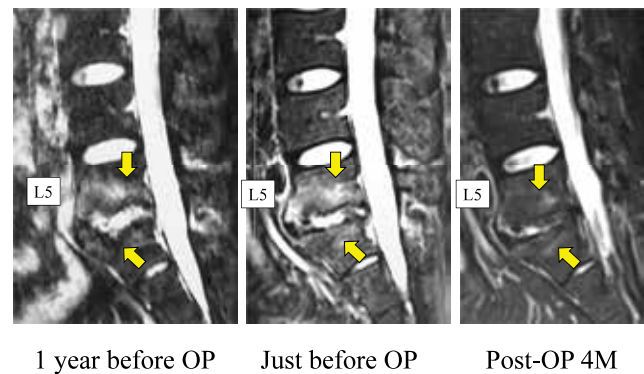


Figure 4. Time course of STIR-MRI before and after OP
Time course change of the inflammatory sign on STIR-MRI. The hyper signal surrounding the L5/s space decreased after the surgery.

DISCUSSION

Modic type 1 change and intradiscal steroid therapy

Since type 1 Modic change is inflammation near the endplate, intra-discal steroid injection is theoretically effective (3, 4, 6-8). Cao *et al.* (8) performed double-blind, randomized, controlled, prospective clinical study with 120 cases with Modic change and chronic low back pain (CLBP). They concluded that intradiscal injection of corticosteroids could be a short-term efficient alternative for CLBP due to Modic changes. Fayad *et al.* (6) evaluated the intra-discal steroid injection in Modic type I and type II cases, and found that pain alleviation was greater in type 1 cases.

Mefford *et al.* (3) reported four golfers with CLBP. They found type 1 Modic change at the right side endplate of the lower lumbar spine in all cases. Intra-discal steroid injection was effective to lessen the pain. In 2 among 4 cases, they confirmed that hyper-signal change on the follow-up STIR-STIR disappeared, meaning the inflammatory sign was also decreased with pain. Mineta *et al.* (4) treated successfully with intra-discal steroid injection, and type 1 converted to type 2. However, the type 2 became back to type 1 again. Then, they gave intra-discal steroid injection again. Finally, type 1 converted again to type 2, and

CLBP disappeared.

Modic type 1 change and P. acnes : clinical review

MRI findings of the pyogenic discitis and Modic type I change are very similar : i.e. high signal on T1-weighted and low signal on T2-weighted image (18). In 2008, the first report proposed the relationship between Modic change and *P. acnes* infection (19). Manniche and O'Neill (10) reviewed some positive papers that *P. acnes* is correlated to Modic type 1 change. They proposed a theory to cause Modic type 1 change after *P. acnes* infection as follows. Since normal disc is surrounded with anatomical barrier against the bacteria ; thus, the leaky disc is the required basic condition to have an infection. Then, *P. acnes* may migrate into the disc. It may cause disc degeneration and damage of the endplate. Finally, it could result in Modic type 1 change. Albert *et al.* demonstrated very interested report to support the leaky disc first then leading Modic change theory (20). They included 61 cases with herniated nucleus pulposus, and microbiological cultures were performed for the disc samples taken during the surgery. Surprisingly, 28 (46 %) of the 61 cases were found to have microorganisms present. The microorganism most frequently cultured was the anaerobic bacterium, *P. acnes* (24 among 28 : 86%). They took follow-up MRI, and evaluated newly occurred Modic change. In 80% of the disc having positive anaerobic bacteria showed new Modic change after the surgery. On the other hand, Jha and Sairyo (11) reviewed the role of *P. acnes* on Modic type 1. They concluded that the role has been still under controversial.

Modic type 1 change and P. acnes : Animal study

In 2016, Dudli *et al.* reported rat experimental study proving that *P. acnes* can cause Modic type 1 change (21). *P. acnes* was injected into rat tail discs, and the infected disc was evaluated histologically and radiologically with MRI. Histological investigation 14 days after injection showed endplates and trabecular bone were resorbed and fibrotic tissue extended into the bone marrow. At day-20, MRI was evaluated and it clearly showed that *P. acnes* injection could cause Modic type 1 change. Contrary, Zamora *et al.* reported that *P. acnes* injection into the rat caudal tail disc induced disc degeneration ; however, no Modic change was observed (22).

Chen *et al.* used rabbit model for understand the relationship between *P. acnes* and Modic type 1 change (23). They successfully induced the moderate disc degeneration with Modic type 1 change by *P. acnes* injection. Shan also used rabbit model (24), and 3 months after the injection they confirmed the occurrence of Modic type 1 change. Histologically, discs injected with *P. acnes* showed degeneration, endplate abnormalities, and inflammatory response.

Antibiotics to Modic type 1 change

Thirty-two patients with chronic low back pain with Modic type 1 changes were treated with Amoxicillin-clavulanate for 90 days (25). At the end of treatment and at long-term follow-up (mean 10.8 months), significant improvement was observed in all outcome measures. These results could support that bacterial infection may play a role in Modic type 1 changes. Albert *et al.* (26) performed a double-blind randomized clinical controlled trial to understand the efficacy of antibiotics for Modic type 1 change. Total 162 patients were enrolled, and antibiotics were used for 100 days and the effects were compared with placebo group. Finally, they proved the effectiveness of the antibiotics for Modic type 1 clinically. On the other hand, recently, a double-blind parallel-group multicentre trial to confirm the effectiveness of antibiotics for Modic changes (27). They included 180 patients, and the patients were divided into antibiotics and

placebo groups. They did not find evidence for convincing clinical effect modifiers of antibiotic treatment in patients with chronic low back pain and Modic changes. Thus, this is also still under controversial.

Infectious discitis and full-endoscopic debridement

The full-endoscopic spine surgery (FESS) was first developed for the discectomy (28, 29). Then, owing to the evolution of surgical equipment such as surgical drill and rongeur, the indication was enlarged to the decompression surgery for the spinal canal stenosis (30-32). Recently, the FESS was applied for debridement and drainage (FEDD) in patients with infectious discitis (13,14,33).

It requires only 8 mm skin incision, and damage of the back muscle is very little ; thus it must be the minimally invasive spine surgery currently. The biggest merit of the FESS is that it can be done under the local anesthesia (28-32). Lin *et al.* reviewed 14 high risk cases with single level infectious discitis. They perform FEDD for all 14 cases, and clinical outcome was satisfactory. They concluded that FEDD may be an effective alternative to extensive open surgery in patients with infectious spondylodiscitis, especially those who are high-risk candidates for surgery (elderly patients with multiple comorbidities and patients in poor general condition).

FESS for Modic type 1 change and nomenclature

In this paper, we demonstrated a case having intractable chronic low back pain due to type 1 Modic change. Any type of the conservative treatment was not effective. Thus, first, we recommended him to undergo intervertebral fusion. He was young and was very active on sports ; thus, he requested us to come up with minimally invasive and motion preservation surgery. As described in this article, Modic type 1 change may be related to infectious discitis ; thus, minimally invasive debridement and drainage is theoretically good option for the surgical management. After written informed consent, we conducted the FEDD to him. After the surgery, low back pain decreased day by day, and the pain almost disappeared completely one week after the surgery. The VAS for low back pain became zero two months after the surgery. We confirmed the disappearance of the inflammation and edema on STIR-MRI. Although this is only single case of the full-endoscopic debridement and drainage for Modic type 1 change, the clinical and radiological results was excellent. Thus, we will continue this procedure for intractable Modic type 1 cases.

Regarding the FESS for the infectious discitis by strong virulent bacteria, FEDD meaning debridement and drainage would be appropriate. Modic type 1 change is inflammation, marrow edema and possible low virulent disc infection. Thus, cleaning is the better term. We would like to propose full-endoscopic disc cleaning (FEDC) for this full-endoscopic surgical procedure.

Limitation

In this study, final follow-up was 10 months after the surgery. He started play golfing without any low back pain recurrence. Mineta *et al.* (4) reported a case who showed recurrence of type 1 Modic change. Using intradiscal steroid injection, type 1 MC was converted to type 2. However, 1 year later, type 2 was converted to type 1 again. Presently, low back pain of our case was subsided completely. We should pay special attention to recurrence of the inflammation.

CONCLUSION

We successfully treated a patient with intractable chronic low

back pain (CLBP) due to type 1 Modic change for more than 4 years using transforaminal full-endoscopic intra-discal debridement and drainage. After the surgery, the CLBP disappeared and inflammatory sign on MRI was also disappeared. In conclusion, we would like to propose the full-endoscopic debridement and drainage as the novel surgical strategy for the intractable Modic type 1 change. Finally, we named this procedure to be transforaminal full-endoscopic disc cleaning (FEDC) surgery.

REFERENCES

1. Modic MT, Steinberg PM, Ross JS, Masaryk TJ, Carter JR : Degenerative disc disease : assessment of changes in vertebral body marrow with MR imaging. *Radiology* 166(1 Pt 1) : 193-9, 1988. DOI : 10.1148/radiology.166.1.3336678
2. Modic MT, Masaryk TJ, Ross JS, Carter JR : Imaging of degenerative disk disease. *Radiology* 168(1) : 177-86, 1988. DOI : 10.1148/radiology.168.1.3289089
3. Mefford J, Sairyo K, Sakai T, Hopkins J, Inoue M, Amari R, Bhatia NN, Dezawa A, Yasui N : Modic type I changes of the lumbar spine in golfers. *Skeletal Radiol* 40(4) : 467-73, 2011
4. Mineta K, Higashino K, Sakai T, Fukui Y, Sairyo K : Recurrence of type I Modic inflammatory changes in the lumbar spine : effectiveness of intradiscal therapy. *Skeletal Radiol* 43(11) : 1645-9, 2014
5. Jensen TS, Karppinen J, Sorensen JS, Niinimäki J, Leboeuf-Yde C : Prevalence of vertebral endplate signal (Modic) changes and their association with non-specific low back pain-A systematic literature review. *Eur Spine J* 17 : 1407-1422, 2008
6. Fayad F, Lefevre-Colau MM, Rannou F, Quintero N, Nys A, Macé Y, Poiraudou S, Drapé JL, Revel M : Relation of inflammatory modic changes to intradiscal steroid injection outcome in chronic low back pain. *Eur Spine J* 16(7) : 925-31, 2007. doi : 10.1007/s00586-006-0301-y. Epub 2007 Jan 10.
7. Simmons JW, McMillin JN, Emery SF, Kimmich SJ : Intradiscal steroids. A prospective double-blind clinical trial. *Spine* 17(6 Suppl) : S172-5, 1992
8. Cao P, Jiang L, Zhuang C, Yang Y, Zhang Z, Chen W, Zheng T : Intradiscal injection therapy for degenerative chronic discogenic low back pain with end plate Modic changes. *Spine J* 11(2) : 100-6, 2011. doi : 10.1016/j.spinee.2010.07.001. Epub 2010 Sep 20.
9. Stirling A, Worthington T, Rafiq M, Lambert PA, Elliott TS : Association between sciatica and Propionibacterium acnes. *Lancet* 357 : 2024-2025, 2001. doi : 10.1016/S0140-6736(00)05109-6
10. Manniche C, O'Neill S : New insights link low-virulent disc infections to the etiology of severe disc degeneration and Modic changes. *Future Sci OA* 5(5) : FSO389, 2019
11. Jha SC, Sairyo K : The role of Propionibacterium acnes in and Modic type 1 changes : A literature review. *J Med Invest* 67(1.2) : 21-26, 2020
12. Ryang YM, Akbar M : Pyogenic spondylodiscitis : symptoms, diagnostics and therapeutic strategies. *Orthopade*. 2020. doi : 10.1007/s00132-020-03945-1. Online ahead of print.
13. Fu TS, Chen LH, Chen WJ : Minimally invasive percutaneous endoscopic discectomy and drainage for infectious spondylodiscitis. *Biomed J* 36(4) : 168-74, 2013
14. Lin GX, Kim JS, Sharma S, Sun LW, Wu HH, Chang KS, Chen YC, Chen CM : Full Endoscopic Discectomy, Debridement, and Drainage for High-Risk Patients with Spondylodiscitis. *World Neurosurg* 127 : e202-e211, 2019. doi : 10.1016/j.wneu.2019.02.206. Epub 2019 Mar 14.
15. Kita K, Sakai T, Abe M, Takata Y, Sairyo K : Rehydration of a degenerated disc on MRI synchronized with transition of Modic changes following stand-alone XLIF. *Eur Spine J* 26(3) : 626-631, 2017
16. Shahmohammadi MR, Behrouzian S : Effect of Preoperative Modic Change in the Outcome of Patients with Low Back Pain Following Posterior Spinal Fusion or Laminectomy. *Asian J Neurosurg* 14(2) : 432-435. 6), 2019
17. Sairyo K, Egawa H, Matsuura T, Takahashi M, Higashino K, Sakai T, Suzue N, Hamada D, Goto T, Takata Y, Nishisho T, Goda Y, Sato R, Tsutsui T, Tonogai I, Kondo K, Tezuka F, Mineta K, Sugiura K, Takeuchi M, Dezawa A : State of the art : Transforaminal approach for percutaneous endoscopic lumbar discectomy under local anesthesia. *J Med Invest* 61(3-4) : 217-25, 2014
18. Cusmano F, Calabrese G, Bassi S, Branislav S, Bassi P : Radiologic diagnosis of spondylodiscitis : role of magnetic resonance. *Radiol Med* 100(3) : 112-9, 2000
19. Albert HB, Kjaer P, Jensen TS, Sorensen JS, Bendix T, Manniche C : Modic changes possible causes and relation to low back pain. *Med Hypotheses* 70(2) : 361-368, 2008
20. Albert HB, Lambert P, Rollason J, Sorensen JS, Worthington T, Pedersen MB, Nørgaard HS, Vernallis A, Busch F, Manniche C, Elliott T : Does nuclear tissue infected with bacteria following disc herniations lead to Modic changes in the adjacent vertebrae? *Eur Spine J* 22(4) : 690-6, 2013
21. Dudli S, Liebenberg E, Magnitsky S, Miller S, Demir-Deviren S, Lotz JC : Propionibacterium acnes infected intervertebral discs cause vertebral bone marrow lesions consistent with Modic changes. *J Orthop Res* 34(8) : 1447-55, 2016
22. Zamora T, Palma J, Andia M, Garcia P, Wozniak A, Solar A, Campos M : Effect of Propionibacterium acnes (PA) injection on intervertebral disc degeneration in a rat model : Does it mimic modic changes? *Orthop Traumatol Surg Res* 103(5) : 795-799, 2017
23. Chen Z, Zheng Y, Yuan Y, Jiao Y, Xiao J, Zhou Z, Cao P : Modic Changes and Disc Degeneration Caused by Inoculation of Propionibacterium acnes inside Intervertebral Discs of Rabbits : A Pilot Study. *Biomed Res Int*. 2016 ; 2016 : 9612437. doi : 10.1155/2016/9612437. Epub 2016 Jan 26.
24. Shan Z, Zhang X, Li S, Yu T, Liu J, Zhao F : Propionibacterium acnes Incubation in the Discs Can Result in Time-Dependent Modic Changes : A Long-Term Rabbit Model. *Spine (Phila Pa 1976)* 42(21) : 1595-1603, 2017
25. Albert HB, Manniche C, Sorensen JS, Deleuran BW : Antibiotic treatment in patients with low-back pain associated with Modic changes Type 1 (bone oedema) : a pilot study. *Br J Sports Med* 42 : 969-973, 2008
26. Albert HB, Sorensen JS, Christensen BS, Manniche C : Antibiotic treatment in patient with chronic low back pain and vertebral bone edema (Modic type 1 changes) : a double-blind randomized clinical controlled trail of efficacy. *Eur Spine J* 22(4) : 697-707, 2013
27. Bråten LCH, Grøvle L, Espeland A, Pripp AH, Grotle M, Hellum C, Haugen AJ, Froholdt A, Rolfsen MP, Nygaard ØP, Lutro O, Kristoffersen PM, Anke A, Schistad EI, Skouen JS, Brox JI, Zwart JA, Storheim K ; AIM-study group : Clinical effect modifiers of antibiotic treatment in patients with chronic low back pain and Modic changes - secondary analyses of a randomised, placebo-controlled trial (the AIM study). *BMC Musculoskelet Disord* 21(1) : 458, 2020
28. Yeung AT : The evolution of percutaneous spinal endoscopy

- and discectomy : state of the art. *Mt Sinai J Med* 67 : 327-32, 2000
29. Yeung AT, Tsou PM : Posterolateral endoscopic excision for lumbar disc herniation : Surgical technique, outcome, and complications in 307 consecutive cases. *Spine* 27 : 722-31, 2002
30. Sairyo K, Chikawa T, Nagamachi A : State-of-the-art transforaminal percutaneous endoscopic lumbar surgery under local anesthesia : Discectomy, foraminoplasty, and ventral facetectomy. *J Orthop Sci* 23(2) : 229-236, 2018
31. Sairyo K, Higashino K, Yamashita K, Hayashi F, Wada K, Sakai T, Takata Y, Tezuka F, Morimoto M, Terai T, Chikawa T, Yonezu H, Nagamachi A, Fukui Y : A new concept of transforaminal ventral facetectomy including simultaneous decompression of foraminal and lateral recess stenosis : Technical considerations in a fresh cadaver model and a literature review. *J Med Invest* 64(1. 2) : 1-6, 2017
32. Sairyo K, Yamashita K, Manabe H, Ishihama Y, Sugiura K, Tezuka F, Takata Y, Sakai T, Omichi Y, Takamatsu N, Hashimoto A, Maeda T : A novel surgical concept of transforaminal full-endoscopic lumbar undercutting laminectomy (TE-LUL) for central canal stenosis of the lumbar spine with local anesthesia : A case report and literature review. *J Med Invest* 66(3. 4) : 224-229, 2019
33. Ito M, Abumi K, Kotani Y, Kadoya K, Minami A : Clinical outcome of posterolateral endoscopic surgery for pyogenic spondylodiscitis : results of 15 patients with serious comorbid conditions. *Spine (Phila Pa 1976)* 32(2) : 200-6, 2007