

Macroendoscopic and histopathological aspects in *Helicobacter pylori* gastroenteritis in dogs – case report

Ionela BEJAN, Cătălina-Andreea TURCU, Vasile VULPE, Sorin-Aurelian PAȘCA

FMV Iași

ionelabejan@gmail.com; catalina.andreea.turcu@gmail.com

vasile_vulpe@yahoo.com; passorin@yahoo.com

Abstract

In current veterinary medical practice, more clinical and imaging investigations are needed to fully assess a patient with digestive symptoms. In this case, the anamnesis and patient history are the starting points in staging a diagnosis. Questions with uncertain answers lead to laboratory tests – blood count and blood biochemistry. The etiologic diversity in digestive pathologies implies these blood tests to exclude some of the diseases. X-ray and ultrasound examinations are the next steps to follow; these are diagnosis methods that precede the endoscopic examination. After the macroendoscopic evaluation of the digestive tract, biopsy samples must be taken for the *Helicobacter pylori* quick test (Figure 1). Histological examination of the biopsy samples taken from canine patients, which were positive for *Helicobacter pylori*, can reveal another lesions in the digestive tract; in this moment a treatment can be initiated to reduce or even to abolish the symptomatology.

Key words: digestive pathologies, endoscopy, *Helicobacter pylori*, histological examination

Introduction

Digestive pathology is most common in the veterinary practice in pets. Extensive etiology implies multiple investigations which lead to a diagnosis in reducing or even abolish digestive symptoms. In most cases, no results are obtained with symptomatic treatment and the patient's condition is gradually degraded.

Most of the time, a possible complicated bacterial gastritis or a gastritis with etiological agent bacteria of *Helicobacter spp* is excluded from the treatment scheme. It scales in gastric and sometimes duodenal mucosa, causing even neoplastic lesions [Figure 4, Figure 8]. Quick tests from gastric or duodenal mucosa taken endoscopically are carried out to confirm this type of gastritis in order to complete the histological examination to fill their margin of error. The studies carried out so far on animals have detected several subspecies of *Helicobacter canis*, *Helicobacter felis*, *Helicobacter heilmannii*, *Helicobacter bizzonii*, requiring complex typing examinations (immunohistochemistry, PCR). [1, 2, 3]

The dual antibiotherapy treatment scheme (methronidazole, amoxicillin/claritromycin), gastric protector (omeprazole) and probiotic administration are the first steps to be taken in improving symptomatology.

After assessing blood and biochemical parameters, ultrasound and radiological examinations, the present case shows the importance of some diagnostic methods: the endoscopic method and the histological examination. The endoscopic examination is a certain and minimum invasive diagnosis method, it helps visualizing surface lesions in the digestive tract mucosa. Multiple biopsy samples can also be taken; one biopsy sample is used for the quick test for *Helicobacter pylori* presence, and at least three biopsy samples are used for histopathological examination.

Materials and methods

This case report includes a male dog, mixed breed, neutered, 11 years old, 32 kg, both internal and external anti-parasite treatment given regularly; he was clinically and imagistic evaluated because of digestive signs: vomit, capricious appetite, weight loss. The patient was being treated with metronidazole (7.5 mg / kg twice daily) and probiotics for gastroenteritis. Following

the blood examination (hematological and biochemical profile), certain digestive pathologies (uremic gastroenteritis, enteropathies with protein loss) were excluded, and the imaging examination (ultrasound, radiography) showed the narrowing of the gastric mucosa and normal intestinal transit.

A basic preanesthetic cardiological consultation (electrocardiogram and blood pressure) was performed, which showed no changes. The endoscopic intervention was decided, under inhalatory anesthesia, to evaluate the esophagus, stomach and duodenum.

Pre-anesthesia consisted of intramuscular administration of medetomidine hydrochloride (0.025 mg / kg) and butorphanol (0.1 mg / kg); for induction, propofol (3mg / kg) was administered slowly, intravenously, and maintenance was performed with isoflurane (5 minutes 3%, then reduced to 1.5%).

Biopsy samples were taken from the duodenal mucosa for histological examination, and biopsy samples were taken from the gastric mucosa for both rapid testing for *Helicobacter pylori* (Figure 1) and histological examination.

Rapid tests in the gastric mucosa detect the presence of urease eliminated by the bacterium, but the specificity is reduced due to the administration of metronidazole.



Fig. 1. Rapid test to detect urease activity eliminated by *Helicobacter pylori*

Endoscopic sampling involves the collection of biopsy samples, 1-3 mm, from the gastric and / or intestinal mucosa. It is the least invasive method of tissue sampling for histological examination.

Immediately after harvesting, tissue biopsy samples were fixed in 10% formaldehyde buffered solution for 48 hours, processed by paraffin inclusion method, sectioned and trichromic Masson stained.

Histological preparations were examined with a Leica DM 750 optical microscope, and images were captured with a Leica ICC 50 HD histological camera (3mpx) and LAS software version 4.2 (2012).

Results

Following the endoscopic examination, areas of moderate congestion were observed in the pyloric area (Figure 2), the retroflexion did not show neoplasms on the region of the small curvature (here gastric tumor formations are usually hidden) (Figure 3); In the first duodenal part, the mucosa had a proliferative, degenerative appearance (Figure 4), in order to highlight a less modified mucosa macroendoscopically (Figure 5).

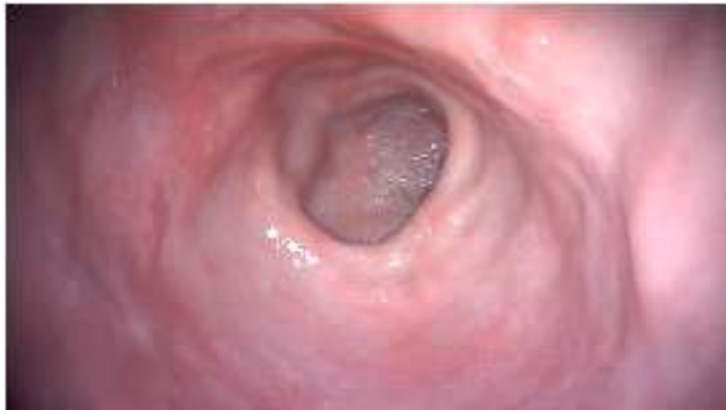

Fig. 2 - Pyloric orifice with slightly modified mucosa - reddish areas appear, with an inflammatory appearance (congestion)

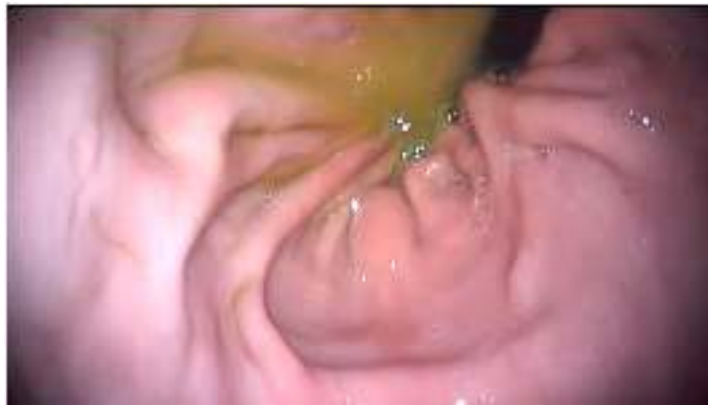

Fig. 3 - Endoscopic retroflexion maneuver to visualize the small curve - normal appearance

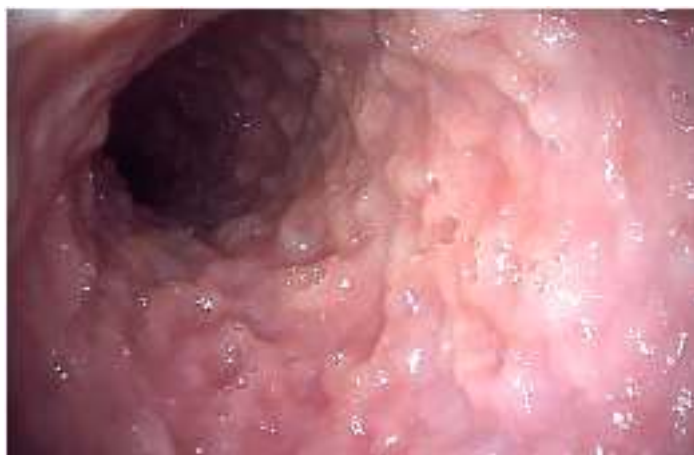

Fig. 4 Endoscopic image of the first duodenal third - proliferative pathological aspect of the mucosa, with ulcers and the absence of the intestinal cilia.

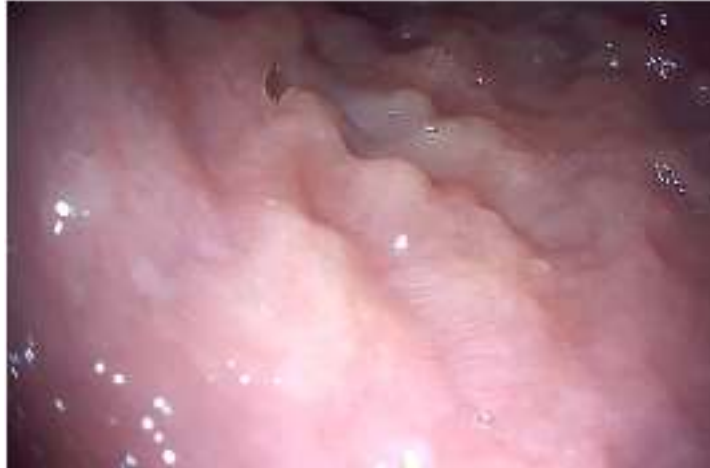

Fig. 5 Endoscopic image of the duodenal mucosa less affected - areas with cilia are observed.

Rapid testing directly from the gastric mucosa for the detection of *Helicobacter pylori* had a false negative result, as histological examination revealed helical bacteria in the duodenal (Figure 6) and gastric (Figure 7) submucosa.

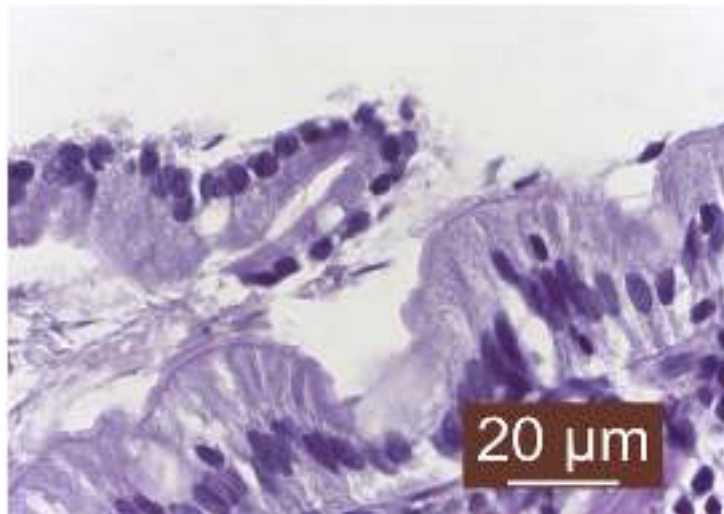


Fig. 6 Multiple *Helicobacter pylori* anchored in the duodenal mucosa

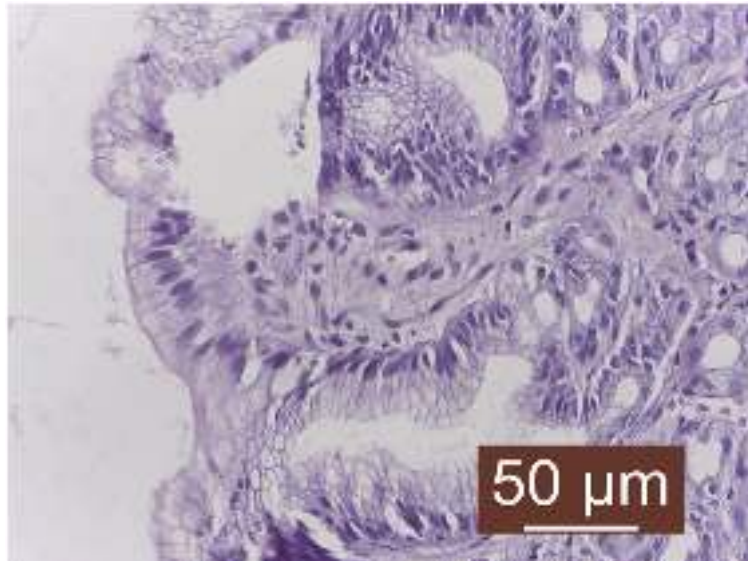


Fig. 7 Hyperplastic gastritis with evidence of *Helicobacter pylori*

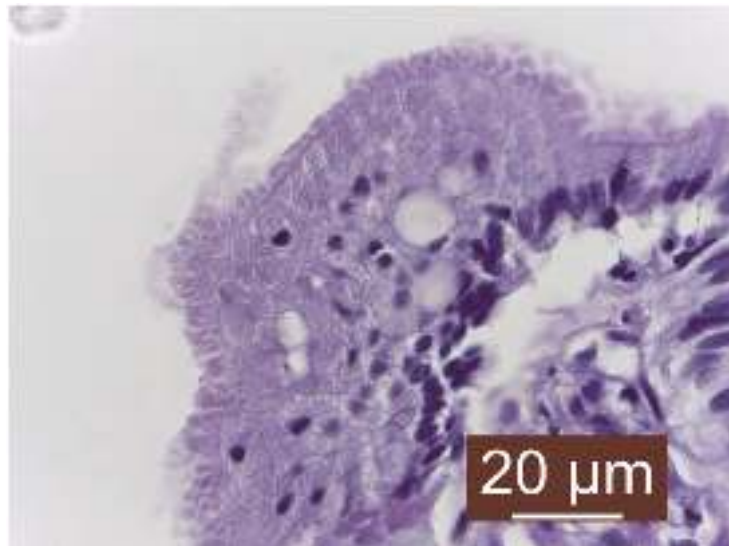

Fig. 8 Epithelial dysplasia (preneoplastic lesion) of the mucosa (intestinal epithelial cells are unorganized, with loss of polarity and arranged in several layers)

Discussions

In the case of diseases of the digestive tract, if the symptomatic treatment does not obtain positive results of the patient's condition, endoscopy is a minimally invasive method of diagnosis. Endoscopy can assess the appearance, integrity of the lining of the esophagus, stomach and intestines and biopsy can be taken for histological examination. Given the histological protocol, rapid tests in the gastric mucosa to detect the presence of *Helicobacter pylori* offer the possibility of instituting treatment to eliminate the bacterium and to partially remit the symptoms of the infection.

Although the rapid test had a false negative result, it was decided to continue treatment with metronidazole (7.5 mg / kg twice daily), with additional amoxicillin (12.5 mg / kg twice daily), omeprazole (1 mg / kg, twice daily before meals) and probiotics for 21 days (standard treatment). In this case report, the histological result was conclusive for *Helicobacter pylori* infection, with helical bacteria present in the gastric and duodenal epithelium, along with other lesions (areas of focal pyloric congestion, proliferative appearance of the duodenal mucosa, lack or very low number of intestinal cilia).

Conclusions

Any digestive disorder requires thorough investigation to have a definite diagnosis. Blood tests, ultrasound and radiological examination, pre-anesthetic consultat (EKG, tensiometry) are essential for endoscopic examination. Vomiting, loss of appetite and progressive weight loss are symptoms that require endoscopic evaluation and mandatory biopsy. It is not examined only macroendoscopically, as most of the time the lesions are deep, and the histological examination is meant to confirm a suspicion of digestive pathology. It should be noted that some patients with helicobacterial gastritis may have false negative tests. It is not excluded that patients with rapid positive tests and histologically missing helical bacteria; in this case the degree of infestation and the place of sampling of the biopsy are important. Therefore, investigations should be continued through detailed histological analysis.

Bibliography

1. *GUT Pathogens*, 2015 – research - Presence and significance of *Helicobacter* spp. in the gastric mucosa of Portuguese dogs
2. *Journal of Comparative Pathology*, vol. 154, 2016 – Canine gastric Pathology: A Review, pag. 9-37
3. *Kubota-Aizawa S et al., Vet Journal* 2017 - Epidemiological study of gastric *Helicobacter* spp. with gastrointestinal disease in Japan and diversity of *Helicobacter heilmannii* sensu stricto, PMID 28720300
4. *Paula R. Giaretta, Jan S. Suchodolski, Albert E Jergens, Jorg M Steiner, Jonatha A Lidbyry, Audrey K Cook, Mohsen Hanifeh, Thomas Spillmann, Susanne Kilpinen, Pernilla Syrja, Raquel R Rech*, 2020 – Bacterial biogeography of the colon in dogs with chronic inflammatory enteropathy