

The helminth fauna of some invasive fishes from various natural and artificial water bodies from the Republic of Moldova

Ion GOLOGAN

Institute of Zoology

1, Academiei str., Chișinău, MD-2028, Republic of Moldova

Phone: +37368901883

E-mail: ionelgologan@outlook.com

Abstract

This paper presents the results of the study of the helminth fauna of invasive fish species from different water bodies from the Republic of Moldova: prussian carp – *Carassius gibelio* (Bloch, 1782), stone moroko – *Pseudorasbora parva* (Temminck & Schlegel, 1846), chinese sleeper – *Perccottus glenii* Dybowski, 1877, pumpkinseed – *Lepomis gibbosus* (Linnaeus, 1758), silver carp – *Hypophthalmichthys molitrix* (Valenciennes, 1844), bighead carp – *Hypophthalmichthys nobilis* (Richardson, 1845). As a result of this study 16 species were detected (*Dactylogyrus* sp., *Gyrodactylus* sp., *Diplozoon paradoxum*, *Eudiplozoon nipponicum*, *Phyllodistomum folium*, *Diplostomum spathaceum*, *Bothriocephalus opsariichthydis*, *Khawia parva*, *Paradilepis scolecina*, *Philometroides sanguinea*, *Pseudocapillaria tomentosa*, *Raphidascaris acus*, *Posthodiplostomum cuticola*, *Valipora campylancristrota*, *Ligula intestinalis*).

Keywords: water bodies, helminths, invasive fish

Introduction

Under the direct action of anthropogenic factors, as well as under the influence of climate change, significant disturbances in the structure of local ichthyocenosis can occur. In a degraded environment, negative processes take place in a much more accelerated form, with invasive fishes capable of causing chain reactions such as: alteration of native fish species habitat, destabilization of host ichthyocenosis, genetic degradation of host fish stocks, introduction of new parasites and diseases, negative socio-economic effects [1,3].

Fish, as a vital source of food for people, in the conditions of a large development gap within countries, can be treated as a desired and economically valuable species (in least developed and developing countries), and on the other side, as an invasive and dangerous species (in developed countries). This is observed in the Republic of Moldova, where silver carp – *Hypophthalmichthys molitrix* (Valenciennes, 1844), bighead carp – *Hypophthalmichthys nobilis* (Richardson, 1845), grass carp – *Ctenopharyngodon idella* (Valenciennes, 1844) and prussian carp – *Carassius gibelio* (Bloch, 1782) are always desired, and, in the USA, were grass carp, silver carp, bighead carp, and wels catfish – *Silurus glanis* Linnaeus, 1758 are considered dangerous species for the ecological security of the country [2,5,6,7].

Invasive fish species are characterized by their rapid expansion in the primary area, naturalization in the receiving territories and major ecological and socio-economic damage. There are scientific data that demonstrate the impact of the invasive fish species over the native ichthyocenosis. Thus grass carp introduced in the Czech Republic caused major damage to common carp – *Cyprinus carpio* Linnaeus, 1758 by contaminating it with *Bothriocephalus gowkongensis*, round goby – *Neogobius melanostomus* (Pallas, 1814) spread *Bucephalus polymorphus* in the Danube river, prussian carp facilitated the spread of the monogenean species *Gyrodactylus shulmani* and *Gyrodactylus sprostonae*, and stone moroko (topmouth gudgeon) – *Pseudorasbora parva* (Temminck & Schlegel, 1846) caused the decrease of belica – *Leucaspis delineatus* (Heckel, 1843) and other cyprinids by spreading the parasite *Sphaerothecum destruens* [3,4]

Therefore, the aim of this study was to determine the level of infestation of the invasive species with helminths.

Materials and Methods

The ichthyological material (prussian carp, stone moroko, pumpkinseed, chinese sleeper, silver carp, bighead carp) necessary for this study was collected between 2017-2019 from different water bodies, during the period of vegetation favourable for the development of fish and parasite hosts, (Dniester river – lower sector of Dubăsari reservoir, Lopatnic river – left tributary of the Prut river, Costești-Stânca lake, Bâc river, Rose Valley lake from Chișinău, Muzeul Satului lake from Chișinău, the ponds from Nimoreni and Fălești district).

The parasitological researches were performed in the laboratory of Parasitology and Helminthology of the Institute of Zoology, on live fishes, according to the standard method proposed by Skryabin K.I. (examination of all internal organs of the animal) and the method proposed by Dogel V.A. and modified by Bykhovskaia – Pavlovskaja [9,11]. The microscopy of the detected helminths was performed using the stereomicroscope MBS, as well the examination at the optical microscope Novex Holland B, as fresh preparation slide-coverglass, with the objective 10x and ocular WF10X DIN/20MM. The detected helminths were identified using the keys written by Bauer [8], and stored in 70% ethanol and Barbagallo solution (formalin 3% + saline solution). For the parasitological evaluation, extensivity (%) and intensivity of invasion were used.

Results and discussions

The study of the helminth fauna of the prussian carp from the Dniester river (lower sector of Dubăsari reservoir), Costești-Stânca lake, Bâc river, revealed an infestation with helminths classified in 4 classes (Monogenea, Trematoda, Cestoda, Chromadorea), 11 families (Dactylogyridae Bychowsky, 1933, Gyrodactylidae Cobbold, 1864, Diplozoidae Palombi, 1949, Gorgoderidae Loos, 1899, Diplostomidae Poirier, 1886, Lytocestidae Hunter, 1927, Bothriocephalidae Blanchard, 1849, Gryporhynchidae Spassky & Spasskaya, 1973, Capillariidae Zedder, 1800, Philometridae Baylis et Daubney, 1926, Raphidascarididae Hartwich, 1954) and 12 genera (*Dactylogyrus*, *Gyrodactylus*, *Diplozoon*, *Eudiplozoon*, *Phyllodistomum*, *Diplostomum*, *Khawia*, *Bothriocephalus*, *Paradilepis*, *Pseudocapillaria*, *Philometroides*, *Rhaphidascaris*).

The specimens of prussian carp collected from Dniester river (lower sector of Dubăsari reservoir) were infested with monogeneans – *Dactylogyrus* sp. (EI-38.57%, II-1-64 ex.), *Eudiplozoon nipponicum* (EI-4.28%, II-1 ex.), and trematodes – *Phyllodistomum folium* (EI-2.85%, II-1-3 ex.), *Diplostomum spathaceum* (EI-21.4%, II-1-6 ex.). Monoinvasions were present in 47,07% of the examined specimens, and mixed invasions in 52.93%.

The detected monogeneans (*Dactylogyrus* sp. and *Eudiplozoon nipponicum*) are geohelminths which parasitize on the gills. They are hermaphrodites, oviparous, and pass from one fish to another without the need for an intermediate host. The biohelminths were represented by trematodes *Phyllodistomum folium* and *Diplostomum spathaceum*. *Phyllodistomum pholium* parasitizes in the ureters, and the intermediate host is the aquatic mollusk *Dreissena polymorpha*. *Diplostomum spathaceum* is a trematode that parasitizes in the fishes eye's lense, and the intermediate hosts represented by mollusks of the genus *Radix* and *Lymnaea*.

The result of the study of helminth fauna of the prussian carp captured from the Costești-Stânca lake, revealed an infestation with helminths from Monogenea class - *Dactylogyrus* sp. (EI-27.27%, II-1-5 ex.), Cestoda class - *Paradilepis scolecina* (EI-11.36%, II-2-6 ex.), *Khawia parva* (EI -2.27%, II-1 ex.), *Bothriocephalus opsariichthydis* (EI-2.27%, II-1 ex.); Chromadorea class - *Rhaphidascaris acus* (EI-6.81%, II-1 ex.). Monoinvasions were present in 25.0% of cases, and in 75.0% of cases mixed invasions were detected 75,0%. Mixtinvasions consisted of associations of two species (*Dactylogyrus* sp. + *Paradilepis scolecina*).

Out of the total helminths detected in the prussian carp from Costești-Stânca lake, 80.0% were represented by biohelminths (*Paradilepis scolecina*, *Bothriocephalus opsariichthydis*, *Raphidascaris acus*) and 20.0% only by geohelminths (monogeneans). *Bothriocephalus opsariichthydis* (syn. *B. gowkongensis*) (fig.1) is an alogene helminth which was introduced with Asian carps (silver carp, bighead carp and grass carp) in 1961 [10].

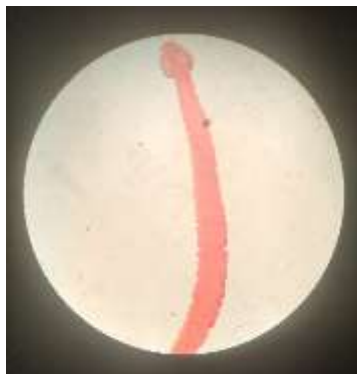
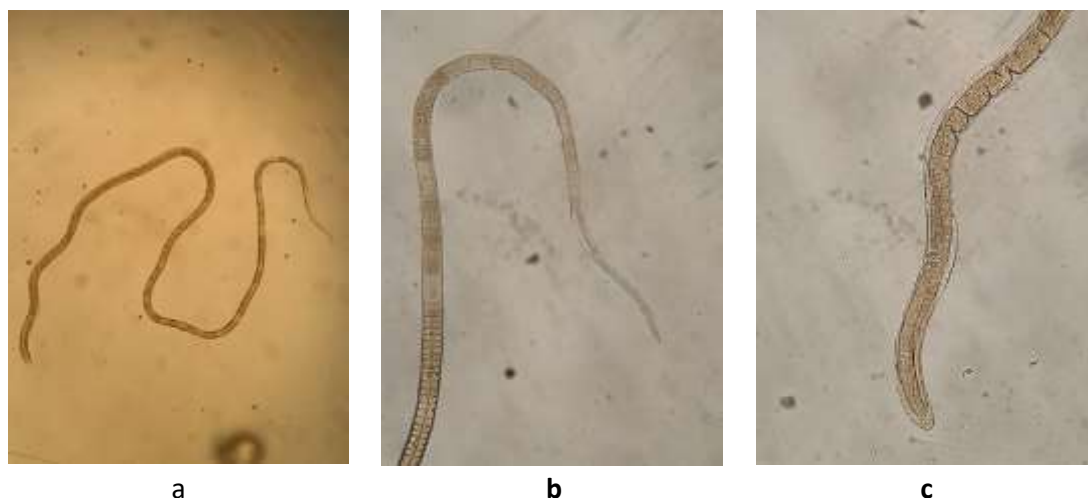


Fig.1 *Bothriocephalus opsariichthydis* found in intestine of a prussian carp (Carmin stain)

The helminth fauna of prussian carp from the Bâc river included parasites from Monogenea class - *Dactylogyrus* sp. (EI-100%, II-29-153 ex.), *Gyrodactylus* sp. (EI-57.89%, II-4-15 ex.), *Diplozoon paradoxum* (EI-36.84%, II of 1-7 ex.), Trematoda class - *Diplostomum spathaceum* (EI-63.15%, II-1-3 ex.), Enoplea class - *Pseudocapillaria tomentosa* (fig.2) (EI-18.94%, II-2-5 ex.) (fig.2).



a

b

c

Fig.2 *Pseudocapillaria tomentosa*

a) general view b) anterior part of the body c) posterior part of the body

Out of the total helminths detected in the prussian carp from Bâc river, 60% were represented by geohelminths (*Dactylogyrus* sp., *Gyrodactylus* sp., *Diplozoon paradoxum*) and 40% by biohelminths (*Diplostomum spathaceum*, *Pseudocapillaria tomentosa*). Mixed invasions were represented by 2, 3, 4 associations of helminths (*Dactylogyrus* sp. + *Gyrodactylus* sp.;

Dactylogyrus sp. + *Diplozoon paradoxum*; *Dactylogyrus* sp. + *Gyrodactylus* sp. + *Diplozoon paradoxum*, *Dactylogyrus* sp. + *Gyrodactylus* sp. + *Pseudocapillaria tomentosa*).

The research of the helminth fauna of stone moroko from various water bodies from the Republic of Moldova (Costești-Stânca lake, Bâc river, Lopatnic river, lake Muzeul Satului), revealed its infestation with helminths systematically classified in 2 classes (Trematoda, Cestoda), 3 families (Diplostomidae Poirier, 1886, Gryporhynchidae Spassky & Spasskaya, 1973, Capillariidae Zeder, 1800) and 5 genera (*Posthodiplostomum* Dubois, 1936, *Paradilepis* Hsü, 1935, *Valipora* Linton, 1927, *Pseudocapillaria* Freitas, 1959, 19)

Stone moroko from Bâc river was infested with cestodes *Paradilepis scolecina*, *Valipora campylancristrota* and nematodes *Pseudocapillaria tomentosa*. *Paradilepis scolecina* and *Valipora campylancristrota* were found in larval stage. The prevalence and intensity of invasion of stone moroko with these parasites were: *Paradilepis scolecina* (EI-30.0%, II-1-2 ex.); *Valipora campylancristrota* (EI-30.0%, II-1 ex.); *Pseudocapillaria tomentosa* (EI-70.0%, II-1-3 ex.). Parasitic invasions in 90,0% of cases were represented by monoinvasions (in one case *Pseudocapillaria tomentosa* was detected, and in another case *Valipora campylancristrota*), and in 10.0% of cases by mixed invasions (*Paradilepis scolecina* + *Valipora campylancristrota* + *Pseudocapillaria tomentosa*).

The parasitic invasions of stone moroko from the Lopatnic river and the lake Muzeul Satului was represented by monoinvasions. The captured specimens were sporadically infested with *Posthodiplostomum cuticola* and *Hepaticola petruschewski*. In the case of infested stone moroko from the Lopatnic river, the metacercariae of *Posthodiplostomum cuticola* inside the cyst were not viable, possible due to host's immune system that increases with age.

The helminthological study of 133 specimens of chinese sleeper (*Perccottus glenii* Dybowski, 1877) from the Lopatnic river revealed the presence of the nematode *Hepaticola petruschewskii* Schulman, 1948 which was detected inside the liver and intestine. The prevalence was 53.58% and the intensity of invasion 5-20 parasites. This nematode is very dangerous for pond fish (common carp, silver carp, grass carp), and can cause mass infestations with a prevalence above 90%. In hepaticolosis pathologic changes are observed in infested fish – disorders of the structure and consistency of the liver, its mosaicism, presence of punctate hemorrhages, destructive changes in hepatocytes. The importance of detecting the nematode *Hepaticola petruschewskii* lies in the fact that chinese sleeper and other invasive fishes act as a vector in the spread of this parasite, thus being dangerous for economically valuable fishes.

As a result of the study of the helminth fauna of the pumpkinseed (*Lepomis gibbosus*, Linnaeus, 1758) from lake Muzeul Satului, it was established that it was infested with *Diplostomum spathaceum* and *Hepaticola petruschewski*. In the specimens captured from the lake Muzeul Satului, the level of infestation with these helminths was: *Diplostomum spathaceum* located in the lens of the eyeball (EI-2.98%, II-1 ex.); *Hepaticola petruschewski* (EI-58.20%, II-1-7 ex.). Parasitic invasions consisting of a species of helminths were present in 5.13% of cases (infestation infestation with *Hepaticola petruschewski*), and in 94.87% of cases, parasitic invasions were represented by mixed invasions.

The pumpkinseed from Rose Valley lake, unlike the one from the Muzeul Satului lake, was infested only with *Diplostomum spathaceum* (EI-81.25%, II-1-7 specimens).

The study of the helminth fauna of silver carp from the pond from the "Codrii" natural forest reserve highlighted an infestation with trematodes from the genus *Diplostomum* von Nordman, 1832 (fig.3) parasitizing in the lens of the eyeball. The extensivity of invasion with this helminth was 60.0%, and the intensity of the invasion 1-130 specimens. The disease caused by metacercariae of these helminth is called diplostomiasis. Specific for diplostomiasis are the acute

form and the chronic form. The acute form, caused by *cercariae*, is very dangerous for juveniles. Punctate hemorrhages on the skin and mass death of juveniles are specific for the acute form. The chronic form, which is also called *worm cataract*, is caused by *metacercariae*, and due to local inflammatory processes, eye cataract occurs, as a result of which fish feeds poorly, becomes cachectic and dies.

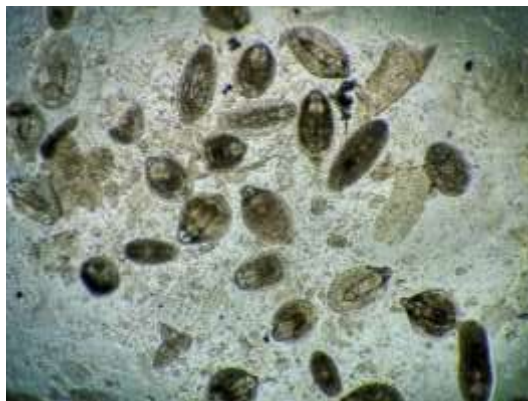

Fig.3 *Diplostomum* von Nordman, 1832 found in the lens of the silver carp

In a pond of Fălești district, a case of massive infestation of the silver carp with plerocercoids of the *Ligula intestinalis* was detected (fig.4). The prevalence was high, above 90%, with intensity of invasion of 3 and more plerocercoids per fish. In ligulosis, fish swim more on the surface of the water, being prone to be eaten by fish-eating birds. The plerocercoid, which parasitizes in the abdominal cavity, by the pressure it generates, causes atrophy of the internal organs, such as gonads, becoming sterile, or penetrates the wall of the abdominal cavity that leads to the death of fish.



Fig.4 Plerocercoids of *Ligula intestinalis* found in the abdominal cavity of a silver carp

The helminth fauna of bighead carp from Nimoreni pond (Pescăruș S.A) was represented by helminths systematically classified in 3 classes (Monogenea, Trematoda, Cestoda), 2 families (Dactylogyridae Bychowsky, 1933, Diplostomidae Poirier, 1886, Gryporhynchidae Spassky & Spasskaya, 1973) *Diplostomum* von Nordman, 1832, *Paradilepis* Hsú, 1935, *Valipora* Linton, 1927).

As a result of the study of the helminth fauna of bighead carp, it was established its infestation with helminths from Monogenea class - *Dactylogyrus* sp. parasitizing on gills (EI-91.67%, II-2-28 ex.), Trematoda class - *Diplostomum spathaceum* in the lens of the eyeball (EI-

44.44%, II-2-38 ex.), Cestoda class - *Paradilepis scolecina* in liver (EI-8.33%, II-1 ex.), and *Valipora campylancristrota* located in the gallbladder (EI-44.44%, II-1-6 specimens). The parasitic invasions represented by monoinvasions were present in 27.27%, of cases and in 72.73% of cases the parasitic invasions were represented by mixed invasions. Mixed invasions consisted of 2 and 3 associations of helminth species (*Dactylogyrus* sp. + *Diplostomum spathaceum*; *Dactylogyrus* sp. + *Valipora campylancristrota*; *Dactylogyrus* sp. + *Diplostomum spathaceum* + *Valipora campylancristrota*; *Dactylogyrus* sp.+ *Valipora campylancristrota*+ *Paradilepis scolecina*).

Conclusions

The study of the helminth fauna of the invasive fishes from various water bodies from the Republic of Moldova, revealed a different level of infestation with helminths. The most infested species were prussian carp (*Dactylogyrus* sp., *Gyrodactylus* sp., *Diplozoon paradoxum*, *Eudiplozoon nipponicum*, *Phyllodistomum folium*, *Diplostomum spathaceum*, *Botriocephalus opsariichthydis*, *Khawia parva*, *Paradilepis scolecina*, *Philometroides sanguinea*, *Pseudocapillaria tomentosa*, *Raphidascaris acus*) followed by stone moroko (*Posthodiplostomum cuticola*, *Paradilepis scolecina*, *Valipora campylancristrota*, *Pseudocapillaria tomentosa*, *Hepaticola petruschewski*). The less infested species were: bighead carp, silver carp, pumpkinseed and chinese sleeper. In future research it will be necessary to expand surveillance on protists and parasitic crustacean fauna.

Bibliography

1. Adrian Usatfii, Marin Usatfii, Ion Toderas [et al. ; Acad. de Științe a Moldovei, Inst. De Zoologie. – Chișinău: S. N., 2015 (F.E.-P. Tipografia Centrală). – 192 p. ISBN 978-9975-53-578-6 . 597.2/5(478)(03)
2. Allison W. Lenaerts, Alison A. Coulter, Zachary S. Feiner and Reuben R. Goforth. Egg size variability in an establishing population of invasive silver silver carp *Hypophthalmichthys molitrix* (Valencienne, 1844). In: Aquatic Invasions (2015) Volume 10, Issue 4: P. 449-461 <http://dx.doi.org/10.3391/ai.2015.10.4.08>
3. Bulat, D.M. Ihtiofauna Republicii Moldova: amenințări, tendințe și recomandări de reabilitare. Chișinău: Foxtrod, 2017. 343 p.
4. Hanel Lubomir, Plesnik Jan, Andreska Jan, Lusk Stanislav, Novak Jindrich&Plistil Jiri. Alien fishes in European Waters In: Bulletin Lampetra VII ZO CSOP VLASIM, 2011, p.148 – 185.
5. Reed Sakamoto. Pacific Northwes Aquatic Invasive Species Profile – Grass Carp *Ctenopharyngodon idella* http://depts.washington.edu/olednlab/wordpress/wp-content/uploads/2013/02/Ctenopharyngodon-idella_Sakamoto.pdf
6. *Silurus glanis* Ecological Risk Screening Summary. U.S. Fish and Wildlife Service – Web Version-8/14/2012 https://www.fws.gov/injuriouswildlife/pdf_files/Silurus_%20glanis_WEB_9-15-2014.pdf
7. Wilson J.R.U., Dormontt E.E., Prentis P.J., Lowe A.J., Richardson D.M. Something in the way you move: dispersal pathways affect invasion success B:Trends in Ecology and Evolution. 2009. V.24. N.3. P. 136-144.
8. Бауер О.Н. Определитель паразитов пресноводных рыб фауны СССР. Том 3. Издательство Наука. Ленинград. 1985.
9. Быховская-Павловская И.Е. Паразиты рыб. Руководство по изучению. Издательство Наука. Ленинград. 1985. p. 90-111.
10. Мариц, Н.М. Паразитофауна рыб водоемов Молдавии (трематоды). Паразиты животных и растений Молдавии, 1963. С. 35-50.
11. Скрыбин К.И. Метод полных гельминтологических вскрытий позвоночных, включая человека. М.: Изд-во МГУ, 1928. 45 с. 9.