

# Allergic contact dermatitis from resin-modified glass ionomers

Glynn Dale Buchanan, Sheree Tredoux, Mohamed Yasin Gamielien<sup>1</sup>

Department of Odontology, School of Dentistry, University of Pretoria, <sup>1</sup>Department of Maxillofacial and Oral Surgery, University of Pretoria, Pretoria, South Africa

## Abstract

Monomers in a variety of dental materials may cause allergic contact dermatitis. While resin materials have been implicated in the onset of this condition, there is a paucity of evidence linking the condition to the resin-modified glass ionomers (RMGIs). This report documents a rare case of a dentist who developed allergic contact dermatitis following exposure to a RMGI. Contact dermatitis occurred despite the use of latex gloves, which were worn during the procedure. Both the acute and chronic stages of the condition were clinically represented. Patch testing was conducted to confirm the diagnosis. A no-touch technique and the routine use of nitrile gloves were subsequently adopted, which resulted in an overall decrease of the condition. Dentists, auxiliary personnel, and students should be aware of the possibility of sensitization to, and the development of allergic contact dermatitis not only from conventional resin materials, but also from the RMGIs.

**Keywords:** Allergic contact dermatitis; gloves; latex; nitrile; resin-modified glass ionomer

## INTRODUCTION

Contact dermatitis is a skin condition that causes inflammation as a result of exposure to an environmental agent.<sup>[1]</sup> It is known that several dental materials can cause allergic contact dermatitis in individuals who are occupationally exposed to these products.<sup>[2]</sup> Examples of such materials include aromatic epoxy acrylate, such as bisphenol A-glycidyl dimethacrylate;<sup>[3]</sup> aliphatic acrylates, such as triethyleneglycol dimethacrylate (TEGDMA) and triethylene diglycol diacrylate (TREGDA) and methyl methacrylate;<sup>[2,4]</sup> and light-curable monomers, such as 2-hydroxyethyl methacrylate (HEMA), commonly found in dental bonding agents.<sup>[5,6]</sup> A rare case of allergic contact dermatitis to bisphenol A in a dental composite resin has also been reported.<sup>[7]</sup> The majority of these compounds are, therefore, found in conventional resin products.

### Address for correspondence:

Dr. Glynn Dale Buchanan, Oral and Dental Hospital, 31 Bophelo Road, Prinshof Campus, University of Pretoria, Riviera, Pretoria, 0002, South Africa.  
E-mail: glynn.buchanan@up.ac.za

Date of submission : 08.02.2019

Review completed : 13.05.2019

Date of acceptance : 18.06.2019

### Access this article online

#### Quick Response Code:



Website:  
www.jcd.org.in

DOI:  
10.4103/JCD.JCD\_69\_19

The monomer HEMA is also found in the liquid component of resin-modified glass-ionomer (RMGI) restorative materials. However, to date, very few – if any – reports of allergic contact dermatitis have been attributed specifically to this class of dental materials.<sup>[6]</sup>

Here, we report a case of allergic contact dermatitis following exposure to Vitremer™, a light-cured RMGI cement containing HEMA. Ethical approval for this case report was obtained from the Research Ethics Committee, Faculty of Health Sciences, University of Pretoria (protocol number 765/2018).

## CASE REPORT

In May 2013, two dentists conducted restorative dental treatment on a pediatric patient under general anesthesia. During this time, Vitremer™ liquid and powder (RMGI, 3M Dental Products, St Paul, MN 55144, USA) were mixed manually prior to placement in the oral cavity.

While mixing the material, the assisting dentist – a 25-year-old male with noncontributory medical history – accidentally

This is an open access journal, and articles are distributed under the terms of the Creative Commons Attribution-NonCommercial-ShareAlike 4.0 License, which allows others to remix, tweak, and build upon the work non-commercially, as long as appropriate credit is given and the new creations are licensed under the identical terms.

**For reprints contact:** reprints@medknow.com

**How to cite this article:** Buchanan GD, Tredoux S, Gamielien MY. Allergic contact dermatitis from resin-modified glass ionomers. J Conserv Dent 2019;22:310-2.

spilled a moderate amount of the Vitremer™ liquid over the gloved fingers of the left hand. Latex gloves were worn during the entire treatment procedure. The treatment was completed uneventfully.

The following day, the dentist noted that the skin on the fingers of the left hand began to become erythematous and intensely pruritic. Over the next 3 days, closely set vesicles developed on the fingers of the left hand, sparing the dorsal and ventral surfaces [Figure 1a]. The vesicles were both pruritic and tender to touch and progressively worsened in intensity over the following days.

Approximately 1 week later, the skin of the left index finger became lichenified, appearing thickened and pigmented, as a result of chronic exposure to the material [Figure 1b]. The thickening was accompanied by altered sensation on the fingertip of the index finger.

Application of a topical antihistamine cream (Phenergan® topical cream) alleviated the pruritus caused by the vesicles.

The vesicles subsided after approximately 10 days and at 2 weeks had resolved completely. The fibrous, thickened skin on the index finger resolved over a period of about 1 month, and normal sensation returned during this time period.

The dentist initially self-diagnosed the condition as allergic contact dermatitis and consulted a medical doctor for further treatment. The diagnosis was confirmed by skin patch testing using the Finn chamber method [Figure 2]. An extreme positive reaction with accompanying erythema, infiltration, and coalescing vesicles was noted during the patch test to Vitremer™, as well as Vitrebond™ (RMGI, 3M Dental Products, St Paul, MN 55144, USA).

Following the initial incident, the dentist adopted the routine use of nitrile gloves instead of latex and developed a no-touch approach to any uncured monomer when using all RMGI and resin products which may contain HEMA. Since adopting this approach, the overall incidence of allergic

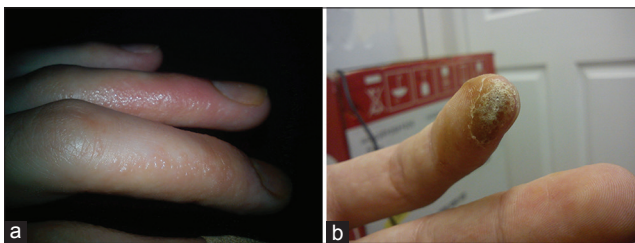
contact dermatitis reactions has decreased significantly. However, similar reactions continue to occur infrequently when contact is accidentally made with HEMA-containing materials.

## DISCUSSION

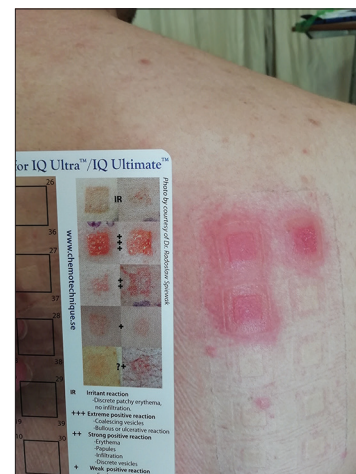Strong evidence exists that some RMGI cements may be severely cytotoxic as well as genotoxic. This is due to the fact that these materials contain and release substances such as HEMA and diphenyliodonium chloride. As a result of the inclusion of these chemicals, local or even systemic effects may result after exposure to these materials.<sup>[5]</sup>

Although previous studies have reported that dental resins can cause the development of allergic contact dermatitis, a 2008 review by Nicholson and Czarnecka did not find any published reports of dental personnel displaying symptoms of acrylate allergy specifically associated with the use of RMGI materials.<sup>[6]</sup> This case therefore represents a rarely reported allergic contact dermatitis directly associated with exposure to RMGI materials. To the authors' knowledge, no other case reports exist linking this condition to the RMGI material class. However, despite the scant nature of literature associated with the reaction, the authors are in agreement with Nicholson and Czarnecka's assertion that this reaction is likely more common than expected.<sup>[6]</sup> Future research efforts may be directed toward establishing the prevalence of this condition among restorative dentists.

Dentists, specialists, and dental auxiliary personnel often come into contact with resin-based materials as well as RMGIs for the provision of restorative treatment. RMGIs are commonly used in both restorative materials and luting cements. While gloves are almost always worn in the practice of modern dentistry, it is known that acrylates may



**Figure 1:** (a) Vesicles, papules, and erythema on the lateral aspects of the left hand fingers, representative of the acute phase of allergic contact dermatitis. (b) Thickened, lichenified skin on the left index finger, representative of the chronic stage of allergic contact dermatitis



**Figure 2:** Extreme positive reactions were found during patch testing to Vitrebond™ and Vitremer™

penetrate through both latex and vinyl gloves.<sup>[4,8]</sup> These precautions may therefore provide only limited protection against the development of allergic contact dermatitis. Nitrile and rubber gloves have been shown to provide better protection, specifically against the passage of HEMA,<sup>[8]</sup> and are therefore recommended when working with RMGI and resin materials.

Allergic contact dermatitis reactions to dental materials may occasionally be severe. Reports of dental nurses who could not continue their occupations due to the severity of the allergic contact dermatitis reaction exist.<sup>[2]</sup> The potential impact of such reactions in certain individuals should therefore not be underestimated.

## CONCLUSION

All dental practitioners, auxiliaries, and students should be aware of the risks of developing reactions such as allergic contact dermatitis from exposure to resin-based dental materials, including RMGIs. A no-touch technique and the use of protective gloves, made from nitrile, should be encouraged to help avoid adverse effects in sensitized individuals.

## Clinical significance

- RMGI dental materials containing HEMA may cause allergic contact dermatitis in dental personnel who are occupationally exposed to the materials. All dental practitioners and auxiliaries using this class of material should be aware of the possibility of the development of this condition
- Latex gloves provide only limited protection against the development of allergic contact dermatitis. A no-touch technique and the routine use of nitrile gloves may provide better protection in sensitized individuals.

## Declaration of patient consent

The authors certify that they have obtained all appropriate patient consent forms. In the form the patient(s) has/have given his/her/their consent for his/her/their images and other clinical information to be reported in the journal. The patients understand that their names and initials will not be published and due efforts will be made to conceal their identity, but anonymity cannot be guaranteed.

## Acknowledgments

The authors would like to thank Dr. Michael T. Boswell for his advice.

## Financial support and sponsorship

Nil.

## Conflicts of interest

There are no conflicts of interest.

## REFERENCES

1. Saint-Mezard P, Rosieres A, Krasteva M, Berard F, Dubois B, Kaiserlian D, *et al.* Allergic contact dermatitis. *Eur J Dermatol* 2004;14:284-95.
2. Kanerva L, Estlander T, Jolanki R. Allergic contact dermatitis from dental composite resins due to aromatic epoxy acrylates and aliphatic acrylates. *Contact Dermatitis* 1989;20:201-11.
3. Carmichael AJ, Gibson JJ, Walls AW. Allergic contact dermatitis to bisphenol-A-glycidylmethacrylate (BIS-GMA) dental resin associated with sensitivity to epoxy resin. *Br Dent J* 1997;183:297-8.
4. Kanerva L, Estlander T, Jolanki R, Tarvainen K. Occupational allergic contact dermatitis caused by exposure to acrylates during work with dental prostheses. *Contact Dermatitis* 1993;28:268-75.
5. Geurtsen W. Biocompatibility of resin-modified filling materials. *Crit Rev Oral Biol Med* 2000;11:333-55.
6. Nicholson JW, Czarnecka B. The biocompatibility of resin-modified glass-ionomer cements for dentistry. *Dent Mater* 2008;24:1702-8.
7. Jolanki R, Kanerva L, Estlander T. Occupational allergic contact dermatitis caused by epoxy diacrylate in ultraviolet-light-cured paint, and bisphenol A in dental composite resin. *Contact Dermatitis* 1995;33:94-9.
8. Andreasson H, Boman A, Johnsson S, Karlsson S, Barregård L. On permeability of methyl methacrylate, 2-hydroxyethyl methacrylate and triethyleneglycol dimethacrylate through protective gloves in dentistry. *Eur J Oral Sci* 2003;111:529-35.

Copyright of Journal of Conservative Dentistry is the property of Wolters Kluwer India Pvt Ltd and its content may not be copied or emailed to multiple sites or posted to a listserv without the copyright holder's express written permission. However, users may print, download, or email articles for individual use.