

Frequency of Acute and Late Reaction of Non-Ionic Iodinated Contrast Media in Contrast Enhanced Computed Tomography

Muhammad Ahmad Naeem¹ Humaira Rauf² Rabia Razzaq³

1.Lecturer, The University of Lahore, Gujrat Campus, Gujrat, Pakistan

2.Senior Lecturer, Department of Allied Health Sciences, Fatima Memorial Hospital, Lahore

3.Department of Allied Health Sciences, Riphah International University Lahore

ABSTRACT

Introduction: A contrast agent is a substance used to increase the contrast of structures or fluids within the body in medical imaging. Contrast agents absorb or alter external electromagnetism or ultrasound, and enhance the radio density in a target tissue or structure. Contrast agents are commonly used to improve the visibility of blood vessels and the gastrointestinal tract. Several types of contrast agent are in use in medical imaging and they can roughly be classified based on the imaging modalities where they are used and the purposes of this study to find out the frequency of adverse reactions of non-ionic iodinated contrast media in contrast enhanced Computed Tomography. **Material Methods:** It was cross-sectional observational study conducted on 133 patients who visited Al-Razi healthcare hospital, Lahore for a CT (computed Tomography) scan. 36 of them got adverse reactions to the non-ionic contrast media. The frequency of adverse reactions happening with the non-ionic contrast usage was determined. **Results:** In this study, one hundred and thirty-three patients who fulfilled the criteria were included in the study. 36 of the patients had adverse reactions to the non-ionic contrast media which included shivering, fatigue, headache, nausea and rashes. All of the patients had no previous history of allergies or contrast reactions. The mean age of patients ranged from 51.49 ± 16.19 years. **Conclusion:** In conclusion, the use of non-ionic contrast media as a CT contrast agent has a safety profile. It is concluded that a non-ionic iodinated contrast media reaction rarely results in long-term sequelae as it is less severe and easily treatable.

Keywords: Non-Ionic Iodine Contrast Media, Computed Tomography, Adverse Reactions

DOI: 10.7176/JHMN/88-05

Publication date: April 30th 2021

INTRODUCTION:

Radio contrast agents are considered as necessary elements of investigative radiology. Small differences in tissue densities of the body don't even allow optimal radiographic evaluation without administration of contrast or contrast enhancement. In short, after the discovery of x-rays by Roentgen, it was felt that enhancement of radio opacity was essential to get better contrast of images.(1) It became clear that high atomic number elements would increase x-ray images. Bismuth, lead, and barium salts were used to develop the first angiogram of an amputated hand, experiments that were published in 1896 by Haschek and Lindenthal in Vienna. These heavy metal salts weren't considered safe enough to be used in living humans. Few decades ago, modifications within the contrast agent's structure were continually sought in a struggle to reduce their toxicity; however, the search for the ideal contrast agent continues.(2) As a safe radio contrast agent, the invention of iodine was accidental. In the early 1920s, when compounds that contain iodine were used to treat syphilis, Osborne et al. observed that the urine of patients treated with iodine was radiopaque; they continue to perform the first successful clinical pyelogram in 1923 at the Mayo Clinic. In the same year, Berberich and Hirsch successfully employed strontium bromide to perform a femoral angiogram. In 1924 Brooks used sodium iodide to perform an angiogram.(3) (4)

1.2 Contrast Media

Contrast materials are chemical substances having very high or very low atomic number or weight, therefore it increases or decrease the density of the organ under study. Contrast agents help distinguish or "contrast" selected areas of the body from surrounding tissue.(5) Contrast materials are considered as safe drugs; adverse events ranging from mild to severe do occur but severe reactions are very uncommon.(6) Instead, serious allergic or other reactions to contrast materials are very rare, radiology departments are well-equipped to deal with these conditions

1.2.2.1 Iodinated (Intravascular) Contrast

Iodinated contrast media are contrast media which consists of iodine atoms that are useful for x-ray based imaging modalities as computed tomography (CT), however they can also be used in angiography, venography, plain radiography and angiography(7). The route of administration as intravenous is most common, other routes can also be used including gastrointestinal (oral, rectal), cysto urethral, vaginal etc. The ability to differentiate between tissues of different x-ray attenuation (image contrast) depends upon two types of interactions between photons and matter: Compton scattering and photoelectric absorption.(8) The atomic no of iodine is 53, the

administration of iodinated contrast media produces image contrast because of differential photoelectric absorption, in comparison to most tissues in the body(9)

1.2.2.2 Ionic Contrast

Ionic contrast media generally, not always, have higher osmolality and more side-effects. For example, Diatrizoate (Hypaque 50/ Gastrografin), Metrizoate (Isopaque 370), iothalamate (Conray), ioxaglate(10)

1.2.2.3 Non- Ionic Contrast

Non-ionic contrast media have lower osmolality and tend to have less side-effects. For example, iopamidol (Isovue 370), iohexol (Omnipaque 350), ioxilan (Oxilan 350), iopromide (Ultravist 370), iodixanol (Visipaque 320), ioversol.(11)

1.2.2.4 Barium (gastrointestinal)

Barium suspension is made of pure barium sulfate. However, particles of barium should be small (0.1-3 μ m), so that it makes them stable in suspension. Barium sulfate is principally utilized in the imaging of the digestive system. The substance is in a form of water-insoluble white powder and preparation will be diluted with water and administered directly into the gastrointestinal tract.(12) Barium sulfate, an insoluble white powder is usually used for enhancing contrast in the GI tract. As the barium sulfate doesn't dissolve, this sort of contrast agent is an opaque white mixture. It's solely utilized in the digestive tract; it's typically swallowed or administered as an enema. After the examination, it leaves the body with the feces.

1.2.2.5 Air & Carbon Dioxide

Both air and barium are used along (hence the term "double-contrast" barium enema) air can be used as a contrast material because it's less radio-opaque than the tissues it is defining. An example the injection of air into a joint cavity permits the cartilage covering the ends of the bones to be visualized.(13) Carbon dioxide also has a role in angiography. It is low-risk as it is a natural product with no risk of allergic potential. However, it can be used solely below the diaphragm as there's a risk of embolism in neurovascular procedures. It must be used carefully to avoid contamination with room air once injected. It is a negative contrast agent in that it displaces blood when injected intravascular(13, 14)

1.4.1 X-Ray

X-ray is a type of electromagnetic radiation that creates the picture of inside of the body. It gives shades of black and white because of absorption of different amount of radiation in various tissues of the body. Bones appear white as it absorbs much radiation while fat and other tissue appear grayish. Air absorbs least radiation and therefore appears black. One must wear lead apron in order to protect body from the radiations(15)

1.4.2 Computed Tomography Scanning with Contrast

Many types of CT require an injection of an iodinated contrast material to show blood vessels and some organs. For these tests, most hospital departments or radiology practices will ask you to fast (not eat or drink) before your appointment. Fasting for 2-4 hours is common, and it is usually permitted to drink water over this time to avoid dehydration(16). It is important that the need to fast does not make you unwell, notably if you have other special dietary requirements (e.g. diabetes). Please check with your doctor or the hospital or radiology practice where you are having the CT if you have any concerns. If you do require an iodinated contrast injection for your test, it is likely that you will be taken into an area where a radiologist, a radiographer or a nurse will discuss iodine contrast with you. They will then use a needle to insert a cannula (a small plastic tube) into a vein in your arm or the back of your hand so that the iodine contrast can be inserted into the cannula during the test. The radiographer carrying out the scan may ask you to hold your breath for some scans. The length of time for every breath hold is usually under 10 seconds. When the iodinated contrast is injected, most people will get a strange metallic taste in the mouth and feel a warm sensation through the body(16). This warm sensation may concentrate around the groin or buttock region and can feel like you may have wet yourself, even though you have not. Do not be concerned if this happens, it is a common sensation and usually goes away within a couple of minutes. Once the radiographer has reviewed the images briefly to check that the appropriate areas have been shown, they will come into the room to assist you off the bed, check if you are feeling well, remove your cannula and then send you home.

1.4.3 Fluoroscopy

It is an imaging modality in which x-rays are used to permit real time imaging of body structures. During this fluoroscopic procedure, continuous emission of x-rays occurs and due to this, dynamic image of specific body structure is captured by the screen. Different contrast materials (High-density or low-density) may administered into the patient body to permit differentiation between structures. It includes barium studies such as barium swallow, barium meal and follow-through, barium enema for assessment of the gastro-intestinal tract etc.(17)

1.4.4 MRI

It is abbreviated as Magnetic Resonance Imaging. The hydrogen nuclei in the patient, protons, act as small magnets. In MR system, when a patient is placed in a static magnetic field, protons align themselves according to the magnetic field. Magnet is like a huge cylinder like device, which accommodates patient during imaging procedure. RF coils surround the patient like gradient coils, shim coils etc. An MRI operating console has certain

controls for the timing of RF pulses rather than kilovolt peak and mill ampere as in CT and X ray operating console(14)

1.4.5 Nuclear Medicine

Nuclear medicine imaging is a branch of medicine which deals with the use of un-sealed radiation sources in the diagnosis and treatment of diseases. It uses radiotracers or radiopharmaceuticals that are injected intravenously into the blood of patient, inhaled or swallowed(18). Nuclear medicine imaging procedures are noninvasive and are usually painless medical procedure that help physicians to diagnose medical conditions. Radiotracers are molecules labelled with a small amount of radioactive material that can be detected on the PET scan. They are made to accumulate in cancerous tumors or regions of inflammation.(18) They can also be made to bind to specific proteins in the body. The most commonly used radiotracer is F-18 fluorodeoxyglucose, or FDG

MATERIAL METHODS

It was a cross-sectional observational study conducted on 133 patients with expected rate of 14.3% Adverse Reactions at 5% level of significance and 5% margin of error that fulfilling the inclusion criteria from the radiology department of Al-Razi healthcare hospital, Lahore. The details of study were explained to the patients that there was no risk involved in the study. An informed consent was obtained from all the patients. Spiral CT was used. Principle of x-rays and ionizing radiation is used with multiple detectors that increase the speed of Image reconstruction. A cannulation of 18 or 22 gauge is inserted into the patient's arm and is asked to lie supine on the table. The position of the patient is adjusted and the prescribed procedure is begun.

RESULTS

One hundred and thirty-three patients who fulfilled the criteria were included in the study. 36 of the patients had adverse reactions to the non-ionic contrast media which included shivering, fatigue, headache, nausea and rashes. All of the patients had no previous history of allergies or contrast reactions. The mean age of patients ranged from 12 to 90 years with a mean of 51.49 ± 16.19 years as shown in (figure no. 1).

Out of 133 patients, 80 (60.2%) males and 53 (39.8%) females were included for the study as shown below in the table as well as the pie chart as shown in (figure 4 and 5). respectively. Out of 133 patients, 36 (36%) patients reacted to non-ionic iodine contrast media which included Shivering, Fatigue, Headache, Nausea and Rashes. Tables as well as charts given below show the reactions on different age groups as represent in (figure 6 and 7) respectively.

Out of 133 patients, 80 (60.2%) males and 53 (39.8%) female's patients were included and 36 of both the genders had adverse reactions.

DISCUSSION

Contrast materials, also called contrast agents or contrast media, are used to highlight pictures of the inside of the body produced by x-rays, computed tomography (CT), magnetic resonance (MR) imaging, and ultrasound. Often, contrast materials enable the radiologist to distinguish normal from abnormal conditions. Contrast materials are not dyes that permanently discolor internal organs. There are substances that temporarily change the way x-rays or other imaging tools interact with the body. Once introduced into the body prior to an imaging exam, contrast materials make certain structures or tissues within the body appear different on the images than they would if no contrast material had been administered. Contrast materials help distinguish or "contrast" selected areas of the body from surrounding tissue. By improving the visibility of specific organs, blood vessels or tissues, contrast materials facilitate physicians diagnose medical conditions.

Non-ionic contrast media have lower osmolality and tend to have fewer side-effects. For example, iopamidol (Isovue 370), iohexol (Omnipaque 350), ioxilan (Oxilan 350), iopromide (Ultravist 370), iodixanol (Visipaque 320), ioversol.

This study is conducted to determine the frequency of adverse reactions of non-ionic iodine contrast media in contrast enhanced computed tomography. In this study one hundred and thirty-three patients were taken as a sample who fulfilled the criteria involved in the study. The age of the patients ranged from 12-90 years with a mean of 51.49 ± 16.193 years as shown in (figure no 1). In these 133 patients 36 patients had adverse reaction to the non- ionic iodine contrast media and rest of the 97 patients had no reaction at all as elaborated in (figure 6 and 7). Of these patients 80 (106.4%) were Male patients and 53 (70.49%) Female patients.

CONCLUSION

In conclusion, use of non-ionic contrast media as a CT contrast agent has a safety profile. It is concluded that a non-ionic iodinated contrast media reaction rarely results in long-term sequelae as it is less severe and easily treatable.

FIGURES:

Figure: 1 **Mean Age of Patients**

Mean	Std. Deviation	Range	Minimum Value	Maximum Value
51.49	16.193	78	12	90

One hundred and thirty-three patients who fulfilled the criteria were included in the study. 36 of the patients had adverse reactions to the non-ionic contrast media which included shivering, fatigue, headache, nausea and rashes. All of the patients had no previous history of allergies or contrast reactions. The mean age of patients ranged from 12 to 90 years with a mean of 51.49±16.19 years as shown in (Table No. 1).

Figure 2: **Age distribution of the patient**

Age	Frequency	Percentage
Younger (<20 years)	5	3.8%
Young Adults (20-40 Years)	28	21.1%
Adults (41-60 Years)	54	40.6%
Older (>60 years)	46	34.6%

Different age groups were included for this study are shown below in the table as well as the pie chart stating 3.8% are younger group less than 20 years, 21.1% are young adults between 20-40 years, 40.6% are adults between 41-60 years & 34.6% are in the group older that are above 60 years.

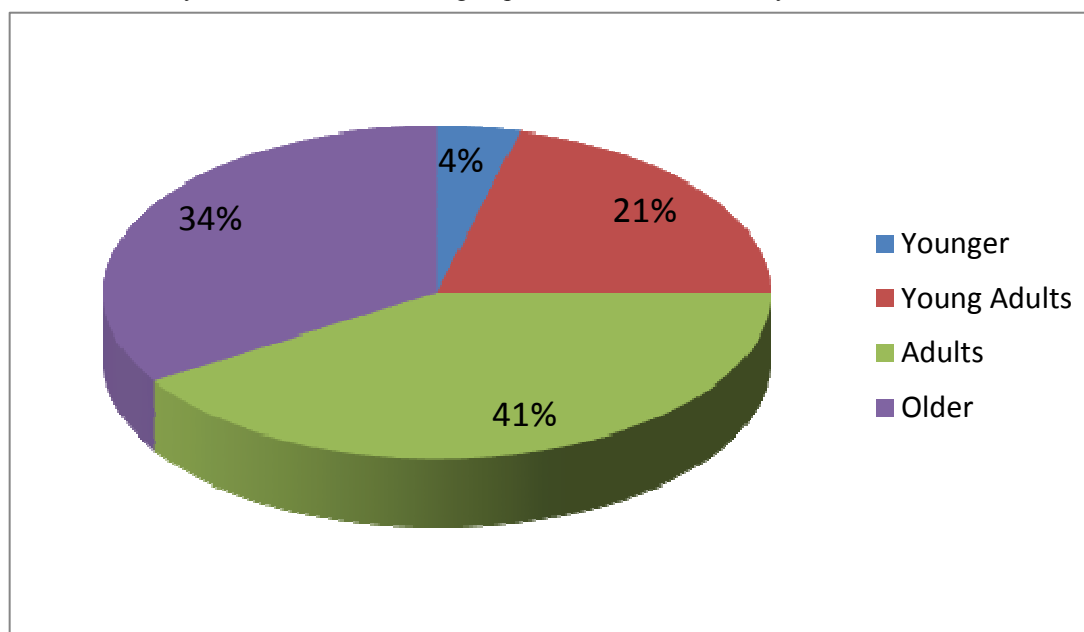


Figure: 3 **Age distribution of the patient**

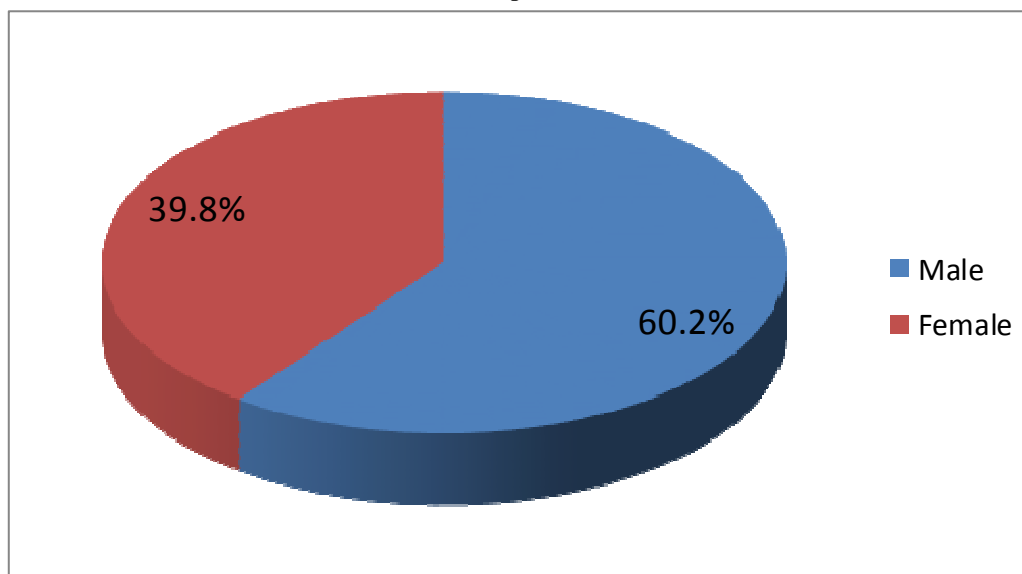
Gender Percentage

Figure: 4 **Gender distribution of the patient**

Gender	Frequency	Percentage
Male	80	60.2%
Female	53	39.8%

Out of 133 patients, 80 (60.2%) males and 53 (39.8%) females were included for the study as shown below in the table as well as the pie chart.

Figure: 5 Gender distribution of the patient



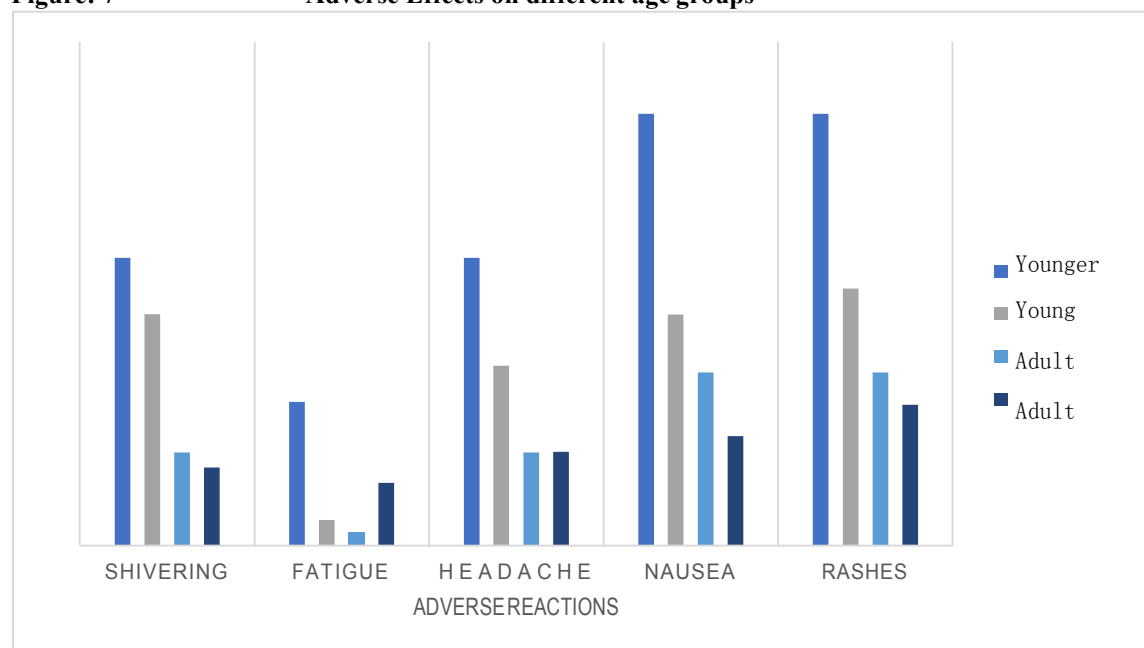
Adverse Effects: -

Figure: 6 Adverse Effects on different age groups

Allergic Reactions	AGE GROUPS			
	Younger	Young Adults	Adults	Older
Shivering	2(40.0%)	9(32.1%)	7(13.0%)	5(10.9%)
Fatigue	1(20.0%)	1(3.6%)	1(1.9%)	4(8.7%)
Headache	2(40.0%)	7(25.0%)	7(13.0%)	6(13.0%)
Nausea	3(60.0%)	9(32.1%)	13(24.1%)	7(15.2%)
Rashes	3(60.0%)	10(35.7%)	13(24.1%)	9(19.6%)

Out of 133 patients, 36 (36%) patients reacted to non-ionic iodine contrast media which included Shivering, Fatigue, Headache, Nausea and Rashes. Tables as well as charts given below show the reactions on different age groups.

Figure: 7 Adverse Effects on different age groups



REFERENCES

1. Hahn MA, Singh AK, Sharma P, Brown SC, Moudgil BM. Nanoparticles as contrast agents for in-vivo

bioimaging: current status and future perspectives. Analytical and bioanalytical chemistry. 2011;399(1):3-27.

2. Laurent S, Henoumont C, Stanicki D, Boutry S, Lipani E, Belaid S, et al. MRI Contrast agents: from molecules to particles: Springer; 2017.
3. Quader MA, Sawmiller CJ, Sumpio BE. Radio contrast agents: history and evolution. Textbook of angiology: Springer; 2000. p. 775-83.
4. Lee N, Choi SH, Hyeon T. Nano - sized CT contrast agents. Advanced Materials. 2013;25(19):2641-60.
5. Lusic H, Grinstaff MW. X-ray-computed tomography contrast agents. Chemical reviews. 2013;113(3):1641-66.
6. Balter S, Hopewell JW, Miller DL, Wagner LK, Zelefsky MJ. Fluoroscopically guided interventional procedures: a review of radiation effects on patients' skin and hair. Radiology. 2010;254(2):326-41.
7. Yu S-B, Watson AD. Metal-based X-ray contrast media. Chemical reviews. 1999;99(9):2353-78.
8. Kinahan PE, Hasegawa BH, Beyer T, editors. X-ray-based attenuation correction for positron emission tomography/computed tomography scanners. Seminars in nuclear medicine; 2003: Elsevier.
9. Caschera L, Lazzara A, Piergallini L, Ricci D, Tuscano B, Vanzulli A. Contrast agents in diagnostic imaging: Present and future. Pharmacological research. 2016;110:65-75.
10. Ginai-Karamat A. Contrast media for radiological examination in gastrointestinal tract leakage. 1987.
11. Reed MC, Gurm HS. Contrast agents. Cardiovascular Catheterization and Intervention: A Textbook of Coronary, Peripheral, and Structural Heart Disease. 2010:28.
12. Awasthi R, Kulkarni GT. Decades of research in drug targeting to the upper gastrointestinal tract using gastroretention technologies: where do we stand? Drug delivery. 2016;23(2):378-94.
13. Taylor SA, Plumb A. The large bowel. Elsevier Health Sciences; 2014.
14. Rumenapp C, Gleich B, Haase A. Magnetic nanoparticles in magnetic resonance imaging and diagnostics. Pharmaceutical research. 2012;29(5):1165-79.
15. Ntusi NA, Samuels P, Moosa S, Mocumbi AO. Diagnosing cardiac disease during pregnancy: imaging modalities. Cardiovascular journal of Africa. 2016;27(2):95.
16. Galper MW, Saung MT, Fuster V, Roessl E, Thran A, Proksa R, et al. Effect of computed tomography scanning parameters on gold nanoparticle and iodine contrast. Investigative radiology. 2012;47(8):475.
17. Yaffe M, Rowlands J. X-ray detectors for digital radiography. Physics in Medicine & Biology. 1997;42(1):1.
18. Singh J, Daftary A. Iodinated contrast media and their adverse reactions. Journal of nuclear medicine technology. 2008;36(2):69-74.

APPENDIX

PERFORMA

MR no: _____ Date: _____ Age: _____
 Gender: _____
 Weight (kg): _____

TYPE OF CONTRAST USED

PATIENT HISTORY

1. Fatigue	<input type="checkbox"/> Yes	<input type="checkbox"/> No
2. Nausea	<input type="checkbox"/> Yes	<input type="checkbox"/> No
3. Vomiting	<input type="checkbox"/> Yes	<input type="checkbox"/> No
4. Shivering	<input type="checkbox"/> Yes	<input type="checkbox"/> No
5. Headache	<input type="checkbox"/> Yes	<input type="checkbox"/> No
6. Rashes	<input type="checkbox"/> Yes	<input type="checkbox"/> No
7. Known Allergic Diseases	<input type="checkbox"/> Yes	<input type="checkbox"/> No
8. Vital Signs	<input type="checkbox"/> Yes	<input type="checkbox"/> No
9. History of contrast reactions	<input type="checkbox"/> Yes	<input type="checkbox"/> No
10. Treatment given (if any)	<input type="checkbox"/> Yes	<input type="checkbox"/> No

NOTES: (if any required)
