



<https://doi.org/10.1016/j.ultrasmedbio.2021.02.018>

## ● Original Contribution

# OXYTOCIN AND MISOPROSTOL WITH DICLOFENAC IN THE PREPARATION FOR MAGNETIC RESONANCE–GUIDED HIGH-INTENSITY ULTRASOUND TREATMENT OF SYMPTOMATIC UTERINE FIBROIDS: A PROSPECTIVE COHORT STUDY

TOMASZ ŁOZIŃSKI,\* ARTUR LUDWIN,† JUSTYNA FILIPOWSKA,\*‡ MAGDALENA ZGLICZYŃSKA,§  
 PIOTR WĘGRZYN,¶ TOMASZ KLUZ,|| and MICHAŁ CIEBIERA§

\* Department of Obstetrics and Gynecology Pro-Familia Hospital, Rzeszów, Poland; † Department of Gynecology and Oncology, Jagiellonian University, Kraków, Poland; ‡ Institute of Nursing and Health Sciences, Faculty of Medicine, University of Rzeszów, Rzeszów, Poland; § Second Department of Obstetrics and Gynecology, Center of Postgraduate Medical Education, Warsaw, Poland; ¶ Department of Obstetrics and Perinatology, Faculty of Health Sciences, Medical University of Warsaw, Warsaw, Poland; and || Department of Obstetrics and Gynecology, Faculty of Medicine, University of Rzeszów, Poland

(Received 25 June 2020; revised 16 February 2021; in final form 19 February 2021)

**Abstract**—Uterine fibroids (UFs) are very common benign tumors of the female reproductive tract. According to recent reports, magnetic resonance–guided high-intensity ultrasound (MR-HIFU) appears to be a well-tolerated and efficient treatment option for UFs. However, MR-HIFU still presents several limitations. The treatment is rarely associated with achieving complete non-perfused volume (NPV). Not all patients are qualified for a final procedure, and selected women obtain very good results in such treatment. The primary objective of this experimental study was to assess the effect of transvaginal misoprostol and intravenous oxytocin preparation on UF volume change, sonication time and NPV after MR-HIFU procedure in women of reproductive age with symptomatic UFs. Secondary outcomes included the effect on the peri-procedural effectiveness of misoprostol and oxytocin. This study enrolled 247 women with symptomatic UFs; based on gynecologic examinations and magnetic resonance imaging (MRI) scans, 128 women qualified for MR-HIFU without pharmacologic treatment, 57 women qualified for the misoprostol/diclofenac group and 62 women qualified for the oxytocin group. Pharmacologic pre-treatment improved NPV compared with non-pharmacologic treatment (average NPV: controls 61.9% ± 25.8%; oxytocin 76.8% ± 20.7%; misoprostol/diclofenac 85.2% ± 15.1%; average sonication time: controls 120 min ± 56.4%; oxytocin 111 min ± 45.4%; misoprostol/diclofenac 80 min ± 47.7%). Statistical analysis did not reveal significant intergroup differences in UF volume changes after 6 mo (controls: n = 40, 37.4% ± 27.5%; oxytocin n = 25, 45.8% ± 31%; misoprostol/diclofenac n = 19, 33.4% ± 23.2%). The misoprostol/diclofenac group, which achieved the highest NPV immediately after the MR-HIFU procedure, was characterized by the lowest UF volume change percentages 6 mo later. The administration of vasoconstrictor drugs (oxytocin and misoprostol/diclofenac) to support MR-HIFU in UF treatment is a new issue that may improve the total effectiveness of this method. Randomized controlled trials are necessary to estimate the real effect of vasoconstrictors on MR-HIFU. (E-mail: [tomasz.lozinski@pro-familia.pl](mailto:tomasz.lozinski@pro-familia.pl)) © 2021 The Author(s). Published by Elsevier Inc. on behalf of World Federation for Ultrasound in Medicine & Biology. This is an open access article under the CC BY-NC-ND license (<http://creativecommons.org/licenses/by-nc-nd/4.0/>).

**Key Words:** Uterine fibroid, Leiomyoma, Ultrasound, Magnetic resonance–guided focused ultrasound (MRgFUS), Magnetic resonance–guided high-intensity ultrasound (MR-HIFU), HIFU, Oxytocin, Misoprostol.

## INTRODUCTION

Uterine fibroids (UFs) are benign tumors of the female reproductive tract that may cause a variety of clinical symptoms including abnormal uterine bleeding

(Parker 2007; Stewart et al. 2016) and pelvic pain. They may also be associated with infertility (Donnez and Dolmans 2016; Al-Hendy et al. 2017; Vitagliano et al. 2018). Various methods are used in treating UFs, from observation or pharmacology to radical surgery (Donnez and Dolmans 2016; Mas et al. 2017; Wang et al. 2020).

Magnetic resonance–guided focused ultrasound (MRgFUS) ablation and a newer method, magnetic

Address correspondence to: Tomasz Łoziński MD, PhD, Department of Obstetrics and Gynecology Pro-Familia Hospital, 35-033 Rzeszów, ul. Witolda 6 b, Rzeszów, Poland. E-mail: [tomasz.lozinski@pro-familia.pl](mailto:tomasz.lozinski@pro-familia.pl)

resonance—guided high-intensity ultrasound (MR-HIFU), appear to be well-tolerated and, in many cases, efficient treatment options for UFs. The MR-HIFU procedure is more precise and involves adequate volumetric heating of the whole UF volume with real-time feedback (Ji et al. 2017; Verpalen et al. 2019). Ultrasound energy produces a thermal effect in the tissue. This technique is based on temperature-related protein denaturation. The resultant necrosis in the tissue leads to the slow stimulation of apoptosis, shrinkage of the tumor and relief of symptoms (Stewart et al. 2003). The effect of this therapy depends on numerous factors, including internal tumor structure (Fan et al. 2018). According to Funaki et al. (2007), three types of UF tumors are observed in magnetic resonance imaging (MRI). They are classified depending on water content, fiber composition and blood supply. UF types I and II are heated effectively with the use of ultrasound and are characterized by a favorable response to the ultrasound beam, while type III does not respond to this treatment method (Funaki et al. 2007). There are numerous limitations associated with the use of this therapy, such as tumor location, size, distance between the lesion and the skin, type III according to Funaki classification, and bowel being located between the uterus and the anterior abdominal wall (Peng et al. 2015).

Regrettably, in many cases MR-HIFU/MRgFUS procedures are still associated with a relatively low effectiveness, sometimes sub-optimal response to treatment, several limitations and, in most cases, the lack of an ultimate solution to the problem. However, widely conducted research (Łoziński et al., 2019a; Verpalen et al. 2019) involved the exploration of substance options that may enhance the effectiveness of UF treatment with ultrasound, uterotonics being one. The underlying hypothesis assumes an increased destruction of UFs with ultrasound with a simultaneous perfusion reduction (Iavazzo et al. 2015).

Oxytocin is a peptide hormone and a neuropeptide. It mediates a variety of physiologic effects in the target tissue (e.g., causes uterine contractions and vasoconstriction in the uterine wall, plays a key role in the initiation of labor, regulates lactation and reproductive behavior) (Bell et al. 2014). Oxytocin receptor activation triggers a variety of pathways to stimulate contraction, primarily by elevating intra-cellular calcium. Some of the cardiovascular actions of oxytocin that might modulate MRgFUS/MR-HIFU procedures include blood pressure lowering, parasympathetic neuromodulation, vasodilation, immunologic or antioxidant activity and metabolic effects (Japundžić-Žigon et al., 2020).

Misoprostol is an analogue of prostaglandin E1, which binds to myometrial cells to cause strong myometrial contractions, leading to the expulsion of tissue. It

also causes cervical ripening with the softening and dilation of the cervix (Elati and Weeks 2009). The drug is recommended for the treatment of postpartum hemorrhage when oxytocin is ineffective and is known as second-line therapy of postpartum bleeding. According to available data, clinicians recommend the administration of misoprostol during myomectomy, as it might reduce bleeding, decrease the volume of transfusions and shorten surgery duration (Iavazzo et al. 2015). According to Celik et al. (2003), the use misoprostol causes a decrease in uterine artery blood flow. The authors suggested that it might be evaluated as an occlusion method and considered a treatment alternative in patients with UFs (Celik et al. 2003).

According to previous research published by our team in 2018, oxytocin administration seems to improve the efficiency of MR-HIFU therapy (Łoziński et al. 2018). After several years of monitoring and studying increasing numbers of patients, we hypothesize that an increased blood flow in UF tissue decreases the efficiency of ultrasound beam treatment. Uterotonics cause tumor shrinking, which leads to the externalization of extracellular fluid and, as a result, more effective heating of the tissue. Decreased blood flow in the tumor reduces the cooling effect of the blood. Our results showed that non-perfused volume (NPV) significantly improved after oxytocin administration (Łoziński et al. 2018).

No data are available to describe the use of misoprostol in MRgFUS/MR-HIFU. Therefore, we wanted to study its possible suitability in this matter. The use of misoprostol during MRgFUS/MR-HIFU therapy is hypothesized to be a factor that reduces the cooling effect of the blood owing to vasoconstriction in the uterus.

## AIM OF THE STUDY

The primary objective of this experimental study was to assess the effect of transvaginal misoprostol/diclofenac and intravenous oxytocin preparation on sonication time and the effect on the peri-procedural effectiveness of misoprostol/diclofenac and oxytocin on the MR-HIFU procedure, which was quantified by NPV. The secondary and technical outcome included UF volume after MR-HIFU procedure in women of reproductive age with symptomatic UFs.

## MATERIALS AND METHODS

### *Design and patients*

This was an experimental, single-center, prospective cohort study performed as part of a larger prospective study project to assess the use of MR-HIFU in the treatment of UFs in women of reproductive age. The study was approved by the Local Bioethics Committee,

and informed written consent was obtained from all the participants.

A part of the project and our experience with the sole use of oxytocin compared with controls were described previously (oxytocin and controls). The study included a cohort in which we implemented no pharmacologic preparation of the patients and introduced oxytocin (Łoziński 2018). Considering the results of the previous study and the potential effectiveness of misoprostol/diclofenac, we introduced consecutive women undergoing MR-HIFU. All UFs were classified according to the International Federation of Gynecology and Obstetrics (FIGO) classification (Munro *et al.* 2011). The inclusion and exclusion criteria were the same as previously reported (Łoziński *et al.* 2018). We included women aged 20–43 y with symptomatic UFs (abnormal uterine bleeding, pain), positive MRI qualification (Funaki type I or II, a suitable beam window) and willingness to preserve fertility. Exclusion criteria were as follows: pregnancy, standard contraindications for MRI and no necessity to preserve fertility according to the requirements of the funding grant.

All women were tested to exclude pregnancy using a urine test before the procedure until the end of July 2017, and after that time pregnancy testing was conducted with additional human chorionic gonadotropin beta blood test 7 d before the procedure (Łoziński *et al.*, 2019b).

Women were enrolled in the Department of Obstetrics and Gynecology, Pro-Familia Hospital, Rzeszów, Poland. During the study, surgical options of UF treatment were also offered, and MR-HIFU was available as an alternative treatment option according to the patient's preference, detailed qualification and the lack of contraindications for MR-HIFU. The patients were divided into three groups: (i) the control group recruited between May 2015 and October 2016 and treated with MR-HIFU with no pharmacologic preparation before the procedure; (ii) the oxytocin group, including women recruited between September 2016 and June 2017 (the patients were administered oxytocin); and (iii) the misoprostol/diclofenac group, including women recruited between July 2017 and September 2018 (the patients were administered misoprostol/diclofenac). An independent Bioethics Committee statement (2017) excluded a combination of other drugs. Women who were recruited between September 2016 and September 2018 but did not receive oxytocin or misoprostol/diclofenac because of specific contraindications or patients' preferences were included in the control group. Standard contraindications for oxytocin (*e.g.*, allergies, high blood pressure, pregnancy) or misoprostol/diclofenac (*e.g.*, high blood pressure or digestive tract cancer) were not considered as exclusion criteria of the study, but the patients did not receive

those agents and were also included in the control group.

#### *Evaluation and qualification*

The qualification included medical history collection and completing a self-composed questionnaire regarding the clinical symptoms of UFs. The participants received a gynecologic examination with speculoscopy and ultrasound (Samsung WS80A, Samsung Group, Seoul, South Korea). All patients were qualified personally by the first author of this manuscript based on the gynecologic examination and MRI. Subsequently, an MRI of the pelvic area was performed using the same device (Philips Ingenia 3.0T system, Philips, Amsterdam, the Netherlands) in all patients. Basing on the structure in T2-weighted MRIs, UFs were divided according to the Funaki classification (Funaki *et al.* 2007). Type I and II UFs were qualified for MR-HIFU, whereas patients with type III UFs, with big areas of necrosis and bowel in the acoustic window, were disqualified.

The remaining 247 women were included in the final analysis and divided according to the following pattern: 128 women qualified for MR-HIFU without pharmacologic treatment, 57 women were included in the misoprostol/diclofenac group, and 62 women were included in the oxytocin group.

Patients presented with different types of UFs, and all patients underwent the MR-HIFU of a single UF, which was suspected to be responsible for the presence of symptoms (the largest and closest to the uterine cavity). However, some patients still presented with multiple lesions. Most of the treated UFs were located in the front, side wall and in the fundus of the uterus. UFs located in the rear wall were mostly disqualified, as this area is beyond the acoustic window.

#### *MR-HIFU procedure*

The preparation and admissions of patients were standardized. Patients were admitted to the hospital at 6:30 AM on the day of the planned treatment. Patients were asked to adhere to a semi-liquid diet 3 days before the treatment. Moreover, 150 mL of sodium dihydrogen phosphate–sodium hydrogen phosphate preparation was administered on the morning of the procedure. Blood test results, thyroid-stimulating hormone (TSH), creatinine clearance and urea tests were checked. Current blood test results of TSH, creatinine clearance and urea were mandatory. MR-HIFU was performed using Sonalve MR-HIFU (Philips, Amsterdam, the Netherlands) with bladder, rectum or bladder and rectum manipulation.

### Oxytocin and misoprostol/diclofenac

During the whole procedure, the patients in the oxytocin group were administered 40 IU of intravenous oxytocin diluted in 500 mL of 5% glucose or 0.9% sodium chloride at the rate of 5 mL/min. We used a higher concentration of oxytocin than recommended by the US Food and Drug Administration for postpartum hemorrhage (40 IU/1000 mL) based on our previous experience and the common use of such an oxytocin concentration in local protocols for gynecologic purposes in our country. As regards Pro-Familia Hospital (the center where the study was conducted), 40 IU of oxytocin is used only in postpartum hemorrhage. The manufacturer labels the maximum dose as 40 IU in 1000 mL of 0.9% sodium chloride or in 5% glucose solution. Moreover, there were no international recommendations or recommendations of well-known agencies or the producer regarding the limitation for the maximal concentration. Patients included to the misoprostol/diclofenac group were asked to use 2 pills of Pfizer Arthrotec (a combination of non-steroidal anti-inflammatory drug and a prostaglandin), 200 mcg misoprostol and 50 mg diclofenac sodium in one pill (the total of 400 mcg of misoprostol and 100 mg of diclofenac in two pills) into the vagina, posterior vault, about 30 min before MR-HIFU procedure. The Bioethical Committee accepted the use of the described doses of both drugs.

### Evaluation during and immediately after the procedure: primary outcome measures

The NPV of the tumor, time of sonication and side effects were evaluated. NPV is the measurement of success in HIFU treatment. It refers to the percentage of necrotic area in a tumor after sonication. A contrast medium (gadolinium) was additionally administered after the procedure to calculate the NPV of UFs as a measurement of technical treatment success.

### Follow-up and secondary outcome measures

The patients were invited to the hospital for a follow-up visit 6 mo after the procedure. It was a regular gynecologic appointment with an ultrasound examination focusing on UF evaluation. Additionally, in patients

whose NPV exceeded 70% immediately after the procedure, MRI scan was performed to check the exact change in UF volume. Ultrasound examinations and MRI were assessed by the same observers who performed pre-operative diagnostics and the MR-HIFU procedure. We performed a follow up MRI check only in women with the success of >70% for economic reasons. All the patients underwent an ultrasound examination, and the results were compared with the pre-treatment examinations.

### Statistical analysis

Values were expressed as means, medians and standard deviations (SD). Data were analyzed with the Mann–Whitney test and the analysis of variance. Statistical significance was set at  $p < 0.05$ . All analyses were performed using Statistica software (version 12.0 PL; StatSoft Inc., Tulsa, OK, USA; StatSoft, Krakow, Poland).

## RESULTS

### Patients

A total of 248 women with symptomatic UFs were primarily enrolled in this experimental study. However, one woman underwent MR-HIFU during early pregnancy because the procedure was performed in the late proliferative phase (Łoziński et al. 2019). Therefore, she was excluded from the study. The median age was 36 years (lower-upper quartile: 33–40 y; min-max: 24–43 y). The median body mass index (BMI) was 22 kg/m<sup>2</sup> (lower-upper quartile: 20.5–25.5 kg/m<sup>2</sup>, min-max: 15.7–38.3 kg/m<sup>2</sup>). The pre-operative medians of UF volume assessed with ultrasound and MRI were: 93.40 mL and 95.00 mL (ultrasound  $p = 0.669$ ; MRI  $p = 0.457$ ), respectively (Table 1).

Table 1 includes data concerning the location of UFs, which were subjected to treatment in the enrolled patients according to the FIGO by Munro et al. (2011).

No statistical differences occurred between the groups regarding the proportion of specific types according to the FIGO classification ( $p = 0.957$ ).

The volume of UFs was comparable in all groups ( $p = 0.499$ ), so the correlation between the time of sonication and the volume was the same for all patients. The baseline UF volume seemed larger for the misoprostol/

Table 1. Lesions that were treated with MR-HIFU: Types of UFs according to FIGO and Funaki classification in each group (number [n]/%), age (n) and BMI (kg/m<sup>2</sup>)

FIGO type	1	2	3	4	5	6	Age	BMI	Funaki type I	Funaki type II
Misoprostol/diclofenac ( $n = 52$ )	3 (5.77)	2 (3.84)	21 (40.38)	14 (26.92)	8 (15.38)	4 (7.69)	35.8	22.87	38	19
Oxytocin ( $n = 67$ )	6 (8.96)	3 (4.47)	26 (38.8)	12 (17.9)	12 (17.9)	8 (11.94)	35.4	23.48	45	17
Control ( $n = 128$ )	8 (6.25)	6 (4.69)	43 (33.59)	30 (23.43)	23 (17.96)	18 (14.06)	36.9	23.26	93	35
<i>P</i> value	ns	ns	ns	ns	ns	ns	ns	ns		ns

BMI = body mass index; FIGO = International Federation of Gynaecology and Obstetrics; MR-HIFU = magnetic resonance–guided high-intensity ultrasound; UF = uterine fibroid.

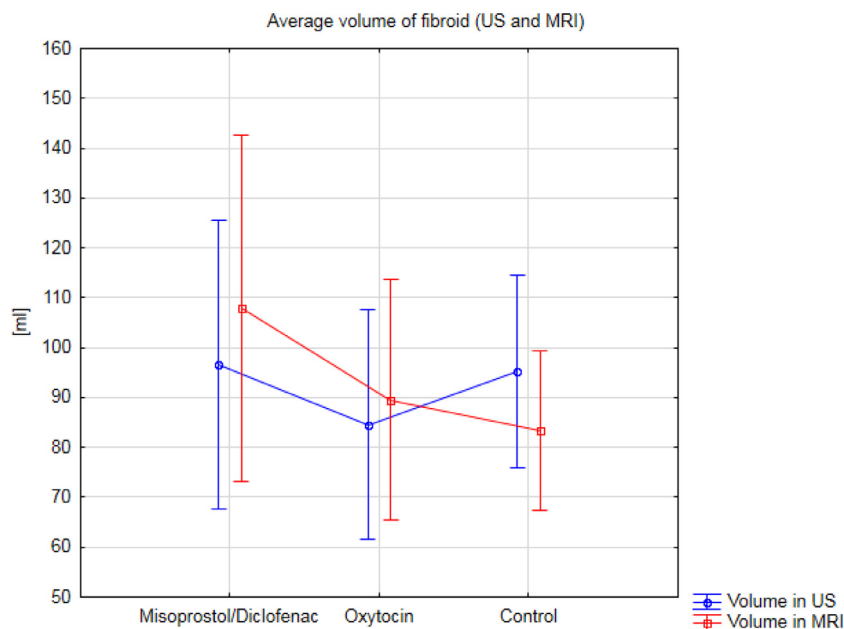


Fig. 1. Average fibroid volume in different groups measured with US and MRI. MRI = magnetic resonance imaging; US = ultrasound.

diclofenac group, although it was not statistically significant with standard deviations. The data are presented in Figure 1 and Table 2.

*NPV and sonication time*

NPV measured after the procedure is the most objective parameter to determine MR-HIFU treatment efficacy. The reduction of UF-related symptoms is the second of those parameters. In our research, we found a relationship between the change of UF volume after treatment and NPV and a reduction in symptoms (self-completed questionnaires). Despite the lack of direct dependence, probably owing to the small size of research groups, we believe that the improvement of NPV or changes in the volume of UFs might be important for the

final treatment result (Fig. 2). The use of misoprostol with diclofenac and oxytocin increased the efficiency of MR-HIFU therapy in UFs. Pharmacologic pre-treatment improved NPV compared with non-pharmacologic treatment (61.9% ± 25.8%). The highest NPV immediately after the procedure was obtained with the use of misoprostol with diclofenac (85.2% ± 15.1%). Oxytocin was found slightly less effective (76.8% ± 20.7%) than misoprostol with diclofenac in achieving higher NPV after MR-HIFU. The next step of study analysis involved the intergroup comparison of NPV percentages achieved immediately after MR-HIFU. Statistical analysis revealed significant differences between all groups, and the highest level of significance was found between the controls and misoprostol/diclofenac-treated group (p = 0.0000001). The results are presented in Table 3 and Figure 3.

After NPV analysis, we compared sonication times between the groups. In this case, the results were also rather surprising. In patients who received misoprostol with diclofenac, the average sonication time (80 min) was almost 40 min shorter compared with patients from the control group (120 min), whereas in patients who received oxytocin, the difference was only about 9 min (111 min). We compared sonication times between all groups. Statistical analysis showed the highest level of significance between the controls and misoprostol/diclofenac-treated group (p = 0.000008). No significant difference was found between oxytocin and the control group (p = 0.28). The results are presented in Table 4 and Figure 4.

Table 2. Comparison of average fibroid volume in different groups measured with ultrasound and MRI

Group	MRI volume (mL)	SD (mL)	
Misoprostol/diclofenac	107.93	119.64	
Oxytocin	89.55	98.77	
Control	87.54	100.00	p = 0.4572

Group	Ultrasound volume (mL)	SD (mL)	
Misoprostol/diclofenac	96.63	101.86	
Oxytocin	84.55	91.60	
Control	99.04	112.12	p = 0.669

MRI = magnetic resonance imaging; SD = standard deviation.

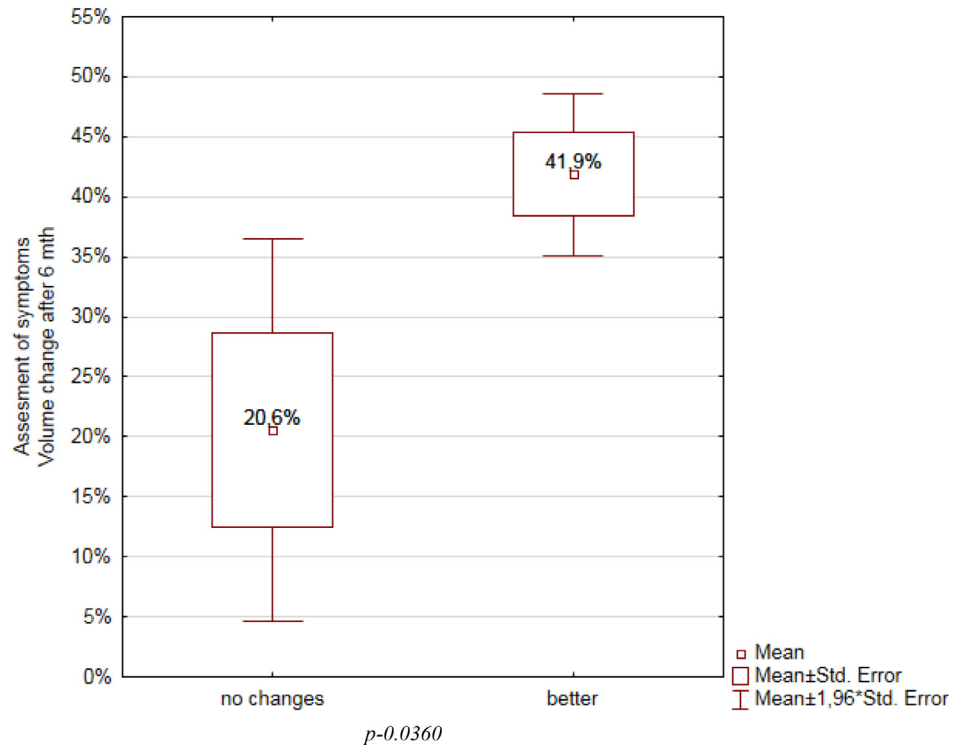
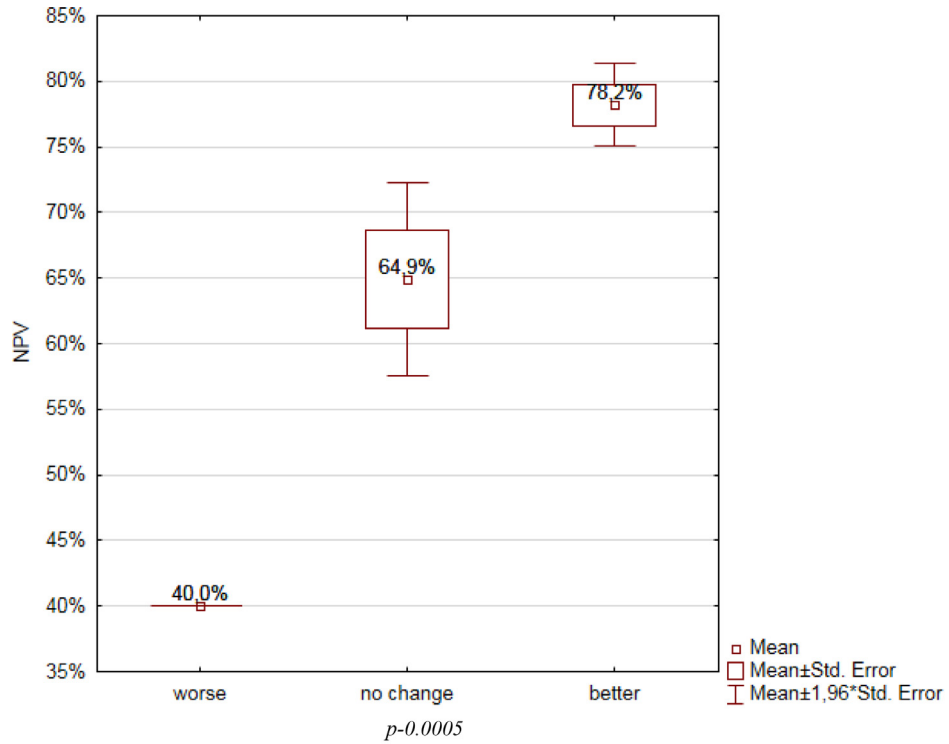


Fig. 2. Comparison between reduction of symptoms and non-perfused volume and volume change (MRI). MRI = magnetic resonance imaging.

*Follow up: UF volume*

As stated before, we assumed that the treatment success would be the NPV of 70% or greater. Therefore,

all patients with the NPV of 70% and higher had an additional MRI scan during the follow-up visit 6 mo after the initiation of the protocol. We compared the long-term

Table 3. The number of patients and NPV immediately after MR-HIFU in selected groups.

	n	NPV	SD	Misoprostol/diclofenac	oxytocin
Misoprostol/diclofenac	52	85.2%	+/- 15.1%		<i>p</i> =0,045
Oxytocin	67	76.8%	+/- 20.7%	<i>p</i> =0,045	
Controls	128	61.9%	+/- 25.8%	<i>p</i> =0,0000001	<i>p</i> =0,000017
Summary	247	70.8%	+/- 24.5%		

non-perfused volume – NPV; number – n; standard deviation – SD

effect of using MR-HIFU with or without the use of additional pharmacologic methods (oxytocin or misoprostol with diclofenac) in all of those patients. Additional MRI scans were performed in 84 patients (34% of the initial group) because of NPV criteria and because some patients were lost to follow-up. Obviously, it would be more beneficial if every patient had a control MRI. However, the lack of financing was the major issue in this context. Therefore, the results concerning tumor volume and its change after the treatment are very interesting. However, because of the small size of the groups, we may treat them as purely technical and secondary. It is necessary to perform at least a control ultrasound examination in all patients, which would lower the costs compared with control MRI scans.

The results for controls, oxytocin and misoprostol/diclofenac groups were 37.4%, 45.8% and 33.4%, respectively. The complete data obtained from additional MRI scans are presented in Table 5 and Figure 5. The results were consistent with the ultrasound volume tests

performed in all patients after 6 mo regardless of the NPV result.

Further steps of statistical analysis involved the comparison of UF volume reduction achieved 6 mo after the initial MR-HIFU treatment. Statistical analysis did not show significant differences between all groups ( $p = 0.3$ ).

Additionally, the study involved the analysis of correlation between the age and UF volume with NPV and sonication time. The results are presented in Table 6.

No significant correlations were found apart from the one referring to the sonication time and UF volume. The strongest correlation was observed in case of misoprostol and diclofenac use ( $r = 0.709$ ) (Table 4). The researchers also analyzed the type of UF according to the criteria by Funaki *et al.* (2007) and the differences in NPV and sonication time depending on UF type I or II and a drug that was administered. The analysis found that the shortest sonication time was achieved with the use of misoprostol with diclofenac as a supporting drug

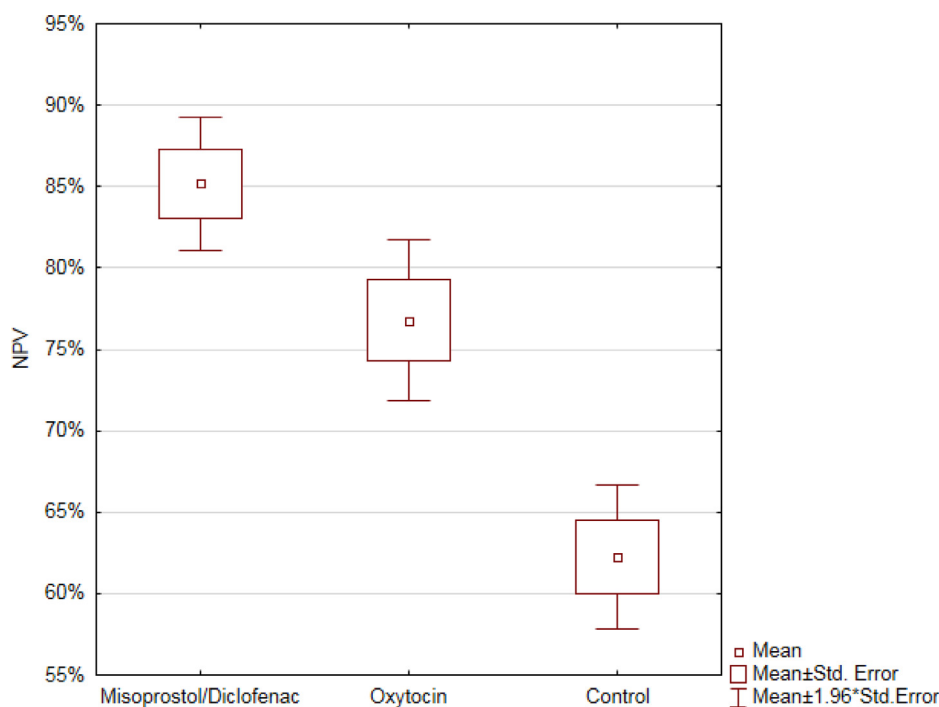


Fig. 3. NPV immediately after MR-HIFU in selected groups (SD). MR-HIFU = magnetic resonance–guided high-intensity ultrasound; NPV = non-perfused volume; SD = standard deviation.

Table 4. The number of patients and MR-HIFU sonication time in selected groups.

	n*	Sonication time [min]	SD	Misoprostol/diclofenac	Oxytocin
Misoprostol/diclofenac	50	80	+/- 47.7%	$p=0,00153$	$p=0,00153$
Oxytocin	67	111	+/- 45.4%		
Controls	122	120	+/- 56.4%	$p=0,000008$	$p=0,28$
Summary	239	109	+/- 53.8%		

minute – min; number – n; standard deviation – SD

(\* lack of data about sonication time in 8 patients from the whole group)

( $p = 0.0000001$ ). The highest NPV percentage was also noted in the misoprostol/diclofenac group, particularly in case of type I UFs ( $p = 0.0000001$ ). We present these data in Figure 6.

## DISCUSSION

The study found that misoprostol with diclofenac had no effect on our most important primary outcome, UF volume after MR-HIFU, whereas oxytocin administration resulted in decreasing UF volume at 6-mo follow-up. Moreover, NPV was higher and sonication times were lower in the misoprostol/diclofenac and oxytocin group compared with women who underwent a MR-HIFU procedure without the use of those drugs. Indeed, the lack of differences may be treated as very disappointing, but the time of procedure was significantly reduced, and it should be regarded as an important finding

considering all benefits associated with shortened procedure time (cost effectiveness). The results indicated that the application of misoprostol/diclofenac and oxytocin might increase MR-HIFU effect on UF tissue thermal destruction. Therefore, it may be concluded that procedures that use MR-HIFU may be modulated with appropriate uterotonics. The highest percentages of UF volume changes were found in the oxytocin group, suggesting that the best results might be obtained with the use of oxytocin injections during the MR-HIFU procedure. Interestingly, the misoprostol/diclofenac group that achieved the highest NPV immediately after the MR-HIFU procedure was characterized by the lowest UF volume change percentages 6 mo later (Fig. 4).

Considering available literature, numerous authors expressed the view that MRgFUS/MR-HIFU has the all potential to become a method of treatment that could shift traditional patterns of UF therapy

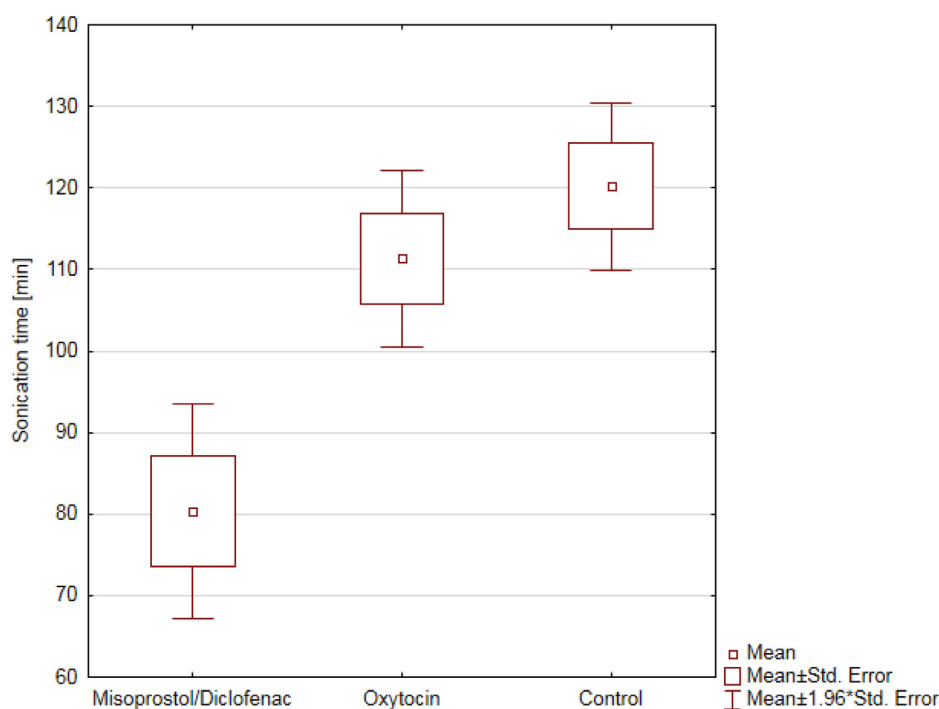


Fig. 4. MR-HIFU sonication times in selected groups (SD). MR-HIFU = magnetic resonance-guided high-intensity ultrasound; SD = standard deviation.



Table 5. Uterine fibroid volume change 6 months after MR-HIFU: Different groups

UFs after 6 months	n	Average volume change	SD
Misoprostol/diclofenac	19	33.4%	±23.2%
Controls	40	37.4%	±27.5%
Oxytocin	25	45.8%	±31%
Summary	84	39%	±27.8%

MR-HIFU = magnetic resonance-guided high-intensity ultrasound; SD, standard deviation; UF, uterine fibroid.

(Schlesinger *et al.* 2013; Ciebiera and Łoziński 2020). The main aim of available studies is to achieve the best clinical efficacy, quickest recovery and the lowest morbidity with the use of this method (Bohlmann *et al.* 2014; Łoziński *et al.* 2017). The main issues related to MRgFUS/MR-HIFU are the optimal preparation of the device, proper patient qualification and effective cooperation between the radiologist and gynecologist (Duc and Keserci 2018). As the efficacy of this method is still not optimal in some cases, advanced research is conducted to increase the total effectiveness of MRgFUS/MR-HIFU therapy with the addition of different drugs (Łoziński *et al.* 2018). This study has some limitations, but we are publishing it to highlight that uterotonic administration in MR-HIFU procedures is a cost-effective and relatively safe modification option of the procedure and may influence the final results. It is worth considering how much the cost of the procedure may

Table 6. Correlations between different parameters

Group	Age/sonication time no correlation	Age/NPV no correlation
Misoprostol/diclofenac	r = 0.046	r = 0.108
Oxytocin	r = 0.038	r = 0.187
Control	r = 0.14	r = 0.155
All	r = 0.071	r = (-0.012)

Group	Volume/sonication time correlation found	Volume/NPV no correlation
Misoprostol/diclofenac	r = 0.709	r = (-0.208)
Oxytocin	r = 0.524	r = (-0.098)
Control	r = 0.618	r = (-0.105)
All	r = 0.569	r = (-0.0819)

NPV = non-perfused volume.

The closer to 1, the stronger the correlation; if negative – it is inversely proportional.

0.0 ≤ |r| ≤ 0.2 – no correlation; 0.2 < |r| ≤ 0.4 – a weak correlation; 0.4 < |r| ≤ 0.7 – a medium correlation; 0.7 < |r| ≤ 0.9 – a strong correlation; 0.9 < |r| ≤ 1.0 – a very strong correlation.

change if the use of certain drugs contributed to the reduction of procedure duration. Therefore, new research is necessary to investigate not only other substances, but also various doses and administration routes of drugs whose effectiveness were confirmed (*e.g.*, oxytocin). The best solution would be a double-blind randomized controlled trial. However, it was impossible for us to conduct such a study. The presented study is a pioneering one as no other studies have been performed to

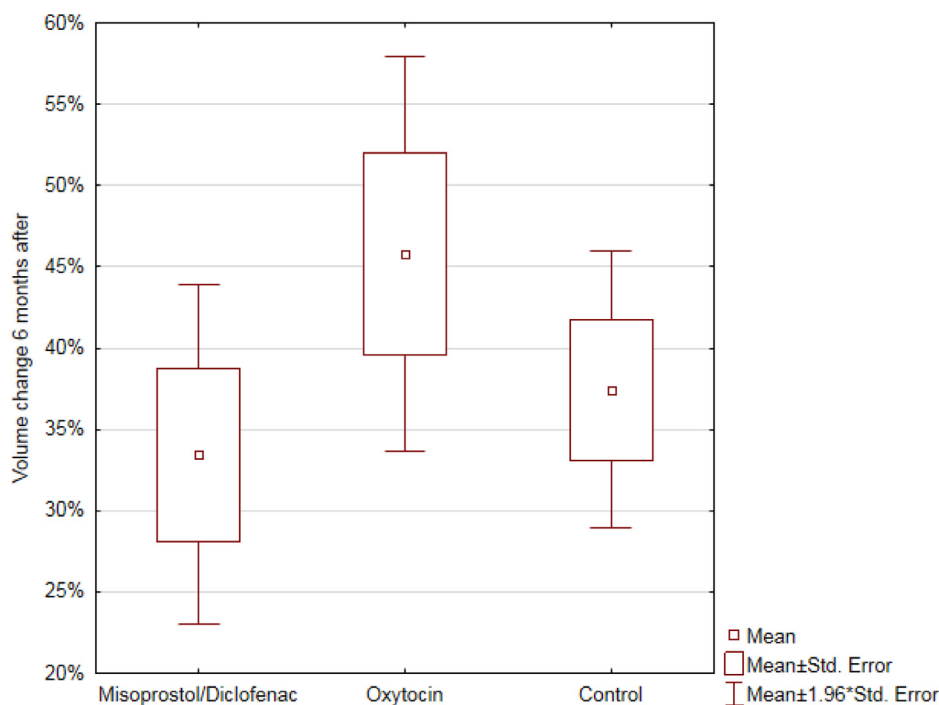


Fig. 5. Uterine fibroid volume change 6 mo after MR-HIFU procedure (SD). MR-HIFU = magnetic resonance-guided high-intensity ultrasound; SD = standard deviation.

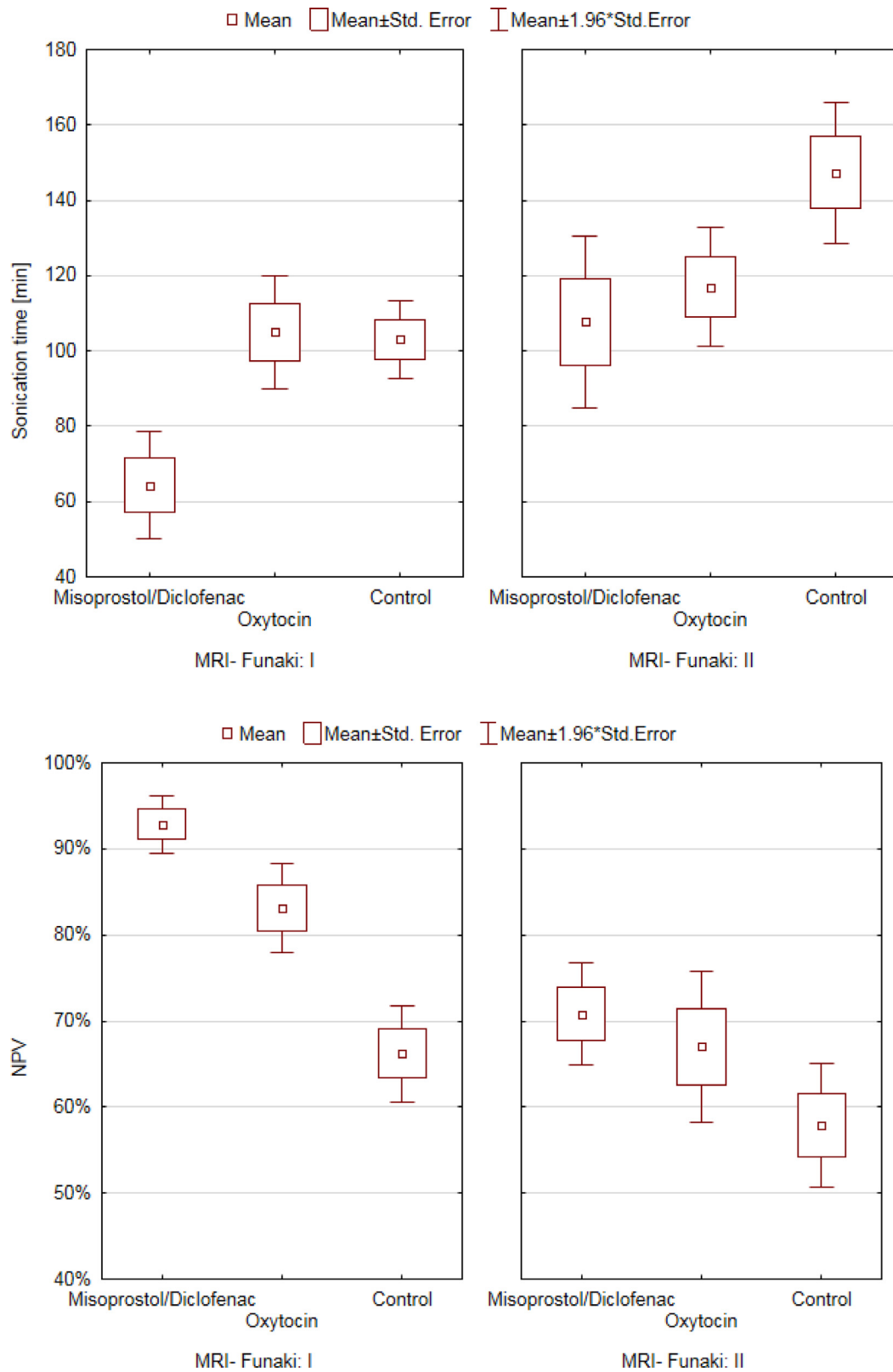


Fig. 6. Sonication time and Funaki type in different groups ( $p=0.0000001$ ) and NPV and Funaki type in different groups ( $p=0.0000001$ ). NPV = non-perfused volume.

assess the use of misoprostol/diclofenac as a co-treatment during MR-HIFU. In the previous study conducted by our team, we proved that the administration of oxytocin is helpful in obtaining higher MR-HIFU treatment efficacy (Łoziński *et al.* 2018), which is why we decided to move further. In this overlapping study, which included more patients in the control and oxytocin group and also assessed the use of a different agent, we found that NPV percentage was the highest and the sonication time was the shortest in patients who had received misoprostol/diclofenac before the procedure. Oxytocin was slightly less effective in this matter, while the patients who did not receive any additional treatment had the lowest NPV and the longest sonication time. The data are very important from the viewpoint of clinicians who use MR-HIFU in their practice, as they show completely different effects of each uterotonic on the course of the procedure. Interestingly, the results do not translate into the final effect achieved on UF tumor volume reduction 6 mo after the initial treatment. A group of women who received misoprostol/diclofenac obtained the poorest results in total tumor volume reduction. The control group was rated as average and the oxytocin group was found to obtain the best results in UF volume reduction. All these results were consistent with ultrasound imaging, which was performed in all patients regardless of NPV. However, no significant differences were found between the groups. Despite this goal of therapy, we have to remember that UF shrinkage might decrease the symptoms in some patients as well. Research in major cohorts of patients might be necessary here. According to our observations obtained from the present study, we suspect that misoprostol causes a strong and sudden constriction of blood vessels, which stands in line with previous observations (Yip *et al.* 2000; Celik *et al.* 2003). The highest necrosis (NPV) recorded in misoprostol group after treatment was probably a false-positive result. Temporary necrosis was caused by misoprostol and not the ultrasound beam, and the final effect was poorer in this group. Numerous patients reported sudden pain during sonication, probably associated with blood vessel constriction. In our viewpoint, the dose of misoprostol requires further research and a randomized controlled trial. Oxytocin is also a strong vasoconstrictor (Loichot *et al.* 2001; Krzymowski and Stefańczyk-Krzyszowska 2002). Its contractile effect in case of the uterine muscle and its nourishing vessels appears to be weaker compared with misoprostol. However, most data concerning this correlation were retrieved from obstetric studies (Rajaei *et al.* 2014; Acharya *et al.* 2017).

In our opinion, vasoconstriction caused by misoprostol at such doses is probably so strong that the obtained NPV is highly improved over the first stage, but it makes heating by MR-HIFU ineffective. In case of

intravenous oxytocin, vasoconstriction seems much more balanced, because not only is NPV higher, but the final effect of volume change is more beneficial, as we showed in the previous study as well (Łoziński *et al.* 2018). Therefore, it seems to be of key importance to make a proper choice of a drug and its dose, which will not only cause the constriction of vessels sufficient to increase necrosis, but also will not reduce the effectiveness of MR-HIFU. Therefore, the following question should be answered: Which drug is more effective in standard regimens? Seemingly, oxytocin will be more beneficial. However, the role of misoprostol should not be neglected after this study. We should perform additional research assessing other doses, other routes of administration or using both variables at the same time (*e.g.*, oral or as an insert) as NPV percentages and sonication times during MR-HIFU were extraordinary with the use of this compound.

The present study presents new possibilities in MR-HIFU therapy with the use of, for example, oxytocin as MR-HIFU support in selected patients. Oxytocin is a cheap and easily available drug that is well tolerated with a few contraindications (Page *et al.* 2017). The main significance of the presented results is the shortening of procedures, which reduces the total health care costs as MRI scans are still expensive. Seemingly, introducing it as a standard for MR-HIFU therapy might be really advantageous in case of further positive research results. In our opinion, better designed studies without a time-dependent cohort, preferably multi-center randomized controlled trials with the blinding of observers and participants, are necessary to be conclusive for the real value of additional pharmacologic treatment during MR-HIFU. Moreover, it seems that based on the results of this study, it is reasonable to perform a robust investigation. Certainly, we should also carry out further research with other drugs or a combination of drugs, such as oxytocin analogues (*e.g.*, carbetocin) or with other prostaglandins (*e.g.*, dinoprostone or sulprostone) to find the most optimal drug that improves the effect of MR-HIFU therapy. Such an option is interesting for consideration, and we hope that this study will open new possibilities for future research.

According to the study protocol, after Local Bioethics Committee approval and obtaining written informed consent, we performed MR-HIFU in symptomatic women, who were also infertile. The safety and effectiveness of MR-HIFU is still poorly assessed in infertile women (Bohlmann *et al.* 2014). Considering few pregnancies were reported after MR-HIFU, mainly in case reports and observational studies with a poor design, this method should be treated as experimental and should not be offered in regular clinical practice before performing well-designed randomized controlled trials to compare

the effect of the procedure with expectant management, myomectomy or drugs. It is also worth emphasizing that there are ongoing studies in China that compare the effects of MR-HIFU and laparoscopic adenomyosis excision (Huang et al. 2020). As the results are promising, we also wait for such studies in UFs.

The main limitation of this study is that it is a non-randomized controlled trial, and the inclusion of patients in the misoprostol/diclofenac, oxytocin and control groups was time-dependent. Hence, unknown confounding factors associated with potential differences in patient management were probably present. Other limitations are associated with the nature of the interpretation of NPV with its unknown reliability, which is always dependent on the observer, although it is still the best known measurement of MR-HIFU treatment efficacy. The most objective outcome was the result of the measurements of UF volume in the follow-up. However, the observers were not blinded, and the best design should include observers who assess the anatomic results without knowledge about the used drugs. Finally, the response rate of 34% at the 6-mo follow-up is too low to make reliable conclusions, and in this study it failed to show a lasting effect of drug co-treatment, yet further randomized controlled trials should be performed to test whether the differences are factual or reflect the prevailing bias and limitations of the study. However, similar results in ultrasound examinations of the whole group of patients prompted us to present them. Another issue was the total dosage of oxytocin and misoprostol or diclofenac. The speed of oxytocin dosage was constant, and the patients ultimately received different total doses of oxytocin. It means that patients with larger UFs and during longer procedures received a higher total dose of oxytocin. The total dose of misoprostol that was available in the bloodstream is also difficult to standardize. According to Ziemann et al. (1997), the mean time to peak levels ( $34 \pm 17$  min compared with  $80 \pm 27$  min, respectively;  $p < 0.001$ ) is different between oral and vaginal administration. Additionally, diclofenac may also change the uterine artery pulsatility index, but the data concerning its influence on UF circulation are unknown (Järvelä et al. 1998).

The strengths are the high standardization of procedures considering measurements, equipment, observers and follow-up in the study. The present results are promising for the improvement of peri- and intra-procedural care with drug preparations. However, the real effect on the most important results, such as symptoms, is unknown, and should be assessed in a longer follow-up period.

The survey of the quality of life (QoL) was not performed in this study, as this endpoint was not planned in the original design of the study for short follow-up (6

mo). We are still collecting data about the QoL in those patients with the emphasis on long-term changes (up to 24 mo).

In our viewpoint, further research should also cover an interesting group of patients who decided to undergo myomectomy after MR-HIFU (with or without drugs). The analysis of available data will show whether any significant differences might predict such patient decisions, which might allow for the change of their qualification or not performing MR-HIFU before myomectomy.

## CONCLUSIONS

The administration of vasoconstrictor drugs in support of MR-HIFU in UF treatment is a new issue that may improve the total effectiveness of this method. MR-HIFU support with misoprostol at described doses significantly improved NPV immediately after the procedure and shortened the sonication time, but long-term observation showed that it did not increase the effectiveness of the therapy. In our opinion, determining the optimal doses of prostaglandins requires further research. Oxytocin administration during MR-HIFU improved NPV after the procedure and may also cause better long-term effects related to UF volume. Based on the observed results it is reasonable to perform randomized controlled trials to estimate the real effect of misoprostol and oxytocin on the most important outcomes of MR-HIFU for the treatment of UFs.

*Acknowledgment*—We thank all clinicians who cooperated with us during this study.

This study was supported by the European Regional Development Fund Programme: Operational Programme Innovative Economy (2007–2013): Establishing a Research and Development Center of Non-invasive therapeutic methods. POIG.04.05.02-00-075/12-00.

This study was also supported by the European Regional Development Fund Programme: Intelligent Development Operational Program (2014-2020): Development and Implementation of a Non-invasive, Personalized Thermoablation Procedure in the Treatment of Specific Types of Neoplasms. POIR.01.01.01-00-0019/15-00.

*Conflict of interest disclosure*—All authors declare no conflict of interest. The funders had no role in the design of the study; in the collection, analyses or interpretation of data; in the writing of the manuscript; or in the decision to publish the results.

## REFERENCES

- Acharya T, Devkota R, Bhattarai B, Acharya R. Outcome of misoprostol and oxytocin in induction of labour. *SAGE Open Med* 2017;5:2050312117700809.
- Al-Hendy A, Myers ER, Stewart E. Uterine fibroids: Burden and unmet medical need. *Semin Reprod Med* 2017;35:473–480.
- Bell AF, Erickson EN, Carter CS. Beyond labor: The role of natural and synthetic oxytocin in the transition to motherhood. *J Midwifery Womens Health* 2014;59:35–42 quiz 108.
- Bohlmann MK, Hoellen F, Hunold P, David M. High-intensity focused ultrasound ablation of uterine fibroids: Potential impact on fertility and pregnancy outcome. *Geburtshilfe Frauenheilkd* 2014;74:139–145.
- Celik H, Sapmaz E, Serhatlioglu S, Parmaksiz C, Altinoglu A. Effect of intravaginal misoprostol use on uterine artery blood flow in patients with myoma uteri. *Fertil Steril* 2003;80:1526–1528.

- Ciebiaera M, Łoziński T. The role of magnetic resonance-guided focused ultrasound in fertility-sparing treatment of uterine fibroids-current perspectives. *Ecancermedicalscience* 2020;14:1034.
- Donnez J, Dolmans MM. Uterine fibroid management: from the present to the future. *Hum Reprod Update* 2016;22:665–686.
- Duc NM, Keserci B. Review of influential clinical factors in reducing the risk of unsuccessful MRI-guided HIFU treatment outcome of uterine fibroids. *Diagn Interv Radiol* 2018;24:283–291.
- Elati A, Weeks AD. The use of misoprostol in obstetrics and gynaecology. *BJOG* 2009;116(Suppl 1):61–69.
- Fan HJ, Cun JP, Zhao W, Huang JQ, Yi GF, Yao RH, Gao BL, Li XH. Factors affecting effects of ultrasound guided high intensity focused ultrasound for single uterine fibroids: A retrospective analysis. *Int J Hyperthermia* 2018;35:534–540.
- Funaki K, Fukunishi H, Funaki T, Sawada K, Kaji Y, Maruo T. Magnetic resonance-guided focused ultrasound surgery for uterine fibroids: Relationship between the therapeutic effects and signal intensity of preexisting T2-weighted magnetic resonance images. *Am J Obstet Gynecol* 2007;196 184.e1–184.e6.
- Huang YF, Deng J, Wei XL, Sun X, Xue M, Zhu XG, Deng XL. A comparison of reproductive outcomes of patients with adenomyosis and infertility treated with high-intensity focused ultrasound and laparoscopic excision. *Int J Hyperthermia* 2020;37:301–307.
- Iavazzo C, Mamais I, Gkegkes ID. Use of misoprostol in myomectomy: A systematic review and meta-analysis. *Arch Gynecol Obstet* 2015;292:1185–1191.
- Japundžić-Žigon N, Lozić M, Šarenac O, Murphy D. Vasopressin & oxytocin in control of the cardiovascular system: An updated review. *Curr Neuropharmacol* 2020;18:14–33.
- Järvelä I, Tekay A, Jouppila P. The effect of diclofenac on uterine artery blood flow resistance during menstruation in patients with and without a copper intrauterine device. *Hum Reprod* 1998;13:2480–2483.
- Ji Y, Hu K, Zhang Y, Gu L, Zhu J, Zhu L, Zhu Y, Zhao H. High-intensity focused ultrasound (HIFU) treatment for uterine fibroids: A meta-analysis. *Arch Gynecol Obstet* 2017;296:1181–1188.
- Krzyszowski T, Stefańczyk-Krzyszowska S. Uterine blood supply as a main factor involved in the regulation of the estrous cycle—a new theory. *Reprod Biol* 2002;2:93–114.
- Loichot C, Krieger JP, De Jong W, Nisato D, Imbs JL, Barthelmebs M. High concentrations of oxytocin cause vasoconstriction by activating vasopressin V1 A receptors in the isolated perfused rat kidney. *Naunyn Schmiedeberg's Arch Pharmacol* 2001;363:369–375.
- Łoziński T, Filipowska J, Gurynowicz G, Gabriel I, Czekierdowski A. Non-invasive therapeutic use of high-intensity focused ultrasound (HIFU) with 3 Tesla magnetic resonance imaging in women with symptomatic uterine fibroids. *Ginekol Pol* 2017;88:497–503.
- Łoziński T, Filipowska J, Krol P, Kubaty A, Wegrzyn P. Oxytocin administration in high-intensity focused ultrasound treatment of myomata. *Biomed Res Int* 2018;2018 7518026.
- Łoziński T, Filipowska J, Gurynowicz G, Zgliczynska M, Kluz T, Jedra R, Skowrya A, Ciebiaera M. The effect of high-intensity focused ultrasound guided by magnetic resonance therapy on obstetrical outcomes in patients with uterine fibroids - experiences from the main Polish center and a review of current data. *Int J Hyperthermia* 2019a;36:582–590.
- Łoziński T, Filipowska J, Ludwin A, Ciebiaera M. The outcome of magnetic resonance-guided high-intensity ultrasound for clinically symptomatic submucosal uterine fibroid performed accidentally in very early pregnancy: A case report. *Int J Hyperthermia* 2019b;36:975–979.
- Mas A, Tarazona M, Dasi Carrasco J, Estaca G, Cristobal I, Monleon J. Updated approaches for management of uterine fibroids. *Int J Womens Health* 2017;9:607–617.
- Munro MG, Critchley HO, Broder MS, Fraser IS. FIGO Working Group on Menstrual Disorders. FIGO classification system (PALM-COEIN) for causes of abnormal uterine bleeding in non-gravid women of reproductive age. *Int J Gynaecol Obstet* 2011;113:3–13.
- Page K, McCool WF, Guidera M. Examination of the pharmacology of oxytocin and clinical guidelines for use in labor. *J Midwifery Womens Health* 2017;62:425–433.
- Parker WH. Etiology, symptomatology, and diagnosis of uterine myomas. *Fertil Steril* 2007;87:725–736.
- Peng S, Zhang L, Hu L, Chen J, Ju J, Wang X, Zhang R, Wang Z, Chen W. Factors influencing the dosimetry for high-intensity focused ultrasound ablation of uterine fibroids: A retrospective study. *Medicine (Baltimore)* 2015;94:e650.
- Rajaei M, Karimi S, Shahboodaghi Z, Mahboobi H, Khorgoei T, Rajaei F. Safety and efficacy of misoprostol versus oxytocin for the prevention of postpartum hemorrhage. *J Pregnancy* 2014;2014 713879.
- Schlesinger D, Benedict S, Diederich C, Gedroyc W, Klibanov A, Larner J. MR-guided focused ultrasound surgery, present and future. *Med Phys* 2013;40 080901.
- Stewart EA, Gedroyc WM, Tempany CM, Quade BJ, Inbar Y, Ehrenstein T, Shushan A, Hindley JT, Goldin RD, David M, Sklair M, Rabinovici J. Focused ultrasound treatment of uterine fibroid tumors: Safety and feasibility of a noninvasive thermoablative technique. *Am J Obstet Gynecol* 2003;189:48–54.
- Stewart EA, Laughlin-Tommaso SK, Catherino WH, Lalitkumar S, Gupta D, Vollenhoven B. Uterine fibroids. *Nat Rev Dis Primers* 2016;2:16043.
- Verpalen IM, Anneveldt KJ, Nijholt IM, Schutte JM, Dijkstra JR, Franx A, Bartels LW, Moonen CTW, Edens MA, Boomsma MF. Magnetic resonance-high intensity focused ultrasound (MR-HIFU) therapy of symptomatic uterine fibroids with unrestricted treatment protocols: A systematic review and meta-analysis. *Eur J Radiol* 2019;120 108700.
- Vitagliano A, Noventa M, Di Spiezio Sardo A, Saccone G, Gizzo S, Borgato S, Vitale SG, Lagana AS, Nardelli GB, Litta PS, Saccardi C. Uterine fibroid size modifications during pregnancy and puerperium: Evidence from the first systematic review of literature. *Arch Gynecol Obstet* 2018;297:823–835.
- Wang Y, Zhang S, Li C, Li B, Ouyang L. Minimally invasive surgery for uterine fibroids. *Ginekol Pol* 2020;91:149–157.
- Yip SK, Tse AO, Haines CJ, Chung TK. Misoprostol's effect on uterine arterial blood flow and fetal heart rate in early pregnancy. *Obstet Gynecol* 2000;95:232–235.
- Zieman M, Fong SK, Benowitz NL, Banskter D, Darney PD. Absorption kinetics of misoprostol with oral or vaginal administration. *Obstet Gynecol* 1997;90:88–92.