

REVIEW PAPER

DOI: <http://dx.doi.org/10.15446/revfacmed.v65n3.56637>

Acute corneal edema without epithelium compromise. A case report and literature review

Edema de córnea agudo sin compromiso epitelial. Reporte de caso y revisión de literatura

Received: 29/03/2016. Accepted: 26/08/2016.

José Augusto Urrego-Díaz^{1,2} • Juan Sebastián Frías-Ordoñez^{1,2} • Germán Figueroa-Echandía² • Guillermo Durán-Silva^{3,4}

¹ Universidad Nacional de Colombia - Bogotá Campus - Faculty of Medicine - Bogotá D.C. - Colombia.

² Fundación Cardioinfantil - Instituto de Cardiología - Bogotá D.C. - Colombia.

³ Hospital Universitario de la Samaritana Empresa Social del Estado - Department of Ophthalmology - Bogotá D.C. - Colombia.

⁴ Universidad de la Sabana - Faculty of Medicine - Department of Ophthalmology - Bogotá D.C. - Colombia.

Corresponding author: José Augusto Urrego-Díaz. Calle 163A No. 13B-60. Telephone number: +57 1 6672727. Bogotá D.C. Colombia.
Email: joaurregod@unal.edu.co.

| Abstract |

Acute corneal edema is caused by various factors, with different levels of severity, and various forms of presentation. This paper reports the case of a male patient presenting with acute corneal edema without epithelium compromise, whose clinical picture, ophthalmological examination and additional tests did not reveal its etiology. Also, a review of available literature was conducted looking for all known causes of acute corneal edema, which are classified according to the etiology of the corneal edema into injury or inflammation of the corneal epithelium or stroma, endothelial dysfunction or increase in intraocular pressure.

Keywords: Cornea; Anterior Chamber; Endothelium; Corneal Edema; Etiology; Causality (MeSH).

Urrego-Díaz JA, Frías-Ordoñez JS, Figueroa-Echandía G, Durán-Silva G. Acute corneal edema without epithelium compromise. A case report and literature review. Rev. Fac. Med. 2017;65(3):513-9. English. doi: <http://dx.doi.org/10.15446/revfacmed.v65n3.56637>.

| Resumen |

El edema de córnea es una entidad que se produce por un gran número de causas y tiene diversas formas de presentación y diferentes grados de afección. En este artículo se reporta el caso de un hombre con edema de córnea agudo sin compromiso epitelial, en el que el cuadro clínico, el examen oftalmológico y los estudios de extensión no lograron establecer su etiología. Además, se hace una revisión de la literatura disponible respecto a todas las posibles causas de edema de córnea agudo, agrupándolas en aquellas que ocasionan el edema por lesión o inflamación epitelial o estromal, por disfunción endotelial o por un aumento en la presión intraocular.

Palabras clave: Córnea; Cámara anterior; Epitelio posterior; Edema; Etiología; Causalidad (DeCS).

Urrego-Díaz JA, Frías-Ordoñez JS, Figueroa-Echandía G, Durán-Silva G. [Edema de córnea agudo sin compromiso epitelial. Reporte de caso y revisión de literatura]. Rev. Fac. Med. 2017;65(3):513-9. English. doi: <http://dx.doi.org/10.15446/revfacmed.v65n3.56637>.

Introduction

The cornea is a transparent avascular tissue exposed to the external environment and responsible for about two thirds of the refractive power of the human eye (1). Its transparency depends on a dehydration state regulated by the inner (endothelium) and external (corneal epithelium) layers (2) that maintain a careful hydroelectrolytic balance to guarantee low levels of water. Corneal endothelial cells play a major role in this equilibrium as they carry sodium and bicarbonate ions from the corneal stroma to the anterior chamber, so that water flows passively out of the cornea preventing edematization, which would damage its transparency (3,4).

Acute corneal edema may present with different levels of endothelial, stromal or epithelial involvement (5). Two pathophysiological mechanisms that are prominent in the production of acute corneal edema without epithelial compromise include alterations in endothelial function and elevation of intraocular pressure (6). This paper reports the case of a patient with unilateral sudden corneal edema without epithelial compromise, in whom a clear cause was not established, thus motivating this investigation.

It is worth noting that, according to the objectives of this paper, some known causes of corneal edema, such as posterior corneal dystrophies or iridocorneal syndrome (7-9), are not included because of their chronic nature.

Case presentation

This paper reports the case of a 38-year-old male patient with motor and speech disability, who was taken by relatives to the emergency room reporting symptoms of eight days of evolution consisting of decreased visual acuity in the left eye, white coloration in the cornea

and red eye. The last symptom resolved after management with topical self-medicated vasoconstrictors, but the relatives went to the ophthalmology service after noticing that the bad vision persisted.

The patient had an ischemic stroke in the distal third of the left carotid artery two months before the onset of the symptoms, which required three surgical interventions: mechanical thrombectomy of the anterior cerebral artery and left middle cerebral artery with complete and partial recanalization respectively, decompressive craniectomy, and autologous cranioplasty. In consequence, the patient presented with a predominantly mixed motor aphasia and right hemibody paresis. Also, after being discharged, the patient was prescribed with 40mg of atorvastatin per day, 100mg of acetyl salicylic acid per day, and naproxen or acetaminophen on an occasional basis. In addition, they reported a family history of cardiovascular disease and cataracts.

On visual ophthalmologic examination, visual acuity was close to hand movement, but it could not be accurately determined due to the patient's neurological condition. Additionally, mild chronic hyperemia and an atrophic left temporal pterygium were observed in the conjunctiva of the left eye. A grade 3 diffuse corneal edema was evidenced with folds in the Descemet's membrane but without epithelial alterations (Figure 1 and 2). The cornea of the right eye did not present any alterations, and no fluorescein uptake was observed. The pupil was central and had adequate light reactivity. Finally, no opacities were evident in the lens (Figure 3).

Intraocular pressure detected by Goldman's tonometer was 16 mmHg. The bottom of both eyes was completely normal, as well as the excavation of the optic disc. Treatment with topical prednisolone (1 drop every 3 hours for 3 weeks) was initiated with no improvement of the edema. Given the persistence of the opacity in the cornea and the associated visual deficit reported by his relatives, a corneal transplant was recommended to the patient as a definitive alternative.

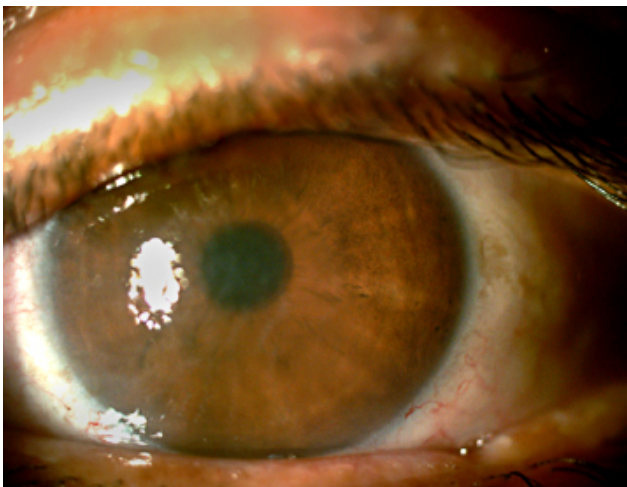


Figure 1. Slit lamp under diffuse light in the left eye with generalized edematized cornea.

Source: Own elaboration based on the data obtained in the study.

Causes of acute corneal edema

The causes of acute corneal edema can be divided into three large categories (10): triggered by epithelial or stromal noxas, such as trauma or viral infection (11-13); triggered by endothelial dysfunction, as will be discussed throughout this article; and triggered by elevation of intraocular pressure (IOP) (2).

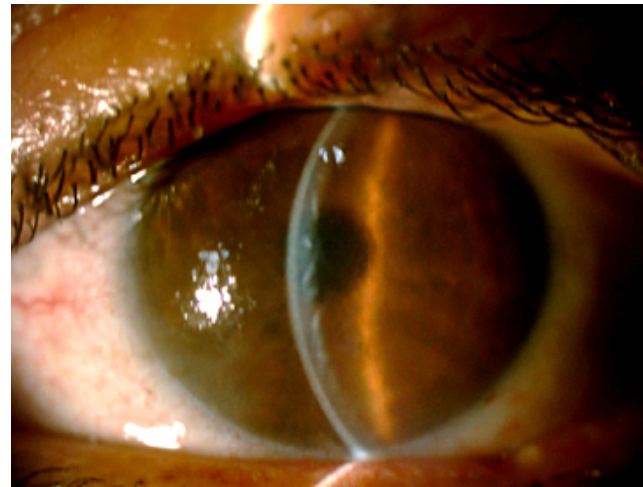

Figure 2. Slit cut under double illumination that allows to observe thickening, opacity and folds of Descemet's membrane.

Source: Own elaboration based on the data obtained in the study.

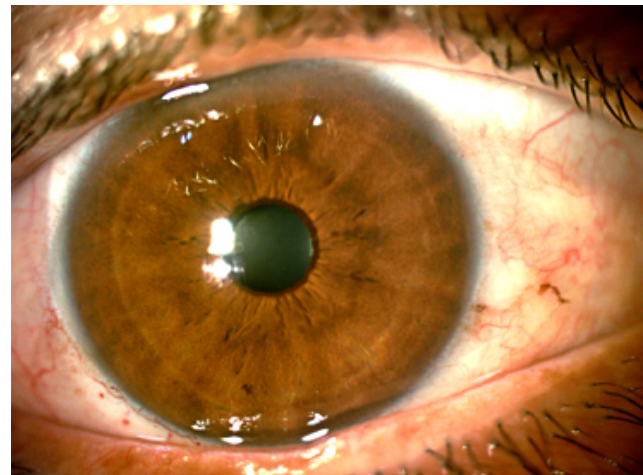


Figure 3. Cornea of the right eye without alterations.

Source: Own elaboration based on the data obtained in the study.

Since the objective of this article is to make an exhaustive review of the causes of corneal edema without epithelial damage and with normal IOP numbers, only the causes that result in edema will be thoroughly reviewed since they affect, one way or another, the dehydrating function of the corneal endothelium.

Regarding other causes, on the one hand, direct trauma, inflammation of the epithelium or corneal stroma may induce endothelial damage, leukocyte migration or rupture of the epithelial barrier (11,16), whereas IOP elevation can be caused when the ability of the endothelium to keep the cornea dehydrated is exceeded. This mechanism may be observed in scenarios such as acute angle-closure glaucoma, endotracheal intubation, and positive pressure ventilation (2).

In other scenarios, this entity is secondary to some alterations in the function of the corneal endothelium, produced by one of the following causes:

Drugs

The use of topical carbonic anhydrase inhibitors (CAI), especially in combination with other topical medications for chronic glaucoma such as latanoprost and timolol, has been reported as one of the causes of acute

corneal edema with a degree of severity as in the case reported in this study (17,18). Inhibiting carbonic anhydrase, which is involved in the expulsion of bicarbonate on the corneal endothelium, may lead to water retention (17). The inability of the epithelial barrier caused by the use of benzalkonium chloride—preservative found in several formulations of ophthalmic eye drops—favors this effect (19,20). Similarly, some association between the use of topical prostaglandin analogues, such as latanoprost and travoprost, and the development of anterior uveitis accompanied by corneal edema has been suggested (21,22).

The development of acute corneal edema secondary to the use of topical mitomycin C in the management of postoperative corneal opacities has been reported as well (23). This drug acts against cancer cells and normal cells during reproduction phases (24), therefore, it may limit subepithelial fibrosis that manifests as corneal opacity (25,26). In the case reported here, the development of the edema was attributed to the toxic effect of mitomycin C over the corneal endothelium, which was facilitated by continuous exposure to this drug in a cornea with denuded epithelium (23).

Aside from topical medications, oral medications are also reported to cause acute corneal edema. This is the case of two NMDA receptor agonists (N-methyl-D-aspartate): amantadine and ketamine (27-30).

Regarding amantadine, there is a relative risk (RR) of 1.7 (95%CI: 1.1-2.8) of developing corneal edema (31), whereas the use of ketamine alone has been clearly associated with only one case (27). This seems to be influenced by the binding of these drugs to NMDA receptors in the corneal endothelium under normal conditions (32), which can lead to the loss of corneal endothelial cells and the subsequent development of edema. In these cases, edema is usually bilateral and decreases after stopping the medication (27,30).

Other non-topical drugs have been considered as possible causes of acute corneal edema, including bacitracin, neomycin, polymyxin B, tetracaine, and phenothiazine (2,33).

Toxins

Some substances, when applied topically on the eye, can trigger endothelial dysfunction with consequent acute corneal edema. Such is the case of cardiac glycosides contained in species such as *Digitalis purpurea* or *Asclepias curassavica*, which may induce acute corneal edema as they inhibit Na⁺-K⁺-ATPase, which in turn participates in endothelial cell functions (34,35).

Foreign bodies in the anterior chamber

In some cases, the development of corneal edema has been attributed to the presence of foreign bodies in the anterior chamber, this edema being the first manifestation of their presence. With this in mind, it is possible to say that, on the one hand, these bodies can produce corneal edema by inducing a local inflammatory response, which damages some endothelial cells. This was reported in the case related to nuclear fragments found in the anterior chamber, even years after phacoemulsification (36,37). On the other, the object itself and its products can directly damage the corneal endothelium, favoring edema as in the case of worms trapped in the anterior chamber (filariasis) (38). Other examples include the presence of cotton waste or other products in the anterior chamber following intraocular surgical interventions (39).

Corneal endothelioma

Corneal endothelitis is an acute inflammatory process limited to the corneal endothelium that can be associated with acute corneal edema.

There are three viruses in the *Herpesviridae* family that can trigger this ophthalmic entity: varicella-zoster virus, HSV (herpes simplex virus) and cytomegalovirus (40-42). In addition, cases of endothelitis caused by *Mixovirus parotiditis* have been reported (43).

This entity manifests as one or multiple acute red eye crisis, with ciliary and pain predominance, and often accompanied by acute corneal edema and keratotic precipitates, with or without manifest uveitis (40,42,44).

Uveitis

Acute corneal edema is a process that can be triggered by local inflammation in uveitis cases, which can damage the corneal endothelium affecting its function (45).

Postoperative period

Post-operative corneal edema is one of the most frequent causes of acute corneal edema (46). This category groups all the cases in which various ocular surgical procedures generate damages that lead to endothelial decompensation (47,48). Some of these procedures include cataract surgery with or without intraocular lens implantation, posterior vitrectomy, retinopexy, trabeculectomy, and other intraocular procedures. Minimally invasive procedures with different lasers such as iridotomy, trabeculoplasty and capsulotomy have also been reported (46,47,49,50).

Corneal edema can appear immediately after phacoemulsification because of the direct effect of this procedure on the surrounding structures, with damage to the endothelial cells and even detachment of the Descemet's membrane (51-54). This edema is mild and transient in most cases, and severe with associated endothelial cell damage in few cases.

Nine cases of corneal edema secondary to laser trabeculoplasty used to treat primary open-angle glaucoma have been reported (49,55-57). In all cases, the edema appeared within the first days after the surgery and resolved in the following weeks or months. In most cases, patients experienced different degrees of corneal opacities as sequelae; thinning of the cornea posterior to the edema with hypermetropic changes was evidenced in 6 of them.

Although the cause is not clear, two possible mechanisms have been proposed: first, changes in endothelial cells documented after laser trabeculoplasty can lead to corneal edema in extreme cases (58,59), and second, although highly unlikely, it may be secondary to the reactivation of HSV (57) since these patients were using topical prostaglandin analogs, which have been associated with this effect (60,61). This mechanism, added to inflammation induced by the surgical procedure, could cause an edema process.

The possibility of acute corneal edema due to the direct effect of the intraocular solutions used in surgery to maintain the anterior segment should be considered. Depending on their physico-chemical characteristics, these solutions can overcome the physiological resistance of the corneal endothelium, which tolerates changes in pH between 6.8 and 8.2, and osmolality variations of 200 to 450 mOsm (48,62). Thus, substances that test these resistance limits, as reported with the accidental instillation of CAI dissolved in distilled water with 0 mOsm (63), may cause acute corneal edema.

Similarly, depending on its components, some of these solutions may directly damage the endothelial barrier, as reported in components such as sodium bisulfate, thimerosal, chlorhexidine and even carbachol. These effects are favored by longer surgical interventions or by endothelium with preexisting damages (64,65).

Systemic diseases

The development of corneal edema has been reported in some mitochondrial diseases such as Pearson's syndrome, Kearns-Sayre syndrome or chronic progressive external ophthalmoplegia (66-69). These types of edemas are frequently chronic; however, some acute and even self-corrective cases have been reported, which can be attributed to acute decompensations of the patient's general condition, thus intensifying the failure of mitochondrial function (66,70).

Some rheumatologic diseases have been recognized as a cause of acute corneal edema, for example polyarteritis nodosa or Reiter's syndrome (9). On rare occasions, other systemic diseases such as Werner's syndrome, Zellweger's syndrome, facomatosis, Refsum's disease and serum sickness (usually bilateral) may lead to acute corneal edema (9).

Hypoxia

Corneal hypoxia can lead to edematization by causing endothelial dysfunction and alterations in corneal metabolism (71). Some examples include mild edema after using contact lenses or an oppressive occlusion (71,72); for the latter case, edema is proposed as the product of a mixture between corneal hypoxia and IOP elevation (73). Furthermore, chronic endothelial diseases such as Fuchs endothelial dystrophy or iridocorneal endothelial syndrome usually begin with predominantly morning edemas secondary to nocturnal palpebral closure, which generates some degree of corneal hypoxia.

Moreover, acute corneal edema can be triggered by endothelial ischemia in a rather unusual scenario, as reported by Nielsen *et al.* (74), who described the case of a patient with temporal arteritis and acute ischemia of the anterior segment of the eye who developed associated acute corneal edema and a decrease of 72% in the count of endothelial cells.

Environment

Based on case reports and biological plausibility, it has been proposed that cold may predispose to the development of acute corneal edema or trigger its onset in predisposed persons, particularly in high wind conditions. These conditions favor the evaporation of the tear film and inhibit the endothelial pump, which promotes the accumulation of water in the cornea (75).

Corneal ectasia

An acute corneal edema, known as acute corneal hydrops, has been reported on several occasions. It occurs in different corneal ectasias such as keratoconus, pellucid marginal degeneration, Terrien marginal degeneration, keratectasia after laser in situ keratomileusis (LASIK) and keratectasia after radial keratotomy (76-79). This entity occurs due to the rupture of a decemet membrane weakened and deformed by corneal ectasia, usually after mechanical stress, which often corresponds to scraping of the eye (80). This rupture leaves a space that allows the passage of fluids from the anterior chamber to the cornea, thus producing acute corneal edema (81).

Idiopathic

To date, nine cases of unknown causes have been reported, which are characterized by sudden unilateral corneal edemas with multiple parallel lines in the endothelium, associated with visual loss without pain. These are known as self-limited corneal edemas with multiple

parallel lines on the endothelium (SCEMPLE) (82-84). Nevertheless, all these cases show a typical characteristic that was not found in the case reported here: the presence of parallel horizontal dotted lines along the corneal endothelium, visible by slit lamp, that correspond to detached endothelial cells grouped in aligned clusters (82). In addition, these symptoms resolved after a week without any kind of sequel.

A specific idiopathic entity was reported on a single occasion, which the authors called brush cell endotheliopathy (14). Such report presented the case of a woman with an acute crisis of corneal edema of 14 years accompanied by red eye and pain, with evidence of focal bullous keratopathy by slit lamp examination, and interdigitations in the margins of the endothelial cells, similar to a zipper, observed using confocal microscopy *in vivo*. The picture progressed over the years in terms of endothelial damage and the degree of corneal opacity, until a penetrating keratoplasty was necessary.

Discussion

Since the mid-twentieth century, the need for a constant state of corneal dehydration was recognized to ensure transparency, and the physiological mechanisms for the fulfillment of this task were clarified (85). To maintain this state, intact epithelium and endothelium are required.

The epithelium is a semipermeable membrane that allows the passage of water, but not of salts, and is located next to the precorneal fluid, the innermost portion of the tear film (86). Fluids are taken to a hypertonic state by the constant evaporation of water, which is compensated by the water leaving the cornea through the epithelium (86,87). However, this mechanism is of little importance compared to the pump function of the corneal endothelium, which passively entrains the water from the cornea by actively expelling sodium and bicarbonate towards the anterior chamber (3). The alteration of these processes, mostly by mechanisms that somehow alter endothelial function, can trigger corneal edema.

Since there was no epithelial compromise in the case reported here, the causes related to such compromise (traumas and infections) were ruled out. In addition, during the first consultation and subsequent check-ups, the patient presented normal IOP, so acute cornea edema caused by IOP elevation was discarded.

Regarding the causes mentioned in this article, medication did not appear to be the cause of the acute corneal edema presented by the patient, since he only used atorvastatin and non-steroidal anti-inflammatory drugs (NSAIDs), which have never been associated with this pathology. Also, it is very unlikely that he was exposed to toxins, especially considering his disability status.

The manifestations and signs of the patient did not suggest at all the presence of a foreign body in the anterior chamber or corneal ectasias, uveitis, corneal endothelitis, any event associated with corneal hypoxia or any of the systemic diseases associated with acute corneal edema mentioned in this article.

On the other hand, the environment, rather than being a cause, seems to be a trigger in predisposed people or a factor of what could be understood as acute multifactorial cornea edema. Actually, only one case in which cold and windy conditions are related to acute corneal edema has been reported; it occurred in an athlete clearly exposed to these conditions, in whom predisposing causes were not ruled out (75).

All of this leads to think that the most viable possibility in this case is acute corneal edema similar to those reported in the idiopathic category. The clinical picture of the patient did not meet the criteria of any of the two idiopathic entities mentioned, and slit lamp examination

did not show any of their characteristics. However, other cases of idiopathic acute corneal edema that are unknown or that have not been considered by the scientific literature may exist, although this is a thorough review. In any case, this is an unusual picture that could be the first or, at most, one of the first of its kind, for which the current scientific knowledge does not seem to be sufficient to elucidate its etiology, pathophysiology and optimal management.

Finally, it should be reiterated that, as described in several articles, the differential diagnosis of corneal edema of unclear cause can be established based on the endothelial characteristics observed by specular microscopy or confocal microscopy *in vivo* (7,10,88). In this case, none of these methods was available, which could have expanded the studies.

Conclusions

This review shows that the causes of corneal edema are multiple, both in relation to the underlying pathophysiological mechanism and the clinical presentation of the patient. These causes can be classified, based on the mechanism, into those that damage the corneal epithelium, an elevation of intraocular pressure and corneal endothelial dysfunction.

In most cases, the etiology can be suspected or confirmed by a good medical history and a comprehensive ophthalmological examination. In a few cases, like this patient, this does not seem to be enough. The case reported here may relate to a poor description in the scientific literature of idiopathic corneal edema, which, like others categorized as idiopathic, has not been adequately understood by the scientific community.

We expect that this report, along with other articles that will contribute to this topic in the future, may shed some light on this unusual presentation.

Author contribution statement

JAUD summarized the case and conducted the search of the scientific literature. JAUD and JSFO reviewed the content of the articles found and created a preliminary version of this article. GFE and GDS reviewed, completed and corrected this version.

Conflict of interest

None stated by the authors.

Funding

None stated by the authors.

Acknowledgement


None stated by the authors.

References

1. Meek KM, Boote C. The organization of collagen in the corneal stroma. *Exp Eye Res.* 2004;78(3):503-12. <http://doi.org/dsmgvz>.
2. Fleisher KE, Hirsch DL, Pahlavi IA, Glickman R. Severe corneal edema after temporomandibular joint reconstruction: report of a case. *J Oral Maxillofac Surg.* 2004;62(10):1324-6. <http://doi.org/cntdnh>.
3. Bonanno JA. Identity and regulation of ion transport mechanisms in the corneal endothelium. *Prog Retin Eye Res.* 2003;22(1):69-94. <http://doi.org/d327dz>.
4. Quiroga R, Klintworth GK. The pathogenesis of corneal edema induced by Tween 80. *Am J Pathol.* 1967;51(6):977-99.
5. Krachmer JH, Mannis MJ, Holland EJ. *Cornea.* 2nd ed. London: Elsevier Mosby; 2005.
6. Levenson JE. Corneal edema: cause and treatment. *Surv Ophthalmol.* 1975;20(3):190-204. <http://doi.org/csw9st>.
7. Laganowski HC, Sherrard ES, Muir MG, Buckley RJ. Distinguishing features of the iridocorneal endothelial syndrome and posterior polymorphous dystrophy: value of endothelial specular microscopy. *Br J Ophthalmol.* 1991;75(4):212-6. <http://doi.org/fkxzwd>.
8. Hamill CE, Schmedt T, Jurkunas U. Fuchs endothelial cornea dystrophy: a review of the genetics behind disease development. *Semin Ophthalmol.* 2013;28:281-6. <http://doi.org/b67w>.
9. Satterfield D, Mannis MJ. Episodic bilateral corneal edema caused by hair groom gel. *Am J Ophthalmol.* 1992;113(1):107-8. <http://doi.org/b67x>.
10. Grupcheva CN, Craig JP, Sherwin T, McGhee CN. Differential diagnosis of corneal oedema assisted by *in vivo* confocal microscopy. *Clin Exp Ophthalmol.* 2001;29(3):133-7. <http://doi.org/dssxvg>.
11. Kumano Y, Yamamoto M, Iwasaki M, Ishibashi T, Inomata H, Mori R. Participation of T lymphocyte in corneal edema in the early stage of herpetic stromal keratitis. *Ophthalmologica.* 1988;196(3):113-25. <http://doi.org/c8srgz>.
12. Gris O, Güell JL, Wolley-Dod C, Adán A. Diffuse lamellar keratitis and corneal edema associated with viral keratoconjunctivitis 2 years after laser *in situ* keratomileusis. *J Cataract Refract Surg.* 2004;30(6):1366-70. <http://doi.org/fjbv5c>.
13. Leshner MP, Durrie DS, Stiles MC. Corneal edema, hyphema, and angle recession after air bag inflation. *Arch Ophthalmol.* 1993;111(10):1320-2. <http://doi.org/c3dkkc>.
14. Hillenaar T, Mooy CM, Verjans GM, Remeijer L. Zipper cell endotheliopathy: a new subset of idiopathic corneal edema. *Ophthalmology.* 2010;117(12):2255-62. <http://doi.org/dgz72x>.
15. Doughman DJ. Acute unilateral central corneal edema. *Am J Ophthalmol.* 1977;84(4):596-7. <http://doi.org/b67z>.
16. Chusid MJ, Nelson DB, Meyer LA. The role of the polymorphonuclear leukocyte in the induction of corneal edema. *Invest Ophthalmol Vis Sci.* 1986;27(10):1466-9.
17. Tanimura H, Minamoto A, Narai A, Hirayama T, Suzuki M, Mishima HK. Corneal edema in glaucoma patients after the addition of brinzolamide 1% ophthalmic suspension. *Jpn J Ophthalmol.* 2005;49(4):332-3. <http://doi.org/btv3r9>.
18. Konowal A, Morrison JC, Brown SVL, Cooke DL, Maguire LJ, Verdier DV, et al. Irreversible corneal decompensation in patients treated with topical dorzolamide. *Am J Ophthalmol.* 1999;127(4):403-6. <http://doi.org/fr6b4>.
19. Aoyama Y, Motoki M, Hashimoto M. [Effect of various anti-glaucoma eyedrops on human corneal epithelial cells]. *Nihon Ganka Gakkai Zasshi.* 2004;108(2):75-83.
20. Yamada E, Yamada H, Yamazaki Y, Matsumura M. A case of severe corneal damage due to Rysmon TG ophthalmic solution. *Folia Ophthalmol Jpn.* 2002;53(10):800-3.
21. Faulkner WJ, Burk SE. Acute anterior uveitis and corneal edema associated with travoprost. *Arch Ophthalmol.* 2003;121(7):1054-5. <http://doi.org/ckt3wc>.
22. Warwar RE, Bullock JD, Ballal D. Cystoid macular edema and anterior uveitis associated with latanoprost use. Experience and incidence in a retrospective review of 94 patients. *Ophthalmology.* 1998;105(2):263-8. <http://doi.org/c3b8ns>.
23. Pfister RR. Permanent corneal edema resulting from the treatment of PTK corneal haze with mitomycin: a case report. *Cornea.* 2004;23(7):744-7. <http://doi.org/fsxnhk>.

24. Goodman-Gilman A, Rall TW, Nies AS, Tayler P. The Pharmacological Basis of Therapeutics. 8th ed. Elmsford: Pergamon Press; 1990.
25. Winkler von Mohrenfels C, Hermann W, Gabler B, Müller M, Marshall J, Lohmann CP. [Topical Mitomycin C for the prophylaxis of recurrent haze after excimer laser photorefractive keratectomy (PRK) - a pilotstudy of 5 patients]. *Klin Monbl Augenheilkd.* 2001;218(12):763-7.
26. Kottler UB, Dick HB. [Mitomycin C in refractive corneal surface surgery with the excimer laser: first experience and review of the literature]. *Klin Monbl Augenheilkd.* 2005;222(6):499-504. <http://doi.org/fgf2ws>.
27. Starte JM, Fung AT, Kerdraon YA. Ketamine-associated corneal edema. *Cornea.* 2012;31(5):572-4. <http://doi.org/b672>.
28. Chang KC, Jeong JH, Kim MK, Wee WR, Lee JH, Jeon BS. The effect of amantadine on corneal endothelium in subjects with Parkinson's disease. *Ophthalmology.* 2010;117(6):1214-9. <http://doi.org/cgzgpb>.
29. Jeng BH, Galor A, Lee MS, Meisler DM, Hollyfield JG, Schoenfield L, et al. Amantadine-associated corneal edema potentially irreversible even after cessation of the medication. *Ophthalmology.* 2008;115(9):1540-4. <http://doi.org/bbgqgs>.
30. Deogaonkar M, Wilson K, Vitek J. Amantadine induced reversible corneal edema. *J Clin Neurosci.* 2011;18(2):298-9. <http://doi.org/fr4bb8>.
31. French DD, Margo CE. Postmarketing surveillance of corneal edema, Fuchs dystrophy, and amantadine use in the Veterans Health Administration. *Cornea.* 2007;26(9):1087-9. <http://doi.org/d54f6m>.
32. Shippy S, Pulido JS, Qian H, Nelson JD, Lu MJ. Evidence for corneal glutamate receptor expression and function. *Investigative Ophthalmology & Visual Science.* 2007;48(13):3472.
33. Oshika T, Itotagawa K, Sawa M. Severe corneal edema after prolonged use of psychotropic agents. *Cornea.* 1991;10(4):354-7. <http://doi.org/fttchj>.
34. Smith JL, Mickatavage RC. The ocular effects of topical digitalis. *Am J Ophthalmol.* 1963;56(6):889-94. <http://doi.org/b674>.
35. Chakraborty S, Siegenthaler J, Büchi ER. Corneal edema due to *Asclepias curassavica*. *Arch Ophthalmol.* 1995;113(8):974-5. <http://doi.org/d9frqm>.
36. Pandit RT, Coburn AG. Sudden corneal edema due to retained lens nuclear fragment presenting 8.5 years after cataract surgery. *J Cataract Refract Surg.* 2011;37(6):1165-7. <http://doi.org/c9p8ff>.
37. Hui JI, Fishler J, Karp CL, Shuler MF, Gedde SJ. Retained nuclear fragments in the anterior chamber after phacoemulsification with an intact posterior capsule. *Ophthalmology.* 2006;113(11):1949-53. <http://doi.org/dk2mmc>.
38. Basak SK, Hazra TK, Bhattacharya D. Persistent corneal edema secondary to presumed dead adult filarial worm in the anterior chamber. *Indian J Ophthalmol.* 2007;55(1):67-9. <http://doi.org/ftmtr6>.
39. Brown SI. Corneal edema from a cotton foreign body in the anterior chamber. *Am J Ophthalmol.* 1968;65(4):616-7.
40. Sundmacher R, Müller O. [The corneal endothelium in ophthalmic zoster (author's transl)]. *Klin Monbl Augenheilkd.* 1982;180(4):271-4.
41. Maudgal PC, Missotten L, De Clercq E, Descamps J. Varicella-zoster virus in the human corneal endothelium: a case report. *Bull Soc Belge Ophthalmol.* 1980;190:71-86.
42. Alfawaz A. Cytomegalovirus-related corneal endotheliitis: A review article. *Saudi J Ophthalmol.* 2013;27(1):47-9. <http://doi.org/bfpjvq>.
43. Singh K, Sodhi PK. Mumps-induced corneal endotheliitis. *Cornea.* 2004;23(4):400-2. <http://doi.org/c42jxh>.
44. Chee SP, Bacsal K, Jap A, Se-Thoe SY, Cheng CL, Tan BH. Clinical features of cytomegalovirus anterior uveitis in immunocompetent patients. *Am J Ophthalmol.* 2008;145(5):834-40. <http://doi.org/d4tw7t>.
45. Choi WJ, Pepple KL, Zhi Z, Wang RK. Optical coherence tomography based microangiography for quantitative monitoring of structural and vascular changes in a rat model of acute uveitis in vivo: a preliminary study. *J Biomed Opt.* 2015;20(1):016015. <http://doi.org/b683>.
46. Cordeiro Barbosa MM, Barbosa JB, Hirai FE, Hofling-Lima AL. Effect of cross-linking on corneal thickness in patients with corneal edema. *Cornea.* 2010;29(6):613-7. <http://doi.org/d4x9pz>.
47. Pires RT, Tseng SC, Prabhasawat P, Puangsricharn V, Maskin SL, Kim JC, et al. Amniotic membrane transplantation for symptomatic bullous keratopathy. *Arch Ophthalmol.* 1999;117(10):1291-7. <http://doi.org/b684>.
48. Edelhauser HF, Hanneken AM, Pederson HJ, Van Horn DL. Osmotic tolerance of rabbit and human corneal endothelium. *Arch Ophthalmol.* 1981;99(7):1281-7. <http://doi.org/cqtfcm>.
49. Moubayed SP, Hamid M, Choremis J, Li G. An unusual finding of corneal edema complicating selective laser trabeculoplasty. *Can J Ophthalmol.* 2009;44(3):337-8. <http://doi.org/c5273h>.
50. Mansour AM, Hrisomalos N. Corneal edema as a complication of a loose retinal tack. *Arch Ophthalmol.* 1987;105(10):1326. <http://doi.org/c56v3r>.
51. Hughes EH, Mellington FE, Whitefield LA. Aqualase for cataract extraction. *Eye.* 2007;21(2):191-4. <http://doi.org/bjbrzb>.
52. Fine IH, Packer M, Hoffman RS. New phacoemulsification technologies. *Journal of Cataract & Refractive Surgery.* 2002;28(6):1054-60. <http://doi.org/d42wpz>.
53. Labiris G, Gatziofas Z, Giarmoukakis A, Sideroudi H, Kozobolis VP. Liquefaction versus torsional IP: a comparative study on endothelial cells, corneal edema and corneal sensitivity. *Ophthalmic Res.* 2013;49(1):37-42. <http://doi.org/f4gjnq>.
54. Watson SL, Abiad G, Coroneo MT. Spontaneous resolution of corneal oedema following Descemet's detachment. *Clin Exp Ophthalmol.* 2006;34(8):797-9. <http://doi.org/bqht7w>.
55. Regina M, Bunya VY, Orlin SE, Ansari H. Corneal edema and haze after selective laser trabeculoplasty. *J Glaucoma.* 2011;20(5):327-9. <http://doi.org/cth2tj>.
56. Song J, Yu D, Song A, Palmares T, Song HS, Song M. Corneal thinning and opacity following selective laser trabeculoplasty: a case report. *Br J Med Med Res.* 2014;4(1):279-87. <http://doi.org/b69b>.
57. Knickelbein JE, Singh A, Flowers BE, Nair UK, Eisenberg M, Davis R, et al. Acute corneal edema with subsequent thinning and hyperopic shift following selective laser trabeculoplasty. *J Cataract Refract Surg.* 2014;40(10):1731-5. <http://doi.org/f2vd6v>.
58. Ong K, Ong L, Ong L. Corneal endothelial changes after selective laser trabeculoplasty. *Clin Exp Ophthalmol.* 2013;41(6):537-40. <http://doi.org/f5cb89>.
59. Ong K, Ong L, Ong LB. Corneal Endothelial Abnormalities After selective laser trabeculoplasty (SLT). *J Glaucoma.* 2015;24(4):286-90. <http://doi.org/f67smd>.
60. Kroll DM, Schuman JS. Reactivation of herpes simplex virus keratitis after initiating bimatoprost treatment for glaucoma. *Am J Ophthalmol.* 2002;133(3):401-3. <http://doi.org/bp9r2f>.
61. Wand M, Gilbert CM, Liesegang TJ. Latanoprost and herpes simplex keratitis. *Am J Ophthalmol.* 1999;127(5):602-4. <http://doi.org/ds5j7v>.
62. Gonnering R, Edelhauser HF, Van Horn DL, Durant W. The pH tolerance of rabbit and human corneal endothelium. *Invest Ophthalmol Vis Sci.* 1979;18(4):373-90.
63. Grimmitt MR, Williams KK, Broecker G, Edelhauser HF. Corneal edema after miocchol. *Am J Ophthalmol.* 1993;116(2):236-8. <http://doi.org/b69d>.
64. Mac Rae SM, Edelhauser HF. Postoperative corneal edema. *Am J Ophthalmol.* 1983;95(4):552-4. <http://doi.org/b69f>.
65. Fraunfelder FT. Corneal edema after use of carbachol. *Arch Ophthalmol.* 1979;97(5):975. <http://doi.org/db8hcr>.

66. Momont AC, Trobe JD. Transient corneal edema and left hemisphere dysfunction in Pearson syndrome. *J Neuroophthalmol*. 2009;29(2):158-9. <http://doi.org/bmts5k>.
67. Lee HF, Lee HJ, Chi CS, Tsai CR, Chang TK, Wang CJ. The neurological evolution of Pearson syndrome: case report and literature review. *Eur J Paediatr Neurol*. 2007;11(4):208-14. <http://doi.org/d4qv2z>.
68. Chang TS, Johns DR, Stark WJ, Drachman DB, Green WR. Corneal decompensation in mitochondrial ophthalmoplegia plus (Kearns-Sayre) syndrome. A clinicopathologic case report. *Cornea*. 1994;13(3):269-73. <http://doi.org/chqjk3>.
69. Colyer MH, Bower KS, Ward TP, Hidayat AA, Subramanian PS. Mitochondrial myopathy presenting with segmental corneal oedema and retrocorneal membrane. *Br J Ophthalmol*. 2007;91(5):696-7. <http://doi.org/cknf2r>.
70. Boonstra F, Claerhout I, Hol F, Smit G, van Collenburg J, Meire F. Corneal decompensation in a boy with Kearns-Sayre syndrome. *Ophthalmic Genet*. 2002;23(4):247-51. <http://doi.org/d38s93>.
71. Bonanno JA. Effects of contact lens-induced hypoxia on the physiology of the corneal endothelium. *Optom Vis Sci*. 2001;78(11):783-90. <http://doi.org/c8k4b4>.
72. Oh JH, Yoo C, Kim YY, Kim HM, Song JS. The effect of contact lens-induced corneal edema on Goldmann applanation tonometry and dynamic contour tonometry. *Graefes Arch Clin Exp Ophthalmol*. 2009;247(3):371-5. <http://doi.org/bv67q7>.
73. Levy B, Nguyen N, Abbott RL, Gee M, Sviedrys A. Hypotony and corneal edema secondary to patching in normal eyes. *Optom Vis Sci*. 1992;69(1):72-5. <http://doi.org/dm445c>.
74. Nielsen NV, Eriksen JS, Olsen T. Corneal edema as a result of ischemic endothelial damage: a case report. *Ann Ophthalmol*. 1982;14(3):276-8.
75. Ettl AR, Felber SR, Rainer J. Corneal edema induced by cold. *Ophthalmologica*. 1992;204(3):113-4. <http://doi.org/dm66j9>.
76. Tuft SJ, Gregory WM, Buckley RJ. Acute corneal hydrops in keratoconus. *Ophthalmology*. 1994;101(10):1738-44. <http://doi.org/b69g>.
77. Sharma N, Maharana PK, Jhanji V, Vajpayee RB. Management of acute corneal hydrops in ectatic corneal disorders. *Curr Opin Ophthalmol*. 2012;23(4):317-23. <http://doi.org/b69h>.
78. Pouliquen Y, D'Hermies F, Puech M, Dhermy P, Goichot-Bonnat L, Savoldelli M. Acute corneal edema in pellucid marginal degeneration or acute marginal keratoconus. *Cornea*. 1987;6(3):169-74. <http://doi.org/fqps5>.
79. Taboureau E, Berthout A, Turut P, Milazzo S. Dégénérescence marginale pellucide compliquée d'un hydrops cornéen aigu spontané. *J Fr Ophthalmol*. 2006;29(6):e13.
80. Grewal S, Laibson PR, Cohen EJ, Rapuano CJ. Acute hydrops in the corneal ectasias: associated factors and outcomes. *Trans Am Ophthalmol Soc*. 1999;97:187-98.
81. Maharana PK, Sharma N, Vajpayee RB. Acute corneal hydrops in keratoconus. *Indian J Ophthalmol*. 2013;61(8):461-4. <http://doi.org/f5csxh>.
82. Le Piane S, Hillenaar T, Remeijer L. Self-limiting corneal edema with multiple parallel lines on the endothelium (SCEMPLE). *Int Ophthalmol*. 2014;34(6):1279-84. <http://doi.org/f6tn6g>.
83. Hori Y, Maeda N, Kosaki R, Inoue T, Tano Y. Three cases of idiopathic "multiple-parallel-line" endotheliitis. *Cornea*. 2008;27(1):103-6. <http://doi.org/ck3tft>.
84. Oxley LA, Carrim ZI. Multiple parallel-line endotheliitis--a form of herpes simplex keratitis? *Optom Vis Sci*. 2012;89(3):E353-5. <http://doi.org/bp67gj>.
85. Cogan DG, Kinsey VE. Physiologic studies on the cornea. *Science*. 1942;95(2476):607-8. <http://doi.org/dhbp3s>.
86. Sarwar M. Factors in the genesis of corneal edema; a slightly different viewpoint of the mode of its production. *Am J Ophthalmol*. 1955;40(1):37-40. <http://doi.org/b69j>.
87. Duke-Elder S, Quilliam JC, Davson H. Some observations on the present position of our knowledge of the intra-ocular fluid. *Br J Ophthalmol*. 1940;24(9):421-44. <http://doi.org/fvp9fp>.
88. Mustonen RK, McDonald MB, Srivannaboon S, Tan AL, Doubrava MW, Kim CK. In vivo confocal microscopy of Fuchs' endothelial dystrophy. *Cornea*. 1998;17(5):493-503. <http://doi.org/cgp2qs>.



IVÁN "IVANQUIO" BENAVIDES
"El niño vacío" – 010
TÉCNICA: TINTA, COLOR DIGITAL