

Oviductal prolapse associated with a leiomyoma in a Hermann's tortoise (*Testudo hermanni*)

*Prolaps van de eileider geassocieerd met een leiomyoom bij een Griekse landschildpad
(Testudo hermanni)*

¹J. Simard, ¹R. Ducatelle, ²A. Van Caelenberg, ¹T. Hellebuyck

¹Department of Pathology, Bacteriology and Avian Diseases, Faculty of Veterinary Medicine, Ghent University, Salisburylaan 133, 9820 Merelbeke, Belgium

²Department of Medical Imaging of Domestic Animals, Faculty of Veterinary Medicine, Ghent University, Salisburylaan 133, 9820 Merelbeke, Belgium

Jules.Simard@UGent.be

ABSTRACT

A twelve-year-old, female Hermann's tortoise (*Testudo hermanni*) was presented with an oviductal prolapse after showing tenesmus for three days prior to presentation. Radiography revealed a soft tissue opacity in the caudal coelomic cavity that ultrasonographically presented as a congested, invaginated tubular structure and was deemed to comprise the left oviduct. After repositioning the oviductal prolapse, coelioscopy confirmed that the invaginated structure consisted of the anterior part of the left oviduct and incorporated a part of the ipsilateral mesovarium and mesosalpinx. A transplastron osteotomy was carried out to perform unilateral salpingectomy and bilateral ovariectomy. A definitive diagnosis of an oviductal leiomyoma was made based on histopathological and immunohistochemical examination of the invaginated part of the oviduct. In the present case, the authors highlight that neoplastic disorders should be considered as a cause of oviductal invagination and prolapse in chelonians. To the authors' knowledge, this is the first report of the diagnosis and successful treatment of an oviductal leiomyoma in a Hermann's tortoise.

SAMENVATTING

Een twaalf jaar oude, vrouwelijke Griekse landschildpad (*Testudo hermanni*) werd aangeboden met een prolaps van het oviduct volgend op tenesmus sinds drie dagen. Radiologisch onderzoek toonde een wekedelenmassa in het caudale coeloom aan die op echografisch onderzoek als een gestuwde, geïnvagineerde tubulaire structuur werd opgemerkt. Tijdens het coelioscopisch onderzoek werd de aanwezigheid bevestigd van een invaginatie van het anterieure deel van het linker oviduct en incorporatie van de ipsilaterale mesovarium en mesosalpinx. Unilaterale salpingectomie en bilaterale ovariectomie werden via transplastronale osteotomie uitgevoerd. De definitieve diagnose van een oviductaal leiomyoom werd gesteld op basis van histopathologisch en immunohistochemisch onderzoek van het geïnvagineerde deel van het oviduct. In deze casuïstiek wordt het belang van tumorale aandoeningen als mogelijke oorzaak bij invaginatie en prolaps van het oviduct bij schildpadden geïllustreerd. Volgens de auteurs is dit de eerste beschrijving van de diagnose en succesvolle behandeling van een oviductaal leiomyoom bij een Griekse landschildpad.

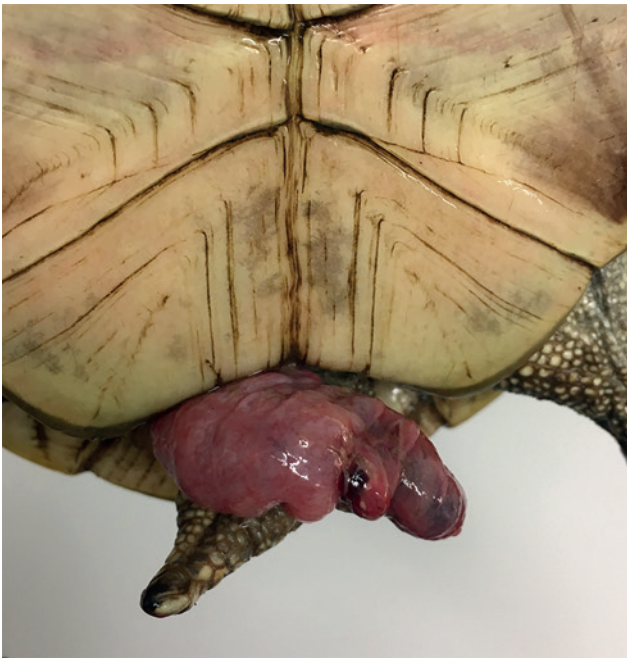

Figure 1. Oviductal prolapse in a Hermann's tortoise (*Testudo hermanni*).

INTRODUCTION

The cloaca of reptiles is a vestibule where the gastrointestinal, urinary and reproductive tract terminate (McArthur and Machin, 2019). Accordingly, a cloacal prolapse in reptiles may consist of everted cloacal tissue or may involve the colon, urinary bladder (chelonians and some lizards), oviduct, hemipenis (snakes and lizards) or phallus/clitoris (chelonians) (Hedley and Eatwell, 2014). Correct identification of the involved anatomical structure may be challenging but is an essential initial step in the diagnostic and therapeutic approach for a cloacal prolapse in reptiles (Music and Strunk, 2017). Prolapse of the phallus or hemipenes is observed most frequently, followed by a prolapse of cloacal tissue or colon, the oviduct and the urinary bladder (Hedley and Eatwell, 2014). Prolapse of the oviduct in reptiles is most frequently associated with dystocia but has also been associated with other reproductive tract disorders, such as salpingitis, oviductal rupture, follicular stasis and oviductal neoplasia (Stahl and DeNardo, 2019). In addition, hypocalcemia, dehydration, systemic infections, uro- and coprolithiasis, obstipation and other space-occupying intracoelomic processes might predispose to the development of oviductal prolapse in reptiles (Stahl and DeNardo, 2019). In the present report, the diagnosis and successful surgical treatment of an oviductal leiomyoma associated with an oviductal prolapse in a Hermann's tortoise (*Testudo hermanni*) are described.

CASE REPORT

A twelve-year-old, female Hermann's tortoise of 1.630 kg was presented with a cloacal organ pro-

lapse after showing decreased appetite and tenesmus for three days. The tortoise was kept individually in an outdoor pen. The applied management was considered adequate. Physical examination revealed the presence of a cloacal organ prolapse that presented as a congested, tubular structure with an approximately diameter of 1.8 cm and a length of 4.5 cm that protruded from the cloacal vent and showed focal dark discolorations, superficial lacerations and hemorrhage (Figure 1). Although longitudinal striation indicative for oviductal tissue was not observed, the prolapsed tissue was considered to comprise the oviduct based on the thick muscular appearance and tubular presentation, luminal patency of the colon and voiding of urine and feces during physical examination (McArthur and Machin, 2019). The tortoise presented active and alert behavior and no other clinical abnormalities were noticed. Parasitological examination of a fecal sample yielded negative results. A blood sample was collected by jugular venipuncture for hematological and biochemical examination at the time of initial presentation and the test results were within physiological reference ranges (Andreani et al., 2014; Leineweber et al., 2019). Dorsoventral and laterolateral full body radiographs were obtained and revealed the presence of an ovoid soft tissue mass (length: 2.3 cm, height: 3.24 cm) with a dense border and slightly more radiolucent center (Figure 2A). Ultrasonographic images were obtained before repositioning the prolapse to avoid interference with assessment of the coelomic cavity (Figure 2B). On ultrasonography, the mass presented as a large, well-defined, luminal structure (2.72 cm x 4.45 cm), heterogeneously filled, with a prominent hypoechoic wall (0.76 – 0.96 cm), which was strongly vascularized based on color flow Doppler sonography (data not shown). A presumptive diagnosis of invagination of the anterior left oviduct was made based on these findings.

Next, cloacoscopy and coelioscopy were performed following induction with 10 mg/kg alfaxalone (Alfaxan®; intravenous injection; Jurox Limited, Crawley, United Kingdom) via the right jugular vein and intubation with an uncuffed 2.5 mm inner diameter endotracheal tube. Anesthesia was maintained with 1.5 - 2 % isoflurane (Isoflo®, Abbott Logistics B.V., Breda, the Netherlands) in 1 L medical oxygen per minute with intermittent positive-pressure ventilation. After the tortoise was positioned in dorsal recumbency, the prolapsed tissue was repositioned in the cloaca and subsequently reduced through the left oviductal papilla under cloacoscopic guidance using a cotton tipped swab. Next, the tortoise was positioned in right lateral recumbency to perform a routine coelioscopy from left prefemoral fossa as previously described by Proença and Divers (2015) and confirmed the presence of an invagination of the anterior part of the left oviduct that incorporated a part of the ipsilateral mesovarium and mesosalpinx (Figure 3). Endoscopy-assisted reduction of the invagination was attempted by performing gentle traction on the

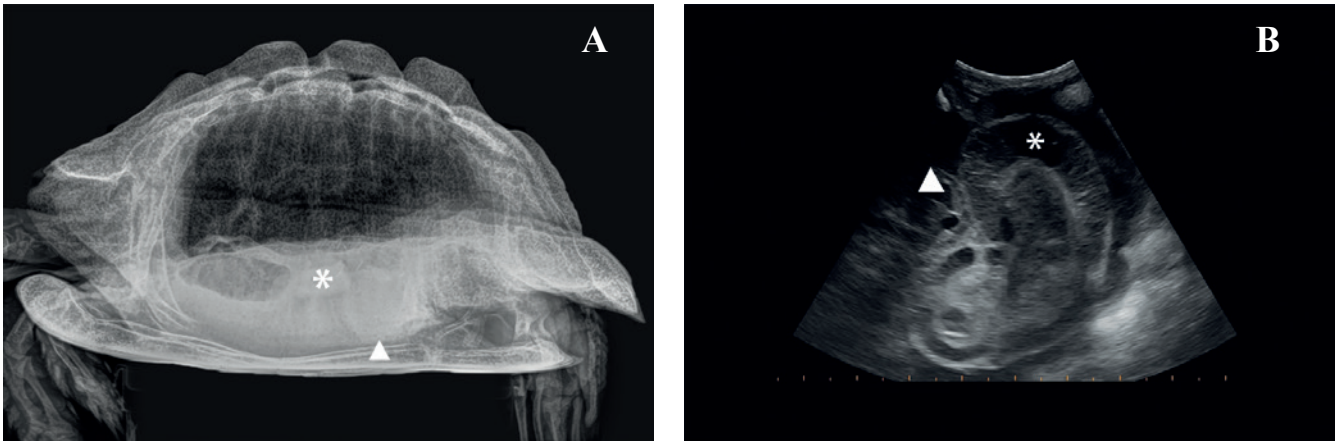


Figure 2. Radiographic and ultrasonographic images from a Hermann's tortoise (*Testudo hermanni*) with an oviductal invagination, primarily associated with an oviductal leiomyoma. **A.** Full body laterolateral radiographic view. An ovoid soft tissue mass (length: 2.3 cm; height: 3.24 cm) with a mild hypodense center in the caudal coelomic cavity (arrowhead) can be observed. A mineralized, irregular structure in gastrointestinal tract is noted in right, mid-coelomic cavity (asterix). **B.** Ultrasonographic image obtained from the left prefemoral fossa showing a thickened and congested oviductal wall (asterix) resulting in a hypoechoic appearance with a small hyperechoic border. An intraluminal heterogeneous echoic appearance is noted. A moderate amount of free coelomic fluid is present (arrowhead).

mesovarium using an atraumatic forceps but was unsuccessful. Accordingly, trapezoidal plastron osteotomy was performed using an oscillating cast saw as previously described by Di Girolamo and Mans (2016), in an endeavor to obtain the desired accessibility of the invaginated structure. The left oviduct was visualized after exteriorization of the left ovary (Figure 4A). Manual reduction of the left oviduct could be achieved but required longitudinal incision of the part of the oviduct that was involved in the invagination over a length of approximately 1 cm (Figure 4B). The anterior part of the oviduct that was previously incorporated in the invagination, showed a thickened wall and a white-yellow glistening mucosal surface. Considering the abnormal appearance of the left oviduct, salpingectomy was performed using bipolar electrocoagulation after applying a Miller's knot with poliglecaprone (Monocryl 4/0, Ethicon, Diegem, Belgium) at the most posterior part of the oviduct. The right oviduct was inspected, but no abnormalities were observed. Subsequently, routine bilateral ovariectomy was performed (Di Girolamo and Mans, 2016). Coelomic inspection revealed no other abnormalities. The coelomic membrane was routinely closed and the plastron osteotomy flap was repositioned and stabilized using a fast-curing two-component resin based on methyl-methacrylate (Technovit® 6091, Kulzer GmbH, Hanau, Germany). Recovery from anesthesia was uneventful. Tramadol (Tramadol EG 50 mg Tablets; 8 mg/kg per orally q48h; Eurogenerics NV, Brussels, Belgium) was chosen as analgesic and given three times. Administration of 20 mg/kg ceftazidime (Glazidim; intramuscular injection q72h; GlaxoSmithKline, Wavre, Belgium) as a prophylactic antibiotic was repeated three times. Epicoelomic fluid therapy was provided for two days to restore perioperative losses. Assist-feeding was provided every three

days until spontaneous food uptake was observed ten days postoperatively. No clinical or ultrasonographic abnormalities could be identified in the tortoise during a control visit that was planned twelve months postoperatively.

At cross section, the infundibulum and uterine tube of the surgically removed oviduct appeared swollen and well vascularized, showing a white-yellow glistening surface on the cut (Figure 4C). Collected tissues were fixed in 10% neutral buffered formalin, processed routinely, embedded in paraffin and stained with hematoxylin and eosin for histopathologic examination. Evaluation of histological sections of the oviduct revealed focal proliferation of smooth muscle cells in a palisading and swirling pattern (Figure 5A). The lamina propria and submucosal tissue of the oviductal wall showed mild but diffuse infiltration with

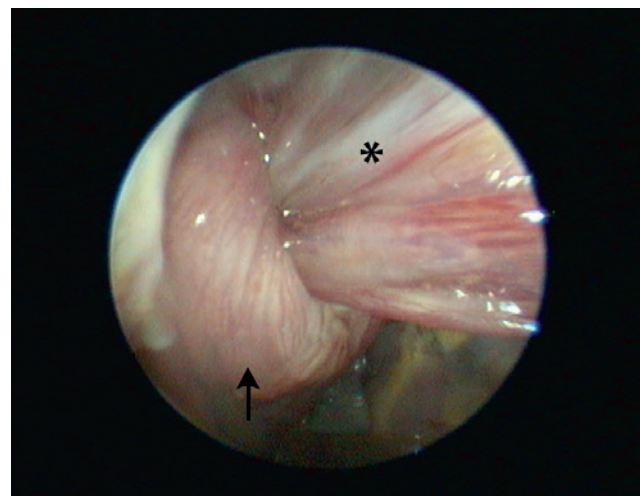


Figure 3. Endoscopic view of an oviductal invagination in a Hermann's tortoise (*Testudo hermanni*). Note the congested oviductal wall (arrow) and incorporation of the ipsilateral mesovarium (asterix).

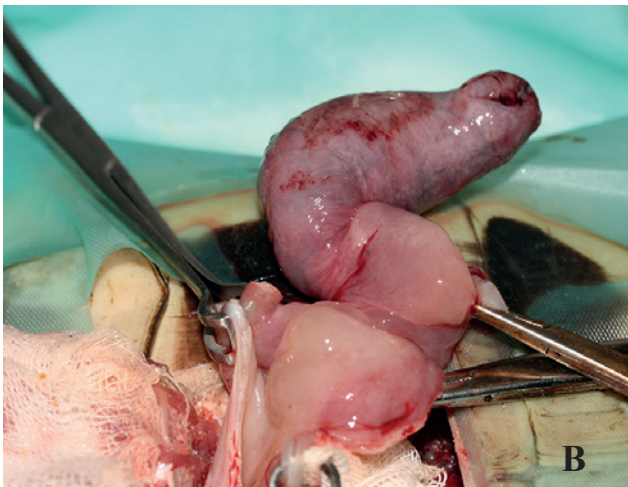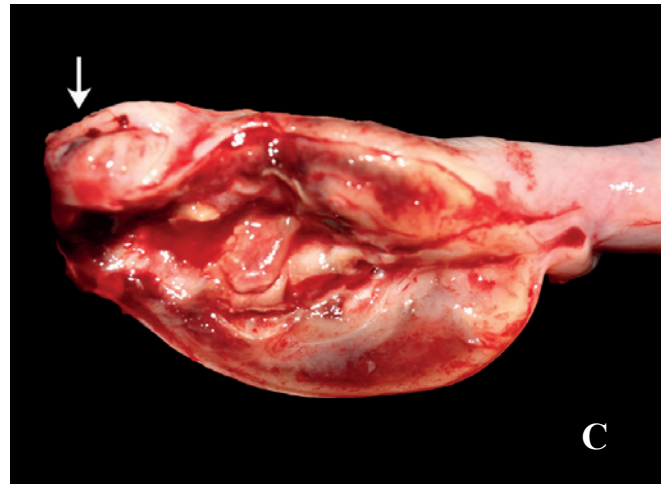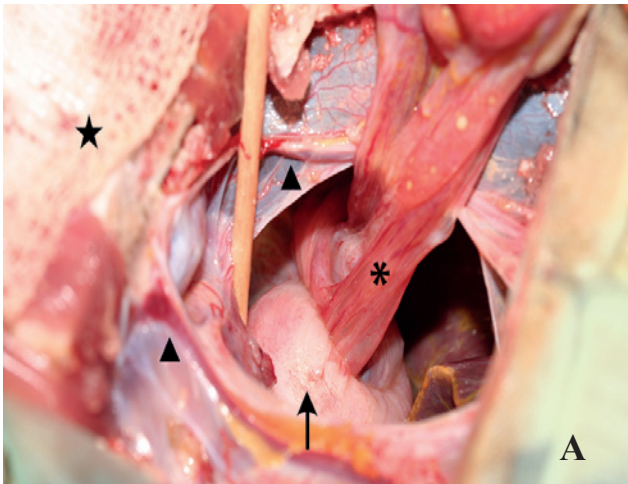


Figure 4. Perioperative images of a plastron osteotomy allowing the surgical approach of the oviductal invagination. **A.** The plastron osteotomy flap is reflected caudally and is covered with a moist sterile compress (star). The coelomic membrane is opened between both abdominal veins (arrowheads) allowing visualization of the invaginated anterior part of the left oviduct. Note the congested oviductal wall (arrow) and the ipsilateral mesovarium and mesosalpinx (asterix) that is incorporated in the invagination. **B.** The incorporated mesentery is released and the invaginated oviduct is retracted after a longitudinal incision was made in the congested oviductal wall. **C.** Longitudinal section view of the anterior oviduct following salpingectomy reveals a swollen, wellvascularized oviductal wall with a white grey to yellow glistening surface on the cut. The ostium of the infundibulum is kept intact (arrow).

heterophils. Immunohistochemical staining using antibodies directed against alpha-smooth muscle actin (α -SMA) was positive (Figure 5B). Based on the histologic examination, a definitive diagnosis of an oviductal leiomyoma was made.

DISCUSSION

Although initially regarded as an unusual condition, neoplastic disorders show an increasing incidence in reptiles, especially in squamates (Mayer and Moore, 2019). In chelonians, the occurrence of neoplastic disorders is less frequently observed, and a limited number of reports have been made in crocodylians (Garner et al., 2004; Mauldin and Done, 2006; Sykes and Trupkiewicz, 2006; Christman et al., 2017). Primary reproductive tract tumors that have been documented in chelonians almost exclusively originate from the gonads and include ovarian teratoma (Newman et al., 2003; Martorell et al., 2009), ovarian dysgerminoma (Machotka et al., 1992; Frye et al., 1994), seminoma (Pees et al., 2015) and testicular interstitial cell adenoma (Frye et al., 1988; Frye et al., 1994). While in squamates, oviductal adenocarcinomas, carcinoma, adenoma and leiomyosarcoma have been de-

scribed (Ramsay et al., 1996; Hernandez-Divers and Garner, 2003; Garner et al., 2004; Mauldin and Done, 2006; Pereira and Viner, 2008; Page-Karjian et al., 2017; Kubiak et al., 2020), only one case of oviductal neoplasia, consisting of an oviductal leiomyoma in a desert tortoise (*Gopherus agassizii*) has been documented (Frye, 1994).

Leiomyomas are mesenchymal tumors arising from smooth muscle cells (Devereaux and Schoolmeester, 2019) and represent the most commonly encountered tumors of the uterus in humans, dogs and cats (Miller et al., 2003; Sabry and Al-Hendy, 2012; Saba and Lawrence, 2013) and the (meso)salpinx in laying hens (Berry et al., 2006; Carrasco and González, 2017). In general, leiomyomas of the uterus or oviduct are considered benign, slow growing and non-invasive with a low metastatic potential (Parker, 2007; Saba and Lawrence, 2013; Carrasco and González, 2017) and often constitute incidental findings that are made during routine surgical procedures or necropsy. Although the exact pathogenesis of uterine and oviductal leiomyomas has not been revealed, in humans, guinea pigs and laying hens, estrogen and progesterone seem to play a predisposing role in the development of leiomyomas by eliciting an increased production of growth factors (e.g. transforming growth factor- β) and cytokines,

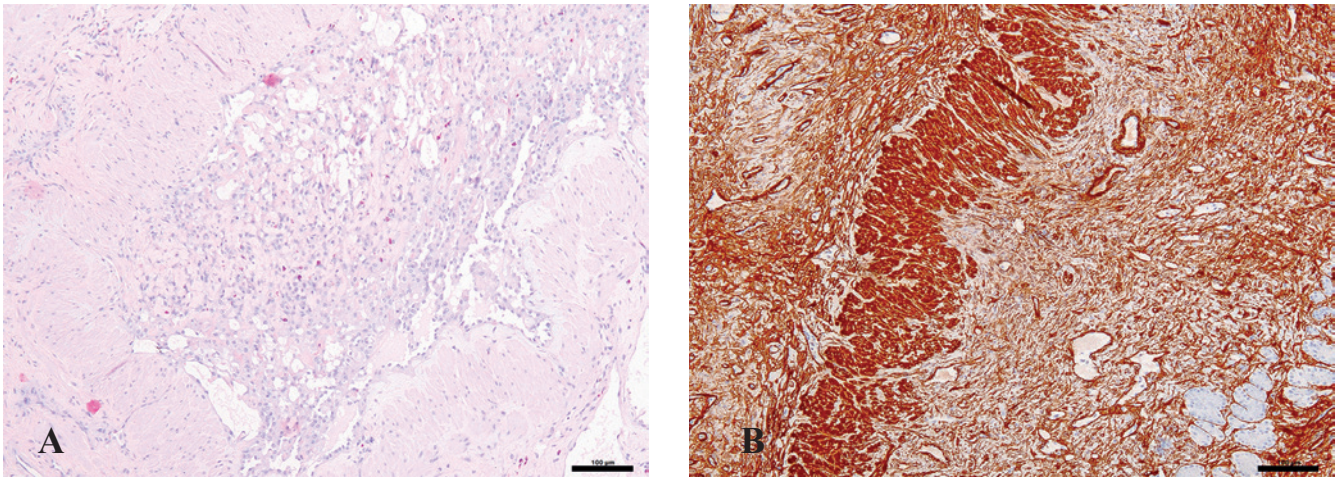


Figure 5. Histological images of an oviductal leiomyoma in a Hermann's tortoise (*Testudo hermanni*). A. Focal proliferation of smooth muscle cells in a palisading and swirling pattern can be observed. Note the diffuse infiltration of the lamina propria and submucosal tissue of the oviductal wall with granulocytes (Hematoxylin and eosin stain; scale bar = 100 μ m). B. Positive immunohistochemical stain with alpha-smooth muscle actin (α -SMA; scale bar = 100 μ m).

which in turn may result in an increase in cell proliferation, cell hypertrophy and/or extracellular matrix (Porter et al., 1995, Sozen and Arici, 2002; Walker and Stewart, 2005, Berry et al., 2006). Consequently, leiomyomas mostly develop during the reproductive years, while regression may be observed during menopause or pseudomenopause (Sabry and Al-Hendy, 2012). Although the presence of estrogen and progesterone receptors have been demonstrated at the level of the oviduct of various reptile species (Girling, 2002), the promoting effect of these hormones towards the development of oviductal leiomyomas has not been studied.

Clinical signs that have been attributed to uterine leiomyomas in humans and conventional pets include infertility, vaginal discharge, pyometra, abdominal pain and the secondary development of urinary tract disease. These signs may be directly associated with the neoplasm but may also result from the space-occupying effect in those cases where uterine leiomyomas reach a considerable size (Miller et al. 2003; Parker, 2007; Nelis et al., 2013; Saba and Lawrence, 2013). In laying hens, leiomyomas appear to have a limited effect on the oviductal function and egg production (Carrasco and González, 2017). In the present case, a cloacal prolapse was seen following vague symptoms consisting of decreased appetite and tenesmus. Although interspecies differences exist, histologically, the reptilian oviduct can be divided into five regions: the infundibulum (the most anterior part of the oviduct), the uterine tube, the isthmus, the uterus and the vagina (Girling, 2002; Stahl and DeNardo 2019). The exact regions that were affected by the leiomyoma in the tortoise could not be identified based on gross anatomical features or histological findings. Taking into account the gross anatomical location however, the infundibulum and uterine tube were considered as the most likely regions that were affected by the neoplasm

and were involved in the prolapse. The mass effect of the intramural oviductal leiomyoma and the potential increased effects of steroid hormones on affected oviductal tissue may have resulted in increased oviductal peristalsis with the development of an invagination of the infundibulum and uterine tube (Nowak, 1999; Berry et al., 2006; Barton et al., 2020). Subsequently, the alterations to the oviduct and invagination may have elicited tenesmus and eventually the development of a prolapse of the posterior part of the oviduct. Further studies are warranted to evaluate if leiomyomas in reptiles also show an increase in steroid hormone receptors expression, and if this coincides with alterations of physiological secretions, ciliary activity and muscle contractions that may predispose to the development of oviductal invagination and prolapse.

Imaging, endoscopy and histopathological examination of collected tissue samples were essential to establish a definitive diagnosis of the primary neoplastic disorder of the oviduct in the present case. The use of advanced medical imaging modalities, such as computer tomography or magnetic resonance imaging, combined with cytological or histological evaluation of endoscopically collected tissue samples may have allowed a preoperative diagnosis of the oviductal tumor (Christman et al., 2017). Endoscopy has been proven to be an important tool in the diagnosis and treatment of chelonian oviductal disease (Mans and Sladky, 2012; Divers, 2019) and has been validated for elective and therapeutic ovariectomy in chelonians (Innis et al., 2007). In the present case however, the narrow prefemoral window did not allow exteriorization of the oviductal invagination, and endoscopy-assisted reduction of the invagination failed. Eventually, transplastron osteotomy was necessary to adequately approach and resect the invaginated oviduct.

Hemiovariosalpingectomy has been described to preserve reproductive potential in a loggerhead sea

turtle (*Caretta caretta*) with a severely traumatized oviductal prolapse (Nutter et al., 2000). Since preservation of the reproductive potential was not of importance and no abnormalities were observed in the contralateral oviduct in the present case, bilateral ovariectomy and unilateral salpingectomy were performed.

Leiomyomas in humans, cats, dogs and laying hens usually present as small white nodules to large, grey, well-vascularized masses and typically have a glistening surface on the cut (Miller et al., 2003; Nelis et al., 2013; Carrasco and González, 2017; Devereaux and Schoolmeester, 2019), similar to what has been observed in the present case. The histological findings for the leiomyoma in the present case largely complied to the main histological characteristics that are observed in uterine leiomyomas in humans and conventional pets as well as those that are seen in leiomyomas of the oviduct of birds. The main characteristics consist of a fascicular pattern of bundles of well-differentiated smooth muscle cells separated by well-vascularized connective tissue. Leiomyoma smooth muscle cells are elongated and show abundant eosinophilic cytoplasm, distinctive cell membranes and less than five mitotic figure per high power field. In general, leiomyomas show immunoreactivity against α -SMA, muscle specific actin, desmin, h-caldesmon and vimentin (Miller et al., 2003; Nelis et al., 2013; Devereaux and Schoolmeester, 2019; Parra-Herran, 2019).

CONCLUSION

Although oviductal leiomyoma seems to be a rare condition in tortoises and this neoplastic disorder may remain unnoticed during a prolonged period of time, the present case illustrates the need to apply a multidirectional approach towards the diagnosis and treatment of oviductal leiomyomas in Hermann's tortoises.

REFERENCES

- Andreani G, Carpenè E, Cannavacciuolo A, Di Girolamo N, Ferlizza E, Isani G. (2014). Reference values for hematology and plasma biochemistry variables, and protein electrophoresis of healthy Hermann's tortoises (*Testudo hermanni* ssp.). *Veterinary Clinical Pathology* 43, 573-83.
- Barton B, Herrera G, Anamthathmakula P, Rock J, Willie A, Harris E, Takemaru K, Winuthayanon W. (2020). Roles of steroid hormones in oviductal function. *Reproduction* 159, R125-R137.
- Berry W, Doernte A, Conner M, Barnes M, Oates S. (2006). Spontaneously occurring fibroid tumours of the laying hen oviduct. *Poultry Science* 85, 1969-1974.
- Carrasco DC, González MS. (2017). Reproductive disorders in commonly kept fowl. *Veterinary Clinics of North America: Exotic Animal Practice* 20, 509-538.
- Christman J, Devae M, Wilson-Robles H, Hoppes S, Rech R, Russel KE, Heatley JJ. (2017). Oncology of reptiles: diseases, diagnosis, and treatment. *Veterinary Clinics of North America: Exotic Animal Practice* 20, 87-110.
- Devereaux KA, Schoolmeester JK. (2019). Smooth muscle tumors of the female genital tract. *Surgical Pathology Clinics* 12, 397-455.
- Di Girolamo N, Mans C. (2016). Reptile soft tissue surgery. *Veterinary Clinics of North America: Exotic Animal Practice* 19, 97-131.
- Divers SJ. (2019). Diagnostic endoscopy. In: Divers SJ and Stahl SJ (editors). *Mader's Reptile and Amphibian Medicine and Surgery*. Third edition, Elsevier, Saint Louis, p. 604-614.
- Frye FL, Dybal NO, Harshbarger JC. (1988). Testicular interstitial tumor in a desert tortoise (*Gopherus agassizii*). *Journal of Zoo Animal Medicine* 19, 55.
- Frye FL. (1994). Diagnosis and surgical treatment of reptilian neoplasms with a compilation of cases 1966-1993. *In Vivo* 8, 885-892.
- Garner MM, Hernandez-Divers SM, Raymond JT. (2004). Reptile neoplasia: a retrospective study of case submissions to a specialty diagnostic service. *Veterinary Clinics of North America: Exotic Animal Practice* 7, 653-671.
- Girling JE. (2002). The reptilian oviduct: a review of structure and function and directions for future research. *Journal of Experimental Zoology* 293, 141-170.
- Hedley J, Eatwell K. (2014). Cloacal prolapses in reptiles: a retrospective study of 56 cases. *Journal of Small Animal Practice* 55, 265-268.
- Hernandez-Divers SM, Garner MM. (2003). Neoplasia of reptiles with an emphasis on lizards. *Veterinary Clinics of North America: Exotic Animal Practice* 6, 251-273.
- Innis CJ, Hernandez-Divers S, Martinez-Jimenez D. (2007). Coelioscopic-assisted prefemoral oophorectomy in chelonians. *Journal of the American Veterinary Medical Association* 230, 1049-1052.
- Kubiak M, Denk D, Stidworthy MF. (2020). Retrospective review of neoplasms of captive lizards in the United Kingdom. *Veterinary Record* 186, vetrec-2018-105308
- Leineweber C, Stöhr AC, Öfner S, Mathes K, Marschang, RE. (2019). Changes in plasma chemistry parameters in Hermann's tortoises (*Testudo hermanni*) influenced by season and sex. *Journal of Herpetological Medicine and Surgery* 29, 113-122.
- Machotka SV, Wisser J, Ippen R, Nawab E. (1992). Report of dysgerminoma in the ovaries of a snapping turtle (*Chelydra serpentina*) with discussion of ovarian neoplasms reported in reptilians and women. *In Vivo* 6, 349-354.
- Mans C, Sladky KK. (2012). Diagnosis and management of oviductal disease in three red-eared slider turtles (*Trachemys scripta elegans*). *Journal of Small Animal Practice* 53, 234-239.
- Martorell J, Soto S, Barrera S, Ramis A. (2009). Case report: ovarian teratoma in a Mediterranean tortoise. *Compendium on Continuing Education for the Practising Veterinarian* 31, 193-196.
- Mauldin GN, Done LB. (2006). Oncology. In: Mader DR (editor). *Reptile Medicine and Surgery*. Second edition, Elsevier, Saint-Louis, p. 299-322.
- Mayer J, Moore AS. (2019). Oncology. In: Divers SJ and Stahl SJ (editors). *Mader's Reptile and Amphibian Medicine and Surgery*. Third edition, Elsevier, Saint Louis, p. 827-834.
- McArthur S, Machin RA (2019). Gastroenterology-cloaca. In: Divers SJ and Stahl SJ (editors). *Mader's Reptile and Amphibian Medicine and Surgery*. Third edition, Elsevier, Saint Louis, p. 775-785.
- Miller MA, Ramos-Vara JA, Dickerson MF, Johnson GC,

- Pace LW, Kreeger JM, Turnquist SE, Turk JR. (2003). Uterine neoplasia in 13 cats. *Journal of Veterinary Diagnostic Investigation* 15, 575-522.
- Music MK, Strunk A. (2016). Reptile critical care and common emergencies. *Veterinary Clinics of North America: Exotic Animal Practice* 19, 591-612.
- Nelis HM, Leemans B, de Vries C, Hoogewijs M, Chiers K, Govaere J. (2013). Oviductal and uterine leiomyomata in mares. *Vlaams Diergeneeskundig Tijdschrift* 82, 81-86.
- Newman SJ, Brown CJ, Patnaik AK. (2003). Malignant ovarian teratoma in a red-eared slider (*Trachemys scripta elegans*). *Journal of Veterinary Diagnostic Investigation* 15, 77-81.
- Nowak R. (1999). Fibroids: Pathophysiology and current medical treatment. *Clinical Obstetrics and Gynecology* 13, 223-238.
- Nutter FB, Lee DD, Stamper MA, Lewbart GA, Stoskopf MK. (2000). Hemiovariosalpingectomy in a loggerhead sea turtle (*Caretta caretta*). *Veterinary Record* 146, 78-80.
- Page-Katjian A, Hahne M, Leach K, Murphy H, Lock B, Rivera S. (2017). Neoplasia in snakes at Zoo Atlanta during 1992-2012. *Journal of Zoo and Wildlife Medicine* 48, 512-524.
- Parker WH. (2007). Etiology, symptomatology, and diagnosis of uterine myomas. *Fertility and Sterility* 87, 725-736.
- Parra-Herran C. (2019). Mesenchymal and miscellaneous lesions of the uterus. In: Nucci M, Parra-Herran C (editors). *Gynecologic Pathology*. Second edition, Elsevier, Saint-Louis, p. 407-496.
- Pees M, Ludewig E, Plenz B, Schmidt V. (2015). Imaging diagnosis – seminoma causing liver compression in a spur-thighed tortoise (*Testudo graeca*). *Veterinary Radiology and Ultrasound* 56, E21-24.
- Pereira ME, Viner TC. (2008). Oviduct adenocarcinoma in some species of captive snakes. *Veterinary Pathology* 45, 693-697.
- Porter KB, Tsibris JCM, Nicosia SV, Murphy JM, O'Brien WF, Rao PS, Spellacy WN. (1995). Estrogen-induced guinea-pig model for uterine leiomyomas - do the ovaries protect. *Biology of Reproduction* 52, 824-832.
- Proença LM, Divers SJ. (2015). Coelioscopic and endoscope-assisted sterilization of chelonians. *Veterinary Clinics of North America: Exotic Animal Practice* 18, 555-570.
- Ramsay EC, Munson L, Lowenstine L, Fowler ME. (1996). A retrospective study of neoplasia in a collection of captive snakes. *Journal of Zoo and Wildlife Medicine* 27, 28-34.
- Saba CF, Lawrence JA. (2013). Tumors of the female reproductive system. In: Withrow SJ, Vail DM, Withrow RL (editors). *Withrow and MacEwen's Small Animal Clinical Oncology*. Fifth edition, Elsevier: Saint-Louis, p. 532-537.
- Sabry M, Al-Hendy A. (2012). Medical treatment of uterine leiomyoma. *Reproductive Science* 19, 339-353.
- Sozen I, Arici A. (2002). Interactions of cytokines, growth factors, and the extracellular matrix in the cellular biology of uterine leiomyomata. *Fertility and Sterility* 78, 1-12.
- Stahl SJ, DeNardo DF. (2019). Theriogenology. In: Divers SJ, Stahl SJ (editors). *Mader's Reptile and Amphibian Medicine and Surgery*. Third edition, Elsevier, Saint Louis, p. 849-893.
- Sykes JM, Trupkiewicz JG. (2006). Reptile neoplasia at the Philadelphia Zoological Garden, 1901-2002. *Journal of Zoo and Wildlife Medicine* 37, 11-19.
- Walker CL, Stewart EA. (2005). Uterine fibroids: the elephant in the room. *Science* 308, 1589-1592.



© 2021 by the authors. Licensee Vlaams Diergeneeskundig Tijdschrift, Ghent University, Belgium. This article is an open access article distributed under the terms and conditions of the Creative Commons Attribution (CC BY) license (<http://creativecommons.org/licenses/by/4.0/>).