



**UNIVERSIDADE ESTADUAL DE CAMPINAS
SISTEMA DE BIBLIOTECAS DA UNICAMP
REPOSITÓRIO DA PRODUÇÃO CIENTÍFICA E INTELLECTUAL DA UNICAMP**

Versão do arquivo anexado / Version of attached file:

Versão do Editor / Published Version

Mais informações no site da editora / Further information on publisher's website:

https://www.scielo.br/scielo.php?script=sci_arttext&pid=S0004-282X2016000400011

DOI: 10.1590/0004-282X20160043

Direitos autorais / Publisher's copyright statement:

©2016 by Associação Arquivos de Neuro-Psiquiatria. All rights reserved.

DIRETORIA DE TRATAMENTO DA INFORMAÇÃO

Cidade Universitária Zeferino Vaz Barão Geraldo

CEP 13083-970 – Campinas SP

Fone: (19) 3521-6493

<http://www.repositorio.unicamp.br>

The Hitchhiker's guide to the rhinencephalon

Um guia prático sobre a anatomia do rinencéfalo

Laura Silveira-Moriyama^{1,2,3,4}, Philip Glass^{3,5}, Suraj Rajan⁶, Rafael Carvalho¹, Fabiano Reis³, Carlos A. A. Penatti¹, Valeria Muio¹

ABSTRACT

Pathology of the rhinencephalon has been a subject of interest in the fields of neurodegenerative diseases, trauma, epilepsy and other neurological conditions. Most of what is known about the human rhinencephalon comes from comparative anatomy studies in other mammals and histological studies in primates. Functional imaging studies can provide new and important insight into the function of the rhinencephalon in humans but have limited spatial resolution, limiting its contribution to the study of the anatomy of the human rhinencephalon. In this study we aim to provide a brief and objective review of the anatomy of this important and often overlooked area of the nervous system.

Keywords: olfactory cortex; anatomy; neuroanatomy.

RESUMO

As patologias do rinencéfalo tem sido assunto de interesse para os estudiosos das doenças neurodegenerativas, do traumatismo cranio-encefálico, epilepsia e outras doenças neurológicas. A maior parte do conhecimento sobre a anatomia do rinencéfalo vem de estudos de anatomia comparativa com outros mamíferos e estudos histológicos em primatas. Estudos de imagem funcional, apesar de proporcionarem informações úteis e interessantes a respeito do funcionamento do rinencéfalo em humanos, sofrem de resolução espacial limitada, e portanto contribuem de maneira restrita ao estudo dos limites das áreas anatômicas. Neste artigo buscamos proporcionar ao neurologista e neurocientista interessado uma revisão prática e objetiva da anatomia desta área importante e muitas vezes esquecida do sistema nervoso.

Palavras-chave: córtex olfatório; anatomia; neuroanatomia.

The interest of the medical community in the rhinencephalon has grown exponentially in the past decades. Much of this popularity stems from the finding of severe hyposmia both in Parkinson's disease¹ and Alzheimer's disease², two of the most prevalent neurodegenerative conditions, as well as in schizophrenia³ and many other neurological and psychiatric conditions. Although now largely acknowledged in the specialized medical literature, such deficits are only infrequently detected in clinical practice, mainly due to a combination of lack of awareness and technical difficulties accessing commercially available smell tests. Despite the steadfast increase in the number of publication regarding the sense of olfaction, this field is still incipient when compared to the study of other senses or the motor system (Figure 1). In addition, the anatomy and the physiology of the olfactory system are still largely mysterious to the average clinician, and

detailed anatomical information regarding the rhinencephalon is largely found in specialized books, usually inaccessible to readers from the developing countries. In this review we aimed to provide the practicing clinicians and the interested researchers with a brief, objective and practical overview of the anatomy of the rhinencephalon, using an open-access platform to facilitate access to this information, in the hope that it will help fuel research in this area and improve the clinical care of patients suffering from olfactory disorders.

THE FLOW OF THE OLFACTORY INFORMATION

Key authorities^{4,5,6} split the olfactory areas into peripheral and central divisions, analogous to the connections described for other sensory systems. This follows the proposed

¹Universidade Nove de Julho, Programa de Pós-graduação em Medicina, Sao Paulo SP, Brazil;

²UCL Institute of Neurology, Reta Lila Weston Institute, London, UK;

³Universidade Estadual de Campinas, Faculdade de Ciências Médicas, Campinas SP, Brazil;

⁴Universidade de São Paulo, Faculdade de Medicina, Departamento de Neurologia, Sao Paulo SP, Brazil;

⁵Universidade Estadual do Sudoeste da Bahia, Faculdade de Medicina, Vitoria da Conquista BA, Brazil;

⁶Premier Health Miami Valley Hospital, The Clinical Neuroscience Institute, Dayton OH, USA.

Correspondence: Laura Silveira-Moriyama; Postgraduate Research Program in Medicine, Universidade Nove de Julho (Uninove); Rua Vergueiro, 235/249; 01504-001 São Paulo; SP, Brasil; E-mail: laurasm@uninove.br

Conflict of interest: There is no conflict of interest to declare.

Received 02 January 2016; Accepted 07 January 2016.



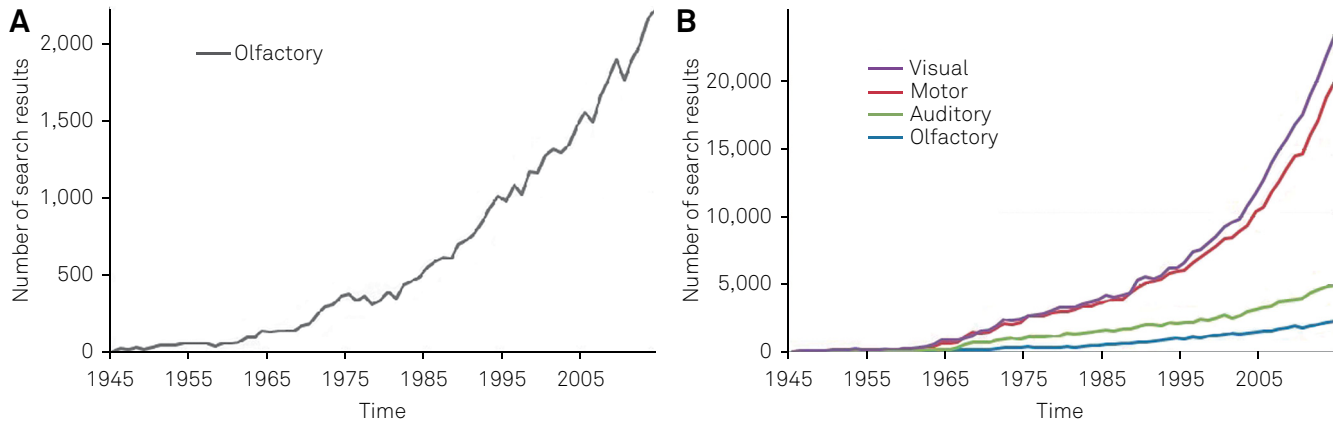


Figure 1. Search results on PubMed (www.ncbi.nlm.nih.gov/pubmed) using search terms (“visual”, “motor”, “auditory” and “olfactory”). (A) shows the number of search results for the term “olfactory” alone, using the number of citations up to two thousand, and demonstrating the exponential increase of search results using the term “olfactory”. (B) shows the comparative number of citations for the terms “olfactory”, “motor”, “auditory” and “visual”, clearly demonstrating that despite the increase, the number of search results is still very small when compared to the terms “visual” and “motor”, and almost half of the volume for term “auditory”.

flow of the olfactory information (Figure 2). The most peripheral element in the olfactory system, the olfactory receptor, was not described in detail until the 1990s. In 1991 Buck and Axel⁷ published a seminal paper which described a multigene family encoding olfactory receptors (ORs), which comprised 1–5% of the human genome. This discovery granted them the Nobel Prize in Physiology or Medicine in 2004⁸ and further contributed to the popularity of olfactory science. Following Buck and Axel’s description, it became clear that each neuron in the olfactory mucosa could express one single type of olfactory receptor (OR), although the same receptor can be found in various neurons widely distributed in the olfactory mucosa. A single odorant

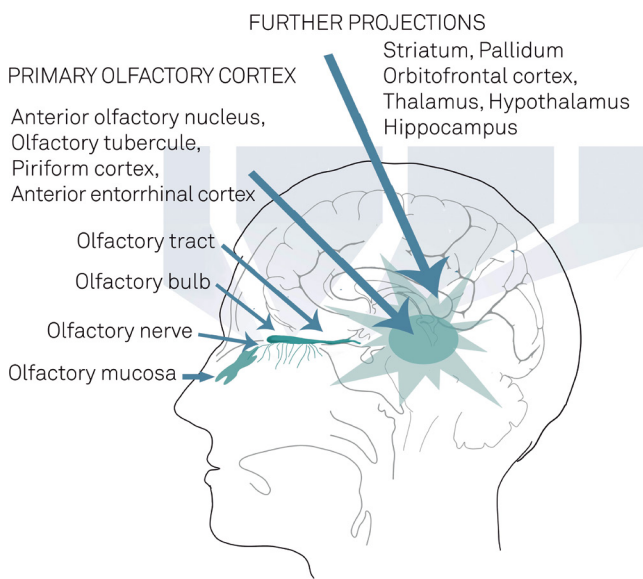


Figure 2. Schematic view of the levels of processing in the rhinencephalon. From bottom to top, the levels are showed in sequential order from more peripheral to more central.

molecule has different parts, which are recognized by a set of different ORs and activate a set of cells in the mucosa⁹. These cells are not simply receptors, but real olfactory neurons and their axons form the olfactory nerve bundles, which cross the skull base in the cribriform plate and synapse in the olfactory bulb. Within the olfactory bulb, there are spheres of neuropil formations called glomeruli, which are formed by axons of the various sensory neurons expressing the same kind of OR. In the glomerulus, these axons synapse onto the dendrites of the projection (mitral and tufted cells) and modulatory cells (most of which secrete GABA and/or dopamine). Figure 3 illustrates these structures.

From the olfactory bulb the information flows to the primary olfactory cortex, which includes the anterior olfactory nucleus, piriform cortex, olfactory tubercle, a small part of the amygdala and the anterior part of the entorhinal cortex. The role of the primary olfactory cortex in humans is not fully understood, but subjects with lesions of this area fail to

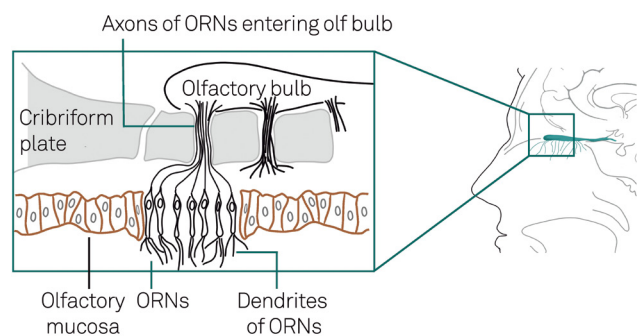


Figure 3. Simplified structure of the olfactory mucosa. Olfactory receptor neurons (ORN) have their cilia in the olfactory mucus and contact with odorant substances, which yield action potentials. This information is transmitted through their axons across the cribriform plate and synapse into the olfactory bulb.

identify odours appropriately, even if they can detect that a smell is present^{10,11,12,13,14,15}, suggesting this area is important for encoding odour identity, a notion supported by functional imaging studies^{16,17,18,19,20}.

The primary olfactory cortex sends projections to various brain regions, including diencephalic structures (thalamus and hypothalamus), limbic cortex (mainly larger parts of the amygdala and also the hippocampus) and neocortex (particularly the olfactory part of the orbitofrontal cortex). The clinician can easily observe this network as the often impressive hedonic and occasionally autonomic responses to smells, and by the close link between olfaction and memory which are often referred to particular smells. Olfactory stimuli are able to generate changes in emotions, behaviour and autonomic functions that are largely unconscious and often powerful.

UNIQUE CHARACTERISTICS OF THE OLFACTORY SYSTEM

In comparison to other sensory systems, olfaction has unique characteristics, which need to be appreciated for the basic understanding of the olfactory pathways. Unlike other senses, the receptors for olfaction are not mere receptor cells that connect to a bipolar neuron. They are true neurons present in the human surface epithelium. This results on them being more vulnerable to insult than neurons in the central nervous system. To compensate, the olfactory neurons can be generated in life through mitotic divisions of the basal cells present in the olfactory epithelium. Their natural turnover is of approximately 30 days²¹. The presence of pluripotent cells in the olfactory epithelium and elsewhere in the olfactory system has been the source of great interest²².

Contrasting with other senses, the first interneuronal synapse does not happen in the spinal cord or brain stem, but in the mitral layer of the olfactory bulb. Unlike other sensory modalities, olfactory projections travel directly to the cerebral hemispheres, without thalamic relay, and while in other senses the diencephalic relay stations project to a single delineated cortical region, the olfactory information is widely projected to a network of distinct regions of the limbic cortex that altogether make up the primary olfactory cortex (POC). The topographic organization for the analysis of olfactory stimuli is still obscure. There seem to be “loose olfactory maps” linking certain neuronal populations in the olfactory bulb and primary olfactory cortex with broad but grouped olfactory stimuli²³ but these “maps” are not as well-defined and anatomically organized as those for visual, auditory and somatic information.

The flow and integration of the olfactory information is rather complex and poorly understood. There is a projection from the POC to the thalamus, but this is not essential for relay of sensory information into the neocortex,

since the POC also projects directly to the orbitofrontal cortex and other cortical regions²⁴. The number of reciprocal and collateral projections of the olfactory system is unusually high. The olfactory bulb (OB) and areas within the POC have numerous internal connections and in addition they further project to the striatum, thalamus, hypothalamus and orbito-frontal cortex^{4,6,24,25}, which project back to the POC. Furthermore, the POC and higher areas send information back to the OB as well²⁶. Among these many neuron pathways and back projections, POC-derived synaptic output to hypothalamus and medial-orbito-frontal cortices have been known to enhance odor-driven social stimuli in appetitive and aversive behaviors²⁷.

THE AREAS OF THE RINENCEPHALON

Olfactory mucosa

The olfactory mucosa is located in the medial and lateral walls of the nasal cavity. It is thicker than the respiratory mucosa and occupies an area of approximately 1 cm² on each side of the nose²⁸. The thickness, extent and integrity of the olfactory mucosa decreases significantly with age, and neuroepithelial degeneration seems to be an inevitable feature of human aging with significant reduction in olfaction^{29,30,31}. Exposure to viral and bacterial infections, head injury, neurodegenerative disorders and chemical exposures also can damage the nasal mucosa³².

The main components of the olfactory mucosa are olfactory receptor neurons (ORN), columnar cells, basal cells microvillar cells and tubo-alveolar cells. ORN are neurons with bipolar appearance that have dendrites immersed in the olfactory mucus where they come into contact with odorant molecules. The thin axons of the few millions²⁸ of ORN form the bundles of the olfactory nerve which travel through the cribriform plate and synapse in the olfactory bulb. Columnar cells provide support for the receptor neurons³³. The function of microvillar cells is still largely unknown but they may be involved in the cell death and regeneration of ORN³⁴. Tubo-alveolar cells of Bowman's glands secrete a serous fluid which may regulate olfactory transduction³³. Last but not least, basal cells are stem cells situated deep in the olfactory epithelium. They undergo mitotic division and differentiate to replace lost receptor neurons, supporting cells³⁵ and olfactory ensheathing cells. These olfactory replacing mechanisms are crucial for the regeneration of the olfactory nerve after trauma³⁶.

Olfactory bulb

The olfactory bulb (OB) has been studied in humans in more detail since the reports of pathological deposits of alpha-synuclein in Parkinson's disease and tau protein in Alzheimer's disease. In carnivores and rodents the OB is a prominent and voluminous structure, unlike in humans.

Therefore caution must be taken when extrapolating this data to humans. In rodents, six well-defined layers are described in the OB. In humans they are not as clearly defined, although the main cells types of each can be identified³⁷.

The olfactory nerve layer is the most superficial layer of the OB. It is composed of unmyelinated axons of olfactory receptor neurons (ORN) and express olfactory marker protein (OMP); therefore it can be easily immunolabelled and identified³⁸. The glomerular layer has a distinctive appearance and is clearly visible in humans. It consists of axons of ORN that give rise to spherical neuropil formations (the glomeruli) that vary in vertebrates from 30 to 200 microns in diameter³⁹ (Figure 4A). In the glomeruli the axons of the ORN synapse onto the arborized dendrites of mitral cells, and also with the modulatory periglomerular cells. Most of the periglomerular cells secrete GABA and/or dopamine. Figure 4B shows dopaminergic periglomerular cells stained by immunohistochemistry for tyrosine hydroxylase.

The external plexiform layer is formed by dendrites of the principal neurons and granule cells and it has few cell bodies in rodents. In humans, it continues with the mitral layer and thus shows histologically with greater cell somata. The mitral cell layer is composed of large pyramidal glutaminergic cells which are the main projection outlets from the olfactory bulb⁴⁰. In humans this layer is thin and poorly demarcated. The total number of mitral cells decreases significantly with age^{41,42}. The internal plexiform layer is another layer

with few cells bodies: it mainly combines the dendritic process of granule cells and the axons of the mitral and tufted cells. Similar to the external plexiform layer, in humans it also merges with the mitral cell layer³⁷.

The granule cell layer has the most numerous cell structures in the rodent olfactory bulb, with a few million neurons. In humans, mitral and granule cells are more numerous and they make up half of the volume of the OB⁴¹. The granule cells have no distinguished axons and its long GABAergic dendrites project internally to the bulb, mainly in the plexiform layer.

Within the olfactory bulbs, quite visible islands of large pyramidal cells can be seen. These are parts of the anterior olfactory nucleus and are therefore functionally related to the primary olfactory cortex. These large neurons contrast with the smaller neurons from the granule cells layer and can be easily identified (Figures 4C and 4D).

Primary olfactory cortex

The primary olfactory cortex (POC) is defined as the area that receives direct projections from the olfactory bulb. It is made up of five main regions, which can be further subdivided. Each region is described below and, because these regions can be found under different acronyms in the literature, their various nomenclatures are listed in Table, except for the anterior cortical nucleus of the amygdala and the periamygdaloid cortex, which are discussed in the text. These areas

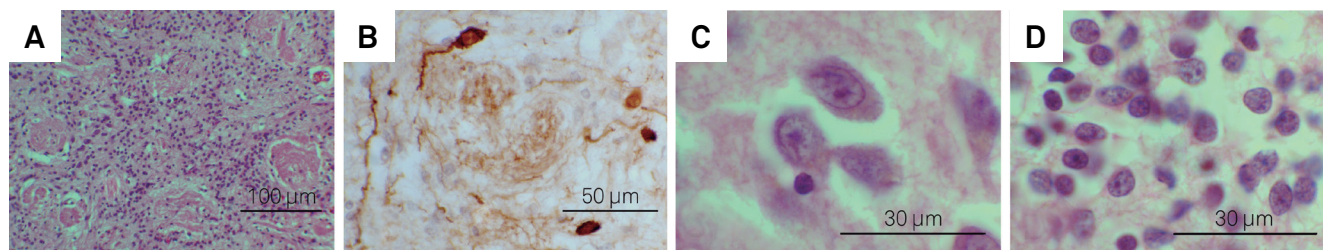


Figure 4. Illustrative photomicrographs showing: histology of glomerular layer (A) and periglomerular dopaminergic cells (B), and appearance of large neurons in islands of the anterior olfactory nucleus inside the olfactory bulb (C), compared to the smaller cells in the granule cell layer (D). Scale bar: 100 μm in A, 50 μm in B, and 30 μm in C and D. (A), (C) and (D) used haematoxylin and eosin stain, and (B) used immunohistochemistry for tyrosine hydroxylase counter stained by haematoxylin.

Table. Different acronyms for the subdivisions of primary olfactory cortex found in the literature. The table displays the most commonly used name on the first column, and other common acronyms in the second column, followed by the number of citations found using the acronym as a search term on the Google Scholar (www.google scholar.com) database.

Most commonly used acronym	Other acronyms found in the literature	Cites
Piriform cortex (25000 cites)	Pyriform cortex	6,09
	Prepyriform cortex	2,31
	Piriform area	544,00
	Pyriform area	391,00
	Prepiriform area	134,00
	Lateral olfactory gyrus	97,00
	Prepyriform area	95,00
Anterior olfactory nucleus (6,990 cites)	Retrobulbar region	613,00
	Anterior olfactory cortex	142,00
Olfactory tubercle (19,500 cites)	Anterior perforated substance	1,43

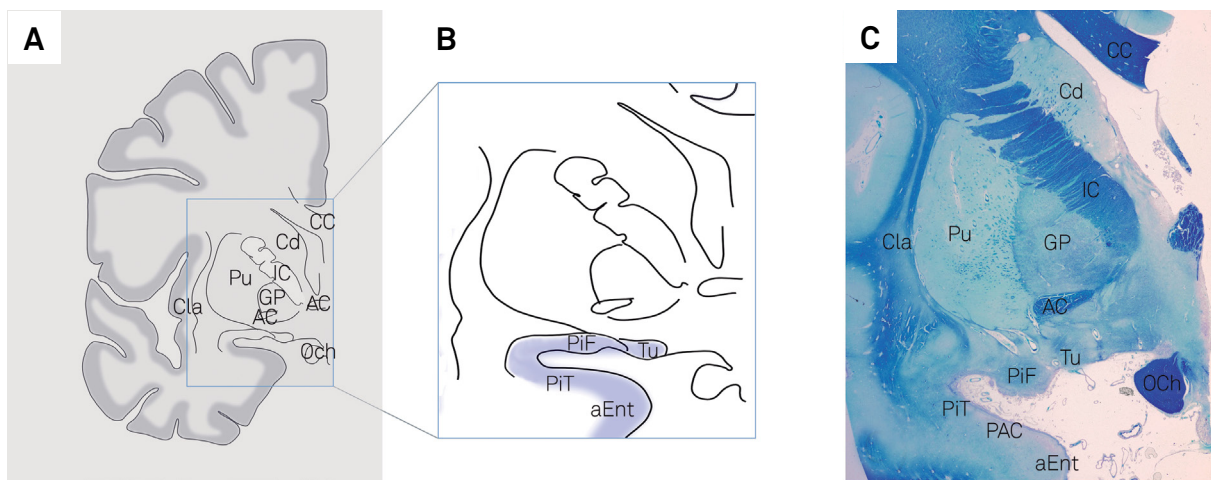
are not well delimited anatomically or histologically, therefore their recognition in histological preparations or in brain imaging largely depends on the appropriate knowledge of their relationship with main anatomical landmarks in the region, and the comparison with seminal literature on the subject. Figure 5 shows a coronal section of a half-brain with the location of one of the structures and various landmarks in the region. Figure 6 presents illustrative MRI coronal images with the main landmarks and the location of some areas of the POC.

Anterior olfactory nucleus

Despite being a prominent and extensive olfactory structure this area has been poorly studied in humans

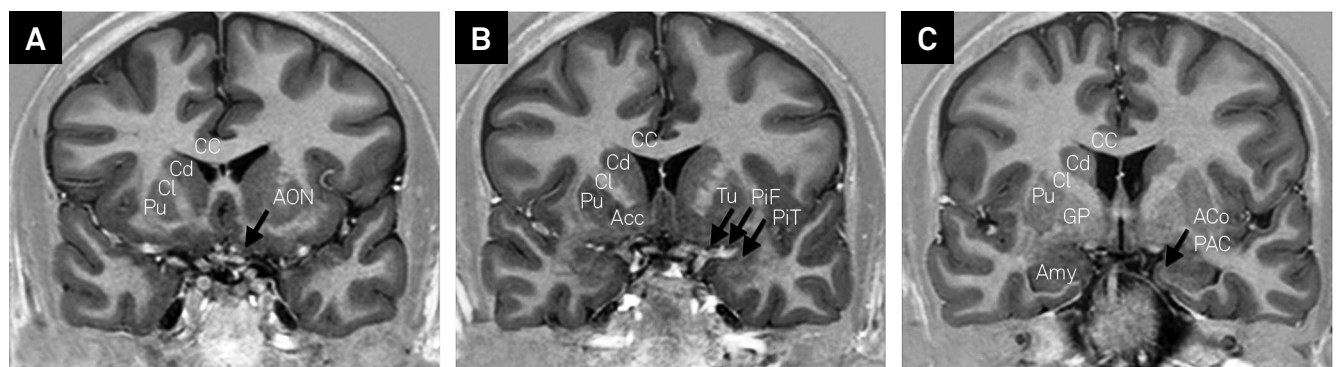
and “existing research is dispersed and obscured by many different nomenclatures and approaches”⁴³. Its solid anatomical location in rodents is quite different from that in primates, where it is dispersed as discontinuous islands of large neurons (Figure 4D) within the OB and OT and a more delineated portion in the forebrain, all showing great inter-individual variability⁴¹.

There is also controversy as to whether it is better termed a nucleus or cortex^{44,45}. Haberly argues that the physiological organization of the olfactory pathway, if considered in parallel with the other sensory pathways, would place the olfactory bulb as the primary olfactory cortex (as it is the first and most simple structure for the coding of smell patterns) and the anterior olfactory cortex and other areas of the POC would then



AC: Anterior commissure; aEnt: anterior entorhinal cortex; CC: corpus callosum; Cd: Caudate head; Cla: claustrum; GP: Globus pallidus; IC: internal capsule; OCh: optic chiasm; PAC: periamygdaloid cortex; PiF; PiT: frontal and temporal parts of piriform cortex; Pu: Putamen; Tu: Olf tubercle.

Figure 5. Illustrative images showing location of some areas of the primary olfactory cortex. Insert (A) shows a schematic drawing with the main landmarks which are easily visible both in histology slides and neuroimaging, while insert (B) shows the corresponding location of the olfactory tubercle, piriform cortex and anterior portion of the entorhinal cortex (blue highlight). Insert (C) shows a coronal section of a half brain stained for luxol fast blue and counterstained with cresyl violet, showing a slightly more posterior location in which the periamygdaloid cortex can be visualized as well.



AC: Anterior commissure; Acc : accumbens nucleus; ACo : anterior cortical nucleus of the amygdala; CC: corpus callosum; Cd: Caudate head; GP: Globus pallidus; IC: internal capsule; PAC: periamygdaloid cortex; PiF; PiT: frontal and temporal parts of piriform cortex; Pu: Putamen; Tu: olfactory tubercle.

Figure 6. Coronal images extracted from T1-weighted magnetic resonance imaging showing location of some areas of the primary olfactory cortex. Inserts show the coronal slices with main landmarks labelled in white on the left half, and the rhinencephalon areas labelled in black and marked with arrows on the right. For a reference for coronal slices see the Paxinos & Mai atlas⁵, coronal slices numbered from the anterior commissure (AC). Insert (A) approximately 1cm anterior from AC, insert (B) slightly anterior to AC, and insert (C) slightly posterior from AC.

be the secondary olfactory cortex. On the other hand standard nomenclature dictates that cortical regions must be clearly divisible into a minimum of at least three tangential layers, and the anterior olfactory nucleus has only two.

Olfactory tubercle

The olfactory tubercle is just anterior to the olfactory trigone, and is bordered by the medial and lateral olfactory tracts. It is also referred to as the anterior perforated substance because of the perforating arteries that transpose it on their way to the subcortical regions. In contrast to rodents and carnivorous mammals where it is trilaminated and quite well developed, in humans it is made up of a loosely laminated allocortical region. In humans its function is not clear, and some evidence suggests it might be linked to the basal ganglia, as it is rich in acetylcholinesterase and its profile of iron, glutamic acid dehydrogenase, succinate dehydrogenase, enkephalin, substance P and epidermal growth factor content are typical of pallidal tissue⁴.

Piriform cortex

The term “piriform cortex” originates from the nomenclature “prepiriform” based on the fact that this distinct region of allocortex is rostral to the “pyriform lobe” present in most carnivores⁴. In rodents the piriform cortex is divided into anterior and posterior portions, which have no clear morphological boundaries. In humans, there is a curvature of the hemisphere with the development of the fetal temporal lobe. In comparison to rodent cerebral hemispheres, the piriform cortex displays a C-type curve. The more anterior portion of the piriform correspond to the human frontal piriform (PiF), and the more posterior portions corresponding to the temporal piriform (PiT)^{4,46} (Figure 5).

Anterior cortical nucleus of the amygdala and the periamygdaloid cortex

The anterior cortical nucleus of the amygdala (ACo) is a very small region of the amygdala, lateral to the PiT. Studies in macaques show that this region, as well as the adjoining periamygdaloid cortex, receive direct projections from the olfactory bulb^{47,48}. In humans the periamygdaloid cortex is almost indistinguishable from the anterior cortical nucleus of the amygdala and the whole area is sometimes referred to as the cortico-amygdaloid transition area, or amygdalo-piriform transition area amygdala⁴. Mai⁵ clearly delimits the ACo as well as a PCo, but other anatomists consider this controversial. In the lower mammals the posterior cortical nucleus of the amygdala receives projections from the accessory olfactory nucleus²⁴, which is a relay for pheromone perception from the vomeronasal organ. The vomeronasal organ is vestigial in humans and its connections and functions have not been well established, making the anatomy and function of the PCo a controversial subject in human anatomy. Other acronyms used for this region in humans of other species include

“cortical amygdaloid nucleus” and “semilunar gyrus”, although these names may not apply entirely to human anatomy.

Entorhinal cortex

The more anterior portions of the entorhinal cortex receive direct input from the olfactory bulb^{5,47,48} and entorhinal activation has been demonstrated in functional magnetic resonance image studies²⁵. The limits of the olfactory areas of the entorhinal cortex in humans are not well defined, but studies indicate it is likely to represent less than 15% of the entorhinal cortex⁴⁹. Figure 5B shows a coronal section of the brain including the anterior portion of the entorhinal cortex.

Olfactory projections beyond the POC

In 1943, Allen showed that potentials could be evoked in the orbital frontal cortex by electrical stimulation of the piriform cortex, and that after ablation of this connection the response was abolished⁵⁰. This led to the notion of the orbitofrontal cortex as the isocortical area related to olfaction. These projections from primary olfactory areas have now been extensively studied in rodents, carnivores and monkeys^{51,52,53,54} mostly by electrophysiological methods, delimiting the olfactory area in the latero-posterior orbital frontal cortex of the monkey (the posterior part of Area 12 of Walker⁵²). Injections of anterograde axonal tracers in the piriform cortex of monkeys were able to label axons in several regions of the agranular insula/posterior orbital cortex that project back to the primary olfactory cortex⁴⁸. Functional imaging studies have also demonstrated odorant-induced orbitofrontal cortex activation, mainly in the orbitofrontal gyri⁵⁵, but the precise location of the input is still a challenge due to limitation of spatial resolution of functional imaging⁵⁶.

In addition to the neocortex, the POC also projects to various areas in the limbic system. In rats there are projections from the POC to various areas of the amygdala, including central nucleus (intermediate, lateral and capsular), basal nucleus (parvocellular division of the basal nucleus) and nucleus of the lateral olfactory tract. The POC also projects to CA1, subiculum and dentate gyrus²⁴. The amygdala is particularly involved in the affective aspects of olfaction, being activated by olfactory stimuli with emotional valence⁵⁵. The hypothalamus also receives an extensive input from the POC in less developed mammals. In humans, its role in olfaction is obscure, but recent research using functional neuroimaging suggests a possible involvement in affective processing of olfactory information⁵⁷ and sexual behavior⁵⁸. The POC projects to the ventral striatum⁵⁹ and medial-dorsal thalamic nucleus^{60,61,62}. The thalamus then projects on to the orbitofrontal cortex⁵³.

FINAL REMARKS

Knowledge of the structures involved in human olfactory processing is still relatively limited, and much of what

is described comes from comparative anatomical studies in rodents, where olfaction plays a much more important role in survival and the sheer size of the rhinencephalon is much larger than in humans. Therefore, caution is needed when translating findings from rodents and other mammals to

microsmatic animals like man, which have a less developed sense of smell. Functional imaging studies, as well as clinical olfactory studies in subjects with delimited lesions of the rhinencephalon are likely to help delineate the olfactory areas in humans.

References

- Doty RL. Olfactory dysfunction in Parkinson disease. *Nat Rev Neurol*. 2012;8(6):329-39. doi:10.1038/nrneurol.2012.80
- Velayudhan L, Gasper A, Pritchard M, Baillon S, Messer C, Proitsi P. Pattern of Smell Identification Impairment in Alzheimer's Disease. *J Alzheimers Dis*. 2015;46(2):381-7. doi:10.3233/JAD-142838
- Rupp CI. Olfactory function and schizophrenia: an update. *Curr Opin Psychiatry*. 2010;23(2):97-102. doi:10.1097/YCO.0b013e328336643f
- Gloor P. The temporal lobe and the limbic system. New York: Oxford University Press; 1997. The olfactory system.
- Paxinos G, Mai J. Atlas of the human brain. 2nd ed. New York: Elsevier Academic Press; 2004.
- Price JL. Olfaction. In: Paxinos, G. editor. The human nervous system. San Diego: Elsevier Academic Press; 2004. p. 1197-211.
- Buck L, Axel R. A novel multigene family may encode odorant receptors: a molecular basis for odor recognition. *Cell*. 1991;65(1):175-87. doi:10.1016/0092-8674(91)90418-X
- Buck LB. Unraveling the sense of smell (Nobel lecture). *Angew Chem Int Ed Engl*. 2005;44(38):6128-40. doi:10.1002/anie.200501120
- Malnic B, Hirono J, Sato T, Buck LB. Combinatorial receptor codes for odors. *Cell*. 1999;96(5):713-23. doi:10.1016/S0092-8674(00)80581-4
- Eskenazi B, Cain WS, Novelly RA, Friend KB. Olfactory functioning in temporal lobectomy patients. *Neuropsychologia*. 1983;21(4):365-74. doi:10.1016/0028-3932(83)90023-4
- Eichenbaum H, Morton TH, Potter H, Corkin S. Selective olfactory deficits in case H.M. *Brain*. 1983;106(2):459-72. doi:10.1093/brain/106.2.459
- Eskenazi B, Cain WS, Novelly RA, Mattson R. Odor perception in temporal lobe epilepsy patients with and without temporal lobectomy. *Neuropsychologia*. 1986;24(4):553-62. doi:10.1016/0028-3932(86)90099-0
- Jones-Gotman M, Zatorre RJ. Olfactory identification deficits in patients with focal cerebral excision. *Neuropsychologia*. 1988;26(3):387-400. doi:10.1016/0028-3932(88)90093-0
- Zatorre RJ, Jones-Gotman M. Human olfactory discrimination after unilateral frontal or temporal lobectomy. *Brain*. 1991;114(1A):71-84.
- Gonçalves Pereira PM, Insausti R, Artacho-Péruela E, Salmenperä T, Kälviäinen R, Pitkänen A. MR volumetric analysis of the piriform cortex and cortical amygdala in drug-refractory temporal lobe epilepsy. *AJNR Am J Neuroradiol*. 2005;26(2):319-32.
- Gottfried JA, Deichmann R, Winston JS, Dolan RJ. Functional heterogeneity in human olfactory cortex: an event-related functional magnetic resonance imaging study. *J Neurosci*. 2002;22(24):10819-28.
- Zelano C, Bensafi M, Porter J, Mainland J, Johnson B, Bremner E et al. Attentional modulation in human primary olfactory cortex. *Nat Neurosci*. 2005;8(1):114-20. doi:10.1038/nn1368
- Gottfried JA. A truffle in the mouth is worth two in the bush: odor localization in the human brain. *Neuron*. 2005;47(4):473-6. doi:10.1016/j.neuron.2005.08.002
- Gottfried JA, Winston JS, Dolan RJ. Dissociable codes of odor quality and odorant structure in human piriform cortex. *Neuron*. 2006;49(3):467-79. doi:10.1016/j.neuron.2006.01.007
- Li W, Luxenberg E, Parrish T, Gottfried JA. Learning to smell the roses: experience-dependent neural plasticity in human piriform and orbitofrontal cortices. *Neuron*. 2006;52(6):1097-108. doi:10.1016/j.neuron.2006.10.026
- Mackay-Sim A. Neurogenesis in the adult olfactory neuroepithelium. In: Doty RL. Handbook of olfaction and gustation. Philadelphia: Marcel Dekker; 2003. p. 93-113.
- Brann JH, Firestein SJ. A lifetime of neurogenesis in the olfactory system. *Front Neurosci*. 2014;8:182. doi:10.3389/fnins.2014.00182
- Uchida N, Takahashi YK, Tanifuji M, Mori K. Odor maps in the mammalian olfactory bulb: domain organization and odorant structural features. *Nat Neurosci*. 2000;3(10):1035-43. doi:10.1038/79857
- Price JL, Russchen FT, Amaral DG. The amygdaloid complex. In: Björklund A, Hökfelt T, Swanson LW. Handbook of chemical neuroanatomy. Amsterdam: Elsevier Science; 1987. p. 279-388.
- Sobel N, Johnson BN, Mainland JD, Yousem DM. Functional neuroimaging of human olfaction. In: Doty RL. Handbook of olfaction and gustation. Philadelphia: Marcel Dekker; 2003.
- Cleland L. Central olfactory structures. In: Doty RL. Handbook of olfaction and gustation. Philadelphia: Marcel Dekker; 2003. p. 165-80.
- Choe HK, Reed MD, Benavidez N, Montgomery D, Soares N, Yim YS et al. Oxytocin Mediates Entrainment of Sensory Stimuli to Social Cues of Opposing Valence. *Neuron*. 2015;87(1):152-63. doi:10.1016/j.neuron.2015.06.022
- Moran DT, Rowley JC 3rd, Jafek BW, Lovell MA. The fine structure of the olfactory mucosa in man. *J Neurocytol*. 1982;11(5):721-46. doi:10.1007/BF01153516
- Nakashima T, Kimmelman CP, Snow JB. Structure of human fetal and adult olfactory neuroepithelium. *Arch Otolaryngol*. 1984;110(10):641-6. doi:10.1001/archotol.1984.00800360013003
- Suzuki Y, Takeda M, Obara N, Suzuki N, Takeichi N. Olfactory epithelium consisting of supporting cells and horizontal basal cells in the posterior nasal cavity of mice. *Cell Tissue Res*. 2000;299(3):313-25. doi:10.1007/s004410050030
- Doty RL, Kamath V. The influences of age on olfaction: a review. *Front Psychol*. 2014;5:20. doi:10.3389/fpsyg.2014.00020
- Menco M. Morphology of the mammalian olfactory epithelium: form, fine structure, function and pathology. In: Doty RL. Handbook of olfaction and gustation. Philadelphia: Marcel Dekker; 2003. p. 17-49.
- Jafek BW. Ultrastructure of human nasal mucosa. *Laryngoscope*. 1983;93(12):1576-99. doi:10.1288/00005537-198312000-00011
- Montani G, Tonelli S, Elsaesser R, Paysan J, Tirindelli R. Neuropeptide Y in the olfactory microvillar cells. *Eur J Neurosci*. 2006;24(1):20-4. doi:10.1111/j.1460-9568.2006.04878.x
- Huard JM, Youngentob SL, Goldstein BJ, Luskin MB, Schwob JE. Adult olfactory epithelium contains multipotent progenitors that give rise to neurons and non-neural cells. *J Comp Neurol*. 1998;400(4):469-86. doi:10.1002/(SICI)1096-9861(19981102)400:4<469::AID-CNE3>3.0.CO;2-8
- Beites CL, Kawachi S, Crocker CE, Calof AL. Identification and molecular regulation of neural stem cells in the olfactory epithelium. *Exp Cell Res*. 2005;306(2):309-16. doi:10.1016/j.yexcr.2005.03.027
- Smith RL, Baker H, Kolstad K, Spencer DD, Greer CA. Localization of tyrosine hydroxylase and olfactory marker protein immunoreactivities in the human and macaque olfactory bulb. *Brain Res*. 1991;548(1-2):140-8. doi:10.1016/0006-8993(91)91115-H

38. Smith RL, Baker H, Greer CA. Immunohistochemical analyses of the human olfactory bulb. *J Comp Neurol*. 1993;333(4):519-30. doi:10.1002/cne.903330405
39. Kratskin B. Anatomy and neurochemistry of the olfactory bulb. In: Doty RL. *Handbook of olfaction and gustation*. Philadelphia: Marcel Dekker; 2003. p. 139-64.
40. Chen WR, Xiong W, Shepherd GM. Analysis of relations between NMDA receptors and GABA release at olfactory bulb reciprocal synapses. *Neuron*. 2000;25(3):625-33. doi:10.1016/S0896-6273(00)81065-X
41. Bhatnagar KP, Kennedy RC, Baron G, Greenberg RA. Number of mitral cells and the bulb volume in the aging human olfactory bulb: a quantitative morphological study. *Anat Rec*. 1987;218(1):73-87. doi:10.1002/ar.1092180112
42. Meisami E, Mikhail L, Baim D, Bhatnagar KP. Human olfactory bulb: aging of glomeruli and mitral cells and a search for the accessory olfactory bulb. *Ann N Y Acad Sci*. 1998;855:708-15. doi:10.1111/j.1749-6632.1998.tb10649.x
43. Brunjes PC, Illig KR, Meyer EA. A field guide to the anterior olfactory nucleus (cortex). *Brain Res Brain Res Rev*. 2005;50(2):305-35. doi:10.1016/j.brainresrev.2005.08.005
44. Ekstrand JJ, Domroese ME, Johnson DM, Feig SL, Knodel SM, Behan M et al. A new subdivision of anterior piriform cortex and associated deep nucleus with novel features of interest for olfaction and epilepsy. *J Comp Neurol*. 2001;434(3):289-307. doi:10.1002/cne.1178
45. Haberly LB. Parallel-distributed processing in olfactory cortex: new insights from morphological and physiological analysis of neuronal circuitry. *Chem Senses*. 2001;26(5):551-76. doi:10.1093/chemse/26.5.551
46. Leon M, Johnson B. Functional units in the olfactory system. *Proc Natl Acad Sci USA*. 2006;103(41):14985-6. doi:10.1073/pnas.0607416103
47. Turner BH, Gupta KC, Mishkin M. The locus and cytoarchitecture of the projection areas of the olfactory bulb in *Macaca mulatta*. *J Comp Neurol*. 1978;177(3):381-96. doi:10.1002/cne.901770303
48. Carmichael ST, Clugnet MC, Price JL. Central olfactory connections in the macaque monkey. *J Comp Neurol*. 1994;346(3):403-34. doi:10.1002/cne.903460306
49. Insausti R, Marcos P, Arroyo-Jiménez MM, Blaizot X, Martínez-Marcos A. Comparative aspects of the olfactory portion of the entorhinal cortex and its projection to the hippocampus in rodents, nonhuman primates, and the human brain. *Brain Res Bull*. 2002;57(3-4):557-60. doi:10.1016/S0361-9230(01)00684-0
50. Allen WF. Distribution of cortical potentials resulting from insufflation of vapors into the nostrils and from stimulation of the olfactory bulbs and the pyriform lobe. *Am J Physiol - Leg Content*. 1943;139(4):553-5.
51. Tanabe T, Iino M, Takagi SF. Discrimination of odors in olfactory bulb, pyriform-amygdaloid areas, and orbitofrontal cortex of the monkey. *J Neurophysiol*. 1975;38(5):1284-96.
52. Tanabe T, Yarita H, Iino M, Ooshima Y, Takagi SF. An olfactory projection area in orbitofrontal cortex of the monkey. *J Neurophysiol*. 1975;38(5):1269-83.
53. Yarita H, Iino M, Tanabe T, Kogure S, Takagi SF. A transthalamic olfactory pathway to orbitofrontal cortex in the monkey. *J Neurophysiol*. 1980;43(1):69-85.
54. Naito J, Kawamura K, Takagi SF. An HRP study of neural pathways to neocortical olfactory areas in monkeys. *Neurosci Res*. 1984;1(1):19-33. doi:10.1016/0168-0102(84)90027-0
55. Zald DH, Pardo JV. Emotion, olfaction, and the human amygdala: amygdala activation during aversive olfactory stimulation. *Proc Natl Acad Sci USA*. 1997;94(8):4119-24. doi:10.1073/pnas.94.8.4119
56. Gottfried JA, Zald DH. On the scent of human olfactory orbitofrontal cortex: meta-analysis and comparison to non-human primates. *Brain Res Brain Res Rev*. 2005;50(2):287-304. doi:10.1016/j.brainresrev.2005.08.004
57. Bensafi M, Rouby C, Farget V, Bertrand B, Vigouroux M, Holley A. Autonomic nervous system responses to odours: the role of pleasantness and arousal. *Chem Senses*. 2002;27(8):703-9. doi:10.1093/chemse/27.8.703
58. Savic I, Berglund H, Gulyas B, Roland P. Smelling of odorous sex hormone-like compounds causes sex-differentiated hypothalamic activations in humans. *Neuron*. 2001;31(4):661-8. doi:10.1016/S0896-6273(01)00390-7
59. Fuller TA, Russchen FT, Price JL. Sources of presumptive glutamergic/aspartergic afferents to the rat ventral striatopallidal region. *J Comp Neurol*. 1987;258(3):317-38. doi:10.1002/cne.902580302
60. Russchen FT, Amaral DG, Price JL. The afferent input to the magnocellular division of the mediodorsal thalamic nucleus in the monkey, *Macaca fascicularis*. *J Comp Neurol*. 1987;256(2):175-210. doi:10.1002/cne.902560202
61. Kuroda M, Price JL. Synaptic organization of projections from basal forebrain structures to the mediodorsal thalamic nucleus of the rat. *J Comp Neurol*. 1991;303(4):513-33. doi:10.1002/cne.903030402
62. Kuroda M, Murakami K, Kishi K, Price JL. Distribution of the pyriform cortical terminals to cells in the central segment of the mediodorsal thalamic nucleus of the rat. *Brain Res*. 1992;595(1):159-63. doi:10.1016/0006-8993(92)91468-T