



UNIVERSIDADE ESTADUAL DE CAMPINAS
SISTEMA DE BIBLIOTECAS DA UNICAMP
REPOSITÓRIO DA PRODUÇÃO CIENTÍFICA E INTELLECTUAL DA UNICAMP

Versão do arquivo anexado / Version of attached file:

Versão do Editor / Published Version

Mais informações no site da editora / Further information on publisher's website:

<https://www.sciencedirect.com/science/article/pii/S0379073815002054>

DOI: 10.1016/j.forsciint.2015.05.012

Direitos autorais / Publisher's copyright statement:

©2015 by Elsevier. All rights reserved.

DIRETORIA DE TRATAMENTO DA INFORMAÇÃO

Cidade Universitária Zeferino Vaz Barão Geraldo

CEP 13083-970 – Campinas SP

Fone: (19) 3521-6493

<http://www.repositorio.unicamp.br>



Case Report

Death in the “microwave oven”: A form of execution by carbonization

Carlos Durão^{a,b,*}, Marcos P. Machado^c, Eduardo Daruge Júnior^d^a National Institute of Legal Medicine and Forensic Sciences, Portugal^b Orthopedic Department, Hospital Vila Franca de Xira, Lisbon, Portugal^c Forensic Anthropology, Legal Medicine Institute Afrânio Peixoto, Rio de Janeiro, Brazil^d Department of Forensic Dentistry, Dental Faculty of Piracicaba, State University of Campinas, FOP-UNICAMP, Brazil

ARTICLE INFO

Article history:

Received 2 April 2015

Received in revised form 5 May 2015

Accepted 12 May 2015

Available online 21 May 2015

Keywords:

“Death in the microwave oven”

Carbonization

Homicide

Human identification

Thermal destruction of corpses

Forensic anthropology

ABSTRACT

Death in the “microwave oven” has nothing to do with microwaves energy. It is the jargon name given to a criminal form of execution by carbonization that has been adopted by drug dealers in Rio de Janeiro (Brazil). The goal is to torture and intimidate victims, in an attempt of corpse occultation and to make identification harder or impossible.

This paper brings to attention of the forensic international community an unusual and very cruel form of execution as a way to document these situations.

© 2015 Published by Elsevier Ireland Ltd.

1. Introduction

Death in the “microwave oven” has nothing to do with microwaves energy. It is the jargon name given to a criminal form of execution by carbonization that has been adopted by drug dealers in Rio de Janeiro (Brazil). The goal is to torture and intimidate victims in an attempt of corpse occultation and to make identification harder or impossible. The method consists in placing the victim, still alive, inside a pile of tires and setting it on fire. The resemblance to an oven inspired the popular term “death in the microwave oven” (Fig. 1). This paper intends to make public this very violent form of death.

2. Case report

The article presents four cases of homicides using carbonization. All cases occurred in the slums where victims were killed inside tires (“microwave oven”). In the first case, charring was not complete and it was possible to observe the presence of soot in the trachea and lung – Montalti sign (Fig. 2) [1,2]. The carmine hue in the lung and brain shows the victim was “cooked” by heat. The heat produces a post mortem artefact that should not be confused

with subarachnoid hemorrhage. In this case the toxicology was positive for carbon monoxide, the evidence that the victim was still alive when it was burned.

In the other cases (Figs. 3 and 4) it is possible to observe the metal alloy tire near the corpses. In the fourth case although with extensive charring it was possible to identify a gunshot fracture.

3. Discussion

In a forensic examination of a carbonized corpse identification is essential. Even in cases of total carbonization it is possible to establish the victim's sex by finding the uterus or prostate which in many cases may be found well preserved [2–6]. Additional methods of identification such as radiology, forensic odontology and forensic biology (DNA) are a major help. All the elements that might be capable of contributing towards this identification process are essential and among these are orthopaedic prostheses, which frequently remain intact [7,8]. However in many of these Brazilian cases of “Death in the microwave oven” the victim's identification becomes quite difficult or even impossible because relatives intimidated through fear of retaliation refuse to collaborate with the authorities.

Another important step in these “execution” cases is the investigation to determine if the victim was still alive or already dead during the carbonization [9,10]. In the former, Montalti' sign is of great value. Just as valuable is the knowledge that injuries with hiperemia may also be inflicted in *post mortem*. The

* Corresponding author at: Hospital Vila Franca Xira, Estrada Nacional n 1, Povos, 2600-009 Vila Franca de Xira, Lisboa, Portugal. Tel.: +351 263 006 500.

E-mail address: drcarlosdurao@hotmail.com (C. Durão).



Fig. 1. A. Steel belts inside the tire. B. A pile of tires. C. Very realistic scenes from the movie Elite Squad (“Tropa de Elite”) that reproduces how the victim is positioned inside a pile of tires. The victim is burned alive as a form of torture.

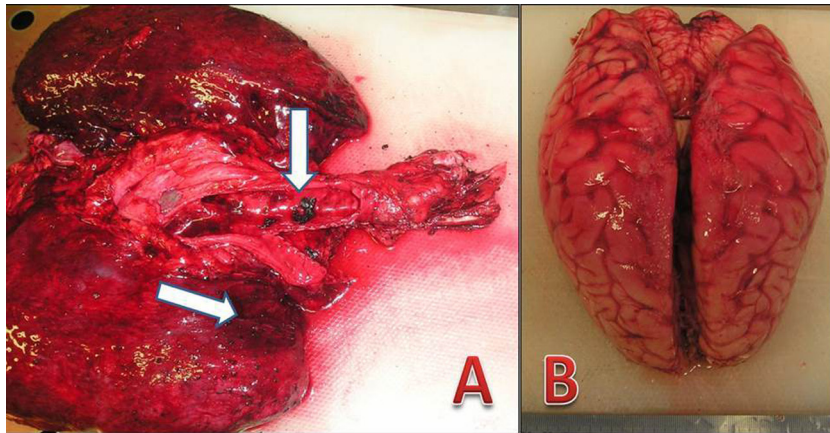


Fig. 2. Case 1. (A) Presence of soot in the trachea (Montalti sign – arrow). The victim was alive when it was burned. (B) Detail of the brain which was “cooked” by heat. The heat produces a post mortem artefact that should not be confused with a subarachnoid hemorrhage.



Fig. 3. Cadaver of a young man who was charred inside a pile of tires. Detail of metallic debris from the tires (arrows).



Fig. 4. Charred corpse, anthropological examination revealed that it was a young adult man. Arrow points the tire metal belts.




Fig. 5. Case 4. (A) Cadaveric remains found in a slum. Arrow points the tire metal belt. (B) Collected material for anthropological inventory. (C) Fragments cleaned and displayed for inventory. (D) Endocranial bevelling by gunshot fracture – entry wound from inner view.

toxicological analysis of carbon monoxide is mandatory; however cyanides may be associated to the death mechanism [3,4].

Trauma interpretation in skeletal remains involving burning can be difficult due to heat related fractures and fragmentation. However experimental studies and casework experience indicate that diagnostic evidence of trauma can survive the burning event but found that their appearance could be influenced by burning-related fragmentation [9–13].

In a skull gunshot fracture, endocranial bevelling is one of the most important indicators of an entry wound. Classic entrance wounds are round or ovoid-shaped openings with sharp edges and a clear punched-out appearance [14]. Internal bevelling can be very useful to identify an entrance wound known as Bonnet' sign [1]. In this case (Fig. 5), the skull was extremely fragmented due to traumatic and heat related fractures. Nevertheless it was possible to identify such a lesion which demonstrates the need for a thorough anthropological reconstruction.

4. Conclusions

This paper brings to attention of the forensic international community an unusual and very cruel form of execution and shows the importance of the correct study of the vital reaction phenomenon and anthropological study as a way to document these situations.

References

- [1] G.V. França, *Medicina Legal*, 8rd edition, Guanabara Koogan, Rio de Janeiro, 2011.
- [2] H. Hércules, *Medicina Legal texto e atlas*, 2rd edition, Atheneu, Rio de Janeiro, 2014.
- [3] P. Saukko, B. Knight, *Knight's Forensic Pathology*, 3rd edition, A Hodder Arnold Publication, London, 2004.
- [4] I. Gerling, C. Meissner, A. Reiter, M. Oehmichen, Death from thermal effects and burns, *Forensic Sci. Int.* 115 (2001) 33–41.
- [5] S.I. Fairgrieve, *Forensic Cremation: Recovery and Analysis*, CRC Press, Boca Raton, FL, 2008.
- [6] G. Grevin, P. Baillet, G. Quatrehomme, A. Ollier, Anatomical reconstruction of fragments of burned human bones: a necessary means for forensic identification, *Forensic Sci. Int.* 96 (1998) 129–134.
- [7] I.R. Matoso, et al., Positive identification of a burned body using an implanted orthopedic plate, *J. Forensic Sci.* 229 (1) (2013) 168.e1–168.e5.
- [8] C.H. Durão, et al., Importance of a national arthroplasty register for identification by medical examiner, *Rev. Bras. Ortop.* 47 (5 São Paulo) (2012).
- [9] D.H. Ubelaker, The forensic evaluation of burned skeletal remains: a synthesis, *Forensic Sci. Int.* 183 (1–3) (2009) 1–5.
- [10] V. Alunni, Forensic aspect of cremations on wooden pyre, *Forensic Sci. Int.* 241 (2014) 167–172.
- [11] E.J. Pope, O.C. Smith, Identification of traumatic injury in burned cranial bone: an experimental approach, *J. Forensic Sci.* 49 (3) (2004) 431–440.
- [12] S.A. Symes, C.W. Rainwater, E.N. Chapman, D.R. Gipson, A.L. Piper Patterned, Thermal destruction of human remains in a forensic setting, in: C.W. Schmidt, S.A. Symes (Eds.), *The Analysis of Burned Human Remains*, Elsevier, 2008, pp. 15–54.
- [13] G.L. Marella, E. Perfetti, G. Arcudi, Differential diagnosis between cranial fractures of traumatic origin and explosion fractures in burned cadavers, *J. Forensic Leg. Med.* 19 (3) (2012) 175–178.
- [14] G. Quatrehomme, M.Y. Iscan, Analysis of bevelling in gunshot entrance wounds, *Forensic Sci. Int.* 93 (1998) 45–60.