

Evaluation of Indonesian and two types of Japanese honey on the acceleration of cutaneous wound healing: an experimental study in mice.

著者	Haryanto, Mukai Kanae, Nakajima Yukari, Okuwa Mayumi , Cau Kim Jiu, Sugama Junko, Nakatani Toshio
著者別表示	Haryanto, 向井 加奈恵, 中島 由加里, 大桑 麻由美, Cau Kim Jiu, 須釜 淳子, 中谷 壽男
journal or publication title	Journal of Health Technology Assessment in Midwifery
volume	2
number	2
page range	80-88
year	2019-10-01
URL	http://doi.org/10.24517/00061586

doi: 10.31101/jhtam.912



Evaluation of Indonesian and two types of Japanese honey on the acceleration of cutaneous wound healing: an experimental study in mice

Haryanto^{a,1,*}, Kanae Mukai^{b,2}, Nakajima Yukari^{c,2}, Mayumi Okuwa^{c,3}, Cau Kim Jiu^{d,5}, Junko Sugama^{c,6}, Toshio Nakatani^{c,7}

^a The Institute of Nursing (STIK) Muhammadiyah, Indonesia.

^b Department of Clinical Nursing, Graduate School of Medical Sciences, Kanazawa University, Japan

^c Advanced Health Care Science Research Unit Innovative Integrated Bio-Research Core Institute for Frontier Science Initiative, Kanazawa University, Japan

^d Faculty Of Nursing Khon Kaen University, Thailand

¹ haryanto@stikmuhptk.ac.id*, ² kanae_m@staff.kanazawa-u.ac.jp, ³ ynakajima@staff.kanazawa-u.ac.jp,

⁴ ookuwa@mhs.mp.kanazawa-u.ac.jp, ⁵ ckj@stikmuhptk.ac.id, ⁶ junkosgm@mhs.mp.kanazawa-u.ac.jp, ⁷ nakatosi@staff.kanazawa-u.ac.jp

* corresponding author

ARTICLE INFO

Article history

Received 8th August 2019

Revised 27th September 2019

Accepted 11th October 2019

Keywords

Indonesian Honey

Japanese Honey

Wound Healing

Hydrocolloid dressing

ABSTRACT

The purpose of this study is to evaluate and clarify the effect of Indonesian honey, two types of Japanese honey and hydrocolloid dressing on wound healing process. Four groups of male mice were treated to produce two circular full-thickness skin wounds on the dorsum. They were then randomly allocated to receive daily Indonesian honey, Japanese honey (Buckwheat and Acacia honey) or hydrocolloid dressing as a control for treatment application. Macroscopic findings were observed from day 0 to 14 after wounding. Microscopic evaluation was assessed using qualitative analysis. The ratios of wound areas for honey groups on day 3 and 7 were smaller than those of the control group. Wound areas of honey groups gradually decreased to almost the same wound area as the control group on day 14, while the wound area of the control group peaked on day 5 and rapidly decreased until day 14. Microscopic finding that Indonesian honey was different with Japanese honey especially Buckwheat honey.

This is an open access article under the [CC-BY-SA](#) license.



1. Introduction

Cutaneous wound healing is a complex biological and an essential physiological process in which can be divided into four stages; homeostasis, inflammation proliferation (granulation, contraction and epithelialization) and remodeling (Mayers, L and Hudson, 2013; Shaw, T. J and Martin, 2009).

Some of the natural sources such as coconut oil (Tarawan, V.M., Mantilidewi, K. I., & Sutedja, 2016), aloe vera (Sari, Y., Purnawan, I., Kurniawan, D.W., & Sutrisna, 2018), red dragon fruit (Tahir, T., Bakri, S., Patellongi, I., Aman, M., Miskad, U.A., Maryunis., Yusuf, S., Rahayu, A. I., Syam, A.D., 2017) and including honey (Haryanto., Urai, T., Mukai, K., Suriadi, Sugama, J., Nakatani, 2012) have been used as complementary therapy in wound care in Indonesia. Recently, honey has known as biologic wound dressing because it contains (Molan, P & Rhodes, 2015). Some countries reported studies on honey such as Turkey (Nisbet, H.O., Nisbet, C., Yarim, M., Guler, A., & Ozak, 2010), Malaysia (Zohdi, R.M., Zaria, Z.A.B., Yusof, N., Mustapha, M & Abdullah, 2012), Iran (Ghaderi, R & Afshar, 2004), Pakistan (Iftihkar, F., Arshad, M., Rasheed, F., Amraiz, D., Anwar, P., & Gulfranz, 2010), and Nigeria (Fukuda, M., Kobayashi, K., & Hirono, 2011).

Generally, honey is composed of approximately 30-40% glucose, 40% fructose, 10% maltose, 20% water and amino acids, vitamins, enzymes, minerals and phytochemical such as flavonoids, and ferulic and caffeic acids (Bergman, A., Yanai, J., Weiss, J., Bell, D., & David, 1983; Ghaderi, R & Afshar, 2004). Several studies have reported that honey is effective for treatment of wounds, both clinically and laboratory. However, effectiveness of honey depends on species of bee, geographical location, and botanical origin, as well as processing and storage conditions (Moore, O. A., Smith, L. A., Campbell, F., Seers, K., McQuay, H.J., Moore, 2001). On the other hand, there have been no studies evaluating and comparing between honey from two or more countries.

Japanese already has known honey including Acacia, and Buckwheat honey. Yamada Bee Farm, Okayama, Japan reported Acacia honey is composed of 70.8% glucose and fructose and 18.6% water, and Buckwheat flour honey is composed of 71.2% glucose and fructose and 17.2% water (Nakajima, Y., Nakano, Y., Fuwono, 2013). On the other hand, Indonesia has many of kinds of honey. However in this study our concerning is jungle honey (*Apis dorsata*), which is composed of 73.4% glucose and fructose and 26% water. Although, they seem to have the same contains probably a lot of sugar and the same effects on wound healing. However, to our knowledge, there have been no studies evaluating of Indonesian honey and two of types of Japanese honey as topical therapy in wound care both macroscopically and microscopically.

Against this background, we hypothesize that Indonesian honey promote wound healing as well as Japanese honey. Therefore, the purpose of this study is to evaluate and clarify the effect of Indonesian honey and two type of Japanese honey on wound healing process. In addition, this study is a continuation of our previous study.

2. Materials and Methods

This study obtained an ethical approval before study conducted from Ethical Board of a university in Indonesia and the Reference number is 293/II.1.AU/KET.ETIK/X/2018.

2.1. Animal Preparation

In this study we used seventy-eight BALB/cCrSlc male mice aged 8 weeks and weighing 22.0-23.8 g. They were caged individually in an air-conditioned room at $25.0 \pm 2.0^{\circ}\text{C}$ with lighting from 08.45 to 20.45 hours. Water and laboratory feed were given ad libitum. The experimental protocols were in accordance with the Guidelines for Care and Use of Laboratory Animals of Kanazawa University, Japan.

2.2. Honey

Indonesian honey (*Apis dorsata*) and two of type Japanese honey, Acacia (*Robinia pseudoacacia*), and Buckwheat flour (*Fagopyrum esculentum*) honey were used in this study.

2.3. Wounded Procedure

In accordance our previous study (Haryanto., Urai, T., Mukai, K., Suriadi, Sugama, J., Nakatani, 2012), mice were anesthetized with i.p. injection of pentobarbital sodium (0.05 mg/g weight). Two circular (4 mm in diameter), full-thickness skin wounds including the panniculus on the both sides of the dorsum of the mouse were made with a sterile disposable biopsy punch (Kai Industries, Japan). Mice were divided into four groups. The day when wounds were made was designated as day 0. Wounds of the experiment groups, Indonesian honey, Acacia and, Buckwheat flour, were treated with either 0.1 mL honey respectively. Treatments were applied using a 1 mL syringe (Fig. 1). All wounds on an individual animal received the same treatment. The wounds were covered with a sterilized gauze 28 mm x 10 mm as secondary dressing to prevent honey run off and to absorb any exudate from the wound surface. The gauze was changed and all wounds were treated with honey. Mice were wrapped twice with sticky bandages (Meshpore Tape; Nichiban, Tokyo, Japan) to prevent gauze from slipping out of position. Meanwhile, wounds of the control group were covered with hydrocolloid dressing (Tegaderm; 3M Health Care, Tokyo, Japan). All control mice were wrapped twice with sticky bandages, which were changed every day, the same as the experimental groups.

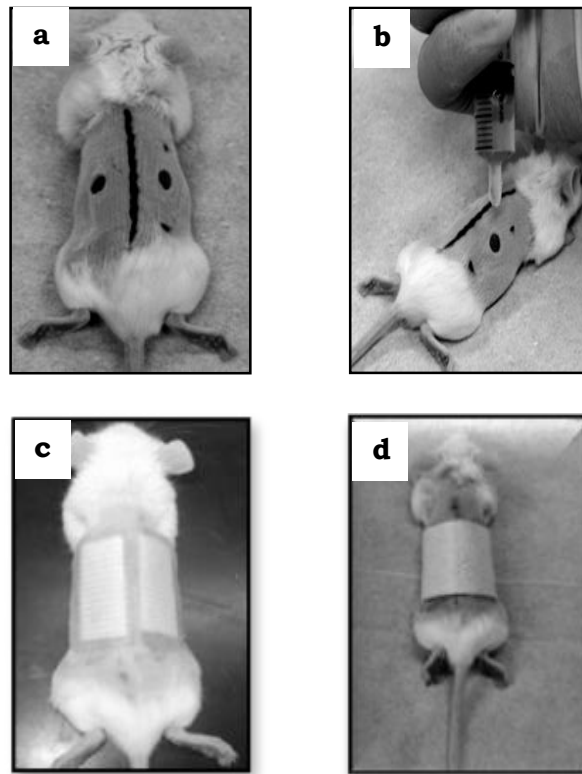


Fig. 1. Wound procedure. (a) Two circular full-thickness skin wounds (4 mm in diameter). (b) Each of the experimental wounds was treated with 0.1 mL of honey. (c) All wounds were covered with gauze. (d) Mice were wrapped with sticky bandages.

2.4. Macroscopic Evaluation

Wound healing progress was observed from day 0 to 14 after wounding. Each wound were observed edema, infection, and necrotic tissue. Wound areas were traced on polypropylene sheets (OHP) and photographs were taken every day. Wound areas were evaluated using Scion Image Beta 4.02 and Adobe Photoshop Elements 6.0.

2.5. Histological Procedure

The mice were euthanized by a massive pentobarbital sodium IP injection on days 3,7,11 and 14 after wounding. The wounds and the surrounding normal skin were excised about 15 mm x 15 mm square, staples onto overhead projector sheets to prevent over-contraction of the samples, and fixed in 4% paraformaldehyde in 0.2 mol/L Phosphate Buffer Saline (PBS) (pH 7.4) for 12 hours. The samples were dehydrated in an alcohol series, cleaned in xylene, and embedded in paraffin to prepare serial 5- μ m sections. The alternate sections were stained with hemotoxylin-eosin (HE).

2.6. Histological Evaluation

Epithelialization and granulation assessment were assessed and observed qualitatively to respect of fibroblast proliferation, collagen formation, angiogenesis and epithelialization under the light microscope (Pawar, R.S., Chaurasiya, P.K., Rajak, H., Singour, P.K., Toppo, F. A., & Jain, 2013).

2.7. Statistical analysis

Data are expressed as mean \pm SD, analyzed using SPSS $\text{\textcircled{R}}$ 8.0.1 (SAS, USA) (ANOVA, multiple comparison Tukey-Kramer). The differences were considered significant at $p < 0.05$.

3. Results

3.1. Macroscopic Observation (Fig. 2)

Macroscopic observation of wound healing. On the third day after wounding, the area surrounding the wound in Indonesian and Japanese honey groups had apparent redness. In addition, necrotic clearly appeared on the surface of wound areas in Indonesian and Japanese honey. This condition was the same as that of the hydrocolloid-dressing group, but the wound area in the hydrocolloid-dressing group was larger than those of the Indonesian and Japanese honey groups. On day 7, the area surrounding the wound in Indonesian and Japanese honey groups had no redness and necrotic on the surface of wound area both groups were decreased. The wound area and necrotic in the hydrocolloid dressing group was also decreased. Granulation and new epithelium were observed all groups. On day 11, the entire wound areas of all groups were covered by new epithelium. On day 14, wounds of all groups healed and were not infected.

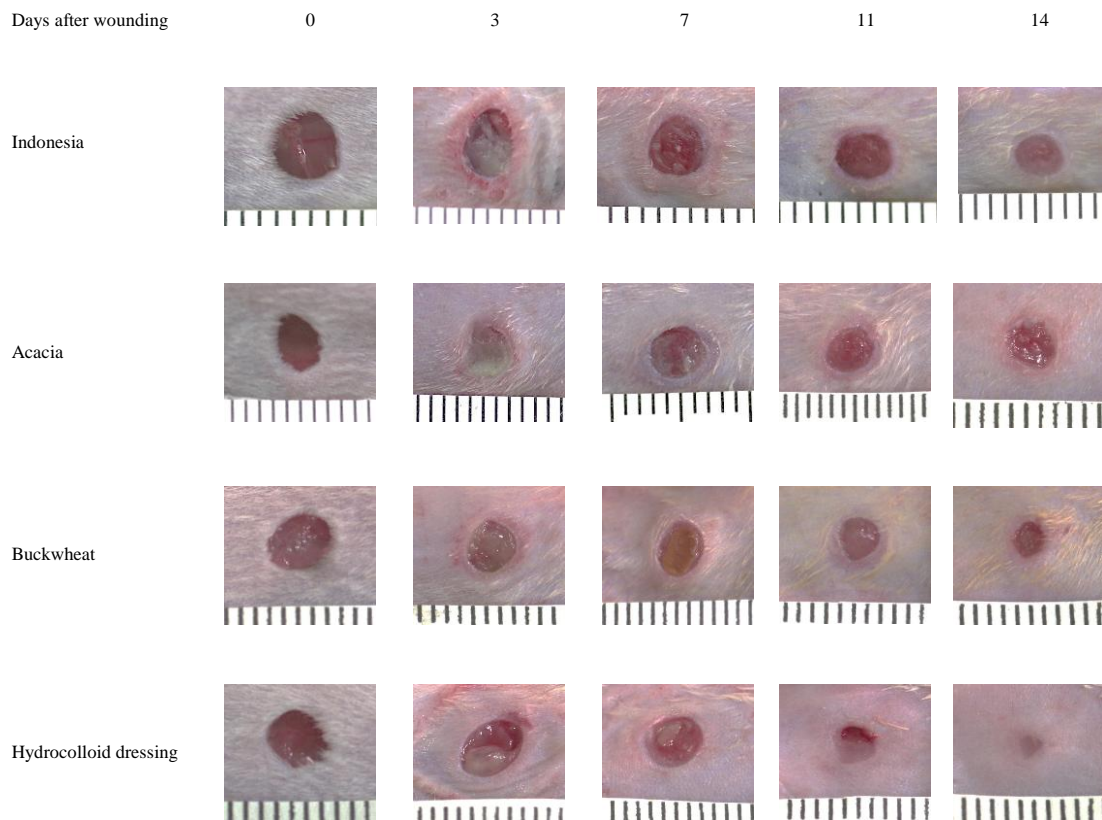


Fig. 2. Macroscopic observation of wound healing. Wounds were created on day 0. The wound areas of the hydrocolloid-dressing group were larger than Indonesian and Japanese honey until day 7 after wounding. The wound areas of the Buckwheat honey groups decreased gradually after on day 5 although on day 5 increased. The wound areas of the Acacia honey groups decreased gradually although on day 11 little increased. The wound areas of Indonesian honey groups decreased gradually. Wound surface on day 3, all groups were covered exudate. On day 7, wound in of the hydrocolloid

3.2. The ratio of wound area (Fig. 3)

The ratios of wound area on day 0 to day 14 to initial wound area on day 0 were calculated. In the Buckwheat flour honey group, the wound area increased on day 1 during the inflammatory phase, however, wound area decreased gradually until day 9 during the proliferative phase, 0.56 ± 0.08 times smaller than on day 0 ($P = 0.001$), decreased gradually until day 14 during remodeling phase, 0.29 ± 0.13 times smaller than on day 0 ($P = 0.000$).

In the Acacia honey group, the wound area decreased until day 4 during the early proliferative phase, 0.73 ± 0.15 times smaller than on day 0 ($P = 0.001$), decreased gradually until day 14 during the remodeling phase, 0.46 ± 0.10 times smaller than day 0 ($P = 0.000$).

In the Indonesia honey group, the wound area decreased until day 4 during the early proliferative phase, 0.62 ± 0.12 times smaller than on day 0 ($P = 0.000$), decreased gradually until day 14 during the remodeling phase, 0.58 ± 0.24 times smaller than day 0 ($P = 0.000$).

In the hydrocolloid-dressing group, the wound area increased gradually during the inflammatory and early proliferative phase, peaked on day 6, 1.66 ± 0.16 times larger than day 0, then, more rapidly decreased from day 8 during proliferative phase, and wounds healed on day 14, 0.30 ± 0.07 times smaller than day 0 ($P = 0.000$).

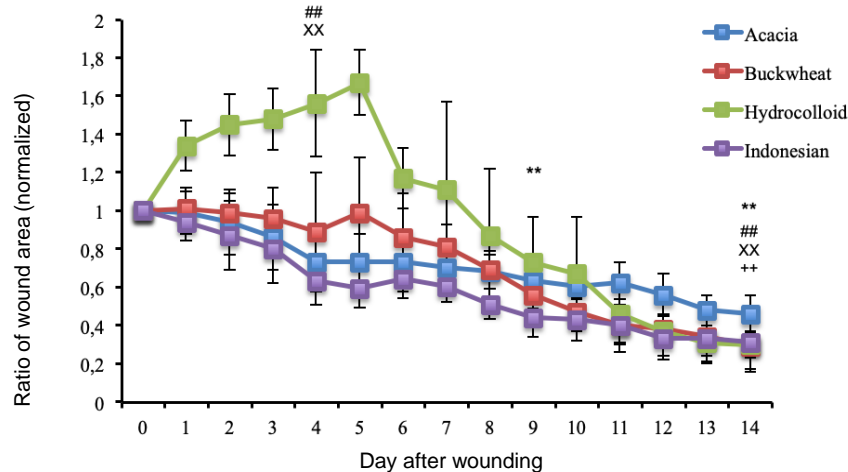


Fig. 3. Ratio of wound is to the initial area on day 0. In the Buckwheat flour honey group, the wound area increased on day 1 during the inflammatory phase, however, wound area decreased gradually until day 9 during the proliferative phase, 0.56 ± 0.08 times smaller than on day 0 ($P = 0.001$), decreased gradually until day 14 during remodeling phase, 0.29 ± 0.13 times smaller than on day 0 ($P = 0.000$). In the Acacia honey group, the wound area decreased until day 4 during the early proliferative phase, 0.73 ± 0.15 times smaller than on day 0 ($P = 0.001$), decreased gradually until day 14 during the remodeling phase, 0.46 ± 0.10 times smaller than day 0 ($P = 0.000$). In the Indonesian honey group, the wound area decreased until day 4 during the early proliferative phase, 0.62 ± 0.12 times smaller than on day 0 ($P = 0.000$), decreased gradually until day 14 during the remodeling phase, 0.58 ± 0.24 times smaller than day 0 ($P = 0.000$). In the hydrocolloid-dressing group, the wound area increased gradually during the inflammatory and early proliferative phase, peaked on day 6, 1.66 ± 0.16 times larger than day 0, then, more rapidly decreased from day 8 during proliferative phase, and wounds healed on day 14, 0.30 ± 0.07 times smaller than day 0 ($P = 0.000$). Data are expressed Mean \pm SD; ANOVA, Tukey-Kramer. * $P < 0.05$, ** , ## , XX , ++ $P < 0.01$,

3.3. Epithelialization and Granulation Tissue (Fig. 4)

Re-epithelialization of wound on 14 day was after wounding. The wound bed after complete healing Indonesian honey and hydrocolloid dressing showed well formed keratinized epithelium and normal collagen tissue. Japanese honey (Buckwheat) revealed keratinized epithelium and less amount of collagen tissue.

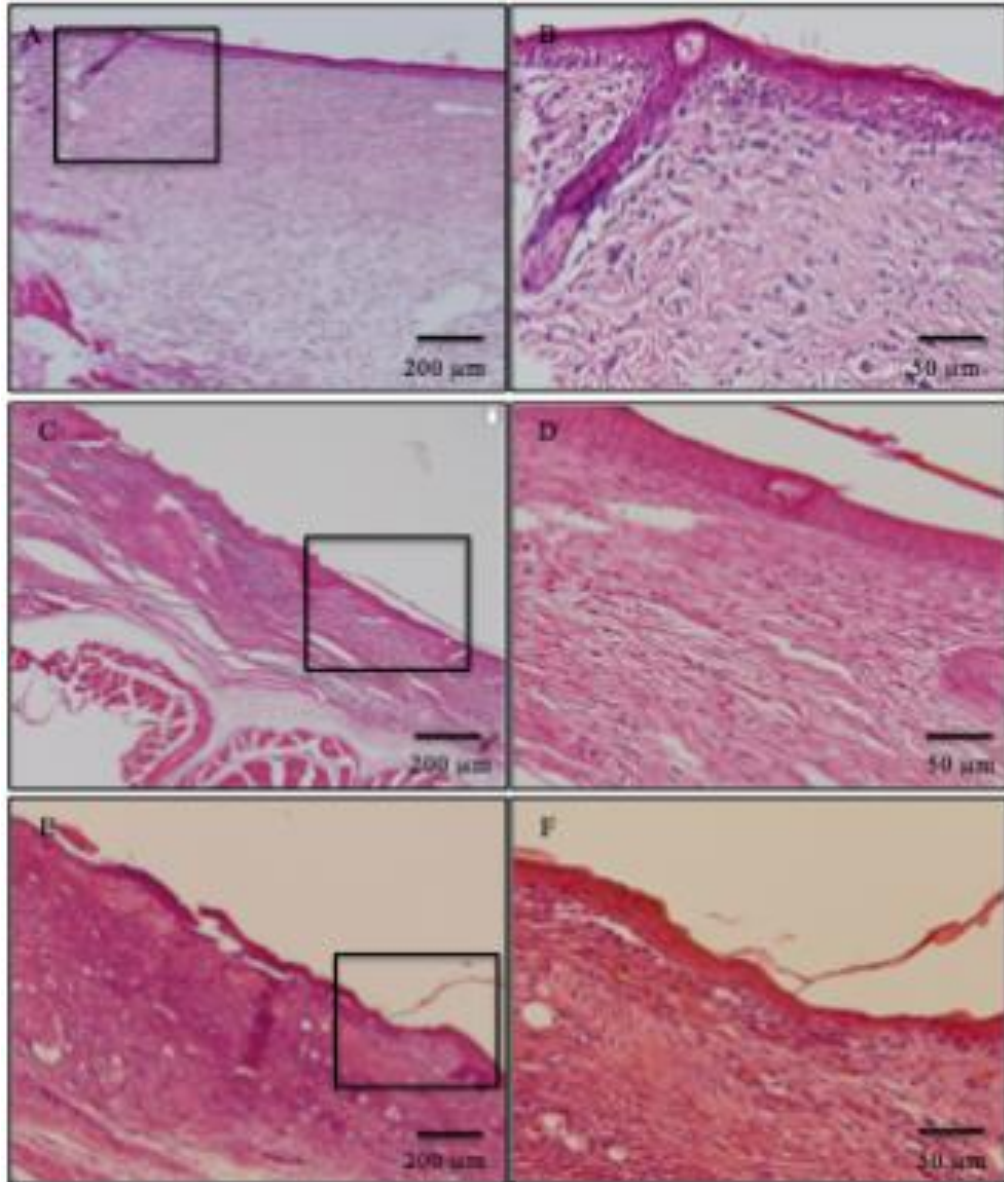


Fig. 4. Histological slides for Hydrocolloid dressing and Indonesian honey (figure A, B, C and D) and Japanese honey represent by Buckwheat honey (figure E and F), stained with hematoxylin and eosin, Acacia honey did not showed. Figure A, B, C and D represents wound tissue after complete healing on day 14. The section showed well-formed keratinized squamous epithelium and the area of dermis showed normal collagen tissue. Figure E and F revealed keratinized squamous epithelium and less amount of collagen tissue.

4. Discussion

In our previous study, we compared Indonesian honey and hydrocolloid dressing and Manuka honey as control positive (Haryanto., Urai, T., Mukai, K., Suriadi, Sugama, J., Nakatani, 2012). As we know that Indonesia is a country has many of kind honey. Many studies suggested honey from some countries could be used as an alternative for wound care. However, there is no study to evaluate between Indonesian and Japanese honey by histologically. To the best of the authors' knowledge this is the first study to compare Indonesian honey and Japanese honey and hydrocolloid dressing in mice.

We found by macroscopic observation the area surrounding the wound in Indonesia and Japanese honey groups had apparent redness and necrotic on the surface of wound area by day 3 (inflammatory phase). This condition was the same as that of the hydrocolloid-dressing group. The ratio of wound area of hydrocolloid-dressing group increased during the inflammatory phase then decreased until the wounds healed by day 14. However, wound areas Indonesian and Japanese honey did not increase during this phase, but rapidly decreased until the wounds healed by day 14. This result is similar in our previous study (Nakajima, Y., Nakano, Y., Fuwono, 2013). The effect of honey on decreasing wound area because of anti-inflammatory action (Ghaderi, R & Afshar, 2004). The wound area treated with Buckwheat honey increased on day 5 was larger than initial day. On the other hand, the wound areas treated with Acacia and Indonesian honey on day 5 were smaller than initial day. This phenomenon can be explained by our previous study that the retention of numerous neutrophils in proliferation and remodelling phases and small amount of deposition of collagen fibers in granulation tissue (Haryanto., Urai, T., Mukai, K., Suriadi, Sugama, J., Nakatani, 2012).

Microscopic analysis on day 14 found that Indonesian honey showed well-formed keratinized squamous epithelium and normal collagen tissue (Figure 4). This shows that there were different between Indonesian and Japanese honey especially Buckwheat honey. The nutrient contents of honey such as fructose, glucose and amino acids and high carbohydrate may help promote epithelialization (Tonks A, Cooper R.A, Price A.J, Molan P.C, 2001; Tonks A.J, Cooper R.A, Jones KP, Blair S, Parton J, 2003). This result shows that effectiveness of honey depends on species of bee, geographical location, and botanical origin, as well as processing and storage conditions (Moore, O. A., Smith, L. A., Campbell, F., Seers, K., McQuay, H.J., Moore, 2001). In addition, the honey properties among countries are different quantitatively and qualitatively (Gheldof N, Wang, X.H, 2002; Gheldof N, 2002). There is a need the future study to analysis contents of Indonesian and Japanese honey.

5. Limitations

The current study had a limitation namely, we didn't show Acacia honey on day 14 microscopically.

6. Conclusion

Indonesian and Japanese honey should be applied in the inflammatory phase. However, in this present study Indonesian honey is better than Japanese honey especially Buckwheat honey. Effectiveness of honey on wound healing depends on the sources honey. However, there is a need to clarify the difference of types of Indonesian honey on wound healing. Therefore, in future we will conduct a study on this issue.

Conflict of Interests

The authors declare that there is no conflict of interests in this research

Acknowledgment

This study was supported in part by grant from Grant-in-Aid for Scientific Research, Japan (no.22592363) and The Institute Nursing of Muhammadiyah, Pontianak, Indonesia.

References

- Bergman, A., Yanai, J., Weiss, J., Bell, D., & David, M. P. (1983). Acceleration of wound healing by topical application of honey: An animal model. *The American Journal of Surgery*, vol.145(issue.3), 374–376.
- Fukuda, M., Kobayashi, K., & Hirono, Y. et al. (2011). Jungle honey enhances immune function and antitumor activity. *Evidence Based Complementary and Alternative Medicine*, 2011, 8.
- Ghaderi, R & Afshar, M. (2004). Topical application of honey for treatment of skin wound in mice. *Iran Journal Medical Sciences*, 29(4), 185–188.
- Gheldof N, Wang, X.H, E. N. J. (2002). Identification and quantification of antioxidant components of honeys from various floral sources. *J Agric Food Chem*, 50, 5870–5877.
- Gheldof N, E. N. J. (2002). Antioxidant capacity of honeys from various floral sources based on the determination of oxygen radical absorbance capacity and inhibition of in vitro lipoprotein oxidation in human serum samples. *J Agric Food Chem*, 50, 3050–3055.
- Haryanto., Urai, T., Mukai, K., Suriadi, Sugama, J., Nakatani, T. (2012). Effectiveness of Indonesian Honey on the Acceleration of Cutaneous Wound Healing: An Experimental Study in Mice. *WOUNDS*, 24(4), 110–119.
- Iftihkar, F., Arshad, M., Rasheed, F., Amraiz, D., Anwar, P., & Gulfraz, M. (2010). Effects of Acacia honey on wound healing in various rat models. *Phytotherapy Research*, vol.24(4), 583–586.
- Mayers, L and Hudson, S. L. (2013). *Wound Care: Getting to the Depth of the Tissue*, Lakeway Texas: The National Center of Continuing Education. 1–16.
- Molan, P & Rhodes, T. (2015). Honey: A Biologic Wound Dressing. *WOUNDS*, 27(issue. 6), 141–151.
- Moore, O. A., Smith, L. A., Campbell, F., Seers, K., McQuay, H.J., Moore, R. A. (2001). Systematic review of the use of honey as a wound dressing. *BMC Complementary and Alternative Medicine*, vol.1(no.2).
- Nakajima, Y., Nakano, Y., Fuwono, S. et al. (2013). Effect of Three Type of Japanese Honey on Full-Thickness Wound in Mice. *Evidence-Based Complementary and Alternative Medicine*, vol.2013, 11.
- Nisbet, H.O., Nisbet, C., Yarim, M., Guler, A., & Ozak, A. (2010). Effect of three types of honey on cutaneous wound healing. *WOUNDS*, vol.22(no.11), pp.275-283.
- Pawar, R.S., Chaurasiya, P.K., Rajak, H., Singour, P.K., Toppo, F. A., & Jain, A. (2013). Wound healing activity of *Sida cordifolia* Linn in rats. *Indian J Pharmacol*, vol 45, 474–478.
- Sari, Y., Purnawan, I., Kurniawan, D.W., & Sutrisna, E. (2018). A Comparative Study of the Effect of *Nigella sativa* Oil Gel and Aloe Vera Gel on Wound Healing in Diabetic Rats. *Journal of Evidence-Based Integrative Medicine*, vol.23, pp.1-6.
- Shaw, T. J and Martin, P. (2009). Wound Repair at A Glance. *Journal of Cell Science*, 122(18), 3209–3213.
- Tahir, T., Bakri, S., Patellongi, I., Aman, M., Miskad, U.A., Maryunis., Yusuf, S., Rahayu, A. I., Syam, A.D., & H. (2017). Evaluation of Topical Red Dragon Fruit Extract Effect (*Hylocereus*

-
- Polyrhizus) on Tissue Granulation and Epithelialization in Diabetes Mellitus (DM) and Non-DM Wister Rats: Pre Eliminary Study. *International Journal of Sciences: Basic and Applied Research*, 32, pp.309-320.
- Tarawan, V.M., Mantilidewi, K. I., & Sutedja, E. (2016). *Coconut Shell Liquid Smoke Promotes Burn Wound Healing*. (38), pp.1-5.
- Tonks A, Cooper R.A, Price A.J, Molan P.C, & J. K. P. (2001). Stimulation of TNF- α release in monocytes by honey. *Cytokines*, 14, 240–242.
- Tonks A.J, Cooper R.A, Jones KP, Blair S, Parton J, & T. A. (2003). Honey stimulates inflammatory cytokines production from monocytes. *Cytokines*, 21, 242–247.
- Zohdi, R.M., Zaria, Z.A.B., Yusof, N., Mustapha, M & Abdullah, M. N. . (2012). Gelam (*Melaleuca* spp.) honey-based hydrogel as burn wound dressing. *Evidence-Based Complementary and Alternative Medicine*, 2012, 7.