

Safety of venipuncture sites at the cubital fossa as informed by ultrasonography

著者	Mukai Kanae, Nakajima Yukari, Nakano Tomotaka, Okuhira Manami, Kasashima Aya, Hayashi Rina, Yamashita Misaki, Urai Tamae, Nakatani Toshio
著者別表示	向井 加奈恵, 中島 由加里, 中谷 壽男
journal or publication title	Journal of Patient Safety
page range	8p.
year	2017-11-15
URL	http://doi.org/10.24517/00056142

doi: 10.1097/PTS.0000000000000441



OPEN

Safety of Venipuncture Sites at the Cubital Fossa as Assessed by Ultrasonography

Kanae Mukai, PhD, RN,* Yukari Nakajima, MHS, RN,† Tomotaka Nakano, RN,‡ Manami Okuhira, RN,‡ Aya Kasashima, RN,‡ Rina Hayashi, RN,‡ Misaki Yamashita, RN,‡ Tamae Urai, PhD, RN,† and Toshio Nakatani, PhD, MD*

Objective: The aim of the present observational study was to identify safe and suitable venipuncture sites for nursing in the clinical setting using ultrasonography to measure the depth and cross-sectional area of each superficial vein before and after tourniquet application as well as the distance between each superficial vein and the median nerve or brachial artery.

Methods and Results: Twenty healthy volunteers (21.8 [0.6]y) were recruited. The visible rate of each superficial vein before and after tourniquet application was 65% for the basilic vein, 90% to 95% for the median cubital vein, and 65% to 80% for the cephalic vein. The cross-sectional area of the median cubital vein after tourniquet application was significantly larger than that of the basilic vein and cephalic vein. The distance between the basilic vein or median cubital vein and median nerve was significantly smaller than that between the cephalic vein and median nerve. The distance between the basilic vein or median cubital vein and brachial artery was significantly smaller than that between the cephalic vein and brachial artery.

Conclusions: These results demonstrated that the cephalic vein at the cubital fossa is a relatively safe venipuncture site because of its distance from the median nerve and brachial artery. When puncturing the cephalic vein is difficult because it is not visible, the median cubital vein at the cubital fossa may be selected for venipuncture due to its cross-sectional area and visibility; however, care is needed to avoid penetrating the vein because the median nerve and brachial artery are located underneath.

Key Words: ultrasonography, superficial veins, median nerve, cubital fossa

(*J Patient Saf* 2017;00: 00–00)

Venipuncture is a medical procedure performed to collect venous blood specimens by physicians, nurses, and medical technologists. Sites including the cubital fossa, wrist, and dorsum of the hands are commonly used to perform venipuncture.¹ Among these sites, the cubital fossa is frequently selected as the venipuncture site to collect venous blood specimens.^{1–3} The basilic vein, median cubital vein, and cephalic vein are superficial veins that are frequently selected for venipuncture at the cubital fossa because of its characteristics: a thick lumen and an easily visible confirmation. However, relatively rare, but potentially

serious complications including nerve injury (1/21000,⁴ 1/25000,⁵ 1/30923,⁶ 1/67000⁷) and mistaken arterial punctures (1/34000⁸) have been reported. Therefore, the anatomical characteristics of the sites at which venipuncture is performed need to be clearly understood to prevent these complications.

Previous topographic anatomical studies reported that the cutaneous nerves run around these superficial veins at the cubital fossa^{3,9–11} and the brachial artery passes deeply along the ulnar side of the median cubital vein.^{2,3} Therefore, low-risk venipuncture sites are considered to be between the middle of the median cubital vein and the separation part of the cephalic and median cubital veins² or the area ranging from the middle segment of the median cubital vein to the confluence between the median cubital vein and cephalic vein.³ However, these topographic anatomical findings only revealed the anatomical running and positional relationships between superficial veins and nerves or arteries. The depth of each superficial vein from the skin surface and positional relationships between superficial veins and nerves or arteries in the living body currently remain unclear.

To resolve these issues, we herein focused on ultrasonography, which has the advantages of wide availability, noninvasiveness, and real-time processing. Ultrasonography is widely used and has improved the success rate of peripheral intravenous access in patients.^{12–15} It has also recently been employed to examine vein depths and widths as well as the locations of nerves.^{11,16} Ohnishi et al.¹⁶ only investigated the distance between the median nerve and closest major superficial vein at the cubital fossa. Therefore, the distances between the median nerve and each superficial vein, which are frequently selected for venipuncture, at the cubital fossa currently remain unclear. Furthermore, Kimori et al.¹¹ only conducted exams under nontourniquet application in healthy young adult (24.5[5.6] y). Therefore, the aim of the present study is to identify safe and suitable venipuncture sites for nursing in the clinical setting using ultrasonography to measure the depth and cross-sectional area of each superficial vein before and after tourniquet application as well as the distance between each superficial vein and the median nerve or brachial artery.

METHODS

Study Design, Setting, and Subjects

An observational study was conducted at a laboratory in Kanazawa University. Twenty healthy volunteers who met the following inclusion criteria were recruited (Table 1): (1) age ≥ 18 years, (2) no cardiovascular risk factors, and (3) willing to participate in this study.

Ethical Approval

All healthy volunteers gave written informed consent before participating in the study, which was approved by the ethics committee of Kanazawa University (Permit Number HS28-6-1).

From the *Department of Nursing Sciences, Faculty of Health Sciences, Institute of Medical, Pharmaceutical and Health Sciences, †Department of Clinical Nursing, Graduate Course of Nursing Science, Division of Health Sciences, Graduate School of Medical Sciences, and ‡Department of Nursing, School of Health Sciences, College of Medical, Pharmaceutical and Health Sciences, Kanazawa University, Kanazawa, Japan.

Correspondence: Toshio Nakatani, PhD, MD, Faculty of Health Sciences, Institute of Medical, Pharmaceutical and Health Sciences, Kanazawa University, 5-11-80 Kodatsuno, Kanazawa, 920-0942 Japan (e-mail: nakatosi@staff.kanazawa-u.ac.jp).

The authors disclose no conflict of interest.

Copyright © 2017 The Author(s). Published by Wolters Kluwer Health, Inc. This is an open-access article distributed under the terms of the Creative Commons Attribution-Non Commercial-No Derivatives License 4.0 (CCBY-NC-ND), where it is permissible to download and share the work provided it is properly cited. The work cannot be changed in any way or used commercially without permission from the journal.

TABLE 1. Participant Characteristics

Variables	Mean(SD)
Male/female, n	10/10
Age, y	21.8 (0.6)
Stature, cm	165.8 (8.5)
Body weight, kg	53.9 (7.8)
Body mass index, kg/m ²	19.5 (1.3)

Setting

All measurements were performed at the Hueter line, which is defined as a straight line connected with the medial epicondyle of the humerus, lateral epicondyle of the humerus, and olecranon of the ulna at the left side of the cubital fossa. The tourniquet application site was identified as the lower point one-third from the acromion to the Hueter line (Fig. 1A), in accordance with a previous study.¹⁷ Tourniquet pressure was defined as the value obtained by multiplying the circumference diameter at the tourniquet application site by 0.9, in accordance with a previous study.¹⁸ Circumference diameters were measured three times and the average was calculated.

Procedure

All measurement data were collected by trained nursing students between August and October 2016. Subjects sat on a seat and their left forearms were placed on a desk in a comfortable position during the measurement period. Three nursing students evaluated whether the superficial veins (basilic vein, median cubital vein, and cephalic vein) were visible before and after tourniquet application at the Hueter line (Fig. 1B). In this evaluation, three nursing students judged visibility with the naked eye only; they did not use a magnifying glass. Each nursing student added a check mark to the sheet if a superficial vein was visible. The superficial veins were considered to be visible only when all three nursing students were in agreement. Visible superficial veins were marked with a marker and photographed. After applying ultrasound transmission gel (Aquasonic 100; Parker Laboratories Inc, Fairfield, NJ) on the skin, the probe was placed on the

transmission gel transversely at the Hueter line and moved distally and proximally to examine the superficial veins, median nerve, and brachial artery. Ultrasound cross-sectional images of each superficial vein, the median nerve, and brachial artery were recorded three times before and after tourniquet application. In the recording of ultrasound cross-sectional images of each superficial vein, a sufficient amount of ultrasound transmission gel was applied at the Hueter line and the probe was placed on the transmission gel with minimal pressure to optimize ultrasound image quality. When ultrasound cross-sectional images of the median nerve and brachial artery were being recorded, the focus was matched with the median nerve or brachial artery to provide details for visualization. While recording ultrasound cross-sectional images after tourniquet application, the tourniquet time was kept within 1 minute.

Ultrasonography

B-mode cross-sectional images of the superficial vein, median nerve, and brachial artery were acquired using Noblus (Hitachi Aloka Medical Inc) with a 5- to 18-MHz linear transducer (Hitachi Aloka medical Inc). Ultrasound scanning was performed by two nursing students who had sufficient training from a researcher with experience of ultrasound. To minimize differences in abilities, two separate students conducted sufficient training until the diameters of superficial veins could be maintained. In ultrasound cross-sections, the nerve typically appears as a round formation that is hyperechogenic from the surrounding muscular tissues, often containing small round hypoechoic areas related to single nerve fibers.^{19,20} Therefore, the median nerve was identified when all trained nursing students confirmed its visualization.

Ultrasound Imaging Analysis

Two observers analyzed all B-mode cross-sectional images for each subject by independent. All parameters were measured three times and the average was calculated.

In each B-mode cross-sectional image, the minimal distance between each superficial vein and the skin and the maximum and minimum diameters of each superficial vein were measured using software that included Noblus (Hitachi Aloka Medical Inc). The minimal distance between each superficial vein and the skin

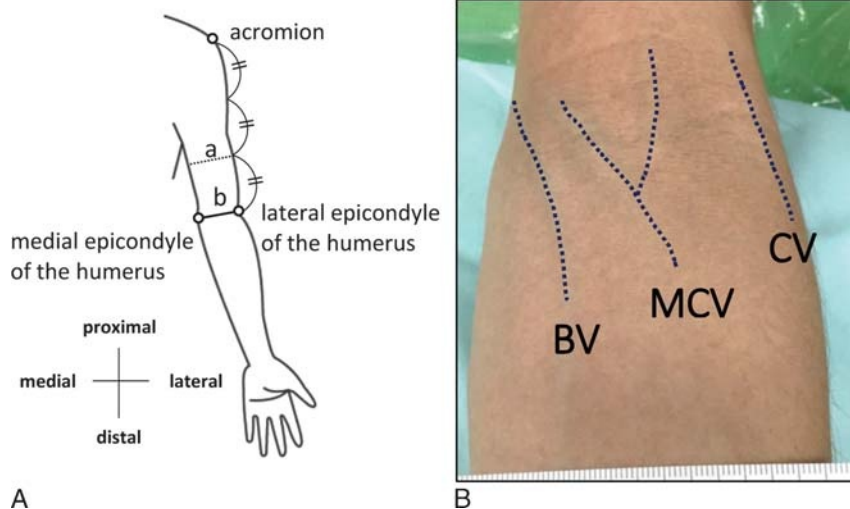


FIGURE 1. An experimental method. A, The image shows the method for identifying a tourniquet application site. a = The tourniquet application site was identified as the lower point one-third from the acromion to the Hueter line. b = The Hueter line was defined as a straight line connecting the medial epicondyle of the humerus, the lateral epicondyle of the humerus, and the olecranon of the ulna at the left side of the cubital fossa. B, The photograph shows visible superficial veins. BV, basilic vein; MCV, median cubital vein; CV, cephalic vein.

(vein depth) was measured as the shortest distance from the skin to the inner venous wall¹³ (Fig. 2A). The maximum and minimum diameters of each superficial vein were measured as the shortest distance between both sides of the inner venous wall^{13,21} (Fig. 2A). Cross-sectional areas were subsequently calculated with the formula $D1 \times D2 \times \pi/4$ (a fixed numerical value), where D1 and D2 are the maximum and minimum diameters, respectively.²¹

The ultrasound B-mode cross-sectional images of the superficial vein were combined with a focus on the brachial artery. Then, the shortest distance between each superficial vein and the median nerve and the shortest distance between each superficial vein and

the brachial artery were measured by the image analysis software ImageJ (National Institutes of Health, Bethesda, MD) in accordance with previous study¹⁶ (Fig. 2B).

Statistical Analysis

Statistical analyses were performed using the statistical analysis software JMP 12.1.0 (SAS Institute Inc, Cary, NC). A *P* value of less than 0.05 was considered to be significant.

Differences in vein depth, maximum diameter, minimum diameter, and the cross-sectional area of each superficial vein before and after tourniquet application were assessed by a paired sample *t* test.

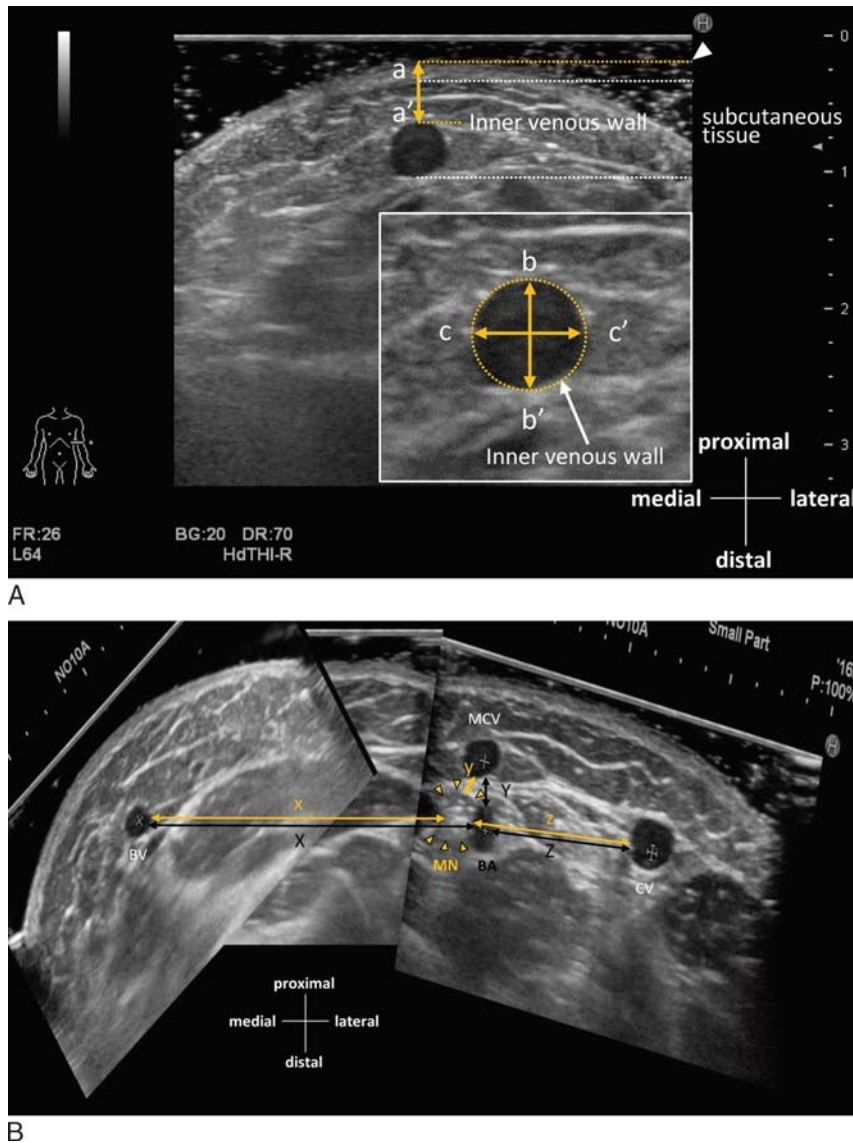


FIGURE 2. Ultrasound image analysis. A, The ultrasound image shows the measurement of depth and diameter. a-a' shows the minimal distance between each superficial vein and the skin (vein depth). b-b' shows the minimum diameter of each superficial vein, and c-c' shows the maximum diameter of each superficial vein. B, The ultrasound image shows the measurement of the distance between each superficial vein and the median nerve or brachial artery. The yellow straight lines show the shortest distance between each superficial vein and the median nerve (x = the distance between the basilic vein and median nerve, y = the distance between the median cubital vein and median nerve, and z = the distance between the cephalic vein and median nerve). The black straight lines show the shortest distance between each superficial vein and the brachial artery (X = the distance between the basilic vein and brachial artery, Y = the distance between the median cubital vein and brachial artery, and Z = the distance between the cephalic vein and brachial artery). BA, brachial artery; BV, basilic vein; CV, cephalic vein; MCV, median cubital vein; MN, median nerve.

The cross-sectional areas of each superficial vein after tourniquet application were compared with a Kruskal-Wallis test followed by post hoc pairwise comparisons using the Steel-Dwass multiple comparison test.

The distances between each superficial vein and the median nerve or brachial artery were compared with a Kruskal-Wallis test followed by post hoc pairwise comparisons using the Steel-Dwass multiple comparison test.

To assess the factors influencing the visibility of the superficial veins, a logistic regression analysis was performed with the characteristics of superficial veins and subjects as dependent variables. Variables that may influence the visibility of the superficial veins were entered as independent variables after confirming their multicollinearity ($r > 0.8$).

RESULTS

Visual or Nonvisual Confirmation of Each Superficial Vein Before and After Tourniquet Application

The visible rate of each superficial vein before and after tourniquet application was 65% (13/20) to 65% (13/20) for the basilic vein, 90% (18/20) to 95% (19/20) for the median cubital vein, and 65% (13/20) to 80% (16/20) for the cephalic vein.

Characteristics of Each Superficial Vein Using Ultrasonography Before and After Tourniquet Application

The mean (SD) vein depths of each superficial vein before and after tourniquet application were 3.1(1.9)mm to 2.9(1.7)mm for the basilic vein, 3.0(1.8)mm to 1.7(0.8)mm for the median cubital vein, and 2.1(0.8)mm to 1.7(0.6)mm for the cephalic vein. The depths of the median cubital vein and cephalic vein were

significantly shallower after than before tourniquet application ($P < 0.01$) (Table 2).

The mean (SD) maximum diameters of each superficial vein before and after tourniquet application were 2.5(1.6)mm to 2.6(0.7)mm for the basilic vein, 4.4(1.1)mm to 4.9(1.5)mm for the median cubital vein, and 2.7(1.4)mm to 2.9(1.6)mm for the cephalic vein. The maximum diameter of the median cubital vein was significantly larger after than before tourniquet application ($P < 0.05$) (Table 2). The mean minimum diameters of each superficial vein before and after tourniquet application were 1.7(0.6)mm to 2.2(0.7)mm for the basilic vein, 2.3(1.0)mm to 3.2(1.2)mm for the median cubital vein, and 1.7(0.7)mm to 2.2(0.8)mm for the cephalic vein. The minimum diameter of each superficial vein was significantly larger after than before tourniquet application ($P < 0.01$) (Table 2). The mean (SD) cross-sectional areas of each superficial vein before and after tourniquet application were 4.6(4.1)mm² to 6.0(3.1)mm² for the basilic vein, 10.3(5.5)mm² to 16.6(9.5)mm² for the median cubital vein, and 5.4(4.2)mm² to 7.6(6.3)mm² for the cephalic vein. The cross-sectional area of each superficial vein was significantly larger after than before tourniquet application ($P < 0.05$) (Table 2). Moreover, the median (range) cross-sectional area after tourniquet application was 5.1 (1.9–14.8) mm² for the basilic vein, 14.2 (2.0–40.0) mm² for the median cubital vein, and 6.0 (0.8–27.1) mm² for the cephalic vein. The cross-sectional area of the median cubital vein after tourniquet application was significantly larger than that of the basilic vein and cephalic vein ($P < 0.01$) (Fig. 3A).

Distances Between Each Superficial Vein and the Median Nerve or Brachial Artery

The median (range) distance between the basilic vein and median nerve was 8.8(1.5–29.9) mm, between the median cubital vein and median nerve was 7.6 (1.7–21.3) mm, and between the

TABLE 2. Ultrasound Characteristics Before and After Tourniquet Application

Variables	Before (n = 20)	After (n = 20)	P
	Mean(SD)	Mean(SD)	
Depth,* mm			
BV	3.1 (1.9)	2.9 (1.7)	0.23
MCV	3.0 (1.8)	1.7 (0.8)	<0.01
CV	2.1 (0.8)	1.7 (0.6)	<0.01
Maximum diameter,† mm			
BV	2.5 (1.6)	2.6 (0.7)	0.99
MCV	4.4 (1.1)	4.9 (1.5)	<0.05
CV	2.7 (1.4)	2.9 (1.6)	0.30
Minimum diameter,† mm			
BV	1.7 (0.6)	2.2 (0.7)	<0.01
MCV	2.3 (1.0)	3.2 (1.2)	<0.01
CV	1.7 (0.7)	2.2 (0.8)	<0.01
Cross-sectional area,‡ mm ²			
BV	4.6 (4.1)	6.0 (3.1)	<0.01
MCV	10.3 (5.5)	16.6 (9.5)	<0.05
CV	5.4 (4.2)	7.6 (6.3)	<0.01

*Measured as the shortest distance from the skin to the inner venous wall (Fig. 1B).

†Measured as the shortest distance between both sides of the inner venous wall (Fig. 1B).

‡Calculated using the formula $D1 \times D2 \times \pi/4$ (a fixed numerical value), where D1 and D2 are the maximum and minimum diameters, respectively (Fig. 1B).

BV, basilic vein; CV, cephalic vein; MCV, median cubital vein.

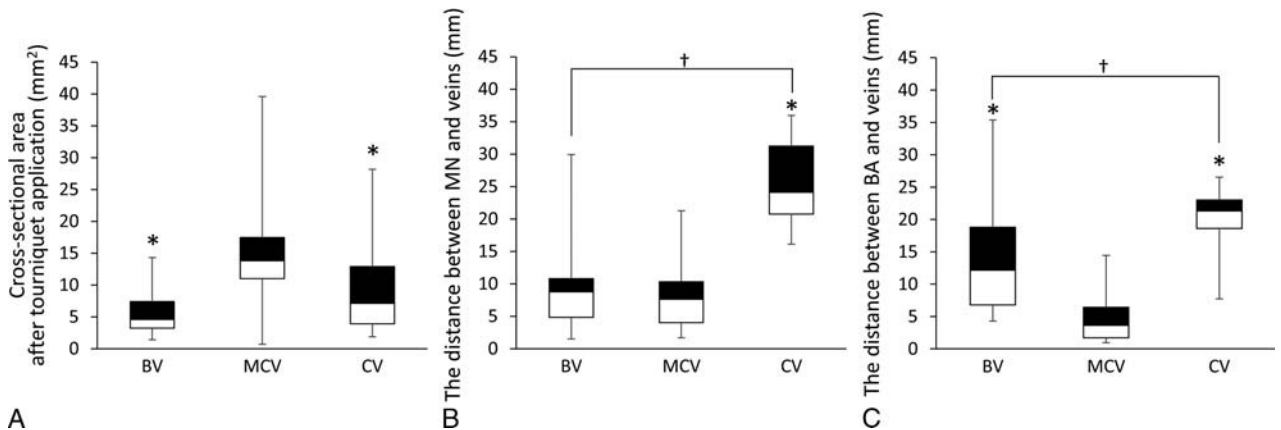


FIGURE 3. Vein area after tourniquet application and distances between the median nerve or brachial artery and each superficial vein. A, The cross-sectional area after tourniquet application is shown in the box plot. B, The distance between the median nerve and each superficial vein is shown in the box plot. C, The distance between the brachial artery and each superficial vein is shown in the box plot (n = 20 for each vein, Kruskal-Wallis and the Steel-Dwass multiple comparison test). **P* < 0.01: the median cubital vein versus the basilic vein or cephalic vein. †*P* < 0.01: the basilic vein versus the cephalic vein. BA, brachial artery; BV, basilic vein; CV, cephalic vein; MCV, median cubital vein; MN, median nerve.

cephalic vein and median nerve was 24.1 (16.1–36.0) mm. The distance between the basilic vein or median cubital vein and median nerve was significantly smaller than that between the cephalic vein and median nerve (*P* < 0.01) (Fig. 3B).

The median distance between the basilic vein and brachial artery was 12.2(4.3–35.4) mm, between the median cubital vein and brachial artery was 3.6(1.0–14.5) mm, and between the cephalic vein and brachial artery was 21.3(7.7–26.5) mm. The distance between the basilic vein or median cubital vein and brachial artery was significantly smaller than that between the cephalic vein and brachial artery (*P* < 0.01) (Fig. 3C). Moreover, the distance between the median cubital vein and brachial artery was significantly smaller than that between the basilic vein and brachial artery (*P* < 0.01) (Fig. 3C).

The Positional Relationship Between the Median Nerve and Brachial Artery

In the present study, three kinds of positional relationships were observed between the median nerve and brachial artery. In most cases, the median nerve and brachial artery were located at the same distance from the epidermis (80%, 16/20 cases) (Fig. 4A). On the other hand, the median nerve was located in a more superficial layer than the brachial artery (5%, 1/20) (Fig. 4B) and in a deeper layer than the brachial artery (15%, 3/20) in some cases (Fig. 4C). In cases in which the median nerve was located in a more superficial layer than the brachial artery, the distance between the median nerve and cubital median vein was 0.81 mm.

Factors Influencing the Visibility of Superficial Veins

Ninety-two superficial veins (76.7%) were clearly visible, whereas 28 (23.3%) were not. Four variables were entered as dependent variables into the logistic regression model with superficial vein visibility. Vein depth and area strongly influenced superficial vein visibility. The odds ratio of vein depth was 2.840-fold higher (*P* < 0.01, confidence interval [CI] = 1.790–5.030) (Table 3), whereas that of vein area was 0.808-fold higher (*P* < 0.01, CI = 0.695–0.916) (Table 3).

Distribution of Visible Superficial Veins and Nonvisible Superficial Veins

A scatter diagram showed the distribution of visible superficial veins (Fig. 5A) and nonvisible superficial veins (Fig. 5B). A total of 89.1% (82/92 superficial veins) of visible superficial veins were at a vein depth of less than 3 mm, whereas 91.3% (84/92 superficial veins) of visible superficial veins had a vein area of 2.5 mm² or greater. On the other hand, 64.3% (18/28 superficial veins) of nonvisible superficial veins were at a vein depth of 3 mm or greater and 42.9% (12/28 superficial veins) of nonvisible superficial veins had a vein area of less than 2.5 mm², regardless of tourniquet application.

DISCUSSION

The aim of the present study is to identify safe and suitable venipuncture sites for nursing in the clinical setting using ultrasonography to measure the depth and cross-sectional area of each superficial vein before and after tourniquet application as well as the distance between each superficial vein and the median nerve or brachial artery. Because topographic anatomical investigations previously reported safe venipuncture sites,^{2,3,11} we attempted to establish safe venipuncture sites that are more suitable for clinical settings using an ultrasound investigation. The results obtained showed that the cephalic vein and median cubital vein are relatively safe venipuncture sites.

Venipuncture is a medical procedure performed to collect venous blood specimens by physicians, nurses, and medical technologists, with the cubital fossa frequently being selected as the venipuncture area to collect venous blood specimens.^{1–3} However, relatively rare, but potentially serious complications including nerve injury (1/21000,⁴ 1/25000,⁵ 1/30923,⁶ 1/67000⁷) and mistaken arterial punctures (1/34000⁸) have been reported. Therefore, the anatomical characteristics of venipuncture need to be more clearly understood to prevent these complications. The present results showed that the cephalic vein was more distant from the median nerve and brachial artery than the basilic vein or median cubital vein. Previous studies reported that the brachial artery passed deeply under the unification part of the basilic and median cubital veins and deeply along the ulnar side of the median cubital vein.^{2,3} Ohnishi et al.¹⁶ reported that the median nerve was located

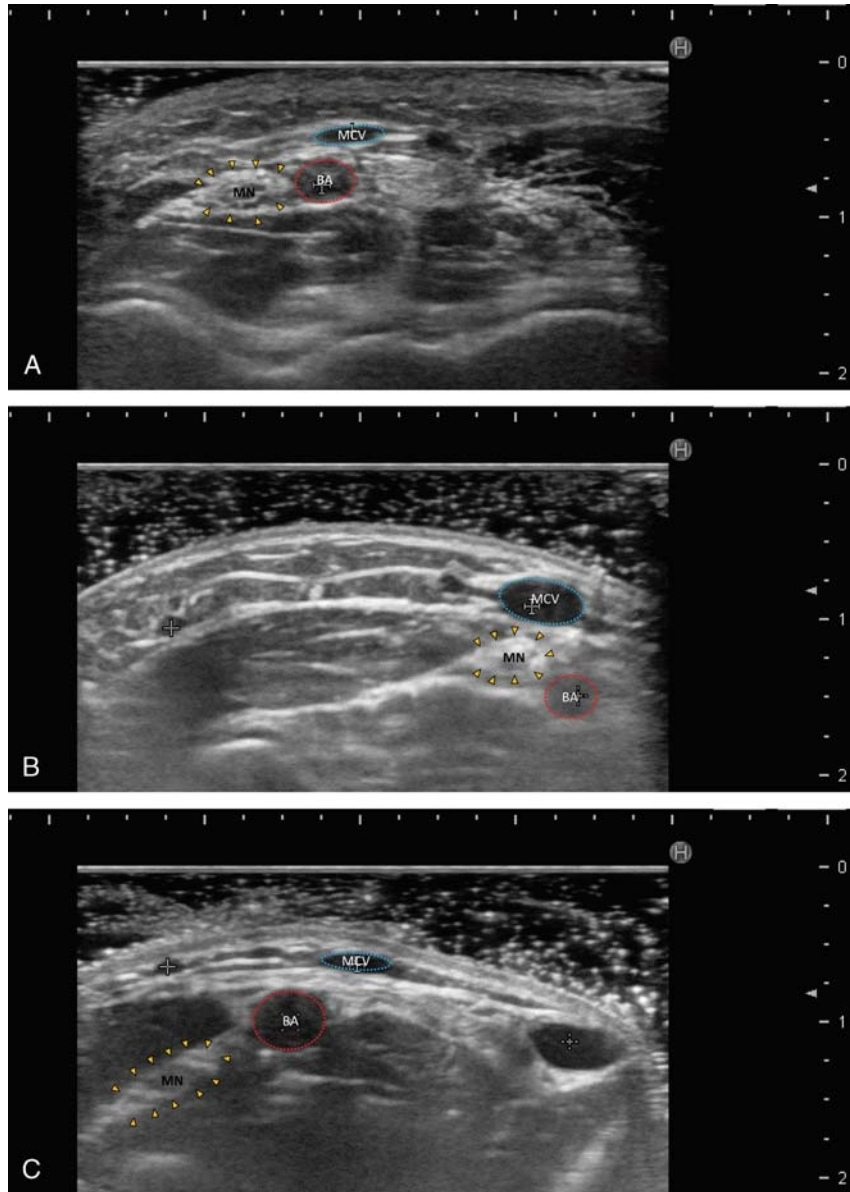


FIGURE 4. Ultrasound images showing positional relationships between the median nerve and brachial artery. A, The median nerve and brachial artery were located at the same distance from the epidermis. B, The median nerve was located in a more superficial layer than the brachial artery. C, The median nerve was located in a deeper layer than the brachial artery. BA, brachial artery; MCV, median cubital vein; MN, median nerve.

on the ulnar side of the brachial artery at the level of the elbow crease. Moreover, Kimori et al.¹¹ showed that the lateral antebrachial cutaneous nerve descended along the deep layer of the cephalic vein. These findings and the present results indicate that the cephalic vein at the cubital fossa is a relatively safe venipuncture site because of its distance from the median nerve, brachial artery, and superficial nerve.

However, the present results showed that the cross-sectional areas of the basilic vein and cephalic vein after tourniquet application were significantly smaller than that of the median cubital vein, and the cephalic vein was not visible in 20% of healthy young volunteers after tourniquet application. This result indicates that although the cephalic vein is a relatively safe venipuncture site because of its distance from the nerves and artery, it is not a guaranteed puncturable blood vessel because it is not visible in some cases. Therefore, when the cross-sectional area of the cephalic

vein is too small to be visible, other sites need to be considered. In the present study, the basilic vein had a lower visible rate and smaller vein area than the median cubital vein; however, no

TABLE 3. A Logistic Regression Analysis of the Visibility of Superficial Veins

Independent Variable	Odds Ratio (95% CI for Odds Ratio)	P
Vein depth, mm	2.840 (1.790–5.030)	<0.01
Vein area, mm ²	0.808 (0.695–0.916)	<0.01

0: visible (92) and 1: nonvisible (28), n = 120.

Other independent variables: tourniquet application (1: after, 0: before) and sex (1: male, 0: female).

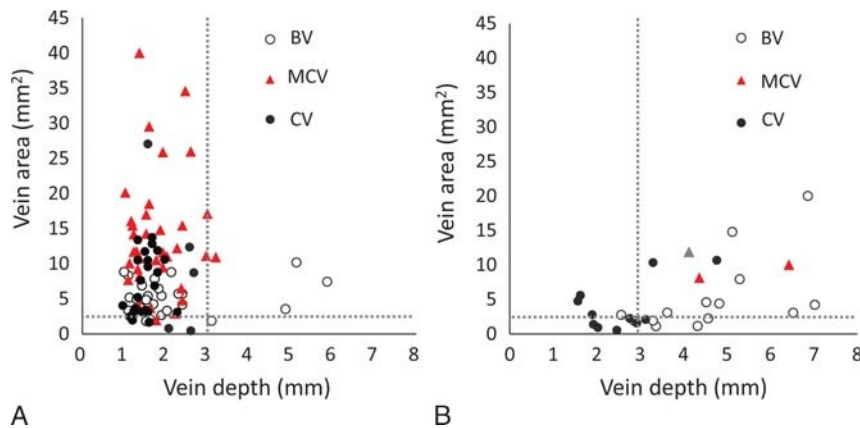


FIGURE 5. Scatter diagram of vein depth and area. A, The distribution of visible superficial veins. B, The distribution of nonvisible superficial veins. BV indicated with a white circle (basilic vein), CV indicated with a black circle(cephalic vein), and MCV indicated with a red triangle (median cubital vein).

significant change was detected in the depth of the basilic vein before and after tourniquet application, and it was not as distant from the median nerve and the brachial artery as the cephalic vein. Moreover, in anatomical observations, previous studies reported that the median antebrachial cutaneous nerve descended along the superficial layer of the basilic vein.^{3,11} These findings and the present results indicate that the basilic vein at the cubital fossa is not suitable for venipuncture. On the other hand, the present study showed that although the median cubital vein was close to the median nerve and brachial artery, the size of the median cubital vein was the largest and its visibility was the highest. Previous studies using anatomical observations reported that fewer cutaneous nerves crossed the superficial layer of the radial median cubital vein, whereas the brachial artery was distributed in the aponeurosis deep layer along this vein,¹¹ and it passed deeply under the unification part of the basilic and median cubital veins and deeply along the ulnar side of the median cubital vein.^{2,3} Moreover, a previous study reported that the distal superficial vein from the cubital fossa line needs to be punctured to avoid penetrating the vein.¹¹ Therefore, these findings and the present results indicate that the median cubital vein at the cubital fossa is suitable for venipuncture^{2,3,11} when it is difficult to puncture the cephalic vein. However, if venipuncture is performed at the median cubital vein, nurses need to avoid penetrating the vein because the median nerve and brachial artery are present underneath.

Our results showed positional relationships between the median nerve and brachial artery. In most cases, the median nerve and brachial artery were located at the same distance from the epidermis (16/20 cases). However, the median nerve was located in a more superficial layer than the brachial artery in one case (1/20); the distance between the median nerve and median cubital vein was 0.81 mm, and thus, if a puncture needle penetrates the blood vessel, there is a high risk of nerve injury. A previous study reported that the distance between the median nerve and closest major superficial vein at the elbow ranged between 0.5 and 27.8 mm.¹⁶ Therefore, positional relationships between the superficial veins, median nerve, and brachial artery need to be confirmed using ultrasonography when venipuncture is performed and particularly when the superficial veins are not visible.

The present study showed differences between visible and nonvisible superficial veins. Previous studies reported that vein size and depth were related to the visibility of the superficial veins or success rate of venipuncture.^{12,22–24} However, these studies merely described the vein size and depth as parameters affecting the visibility of the superficial veins or success rate of

venipuncture^{12,24} or only showed that vein depth influenced the visibility of the superficial veins by a univariate analysis²² or multilogistic regression analysis.²³ On the other hand, in the present study, the logistic regression analysis showed that vein depth and area strongly influenced the visibility of the superficial veins. Moreover, our scatter plot showed that the visibility of the superficial veins was more than 80% when a vein depth of less than 3 mm or vein area of 2.5 mm² or greater were set as the cut-off point. When vein depth of 3 mm or greater or vein area of less than 2.5 mm², the visibility of the superficial veins decreased to approximately 40% to 60%. These results indicate that the visibility of the superficial veins decreased when the vein depth was 3 mm or greater and the vein area was 2.5 mm² or less.

Our present findings can assist nurses to improve current practice by providing knowledge based on anatomical investigation using ultrasonography. The guidelines for selecting a peripheral venipuncture site described in the textbook published in the United States²⁵ are as follows: (1) look for a vein that has a firm, round appearance with a relatively straight pathway; (2) the cephalic vein of the arm is one of the best veins to use because it is relatively large, and the forearm provides a natural splint; (3) if available, use visualization technologies, such as portable ultrasound or imaging devices. This textbook is limited to mention a general point, and the anatomical evidence is not clearly described. Therefore, our present study suggests the following points. (1) The cephalic vein at the cubital fossa is a relatively safe venipuncture site because of its distance from the median nerve, brachial artery, and superficial nerve. (2) When puncturing the cephalic vein is difficult because it is not visible, the median cubital vein at the cubital fossa is selected for venipuncture because of its cross-sectional area and visibility; however, care is needed to avoid penetrating the vein because the median nerve and brachial artery are present underneath. (3) If the superficial veins are not visible, they are present at a depth of 3 mm or greater or have a small vein area of 2.5 mm² or less. In addition, if the superficial veins are not visible, positional relationships between the superficial veins, median nerve, and brachial artery need to be confirmed using ultrasonography. By acquiring this knowledge, it is believed that safe venipuncture can be performed by nurses.

The present study had limitations. We only investigated healthy, young, and lean or normal weight subjects from an Asian population. It is important to note that variations in age, body mass index, ethnicity, and the presence of venous disease or circulatory issues may affect measurements. Moreover, this study

conducted a small sample size. Therefore, the generalization of this study is limited and further research is needed. In addition, because it was not possible to blind the three nursing students assessing superficial vein visibility, we cannot deny the possibility that there is some potential influence.

CONCLUSIONS

Our results confirmed that the cephalic vein at the cubital fossa is a relatively safe venipuncture site because of its distance from the median nerve and brachial artery. When puncturing the cephalic vein is difficult because it is not visible, the median cubital vein at the cubital fossa is selected for venipuncture because of its cross-sectional area and visibility; however, care is needed to avoid penetrating the vein because the median nerve and brachial artery are present underneath. Moreover, if the superficial veins are not visible, they are present at a depth of 3 mm or greater or have a small vein area of 2.5 mm² or less.

ACKNOWLEDGMENT

The authors thank Ms. Hanae Nitta for assistance with collecting data and discussions about the data.

REFERENCES

- Kato J. Peripheral nerve injury in venipuncture [in Japanese]. *Masui*. 2010; 59:1357–1363.
- Mikuni Y, Ichinohe T, Chiba S. Topographic anatomy of superficial veins and brachial arteries in cubital fossa for safe venous puncture site [in Japanese]. *Struct Funct*. 2012;10:86–93.
- Mikuni Y, Chiba S, Tonosaki Y. Topographical anatomy of superficial veins, cutaneous nerves, and arteries at venipuncture sites in the cubital fossa. *Anat Sci Int*. 2013;88:46–57.
- Newman BH, Waxman DA. Blood donation-related neurologic needle injury: evaluation of 2 years' worth of data from a large blood center. *Transfusion*. 1996;36:213–215.
- Berry PR, Wallis WE. Venepuncture nerve injuries. *Lancet*. 1977;11: 1236–1237.
- Kato J, Araki H, Kimura M, et al. Incidence and prognosis of persistent pain induced by venipuncture for blood sampling: an observational study over a 5-year period. *Pain Med*. 2012;13:1627–1630.
- Tsukuda Y, Funakoshi T, Nasuhara Y, et al. Venipuncture nerve injuries in the upper extremity from more than 1 million procedures. *J Patient Saf*. 2016. [Epub ahead of print].
- Newman BH. Arterial puncture phlebotomy in whole-blood donors. *Transfusion*. 2001;41:1390–1392.
- Yamada K, Yamada K, Katsuda I, et al. Cubital fossa venipuncture sites based on anatomical variations and relationships of cutaneous veins and nerves. *Clin Anat*. 2008;21:307–313.
- Hori M, Miura M, Arao H, et al. Morphology of the topographical relations between cutaneous veins and nerves in the human upper extremity [in Japanese]. *Jap J Nurs Art Sci*. 2009;8:20–28.
- Kimori K, Dai M, Sugama J, et al. Positional relationship between the superficial venous and cutaneous nerve distributions in the cubital fossa: basic study for venous puncture techniques [in Japanese]. *Struct Funct*. 2010;8:67–72.
- Witting MD, Schenkel SM, Lawner BJ, et al. Effects of vein width and depth on ultrasound-guided peripheral intravenous success rates. *J Emerg Med*. 2010;39:70–75.
- Brandt HG, Jepsen CH, Hendriksen OM, et al. The use of ultrasound to identify veins for peripheral venous access in morbidly obese patients. *Dan Med J*. 2016;63:pii:A5191.
- Stolz LA, Stolz U, Howe C, et al. Ultrasound-guided peripheral venous access: a meta-analysis and systematic review. *J Vasc Access*. 2015;16: 321–326.
- Costantino TG, Kirtz JF, Satz WA. Ultrasound-guided peripheral venous access vs. the external jugular vein as the initial approach to the patient with difficult vascular access. *J Emerg Med*. 2010;39:462–467.
- Ohnishi H, Urata T, Kishino T, et al. A novel maneuver to prevent median nerve injury in phlebotomy. *Ann Intern Med*. 2009;151:290–291.
- Katou A, Mori M. Tourniquet pressure and tourniquet application method when nurses perform venipuncture [in Japanese]. *J Jap Soc Nurs Res*. 2010;33:131–136.
- Kato A, Mori M. The effect of pressure of tourniquet for venipuncture on overswelling of the vein—Fasten ratio of tourniquet to upper arm circumference [in Japanese]. *Jap J Nurs Art Sci*. 2009;8:10–15.
- Graif M, Seton A, Nerubai J, et al. Sciatic nerve: sonographic evaluation and anatomic-pathologic considerations. *Radiology*. 1991;181:405–408.
- Ricci S. Ultrasound observation of the sciatic nerve and its branches at the popliteal fossa: always visible, never seen. *Eur J Vasc Endovasc Surg*. 2005;30:659–663.
- Planken RN, Keuter XH, Kessels AG, et al. Forearm cephalic vein cross-sectional area changes at incremental congestion pressures: towards a standardized and reproducible vein mapping protocol. *J Vasc Surg*. 2006; 44:353–358.
- Kimori K, Sugama J, Nakatani T, et al. Investigation of invisible peripheral veins for certain and safe venipuncture in catheter placement: non-invasive measurement of width, depth, and skin color [in Japanese]. *Jap J Nurs Art Sci*. 2011;10:103–110.
- Ichimura M, Matsumura Y, Sasaki S, et al. The characteristic of healthy adults with hardly palpable vein—relations between easy venous palpation and physical factors. *Int J Nurs Pract*. 2015;21:805–812.
- Kimori K, Sugama J. Investigation of vasculature characteristics to improve venepuncture techniques in hospitalized elderly patients. *Int J Nurs Pract*. 2016;22:300–306.
- Treas LS, Wilkinson JM. *Basic Nursing, Concepts, Skills & Reasoning*. Philadelphia, PA: F. A. Davis Company; 2014;1409.