

Growth factors, genes, bone proteins and apoptosis in the temporomandibular joint (TMJ) of children with ankylosis and during disease recurrence

Mara Pilmane, Andrejs Skagers

SUMMARY

Aim of study was complex detection of appearance and distribution of growth factors, facial bone growth stimulating genes, ground substance proteins and apoptosis in bone of ankylotic TMJ in primary and repeatedly operated children.

Materials and Methods. Ankylotic tissue was obtained during the arthroplastic surgery from two 6 years old children (boy and girl) with osseous type of disease. The girl underwent the repeated surgery in TMJ due to the same diagnosis in age of 12 years. Ankylotic tissue was proceeded for detection of BMP2/4, TGF β , Msx2, osteopontin, osteocalcin immunohistochemically, and apoptosis.

Results demonstrated massive bone formation intermixed by neochondrogenesis, the lack of BMP 2/4, but abundant number of TGF β -containing cells in bone of all tested cases. Despite rich osteopontin positive structures in bone obtained from both – primary and repeated surgery, osteocalcin demonstrated variable appearance in 6 years aged children, but was abundant in joint 5 years later during disease recurrence. Expression of Msx2 varied widely before, but with tendency to decrease stabilized until few positive cells in bone of 12 years old girl. Apoptosis practically was not detected in primarily operated TMJ, but massively affected the supportive tissue in girl with recurrent ankylosis.

Conclusions. The lack of BMP2/4 expression in ankylotic bone proves the disorders in cellular differentiation with simultaneous compensatory intensification of cellular proliferation and/or growth by rich expression of TGF β leading to the remodelling of TMJ.

Mainly rich distribution of osteocalcin and osteopontin indicate the intensive mineralization processes of ankylotic bone.

Persistent Msx2 expression is characteristic for the supportive tissue of recurrent ankylosis of TMJ and indicates the persistent stimulation of bone growth compensatory limited by massive increase of programmed cell death.

Key words: growth factors, osteopontin, osteonectin, apoptosis, temporomandibular joint, children.

INTRODUCTION

The ankylosis or hypomobility of temporomandibular joint (TMJ) is of multifactorial aetiology, interferes with the growth of affected condyle and further fusion of it and the glenoid cavity and skull

base [1, 2]. Additionally, there are some variations in ossification of the TMJ and surrounding tissue that not always could be operated and/or followed up [3]. Main morphological changes enrolled chondroid hyperplasia [4] and transformation of the cartilage cells into osteocytes [5]. However, patomorphology of ankylosis is not unite and also displays different aspects. Progressive ankylosis gene (ank) which regulates the osteoblast differentiation is discovered lately [6]. Mice models demonstrated also involvement of deficiency of Indian hedgehog in disregulation of some growth factors and the same growth of TMJ,

¹*Institute of Anatomy and Anthropology, Riga Stradins University, Riga, Latvia*

²*Institute of Stomatology, Riga Stradins University, Latvia*

*Mara Pilmane*¹ – MD, Dr. hab. med., prof.
*Andrejs Skagers*² – MD, Dr. hab. med., prof.

Address correspondence to Prof. Mara Pilmane, Dzirciema street 16, Riga LV-1007, Latvia.
E-mail address: pilmane@latnet.lv



Fig. 1. Complete fusion between mandible, zygoma and temporal bone: beginning of separation. 6 years old girl with osseous ankylosis of TMJ.

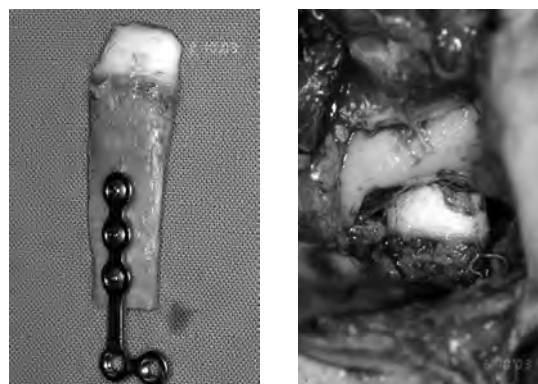


Fig. 2, 3. Reconstruction using costochondral graft in 12 years old girl with osseous ankylosis of TMJ

leading to condylar disorganization [7] and *Shox2* [8] that plays a role in expression of osteogenic genes. Also hydrostatic pressure is mentioned among significant mechanical forces as a regulator of functions in supportive tissue and even expression of different growth factors [9]. Despite of the above mentioned it is not clear whether there are correlations between the influence of complex genes/growth factors/supportive tissue proteins and between recurrence of ankylosis in TMJ in long period of time. Also such molecular event as programmed cell death that is described to play an important role in TMJ during local tissue reduction [10] and inflammatory diseases [11], is not characterized in ankylotic tissue of this region at all. Thus, our aim was complex detection of appearance and distribution of growth factors, facial bone growth stimulating genes, ground substance proteins and apoptosis in bone of ankylotic TMJ in primary and repeatedly operated children.

MATERIALS AND METHODS

Ankylotic tissue was obtained during the primary arthroplastic surgery from two 6 years old

(one girl and one boy) old children (Figures 1-3) with osseous type of disease. Despite the rib bone/cartilage autotransplantation in TMJ the girl underwent the repeated surgery due to the recurrence of disease in age of 12. The resected tissues (Fig. 4) of both – primary and secondary surgeries were fixed in Stefanini’s solution and after decalcified into “Decalcifer, rapid” (I.T. Baker company, code ITB RS 155800054, The Netherland) solution for 24 hours. Then tissues were dehydrated through a graded series of ethanol, embedded in paraffin, and sectioned into 5 µm thick slices.

For bone fragments of each case general morphological evaluation, routine staining with haematoxylin and eosin was performed. For immunohistochemistry (IMH) antibodies against: bone morphogenetic protein 2/4 (BMP 2/4, working dilution 1:100, R and D systems, UK), osteocalcin (working dilution 1:100, Abcam, UK), osteopontin (working dilution 1:100, Abcam, UK), transforming growth factor beta (TGFβ, working dilution 1:1000, Cambridge Science Park, UK); homeobox-containing transcription factor muscle segment homeobox 2 (*Msx2*, mouse, 1: 250, Abcam, UK) were

Table. Semiquantitative evaluation of relative appearance in growth factors, genes, bone proteins and apoptosis in TMJ ankylotic bone before and after its reconstruction

Factors//TMJ	TGFβ	BMP 2/4	Msx2	Osteopontin	Osteocalcin	TUNEL
Primary surgery cases n=2 (6 years old boy and 6 years old girl)	++++	–	0/++++	+++	++++	0/+
Repeated surgery case n=1 (12 years old girl, the same as above)	++++	–	+	+++	++++	++++

TMJ – temporomandibular joint;
 TGFβ – transforming growth factor beta;
 BMP 2/4 – bone morphogenetic protein 2/4;
 Msx2 – homeobox-containing transcription factor muscle segment homeobox 2;
 TUNEL – terminal deoxynucleotidyl transferase-mediated deoxyuridinetriphosphate nick end-labelling;
 0/+ – occasional positive structures seen in visual field;
 + – few immunoreactive structures seen in visual field;
 +++ – numerous immunoreactive structures seen in visual field;
 ++++ – abundance of immunoreactive structures seen in visual field.

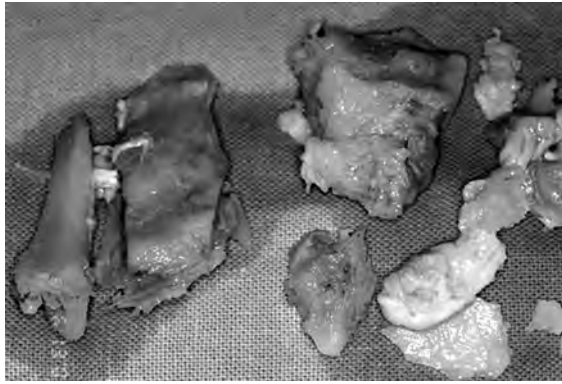

Fig. 4. Bone fragments removed from site of ankylosis in 6 years old girl with osseous ankylosis of TMJ

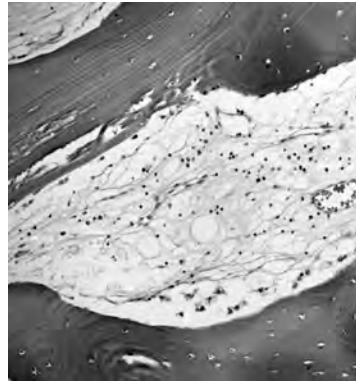


Fig. 5. Note massive connective tissue fragments around the bone speculae in 12 years old girl with recurrence of TMJ ankylosis $\times 240$

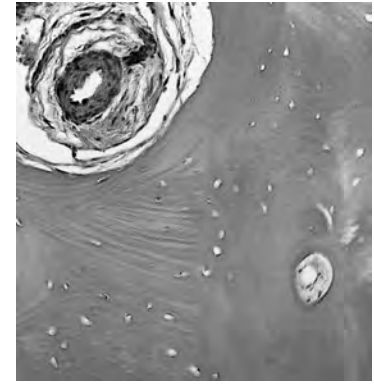


Fig. 6. Sclerotic artery in the connective tissue near the ankylotic bone of TMJ in 6 years old boy. Haematoxylin and eosin, $\times 240$.

performed IMH by using of standard Dako EnVision and RD Systems kits. IHC labelling was achieved using the standard streptavidin and biotin method [12, 13]. To evaluate IHC reaction, semiquantitative method was used. Scale was as following: "0" – no positive structures found in visual field, "0/+" – occasional positive structures seen in visual field, "+" – few immunoreactive structures seen in visual field, "++" – moderate number of immunoreactive structures seen in visual field, "+++" – numerous immunoreactive structures seen in visual field, and "++++" – abundance of immunoreactive structures seen in visual field. For apoptosis detection, terminal deoxynucleotidyl transferase-mediated deoxyuridine triphosphate nick end-labelling (TUNEL) using in situ cell death detection kit (Roche Applied Science, Penzberg, Germany) was performed [14].

RESULTS

Expression of different factors was similar in bone obtained from primary TMJ surgeries in both children – 6 years old girl and boy. Thus these data

are described together in Table 1. Separately Table shows also semiquantitative evaluation of relative appearance in different factors of bone from girl who underwent the repeated surgery in age of 12 years on TMJ.

Routine review pictures demonstrated massive compact bone formation mixed by neocondrogenesis in resected bone fragments of children from both cases – primary and secondary surgery. Bone showed mainly osteocytes and a narrow proliferation zone was detected only fragmentally. Prominent connective tissue ingrowths with sclerotic blood vessels separated bone fragments in ankylotic tissue of all primary and repeatedly operated cases (Fig. 5-6).

TGF β was richly secreted by osteocytes in bone obtained from all cases of primary surgery (Fig. 7) and also in bone of girl who underwent the repeated surgery in 5 years due to the disease recurrence (Fig. 8).

BMP2/4 was absent at all, but osteopontin – abundant in supportive tissue cells of primarily and repeatedly operated patient.

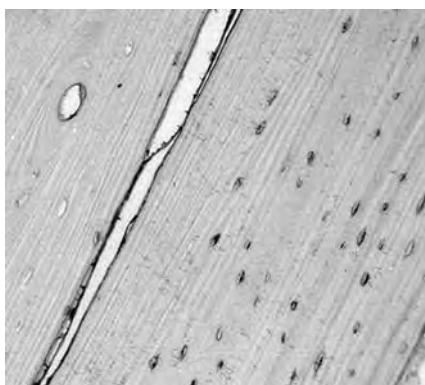


Fig. 7. Bone shows numerous TGF β -containing osteocytes in 6 years old child before TMJ reconstruction. TGF β IMH, $\times 240$.

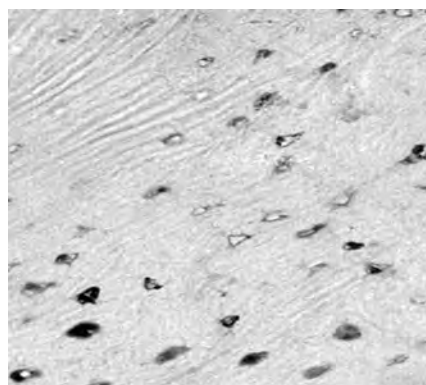


Fig. 8. Numerous positive for TGF β bone cells in TMJ region of 12 years old girl with ankylosis recurrence. TGF β IMH, $\times 400$.




Fig. 9. Patchy distribution of osteocalcin positive osteocytes in ankylotic bone of 6 year old child. Osteocalcin IMH, $\times 240$.

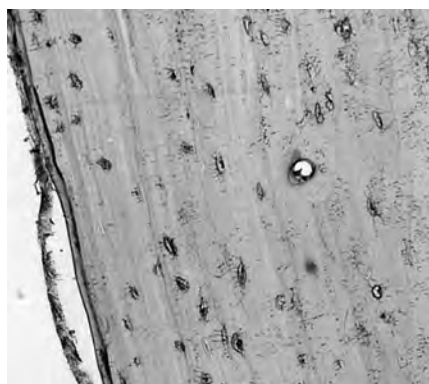


Fig. 10. Numerous osteocalcin immunoreactive cells in ankylotic bone of 12 years old girl 5 years after first bone/cartilage reconstruction surgery. Osteocalcin IMH, ×240.

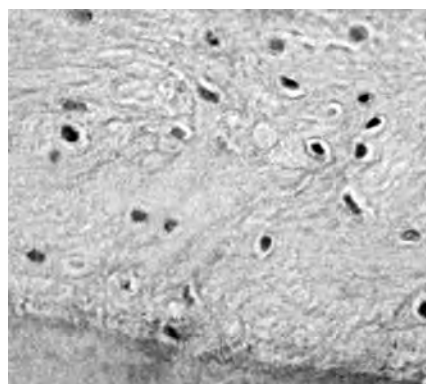


Fig. 11. Bone regions with moderate number of Msx2-containing cells in TMJ of 6 years old child. Msx2 IMH, ×240.

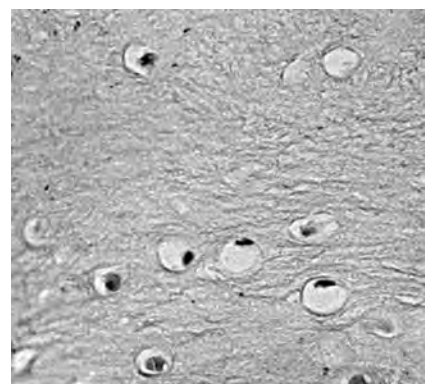


Fig. 12. Few Msx2 positive cells in neochondrogenesis region of 6 year old child with ankylotic TMJ. Msx2 IMH, ×240.

Osteocalcin demonstrated variable appearance of positive cells that often was of focal character in TMJ of primarily resected bone cases (Fig. 9). However, more intensive patchy expression of osteocalcin-containing cells was seen in the TMJ bone of 12 years old child with recurrence of disease (Fig. 10).

Inhomogeneous Msx2 distribution affected mainly ankylotic bone and cartilage before the TMJ reconstruction (Figs. 11, 12), but expression of this gene decreases until the few positive cells in the visual field in case of disease recurrence (Fig. 13).

There were few apoptotic cells observed in ankylotic bone obtained from primary surgeries (Fig. 14). However, apoptosis massively affected the bone after autotransplantation (Fig. 15).

DISCUSSION

We found various (from indistinct up to the abundant) Msx2-containing cells distribution in ankylotic bone that was slightly stabilized until few positive cells in case of disease recurrence in 5

years. Also group from Japan discovered connection between the Msx2 gene and ankylotic diseases (ankylotic spondylitis) in population [15]. Msx2 is one of the strongest facial bone inducer and mainly influences mesenchymal cells. The last ones differentiate into chondrogenic, osteogenic, and fibrogenic cells. Interestingly, that Msx2 expression differs in different sites of calvarium and is more intensive in perichondrium of skull basis [16]. Taking in account the presence of mixed regions of chondrogenesis and osteogenesis in ankylotic bone of our patients and the described fact that both – hereditary and also mechanical modulations (changed hydrostatic pressure, for example), of growth and development share a common pathway via genes [17] we speculate on the strong persistent Msx2 growth stimulating role in ankylosis. In such a way Msx2 should be added to those genes that are described to be involved in the pathogenesis of ankylotic supportive tissue forming. So, Indian hedgehog modulates embryonic mandibular condylar growth and its deficiency raises growth retardation and decreases cell proliferation [7]. Also importance of FGF, TGF β , sclerosin,



Fig. 13. Only few cells demonstrate Msx2 immunoreactivity in 12 years old girl TMJ affected by ankylosis recurrence. Msx2 IMH, ×240.

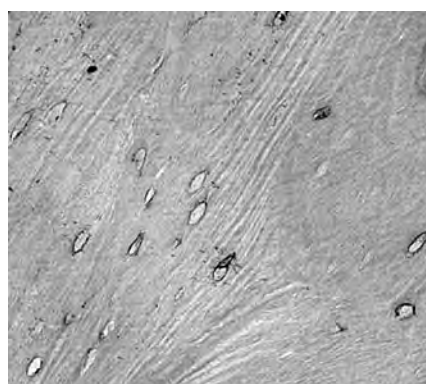


Fig. 14. Note occasional apoptotic cells in ankylotic bone of 6 years old child. TUNEL, ×240.

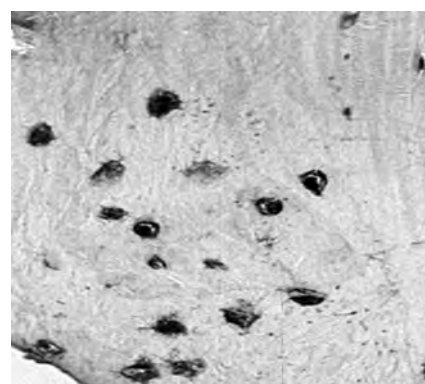


Fig. 15. Total apoptosis in ankylotic bone in TMJ region 5 years after reconstruction of 12 years old girl. TUNEL, ×400.

tuftelin coding genes is noted to play a role in mesenchymal cell proliferation and differentiation in condylar region [18].

Regeneration/growth of facial tissue depends also on growth factors such as BMP 2/4 and TGF β . BMP stimulates the repair of defects in facial supportive tissue like mandibular condyle postoperatively and of whole TMJ [19, 20]. We observed lack of BMP 2/4 despite unchanged rich TGF β expression in pre- and postautotransplantation developed ankylotic bone. BMP is known to stimulate differentiation of osteoblasts [21] and this process seemingly is affected in our patients as mainly ankylotic bone here demonstrated osteocytes. On other side, rich TGF β expression in ankylotic bone could show the earlier by other authors described function of this growth factor to stimulate mesenchymal cells proliferation and differentiation [18].

Additionally, the ankylotic bone of our patients more displays mineralization process due to the abundant increase of osteocalcin expression which is known to modulate bone metabolism [22] in mineralization aspect. This is proved also by rich osteopontin expression as it is known to raise appearance of spontaneous non-uniform mineralization regions in the bone of experimental animals in association of ank gene expression [23].

Apoptosis was seen in rare cells of ankylotic bone obtained during primary arthroplastical surgeries, while the recurrent ankylotic tissue demonstrated abundance of cells in programmed cell death condition. Apoptosis usually correlates to the distinct gene expression, for instance, to bcl-2 expression, and

this combination is explained as stimulated survey of proliferative and prehypertrophic chondrocytes [24]. In absence of regeneration-stimulating growth factors (BMP 2/4), when mainly unhomogenously mineralized bone develops, possibly the apoptosis mechanism is that what compensates the common massive inqualitative bone remodelling in TMJ and its region.

CONCLUSIONS

The lack of BMP2/4 expression in ankylotic bone proves the disorders in cellular (more likely osteoblasts) differentiation with simultaneous compensatory intensification of cellular proliferation and/or growth by rich expression of TGF β leading to the remodelling of TMJ.

Mainly rich distribution of osteocalcin and osteopontin indicate the intensive mineralization processes of ankylotic bone.

Persistent Msx2 expression is characteristic for the supportive tissue of recurrent ankylosis of TMJ and indicates the persistent stimulation of bone growth compensatory limited by massive increase of programmed cell death.

ACKNOWLEDGEMENTS

This work has been partly supported by the European Social Fund within the project "Multidisciplinary Research in Biomaterials Technology of New Scientist Group", No.2009/0199/1DP/1.1.1.2.0/09/APIA/VIAA/090.

REFERENCES

1. Das UM, Keerthi R, Ashwin DP, VenkataSubramanian R, Reddy D, Shiggaon N. Ankylosis of temporomandibular joint in children. *J Indian Soc Pedod Prev Dent* 2009;27:116-20.
2. de Andrade LH, Cavalcante MA, Raymundo R Jr, de Souza IP. Temporomandibular joint ankylosis in children. *J Dent Child (Chic)* 2009;76:41-5.
3. Gundlach KK. Ankylosis of the temporomandibular joint. *J Craniomaxillofac Surg* 2010;38:122-30.
4. Kim SM, Park JM, Kim JH, Kwon KJ, Park YW, Lee JH, et al. Temporomandibular joint ankylosis caused by chondroid hyperplasia from the callus of condylar neck fracture. *J Craniofac Surg* 2009;20:240-42.
5. Peltomäki T, Quevedo LA, Jeldes G, Rönning O. Histology of surgically removed overgrown osteochondral rib grafts. *J Craniomaxillofac Surg* 2002;30:355-60.
6. Kirsch T, Kim HJ, Winkles JA. Progressive ankylosis gene (ank) regulates osteoblast differentiation. *Cells Tissues Organs* 2009;189:158-62.
7. Ochiai T, Shibukawa Y, Nagayama M, Mundy C, Yasuda T, Okabe T, et al. Indian hedgehog roles in post-natal TMJ development and organization. *J Dent Res* 2010;89:349-54.
8. Gu S, Wei N, Yu L, Fei J, Chen Y. Shox2-deficiency leads to dysplasia and ankylosis of the temporomandibular joint in mice. *Mech Dev* 2008;125:729-42.
9. Elder BD, Athanasiou KA. Synergistic and additive effects of hydrostatic pressure and growth factors on tissue formation. *PLoS One* 2008;3:e2341.
10. Loreto C, Almeida LE, Trevilatto P, Leonardi R. Apoptosis in displaced temporomandibular joint disc with and without reduction: an immunohistochemical study. *J Oral Pathol Med* 2011;40:103-110.
11. Hirota Y, Habu M, Tominaga K, Sukedai M, Matsukawa A, Nishihara T, Fukuda J. Relationship between TNF- α positive chondrocytes in antigen-induced arthritis of the rabbit temporomandibular joint. *J Oral Pathol Med* 2006; 35:91-98.
12. Guesdon JL, Ternynck T, Avrameas S. The use of avidin-biotin interaction in immunoenzymatic techniques. *J Histochem Cytochem* 1979;27:1131-39.
13. Hsu SM, Raine L, Fanger H. The use of antiavidin antibody and avidin-biotin peroxidase complex in immunoperoxidase technics. *Am J Clin Pathol* 1981;75:816-21.
14. Gavrieli Y, Sherman Y, Ben-Sasson SA. Identification of programmed cell death *in situ* via specific label of nuclear DNA fragmentation. *J Cell Biol* 1992;119:493-01.
15. Furuichi T, Maeda K, Chou CT, Liu YF, Liu TC, Miyamoto J, et al. Association of MSX2 gene polymorphism with ankylosing spondylitis in Japanese. *J Hum Genet* 2008; 53:419-424.

16. Nie X. Developmentally regulated expression of MSX1, MSX2 and Fgfs in the developing mouse cranial base. *Angle Orthod* 2006;76:990-995.
17. Mao JJ, Nah HD. Growth and development: hereditary and mechanical modulations. *Am J Orthod Dentofacial Orthop* 2004;125:676-89.
18. Hinton RJ, Serrano M, So S. Differential gene expression in the perichondrium and cartilage of the neonatal mouse temporomandibular joint. *Orthod Craniofac Res* 2009;12:168-77.
19. Suzuki T, Bessho K, Fujimura K, Okubo Y, Segami N, Iizuka T. Regeneration of defects in the articular cartilage in rabbit temporomandibular joints by bone morphogenetic protein-2. *Br J Oral Maxillofac Surg* 2002;40:201-06.
20. Suzuki T, Bessho K, Segami N, Nojima T, Iizuka T. Bone morphogenetic protein-2 in temporomandibular joints with internal derangement. *Oral Surg Oral Med Oral Pathol Oral Radiol Endod* 1999;88:670-73.
21. Singhatanadgit W, Salih V, Olsen I. Bone morphogenetic protein receptors and bone morphogenetic protein signaling are controlled by tumor necrosis factor-alpha in human bone cells. *Int J Biochem Cell Biol* 2006;38:1794-807.
22. Mitra D, Elvins DM, Collins AJ. Biochemical markers of bone metabolism in mild ankylosing spondylitis and their relationship with bone mineral density and vertebral fractures. *J Rheumatol* 1999;26:2201-04.
23. Johnson K, Goding J, Van Etten D, Sali A, Hu SI, Farley D, et al. Linked deficiencies in extracellular PP9i) and osteopontin mediate pathologic calcification associated with defective PC-1 and ANK expression. *J Bone Miner Res* 2003;18:994-1004.
24. Li S, Jin Y, Wang H, Li Y. Role of apoptosis and bcl-2 gene in the temporomandibular joint development. *Hua Xi Kou Qiang Yi Xue Za Zhi* 1999;17:205-07.

Received: 21 10 2010

Accepted for publishing: 23 09 2011