

# We are IntechOpen, the world's leading publisher of Open Access books Built by scientists, for scientists

5,800

Open access books available

142,000

International authors and editors

180M

Downloads

Our authors are among the

154

Countries delivered to

TOP 1%

most cited scientists

12.2%

Contributors from top 500 universities



WEB OF SCIENCE™

Selection of our books indexed in the Book Citation Index  
in Web of Science™ Core Collection (BKCI)

Interested in publishing with us?  
Contact [book.department@intechopen.com](mailto:book.department@intechopen.com)

Numbers displayed above are based on latest data collected.  
For more information visit [www.intechopen.com](http://www.intechopen.com)



# Complications Associated with Aortic Aneurysm Repair

*Zachary Chadnick and Kuldeep Singh*

## Abstract

Aortic aneurysm repair is a common procedure and may be performed in an open or endovascular fashion, It is important to be aware that there exist many potential hazards associated with aortic aneurysm repair. The fact that this entity can be treated in an open or in an endovascular fashion increases the complexity of the problems that may arise. To begin there exists the inherent risks associated with any surgical procedures in the high-risk patient including bleeding, infection, cardiovascular and respiratory issues that may arise. Complications can also occur in the acute or delayed setting and can present several months or even years after repair. Aneurysms may form in the abdominal or thoracic aorta and each segment has its own unique set of issues that may present after repair. Experience and knowledge of associated problems is imperative for early recognition and best outcomes.

**Keywords:** aortic, aneurysm, repair, Complications, endoleak, migration, rupture, ischemia, thoracic, abdominal

## 1. Introduction

Aortic aneurysm treatment can be divided into open and endovascular repair, each with their own benefits and disadvantages [1–3]. The technique is chosen based on the patient's age, anatomy, and comorbidities. Numerous graft and graft materials exist as well. Associated complications vary based on the chosen technique [3–5]. In this chapter we will discuss both acute and delayed complications of open and endovascular repair of thoracic aortic aneurysms (TAA) and abdominal aortic aneurysms (AAA). Factors associated with increased complications and poor outcomes are advanced age, more severe disease, need for emergent intervention with a ruptured aneurysm, and presence of associated comorbidities such as cardiovascular disease (CVD), chronic obstructive pulmonary disease (COPD) and diabetes mellitus (DM) [6–8].

Aneurysms of the various portions of the aorta often have their own unique etiology and pathogenesis and therefore may require different interventions and thus have their own unique complications. Various classification systems exist for thoracoabdominal aneurysms but the Crawford classification is most commonly used (**Table 1**) [9]. AAAs are typically classified based on the proximity or involvement of the renal arteries. Anatomic knowledge and knowledge of the classification systems is important when discussing repair or issues associated with the repair.

Type I	Distal to the left subclavian artery and extending to include the origin of the celiac axis and possibly SMA Possible renal involvement, but does not extend below the renal arteries
Type II	May or may not include part if not all of the ascending aorta Contains descending aorta distal to the left subclavian and extends to the infrarenal aorta, possibly to the aortic bifurcation
Type III	Distal half of the descending thoracic aorta (6th intercostal space) into the aortic bifurcation
Type IV	Entire abdominal aorta from the diaphragm to the aortic bifurcation
Type V	Distal half of the descending aorta (6th intercostal space) and extending to the visceral segment but avoiding the renal arteries

**Table 1.**  
*Crawford classification of thoracoabdominal aortic aneurysms.*

## 2. Nonspecific complications

There are several complications of aortic aneurysm repair that are non-procedure specific. Given the common comorbidities associated vascular disease many patients, are at risk for cardiovascular events including, stroke, myocardial infarction (MI), and thromboembolic events [6, 7, 10, 11]. Patients with a AAA are considered to have the equivalent of coronary artery disease (CAD) [12]. Many risks can be mitigated in elective repair by undergoing the appropriate preoperative risk stratification and medical optimization. Patients will benefit from evaluation for concomitant CAD, carotid disease, renal function - especially if the renal arteries are involved [13]. Perioperative morbidity is often due cardiovascular, pulmonary, and ischemic events. CAD is the leading cause of both early and late mortality following AAA repair. COPD and renal insufficiency are also associated with increased perioperative morbidity and mortality [14–16].

Endovascular aneurysm repair (EVAR) is associated with overall lower complication rates compared to open surgery. Systemic and non-specific complications include cardiopulmonary, ischemic, and renal issues related to both IV contrast and embolic disease. In endovascular repair the risk of renal disease ranges from 3 to 12% while cardiovascular complications range from 1.8–5.3% [2, 17–19]. In several studies there are similar risk factors for cardiovascular complications in open repair and no significant differences were seen with respect long-term cardiovascular mortality between EVAR and open repair [20].

The incidence of pulmonary complications ranges from 2.9–3.3% with EVAR, and are thought to be higher with open repair. The need for postoperative mechanical ventilation is as low as 3.0% [12, 17], and the procedure can be done without the need for intubation and general anesthesia depending on anatomy. Many patients undergoing open repair can be extubated immediately after the procedure. Rates of pulmonary complications are associated with advanced age and pulmonary comorbidities at baseline [16, 21].

### 2.1 Prophylaxis

Patient undergoing both endovascular and open AAA repair are considered to be at moderate to high risk for thromboembolic events therefore use of chemical or mechanical deep vein thrombosis (DVT) prophylaxis is recommended. Incidence of DVT occurs in 1–10% [11] and due to comorbidities, most patients undergoing aortic surgery are at increased risk. Pharmacologic prophylaxis can be omitted in patients who have a ruptured aneurysm as the risk of bleeding is outweighed by

the risk of developing a DVT. Of note the use of intraoperative heparin should not be confused with appropriate pharmacological DVT prophylaxis. This due to the late administration as it is often only given after vessel clamping, especially in open surgery [11, 14, 22].

Antibiotic prophylaxis is also recommended to decrease rate of graft infection in both open and endovascular surgery. Bowel preparation is not routinely recommended as its associated with poor outcomes secondary to dehydration. Due to the potential high volume of contrast use, nephropathy can be mitigated by several strategies such as minimizing contrast use and pre-hydration [12, 23]. Renal artery stenting can be used especially in the setting of renal artery stenosis with preexisting renal insufficiency if planning to use a device with suprarenal fixation, although utility is not well-established routine use is surgeon and patient specific [23–25]. Ureteral stenting can be considered in patients undergoing open repair with a suspected hostile abdomen although routine use is not recommended [23]. Lastly hypogastric embolization may be needed to prevent a type II endoleaks or to gain adequate seal zone. With the advent of branched devices use of hypogastric coiling is now decreasing and limited to specific circumstances [25, 26].

## 2.2 Ischemia

Ischemic complications are frequent and, in some studies, occur at a higher rate in endovascular compared to open surgery, this is thought to be driven by endograft limb occlusion [27]. Lower extremity ischemia is the most common complication and may be due to thrombosis, embolism, dissection or obstruction secondary to malposition [2, 27–30]. This occurs in up to 7% of the patients and occurs within months of repair. Occlusion typically manifests as acute limb ischemia but may present as rest pain, intermittent claudication or decreased femoral pulses. Treatment often requires open femoral crossover graft placement as endovascular technique may not be effective [28, 29, 31].

Intestinal ischemia following EVAR can affect both the small and large bowel although colonic ischemia is more common and thought to be due to endograft coverage of the IMA. Rates are similar with respect to open repair ranging from 1 to 3%. Ischemia in the setting of the SMA is rare and thought to be secondary to embolism due to wire manipulation in the suprarenal aorta [30]. A higher rate of colonic ischemia is associated with ruptured aneurysm, long operative duration, presence of a large IMA occluded during repair and preoperative hypogastric artery embolization [30, 32].

Pelvic ischemia can often occur due to hypogastric artery embolization done either for pre-op planning or incidentally. When patients have difficult anatomy or iliac artery aneurysmal disease the artery is prophylactically embolized. Due to the presence of iliac branch devices utility is now limited. However atheroembolic and thromboembolic phenomena can still occur with attempts to preserve hypogastriacs. Symptoms include buttock claudication and erectile dysfunction in up to 40% of patients [33].

Renal ischemia can be due to embolism, thrombosis, dissection or impingement of the origin by the endograft. Incidence ranges from 0.7–18% [34–36]. AKI develops at an average rate of 6.7% which is significantly lower than that for open repair. Inadvertent coverage of the renals by the graft is associated with a short neck, salvage can be attempted by shifting the graft inferiorly, stenting the occluded renals and via surgical bypass. It is unclear whether suprarenal fixation is associated with deterioration in renal function [35].

### **3. The abdominal aorta**

The abdominal aorta is the most common site of arterial aneurysm and is defined by an increase in 50% above the normal size. The abdominal aorta is a retroperitoneal structure beginning at the diaphragmatic hiatus extending to the aortic bifurcation at the level of fourth lumbar vertebrae where it branches into the iliac vessels. It lies slightly to the left of the midline to make room for the superior vena cava (SVC). Its branches from cranial to caudal are: the left and right inferior phrenic arteries, left, right and middle suprarenal arteries, the celiac axis, the superior mesenteric artery (SMA), the left and right renal arteries, possible accessory renal arteries, the left and right gonadal arteries, and finally the inferior mesenteric artery (IMA). The middle sacral and paired lumbar arteries are present as well.

EVAR is one of the most important advancements in vascular surgeries recent history. Using minimally invasive endovascular procedures folded graft components are delivered into a vessel lumen via an access vessel and a sheath. The graft is deployed leading to expansion of the endograft, the graft makes contact with the vessel walls sealing and excluding the aneurysm sac from blood flow and pressure. The endovascular technique has a significant reduction in perioperative morbidity and mortality due to avoidance of aortic exposure and cross-clamping [37, 38]. Although with endovascular repair is associated with high technical success and lower associated complications compared to open repair, the dynamicity of the graft leads to increased rate of late complications. These are related to a technical aspect of the endograft placement such as problems with access, stability or integrity of the endograft the majority of the time.

AAAs are described as infrarenal, juxta/pararenal, or suprarenal renal depending on the involvement of the visceral and renal vessels, with origins below, at or above the levels of the renals respectively. They most often occur between the renal and inferior mesenteric arteries with only 5% involving the renal or visceral arteries. Up to 40% involve the iliac arteries. Infrarenal aneurysms with or without iliac involvement can be treated easily using standard endovascular techniques however visceral involvement will often require more complex endovascular repair with fenestrated, branched or physician modified devices, or open repair [39, 40].

#### **3.1 Endovascular abdominal complications**

Anatomic suitability is the primary determining factor for successful long term endovascular repair. Aortic neck diameter, length, and angulation, taper and infrarenal length are all important measurements to determine feasibility of endovascular repair. In addition to these standard measurements, aberrant anatomy such as renal artery anomalies, horseshoe kidney, iliac artery diameter, distance from bifurcation and sac diameter are all parameters that must be taken into account when planning a successful endovascular repair. With continuing advancements in endograft design their utility and range of use continue to grow. Studies have shown that poor compliance with device specific recommendations are associated with high aneurysm enlargement [41].

The overall complication rate for EVAR is approximately 10% but can range up to 30% in some studies [4, 5, 17]. Endograft complications rarely require conversion to open surgery. Whether complications occur during the initial surgery or are delayed they can usually be managed endovascularly if they require any intervention at all. The main reason for reintervention is typically device related complications. The overall incidence of conversion to open surgery is approximately 2% [42]. Higher complication and conversion rates are associated with larger aneurysm diameter [43].

Vascular access is most commonly obtained percutaneously via the bilateral femoral arteries but can be obtained via femoral cutdown. Open access can be more challenging in obese patients or with prior groin surgery but it may be preferred in patients with severe femoral disease [44, 45]. Prior to device deployment anticoagulation is initiated via weight-based dose heparin to prevent thrombosis and embolic complications, this may be reversed at the surgeon's discretion at the end of surgery if it is deemed the patient is high bleeding risk. Although routinely done, routine use is not associated with improved outcomes [11, 22].

The most common technical complications include injury to the iliac and femoral vessels vascular injury during access, device deployment or closure. Endoleaks are another common complication and occur when there is persistent flow into the aneurysm sac leading to expansion. Some endograft complications are device specific and will not be discussed here [44, 46].

Contrast related complications such as allergy and nephropathy are unique to endovascular repair and occur at a rate from 0.7–2%. Contrast induced nephropathy is thought to be caused by agent induced renal ischemia causing acute tubule necrosis. Moreover, the long-term use of contrast for surveillance has been associated with decreased renal function in some studies [47–50]. This can be mitigated with dilute use, use of CO<sub>2</sub> angiography and use of intravascular ultrasound for surveillance [24, 36, 51].

Graft deployment occurs after the endograft is precisely placed at the target location, Prior to deployment the blood pressure is typically lowered with a mean below 60 to prevent premature deployment and distal migration, this is referred to as the wind-sock effect. Once deployed the graft is planned at the proximal and distal landing zones as well as at the graft junctions. Evaluation for an Endoleak immediately follows using repeat arteriography. Endoleaks of the thoracic aorta occur at a rate of around 3.9%, lower than the associated rates at 15.3% with abdominal aortic repair [1, 52].

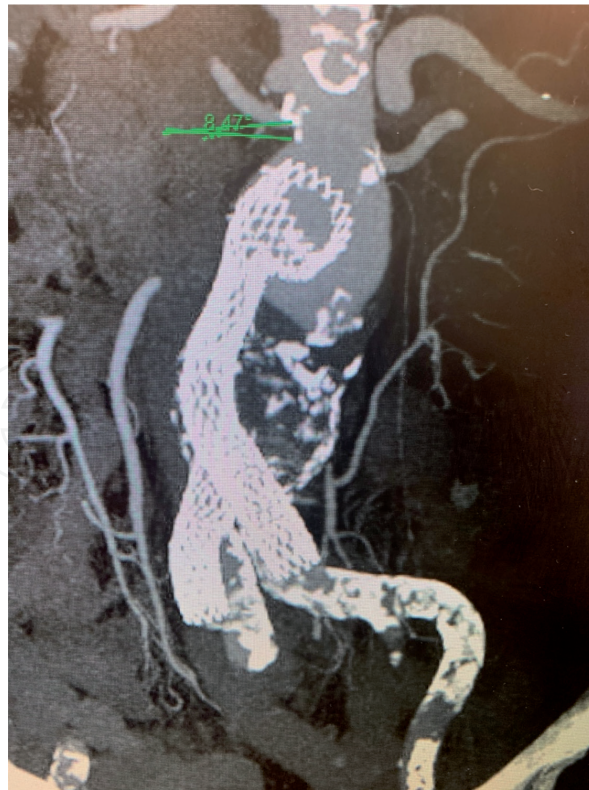
### 3.2 Endoleaks

An endoleak is defined as the presence of persistent blood flow into the aneurysm sac after graft placement and is one of the most common complications associated with endovascular aneurysm repair. Entire chapters and textbooks have been dedicated to the various types of endoleaks and their management so this will only be a brief overview. Endoleaks occur from inadequate fixation or sealing of the graft, breakdown of graft material, component separations, stent fractures and endograft collapse [52]. There are five types of endoleaks overall.

Type I endoleaks occur when there is an incompetent seal at the proximal (IA) or distal (IB) attachment site (**Figure 1**). Rates can be decreased by strict adherence to the on label instructions for use of the device. Type 1 endoleaks must be repaired if identified and are associated with persistence aneurysm growth. These can be repaired with additional ballooning or the placement of additional endograft components.

Type II endoleaks result from flow into the aneurysm sac from one or more patent branch vessel such as a lumbar vessel or the IMA. Preemptive measures such as embolization can be used and are often effective, however routine use is often not justified or recommended. This is because many type II endoleaks do not require treatment and remain asymptomatic with no effect on disease progression. Embolization, glue insertion, and use of branched devices have all been used with variable success.

Type III endoleaks result from the dissociation of the graft components or graft fracture. Certain grafts are associated with higher incidence of type III endoleaks



**Figure 1.**  
*Type 1 endoleak caused by slipped graft with no fixation.*

and thus these can be prevented through judicious device selection. Type IV endoleaks occur due to graft porosity. Like type 1 endoleaks, both type III and IV endoleaks can be repaired with ballooning, additional graft component placement and relining. Both type I and type III endoleaks require urgent intervention while type II and IV endoleaks typically do not require intervention at the time of the initial surgery.

Type V endoleaks are undefined and occur when the aneurysm continues to grow without any demonstrable endoleaks on all imaging modalities. It is referred to as endotension and has no well-defined or established treatment. Routine surveillance using computed tomography (CT) scan, ultrasound (US) and magnetic resonance imaging (MRI) have all been described and various time intervals depending on disease severity. The most common protocols utilize CT angiogram (CTA) at 1, 6, and 12 months with annual follow up thereafter [3, 12, 14].

### **3.3 Access site and other early complications**

Immediate problems are common but unpredictable and are typically correctable at the time of surgery if recognized early. The most common problems are related to insertion of the delivery system in up to 7.7% of cases [53]. Arterial rupture and dissection occurred at 0.7% and 0.9% rate respectively. Problems related to deployment and retrieval each occur at a rate of 0.4%. Accidental coverage of the visceral vessels occurs at a rate of 0.8%, atheroembolism occurs in 0.5% of patients. Lower limb ischemia is due to graft limb kinks and limb occlusion in 0.7 and 0.9% respectively. Lastly the hypogastric artery exclusion is required in 2.7% of patients.

Access site problems during EVAR are among the most common complications at a rate of 9–16% [53–55], these include, hematoma, thrombosis of the access vessel, distal embolization, dissection, pseudoaneurysm and formation of an arteriovenous fistula. Due to the unique pathophysiology and varying severity of these complications they are all managed in their own unique ways. Percutaneous

access prevents the need for femoral cut down and thus increases the rate of wound infection. With the advent of new devices and delivery systems there are reduced complication rates compared to the original devices and are now as low as 4.4%.

### **3.4 Late complications**

Although graft thrombosis can occur in the early post-operative period the endograft is a dynamic entity and may respond as such. Late endograft complications occur in up to 30% of cases leading to angulation, kink, migration and thrombosis of the endograft [56, 57]. Larger neck diameter is also associated with adverse events. Migration of the endograft can be identified on abdominal plain films and should be further evaluated with CT [58].

Device migration is one of the most common causes of secondary intervention after EVAR and is due proximal neck dilation either secondary to continued degeneration or oversizing [43, 59]. Another late complication is component separation and is due to the modular design of the endografts. Although the prevalence has decreased with the newer endografts, it can still occur due to inadequate overlap and poor graft integrity. Shrinking of the aneurysm sack can also lead to changes in the forces pulling at the limbs causing movement, decreasing the overlapping length and eventually separation (type III endoleak).

Limb Kinking and occlusion are more common in endovascular repair at a rate of 2.3% vs. 0.2% of open cases. Some studies have shown rates as high as 3.7% and an association with endoleaks, graft thrombosis, migration and need for conversion to open repair. Diagnosis can be made on duplex US, CT or MRI. Symptomatic patients can be treated with additional endovascular approaches and stenting and if the limb remains patent but if occluded open repair and bypass may be required [43].

### **3.5 Post implantation syndrome**

Post implantation syndrome typically occurs in the early post-operative period and is thought to be due to endothelial activation. It occurs between 13 and 60% of patients. This occurs secondarily to the placement of the prosthetic graft and typically presents with fever, leukocytosis and a generalized inflammatory response with elevated mediators such as C-reactive protein, IL-6 and TNF-alpha. With placement of thoracic grafts pleural effusions are common as well, the POMEVAR trial assessed whether preoperative steroids improved outcomes [48]. The trial showed that inflammatory markers were lower in the steroid group, and postoperative narcotics requirements were lower as well. No differences were appreciated in perioperative morbidity however patients fulfilled discharge criteria one full day sooner. No long-term data exists nor does any optimal dosing strategy.

### **3.6 Conversion**

Open AAA have their own associated risks and complications in both the elective and emergent setting. Unplanned conversion from endovascular failure also has its own associated risk factors and is associated with worse outcomes than a planned open procedure. This is thought to be due to the fact that patients may not have been a candidate for open procedure. Due to the known need for conversion to open, when patients are being prepared for endovascular procedures preoperative risk stratification for open surgery is still often recommended [42, 48].

Although many differences exist when comparing open and endovascular surgery the principal distinction results from the need for aortic cross-clamping in open surgery. Depending on the extent of the disease suprarenal and supraceliac



control is often needed for at least a short period of time leading to further organ ischemia and hemodynamic shifts. The perioperative morbidity and mortality is increased in conversion from open to endovascular repair in both the elective and emergent setting ranging from 10 to 13% [48–50]. Conversion surgery is associated with higher risk than open surgery [48] however mortality rates are comparable and lower in some studies. Late conversion is associated with worse outcomes than early conversion [60].

### **3.7 Open abdominal complications**

Although endovascular approaches are gaining popularity for the majority of AAAs, indications for open repair still exist and are mainly due to unfavorable anatomy for EVAR. Open repair is recommended for patients requiring intervention who do not meet the criteria for any endovascular device [19, 20]. Open repair is contraindicated in patients whose procedure risk is outweighed by risk of rupture. Of note, despite the higher perioperative morbidity and mortality associated with open repair, the long-term outcomes are similar when compared to endovascular repair [20].

Factors associated with higher complication rates in open repair are mainly due to medical comorbidities such as CAD, COPD, cerebrovascular disease, and renal dysfunction with serum Cr >2.0, AAA diameter > 6.5 cm, suprarenal cross clamping, advanced age, and female sex. Patients should all receive appropriate preoperative screening and medical optimization including cardiovascular evaluation, Aortic imaging to assess extent of the disease and evaluation for horseshoe kidney or an inflammatory aneurysm which require special considerations for repair [14, 60]. Inflammatory aneurysms are characterized by perianeurysmal fibrosis and contrast enhancing and thickening of the aneurysm wall. An inflammatory component is present in approximately 3% of aneurysms [61–63]. Although these can be repaired endovascularly open repair is often preferred and a retroperitoneal approach is often recommended.

Access to the aorta can be obtained via the transperitoneal or retroperitoneal approach, the former can be further divided into a midline or transverse incision [64]. Although overall perioperative mortality is similar for both approaches [65–67], the retroperitoneal method is associated with lower rates of postoperative complications such as pneumonia, hernias, ileus, reduced blood loss, and shorter ICU length of stay. Retroperitoneal incisions are however associated with increased risk of wound complications including flank hernia and incisional pain. Ultimately incisional approach is based largely on patient factors, and surgeon experience/preference [66, 68].

Anastomotic aneurysms are another complication unique to open repair. They can be true aneurysms related to ongoing degeneration or false/pseudoaneurysms resulting from disruption of the suture line [69]. Suture line disruption can be due to technical error but has a strong association with infection. Both true and false aneurysms can occur proximally or distally and typically require redo surgery for repair. Relining is an alternative if it is feasible and no associated infection exists [70].

#### *3.7.1 Ischemia related to open repair*

As with endovascular repair complications include ischemia, and renal dysfunctions. Late complications include incisional hernia, anastomotic aneurysm, graft infection and aortoenteric fistula. Late complications occur in 9.5% of patients [71].

In open surgery extremity ischemia can occur due to clamp injury, wall dissection, thrombosis and distal thromboembolism [19, 21]. Minimizing dissection and clamping heavily diseased regions can minimize extremity ischemia. Pelvic ischemia can lead sexual dysfunction may be due to pelvic nerve dysfunction with autonomic nerve injury resulting in impotence [36].

Renal dysfunction can result from decreased blood flow during mobilization and clamping of the aorta or due to embolism of debris into the renal arteries. Incidence is high with suprarenal repair however infrarenal repair can still reduce renal blood flow and result in renal dysfunction. Renal failure is associated with higher 30-day mortality [25, 37]. The small and large intestine can be both affected in open repair. Acute mesenteric ischemia is rare with an infrarenal AAA. Colonic ischemia is increased with ruptured aneurysm however the incidence of ischemia depends on method used to detect the disease and many patients will not have significant symptoms.

### **3.8 Compartment syndrome**

Abdominal compartment syndrome results in organ dysfunction secondary to increased compartment pressures. This can occur following open or endovascular repair in patients who have a ruptured aneurysm. This is thought to be due to the increased volume resuscitation needed combined with the increased retroperitoneal volume in blood loss. Rates are as high in 10 of patients Following EVAR [72]. Management is with decompressive laparotomy with EVAR and reopening the incision and fascia if open repair was performed. If there was severe limb ischemia, reperfusion of the affected limbs could result in extremity compartment syndrome requiring prompt recognition and intervention with fasciotomy. The myonecrosis associated with compartment syndrome is treated with hydration, cardiac monitoring and supportive care.

### **3.9 Infection**

Infection is rare with some studies showing rates as low as 0.3% in all aneurysm surgeries. Infection rates range from 0.4 to 3% in EVAR and are associated with high mortality rates ranging up to 50% [73–77]. Aneurysm extension in the femoral region can increase the incidence up to 3%. Early presentation is thought to be due to seeding with skin flora or inadequate sterile technique while late presentations are associated with an aortoenteric fistula (AEF). AEFs are caused by erosion of the graft into the small bowel – most commonly the third portion of the duodenum. This is much more common with open repair [73]. Treatment typically requires removal of the infected graft with extraanatomical reconstruction to restore blood flow to the lower extremities. In-situ reconstruction can be also be used [75, 77].

Autogenous conduit such as femoral vein graft can be used and is reserved for use in the presence of gross infection [78, 79]. If the patient does not have an adequate donor vessel antibiotic impregnated grafts, cryopreserved arterial conduits and endovascular grafts have all been used with varying success. Conservative strategies exist with antibiotic therapies if the patient cannot tolerate open surgery. Bloodstream infection and postoperative surgical site infection are associated with aortic graft infection and occur at a mean of 3 years following the procedure [79]. Timely administration of prophylactic antibiotics and adherence to strict sterile technique all decreased the incidence of surgical site infections. PTFE grafts may be associated with increased infection resistance as opposed to polyester grafts.

## 4. The thoracic aorta

Thoracic aneurysms are much rarer than abdominal aneurysms and can involve one or more segments. Classification is based on the various anatomic structures involved including the root, ascending, arch and descending portions. Approximately 60% of thoracic aneurysms involved the root and ascending portion, 40% involve the descending and 10% involve the arch. Another 10% of aneurysms involve the thoracoabdominal aorta often involving more than one segment.

### 4.1 Endovascular thoracic aorta

Endovascular repair of the thoracic aorta (TEVAR) is a minimally invasive approach and has fewer complications and associated morbidities than open repair. Mortality rates range from 1.9–3.1% [3, 41, 44, 80], with overall morbidity rates being as low as 9% [42]. Despite being its initial use as a treatment for patients who were unable to tolerate an open procedure, it is now the preferred treatment options due to the improved risk profile in most patients with suitable anatomy. Indications for open vs. endovascular approaches are often unclear and many surgical societies place an emphasis on individualized approach taking many factors into account, furthermore many hybrid techniques exist with a combination of open and endovascular approaches [3, 6, 7, 17].

From an anatomical and endovascular standpoint, the thoracic aorta is divided into 4 landing zones (0–4) which determines the need for aortic debranching and endovascular coverage (**Table 2**). Endovascular repair avoids a sternotomy/thoracotomy, and the need to cross clamp the aorta. Lack of aortic cross clamping has a lower incidence of end organ ischemia. Endovascular surgery is associated with less respiratory dependency, and has significantly improved post-operative pain, furthermore endovascular surgery has Unless related to a genetically mediated disease, endovascular repair is preferred for most descending aortic aneurysms [81–83]. Like with the abdominal aorta TEVAR can require conversion to open repair in certain situations such as in the case of persistent endoleak and late rupture.

#### 4.1.1 Graft related complications

Various devices exist for thoracic aortic aneurysms. The degree of support varies from device to device and each is thought to have their own benefits and setbacks. Flexibility is associated with increased adaptability to aneurysm configuration overtime while some feel that fully supported endografts are more resistant to kinking and subsequent thrombosis. Furthermore, increased graft complexity is associated with more complications.

A notable risk with TEVAR is coverage of the left subclavian artery [84]. This is implemented in many patients without sequelae or complications however certain groups of patients may not tolerate coverage. Although routine revascularization

Zone 0	Proximal to the origin of the brachiocephalic artery
Zone 1	Distal to the brachiocephalic but proximal to the left Common carotid
Zone 2	Distal to the left common carotid but proximal to the left subclavian
Zone 3	Less than 2 cm from the left subclavian without coverage
Zone 4	More than 2 cm distal to the left subclavian but within the proximal half of the thoracic aorta

**Table 2.**  
*Thoracic aortic landing zones.*

is not necessary, patients with a dominant left vertebral system, hypoplastic right vertebral artery, patent left inferior mammary after CABG, functioning left upper extremity dialysis AV-fistula or an incomplete Circle of Willis are at high risk of symptoms including stroke and paraplegia. Any planned coverage in these patients should be preceded by left carotid to subclavian bypass or carotid transposition. Symptoms of subclavian coverage can include development of debilitating arm pain, acute hand ischemia and claudication symptoms. These can be treated with elective revascularization, however may resolve overtime without interventions as collateral circulation develops [85–87].

Depending on the extent of disease the carotid, renal and visceral vessels can all be covered as well. If the renal arteries or superior mesenteric artery are involved the use of a fenestrated or branched graft should be used if possible [40, 41, 53, 88]. If deemed impossible a hybrid procedure can be performed with debranching and reimplantation, or a bypass procedure to restore adequate blood flow. If there is adequate collateral circulation to the covered vessel as occurs with the celiac axis in most patients, no further intervention is required. If not required for circulation and collateral flow exists certain vessels may be prophylactically embolized to prevent an endoleak [89, 90].

#### *4.1.2 Non-graft related complications*

Endovascular procedures require delivery of a large bore sheath into the aorta with separate access for arteriography. This is typically performed via a femoral cut down or in a percutaneous fashion to avoid femoral cutdown. Access site complications associated with TEVAR result from passage of the sheath into the vessel and can result in iliac artery disruption. Rates of disruption are increased if the vessel is small-diameter, tortuous, or excessively calcified. Adjunctive procedures may be performed prior to sheath placement such as angioplasty and stenting to facilitate sheath placement and reduce complications. Other strategies to decrease access site complications are creation of an iliac conduit, directly expose the common iliac or aortic exposure with direct delivery of the graft through the abdominal aorta.

Due to risk of neurologic and vascular complications patients are transferred to a monitored unit postoperatively for routine neurovascular checks assessing for stroke, spinal cord and extremity ischemia. These are rare and in the absence of symptoms, patients are typically stable for discharge after 2–3 days [91–93].

Ischemia secondary to vessel coverage was discussed in detail in the AAA section however ischemia can also occur secondary to embolism during graft placement or from retrograde dissection. Dissection can occur in the immediate perioperative period or be delayed. Rates are as high as 2.5% and are associated with hypertension, vascular disease, presence of an acute dissection and use of bare metal stent [6, 85, 94].

## **4.2 Ischemic and neurologic complications**

The first complication that will be discussed related to thoracic aortic aneurysm repair is paresis and paraplegia. This can occur along any segment and its risk is related to the extent of aortic involvement. It has been estimated to occur at rates between 8% and 30%. The rates of spinal cord ischemia are comparable if not slightly lower with endovascular repair compared to open surgery and range from 3 to 11% [84, 93, 95–97]. Spinal cord ischemia occurs in the acute setting with a mean onset time of 10.6 hours following repair.

There are three major blood supplies to the spinal cord, the vertebral arteries in the neck, the anterior spinal artery and the two posterior spinal arteries that

anastomose distally at the conus medularis. The anterior spinal artery supplies the anterior two-thirds. The thoracic spinal cord especially dependent on radicular contributions to the anterior spinal artery, namely the Artery of Adamkiewicz between T9-T12. There are reserves with collateral circulation however as more of the arterial system is disturbed the higher the likelihood of injury. If able to limit the disruption to 8 or fewer segments then the risk of paresis and paraplegia are low. Crawford Type II aneurysms have the highest risk.

Certain spinal precautions can be implemented in both open and endovascular repair to decrease risks. Whether open or endovascular repair is performed, extent of coverage is the highest associated risk factor with paralysis [98, 99]. Hypotension, procedural duration, need for reimplantation and renal insufficiency are all associated risk factors [93, 96, 99]. Spinal ischemia is very rare with EVAR for AAA with an incidence of <0.21% [100] compared to has high as 12% for TEVAR repair. Risk of paraplegia can be mitigated with cerebrospinal fluid drainage using a lumbar drain [99]. Perioperative monitoring using spinal perfusion pressure is also recommended with an intrathecal pressure recommended to be  $\leq 10$  mmHg [101, 102]. Reimplantation of patient lower intercostal arteries, namely T8-T12 is also associated with decreased risk of neurologic deficits.

Ischemic complications from TEVAR can occur in the extremities, visceral organs and cerebrovascular system as well. Although less specific to the spinal cord, ischemia to the brain and emboli from plaque/thrombus disruption can lead to stroke and stroke-like symptoms, mesenteric ischemia, and ALI. Overall, 30-day stroke rates were once as high as 20% in patients requiring arch repair but have decreased significantly.

Due to the proximity of the seal zones to the carotid and vertebral artery there is risk of embolic stroke, these are associated with proximal graft deployment, presence of mobile atheroma in the arch and previous stroke. Rates range from 4 to 8% and are comparable with open surgery [103]. Silent embolization is also thought to commonly occur however the significance is not well understood at this time.

#### *4.2.1 Visceral ischemia*

Celiac axis coverage is controversial and although not typical, can result in visceral ischemia. Collateralization via in the pancreaticoduodenal arcade should allow blood flow via the SMA however this is not always the case. If the graft were to cover the SMA or renal arteries, revascularization would be necessary if a fenestrated or branched device was not used [90, 104].

### **4.3 Delayed complications**

CT Scan is used for surveillance and typically done at 1, 6, and 12 months post operatively with annual surveillance thereafter. Secondary intervention is fairly common [3, 17, 103, 105] and evidence of endoleaks typically require prompt intervention. Type II endoleaks in the setting of stable aneurysm sack size can be observed.

Late outcomes are usually related to the natural history of the disease and related to the graft itself, endoleaks have been discussed but the device can migrate, collapse or infold as well [1, 47]. Migration above 1 cm caudally can occur at a rate of 1–3% over a one-year period. This is increased with grafts that are oversized or associated with tortuous seal zone. In-folding and collapse primarily occur in younger patients and has a higher association with traumatic dissection and is related to severe proximal aortic angulation or oversizing. Symptoms are related to aortic occlusion and require prompt intervention. Overlapping and device separation has been reported as well, however all of these issues typically respond well

to endovascular techniques [106, 107]. The need for secondary intervention from various causes ranges from 3.6 to 24% [108–111].

A large case series with 1 year follow up looked at patients treated with endovascular stents for aneurysm, dissection and traumatic injury with fatal complications occurring in 4% of patients resulting from aneurysmal rupture, stent erosion into the esophagus, bleeding and arterial injury [112]. Late stent complications occurred in 38% of patients and presented with malposition, endoleaks, dissection, distal embolization, gut ischemia, and infection. Aortobronchial and aortopulmonary fistulas related to compression as a consequence of endoleaks are rare but potential lethal complications.

#### **4.4 Open thoracic complications**

Although endovascular procedures are gaining popularity for many thoracic pathologies, open surgery still remains the standard of care for various situations. Open surgery remains the standard of care for ascending aneurysms >5.5 cm, >4.5 cm with associated genetic anomalies (>4.2 cm with patients with Loeys-Dietz Syndrome), and rapid expansion. Patient selection must also be considered and may be an indication for open repair. As many open thoracic procedures require cardiopulmonary bypass and often use hypothermic circulatory arrest, the associated risks and complications all apply and will not be discussed in detail [3, 92]. In summary patients who do not meet the anatomic criteria to place an available endograft and require repair they must undergo an open procedure.

Bleeding requiring intervention occurs in 10% of patients requiring emergent repair and 3% of patients undergoing elective repair. Bleeding can lead to cardiac tamponade, shock, dilutional coagulopathy and have other associated transfusion related complications. It can also present in a delayed fashion with a hemothorax requiring further intervention. Prevention can include correction of all coagulation defects, obtaining strict hemostasis, use of antifibrinolytic and hemostatic agents. Bleeding can occur with TEVAR, EVAR and Open AAA repair however is most severe when associated with open thoracic repair [3, 113, 114].

Ischemic renal and neurologic complications are discussed above however emboli and ischemia can affect the extremities and visceral organs as well. Peripheral nerve injuries can result as a consequence of excessive traction, but often improve with conservative management and do not require any interventions [30, 35]. Distal arch surgery is associated with injury to the recurrent laryngeal nerve resulting in hoarseness and vocal cord paralysis, while injury to the phrenic nerve is associated with diaphragmatic paralysis and respiratory distress/failure [3].

Para-anastomotic pseudoaneurysm is a notable potential late complication of open thoracoabdominal repair, and often occurs in the setting of graft infection. It is often repaired with re-do open repair, however endovascular options exist for certain patients with appropriate anatomy and prohibitive risk to open surgery [69].

#### **4.5 The aortic valve**

The involvement of the aortic valve requires special consideration with repair and thus has its own specific set of associated complications. Furthermore, aortic stenosis and insufficiency may present as a late complication of ascending aortic or arch repair. This can also be associated with re-aneurysm formation, dissection and endocarditis of the valve. Furthermore, involvement of the aortic valve and root require coronary artery reimplantation. Valve-sparing aortic replacement is possible and recommended for patients with ascending disease who do not have significant root dilation [115–117].

## **5. Conclusion**

In conclusion many complications exist with respect to aortic aneurysm repair and exist among all types of repair and relate to the comorbidities associated with the disease such as myocardial infarction and stroke, while others related to graft placement and surgery as occurs with visceral ischemia. Endovascular and Open repair and the Abdominal and thoracic aorta each do have their own unique associated risks. Open procedures have high rates of infection and bleeding, while endovascular repair have higher associated risks of contrast related injuries and risk conversion to open surgery. The thoracic aorta has higher associated rates of spinal ischemia and paralysis.

### **Conflict of interest**

The authors declare no conflict of interest.

### **Author details**

Zachary Chadnick and Kuldeep Singh\*  
Staten Island University Hospital, New York, United States

\*Address all correspondence to: [ksingh7@northwell.edu](mailto:ksingh7@northwell.edu)

### **IntechOpen**

© 2021 The Author(s). Licensee IntechOpen. This chapter is distributed under the terms of the Creative Commons Attribution License (<http://creativecommons.org/licenses/by/3.0>), which permits unrestricted use, distribution, and reproduction in any medium, provided the original work is properly cited. 

## References

- [1] Bavaria JE, Appoo JJ, Makaroun MS, Verter J, Yu Z-F, Mitchell RS, et al. Endovascular stent grafting versus open surgical repair of descending thoracic aortic aneurysms in low-risk patients: a multicenter comparative trial. *J Thorac Cardiovasc Surg.* 2007 Feb;133(2):369-377.
- [2] Becquemin J-P, Pillet J-C, Lescalie F, Sapoval M, Goueffic Y, Lermusiaux P, et al. A randomized controlled trial of endovascular aneurysm repair versus open surgery for abdominal aortic aneurysms in low- to moderate-risk patients. *J Vasc Surg.* 2011 May;53(5):1167-1173.e1.
- [3] Hiratzka LF, Bakris GL, Beckman JA, Bersin RM, Carr VF, Casey DE, et al. 2010 ACCF/AHA/AATS/ACR/ASA/SCA/SCAI/SIR/STS/SVM guidelines for the diagnosis and management of patients with Thoracic Aortic Disease: a report of the American College of Cardiology Foundation/American Heart Association Task Force on Practice Guidelines, American Association for Thoracic Surgery, American College of Radiology, American Stroke Association, Society of Cardiovascular Anesthesiologists, Society for Cardiovascular Angiography and Interventions, Society of Interventional Radiology, Society of Thoracic Surgeons, and Society for Vascular Medicine. *Circulation.* 2010 Apr 6;121(13):e266-369.
- [4] Gabrielli L, Baudo A, Molinari A, Domanin M. Early complications in endovascular treatment of abdominal aortic aneurysm. *Acta Chir Belg.* 2004 Oct;104(5):519-526.
- [5] Brown LC, Greenhalgh RM, Powell JT, Thompson SG, EVAR Trial Participants. Use of baseline factors to predict complications and reinterventions after endovascular repair of abdominal aortic aneurysm. *Br J Surg.* 2010 Aug;97(8):1207-1217.
- [6] Coady MA, Rizzo JA, Hammond GL, Kopf GS, Elefteriades JA. Surgical intervention criteria for thoracic aortic aneurysms: a study of growth rates and complications. *Ann Thorac Surg.* 1999 Jun;67(6):1922-1926; discussion 1953-1958.
- [7] Chung J, Corriere MA, Veeraswamy RK, Kasirajan K, Milner R, Dodson TF, et al. Risk factors for late mortality after endovascular repair of the thoracic aorta. *J Vasc Surg.* 2010 Sep;52(3):549-554; discussion 555.
- [8] Feezor RJ, Martin TD, Hess PJ, Klodell CT, Beaver TM, Huber TS, et al. Risk factors for perioperative stroke during thoracic endovascular aortic repairs (TEVAR). *J Endovasc Ther.* 2007 Aug;14(4):568-573.
- [9] Vandy FC, Girotti M, Williams DM, Eliason JL, Dasika NL, Michael Deeb G, et al. Iliofemoral complications associated with thoracic endovascular aortic repair: frequency, risk factors, and early and late outcomes. *J Thorac Cardiovasc Surg.* 2014 Mar;147(3):960-965.
- [10] Crawford ES, Crawford JL, Safi HJ, Coselli JS, Hess KR, Brooks B, et al. Thoracoabdominal aortic aneurysms: preoperative and intraoperative factors determining immediate and long-term results of operations in 605 patients. *J Vasc Surg.* 1986 Mar;3(3):389-404.
- [11] de Maistre E, Terriat B, Lesne-Padieu A-S, Abello N, Bouchot O, Steinmetz EF. High incidence of venous thrombosis after surgery for abdominal aortic aneurysm. *J Vasc Surg.* 2009 Mar;49(3):596-601.
- [12] Hirsch AT, Haskal ZJ, Hertzner NR, Bakal CW, Creager MA, Halperin JL, et al. ACC/AHA 2005 Practice Guidelines for the management of patients with peripheral arterial disease (lower



extremity, renal, mesenteric, and abdominal aortic): a collaborative report from the American Association for Vascular Surgery/Society for Vascular Surgery, Society for Cardiovascular Angiography and Interventions, Society for Vascular Medicine and Biology, Society of Interventional Radiology, and the ACC/AHA Task Force on Practice Guidelines (Writing Committee to Develop Guidelines for the Management of Patients With Peripheral Arterial Disease): endorsed by the American Association of Cardiovascular and Pulmonary Rehabilitation; National Heart, Lung, and Blood Institute; Society for Vascular Nursing; TransAtlantic Inter-Society Consensus; and Vascular Disease Foundation. *Circulation*. 2006 Mar 21;113(11):e463-654.

[13] Dawson J, Vig S, Choke E, Blundell J, Horne G, Downham C, et al. Medical optimisation can reduce morbidity and mortality associated with elective aortic aneurysm repair. *Eur J Vasc Endovasc Surg*. 2007 Jan;33(1):100-104.

[14] Chaikof EL, Brewster DC, Dalman RL, Makaroun MS, Illig KA, Sicard GA, et al. The care of patients with an abdominal aortic aneurysm: the Society for Vascular Surgery practice guidelines. *J Vasc Surg*. 2009 Oct;50(4 Suppl):S2-49.

[15] Chaikof EL, Blankensteijn JD, Harris PL, White GH, Zarins CK, Bernhard VM, et al. Reporting standards for endovascular aortic aneurysm repair. *J Vasc Surg*. 2002 May;35(5):1048-1060.

[16] Moll FL, Powell JT, Fraedrich G, Verzini F, Haulon S, Waltham M, et al. Management of abdominal aortic aneurysms clinical practice guidelines of the European society for vascular surgery. *Eur J Vasc Endovasc Surg*. 2011 Jan;41 Suppl 1:S1-58.

[17] Prinssen M, Verhoeven ELG, Buth J, Cuypers PWM, van Sambeek MRHM,

Balm R, et al. A randomized trial comparing conventional and endovascular repair of abdominal aortic aneurysms. *N Engl J Med*. 2004 Oct 14;351(16):1607-1618.

[18] EVAR trial participants. Endovascular aneurysm repair versus open repair in patients with abdominal aortic aneurysm (EVAR trial 1): randomised controlled trial. *Lancet*. 2005 Jul 25;365(9478):2179-2186.

[19] Lederle FA, Freischlag JA, Kyriakides TC, Padberg FT, Matsumura JS, Kohler TR, et al. Outcomes following endovascular vs open repair of abdominal aortic aneurysm: a randomized trial. *JAMA*. 2009 Oct 14;302(14):1535-1542.

[20] Khan S, Lombardi JV, Carpenter JP, Trani J, Alexander JB, Caputo FJ. Open abdominal aortic aneurysm repair is still necessary in an era of advanced endovascular repair. *J Vasc Surg*. 2016 Aug;64(2):333-337.

[21] Fonseca R, Rockman C, Pitti A, Cayne N, Maldonado TS, Lamparello PJ, et al. Intermediate-term EVAR outcomes in octogenarians. *J Vasc Surg*. 2010 Sep;52(3):556-560; discussion 560-561.

[22] Gould MK, Garcia DA, Wren SM, Karanicolas PJ, Arcelus JI, Heit JA, et al. Prevention of VTE in nonorthopedic surgical patients: Antithrombotic Therapy and Prevention of Thrombosis, 9th ed: American College of Chest Physicians Evidence-Based Clinical Practice Guidelines. *Chest*. 2012 Feb;141(2 Suppl):e227S-e277S.

[23] Landry GJ, Lau IH, Liem TK, Mitchell EL, Moneta GL. Adjunctive renal artery revascularization during juxtarenal and suprarenal abdominal aortic aneurysm repairs. *Am J Surg*. 2010 May;199(5):641-645.

[24] Brown LC, Brown EA, Greenhalgh RM, Powell JT,

Thompson SG, UK EVAR Trial Participants. Renal function and abdominal aortic aneurysm (AAA): the impact of different management strategies on long-term renal function in the UK Endovascular Aneurysm Repair (EVAR) Trials. *Ann Surg*. 2010 May;251(5):966-975.

[25] Zettervall SL, Soden PA, Deery SE, Ultee K, Shean KE, Shuja F, et al. Comparison of Renal Complications between Endografts with Suprarenal and Infrarenal Fixation. *Eur J Vasc Endovasc Surg*. 2017 Jul;54(1):5-11.

[26] Kusaka J, Matsumoto S, Hagiwara S, Koga H, Noguchi T. Use of perioperative ureteral stent in abdominal aortic aneurysm with retroperitoneal fibrosis - A report of two cases. *Korean J Anesthesiol*. 2012 Jul;63(1):76-79.

[27] Casey K, Al-Khatib WK, Zhou W. Hypogastric artery preservation during aortoiliac aneurysm repair. *Ann Vasc Surg*. 2011 Jan;25(1):133.e1-8.

[28] Mehta M, Veith FJ, Ohki T, Cynamon J, Goldstein K, Suggs WD, et al. Unilateral and bilateral hypogastric artery interruption during aortoiliac aneurysm repair in 154 patients: a relatively innocuous procedure. *J Vasc Surg*. 2001 Feb;33(2 Suppl):S27-S32.

[29] Maldonado TS, Rockman CB, Riles E, Douglas D, Adelman MA, Jacobowitz GR, et al. Ischemic complications after endovascular abdominal aortic aneurysm repair. *J Vasc Surg*. 2004 Oct;40(4):703-709; discussion 709-710.

[30] Faure EM, Becquemin J-P, Cochenec F, ENGAGE collaborators. Predictive factors for limb occlusions after endovascular aneurysm repair. *J Vasc Surg*. 2015 May;61(5):1138-1145.e2.

[31] Taudorf M, Jensen LP, Vogt KC, Grønvald J, Schroeder TV, Lönn L. Endograft limb occlusion in EVAR: iliac

tortuosity quantified by three different indices on the basis of preoperative CTA. *Eur J Vasc Endovasc Surg*. 2014 Nov;48(5):527-533.

[32] Becquemin J-P, Majewski M, Fermani N, Marzelle J, Desgrandes P, Allaire E, et al. Colon ischemia following abdominal aortic aneurysm repair in the era of endovascular abdominal aortic repair. *J Vasc Surg*. 2008 Feb;47(2):258-263; discussion 263.

[33] Mantas GK, Antonopoulos CN, Sfyroeras GS, Moulakakis KG, Kakisis JD, Mylonas SN, et al. Factors Predisposing to Endograft Limb Occlusion after Endovascular Aortic Repair. *Eur J Vasc Endovasc Surg*. 2015 Jan;49(1):39-44.

[34] Perry RJT, Martin MJ, Eckert MJ, Sohn VY, Steele SR. Colonic ischemia complicating open vs endovascular abdominal aortic aneurysm repair. *J Vasc Surg*. 2008 Aug;48(2):272-277.

[35] Rayt HS, Bown MJ, Lambert KV, Fishwick NG, McCarthy MJ, London NJM, et al. Buttock claudication and erectile dysfunction after internal iliac artery embolization in patients prior to endovascular aortic aneurysm repair. *Cardiovasc Intervent Radiol*. 2008 Aug;31(4):728-734.

[36] Saratzis A, Melas N, Mahmood A, Sarafidis P. Incidence of Acute Kidney Injury (AKI) after Endovascular Abdominal Aortic Aneurysm Repair (EVAR) and Impact on Outcome. *Eur J Vasc Endovasc Surg*. 2015 May;49(5):534-540.

[37] Giles KA, Pomposelli F, Hamdan A, Wyers M, Jhaveri A, Schermerhorn ML. Decrease in total aneurysm-related deaths in the era of endovascular aneurysm repair. *J Vasc Surg*. 2009 Mar;49(3):543-550; discussion 550-551.

[38] Dillavou ED, Muluk SC, Makaroun MS. Improving

- aneurysm-related outcomes: nationwide benefits of endovascular repair. *J Vasc Surg.* 2006 Mar;43(3):446-451; discussion 451-452.
- [39] Greenberg RK, Sternbergh WC, Makaroun M, Ohki T, Chuter T, Bharadwaj P, et al. Intermediate results of a United States multicenter trial of fenestrated endograft repair for juxtarenal abdominal aortic aneurysms. *J Vasc Surg.* 2009 Oct;50(4):730-737.e1.
- [40] Ricotta JJ, Oderich GS. Fenestrated and branched stent grafts. *Perspect Vasc Surg Endovasc Ther.* 2008 Jun;20(2):174-187; discussion 188-189.
- [41] Schanzer A, Greenberg RK, Hevelone N, Robinson WP, Eslami MH, Goldberg RJ, et al. Predictors of abdominal aortic aneurysm sac enlargement after endovascular repair. *Circulation.* 2011 Jun 21;123(24):2848-2855.
- [42] Moulakakis KG, Dalainas I, Mylonas S, Giannakopoulos TG, Avgerinos ED, Liapis CD. Conversion to open repair after endografting for abdominal aortic aneurysm: a review of causes, incidence, results, and surgical techniques of reconstruction. *J Endovasc Ther.* 2010 Dec;17(6):694-702.
- [43] Peppelenbosch N, Buth J, Harris PL, van Marrewijk C, Fransen G, EUROSTAR Collaborators. Diameter of abdominal aortic aneurysm and outcome of endovascular aneurysm repair: does size matter? A report from EUROSTAR. *J Vasc Surg.* 2004 Feb;39(2):288-297.
- [44] Howell M, Villareal R, Krajcer Z. Percutaneous access and closure of femoral artery access sites associated with endoluminal repair of abdominal aortic aneurysms. *J Endovasc Ther.* 2001 Feb;8(1):68-74.
- [45] Torsello GB, Kasprzak B, Klenk E, Tessarek J, Osada N, Torsello GF. Endovascular suture versus cutdown for endovascular aneurysm repair: a prospective randomized pilot study. *J Vasc Surg.* 2003 Jul;38(1):78-82.
- [46] Gimzewska M, Jackson AI, Yeoh SE, Clarke M. Totally percutaneous versus surgical cut-down femoral artery access for elective bifurcated abdominal endovascular aneurysm repair. *Cochrane Database Syst Rev.* 2017 Feb 21;2:CD010185.
- [47] Ultee KHJ, Soden PA, Zettervall SL, Darling J, Verhagen HJM, Schermerhorn ML. Conversion from endovascular to open abdominal aortic aneurysm repair. *J Vasc Surg.* 2016 Jul;64(1):76-82.
- [48] Phade SV, Keldahl ML, Morasch MD, Rodriguez HE, Pearce WH, Kibbe MR, et al. Late abdominal aortic endograft explants: indications and outcomes. *Surgery.* 2011 Oct;150(4):788-795.
- [49] Brewster DC, Jones JE, Chung TK, Lamuraglia GM, Kwolek CJ, Watkins MT, et al. Long-term outcomes after endovascular abdominal aortic aneurysm repair: the first decade. *Ann Surg.* 2006 Sep;244(3):426-438.
- [50] Brinster CJ, Fairman RM, Woo EY, Wang GJ, Carpenter JP, Jackson BM. Late open conversion and explantation of abdominal aortic stent grafts. *J Vasc Surg.* 2011 Jul;54(1):42-46.
- [51] Mehta M, Veith FJ, Lipsitz EC, Ohki T, Russwurm G, Cayne NS, et al. Is elevated creatinine level a contraindication to endovascular aneurysm repair? *J Vasc Surg.* 2004 Jan;39(1):118-123.
- [52] Preventza O, Wheatley GH, Ramaiah VG, Rodriguez-Lopez JA, Williams J, Olsen D, et al. Management of endoleaks associated with endovascular treatment of descending thoracic aortic diseases. *J Vasc Surg.* 2008 Jul;48(1):69-73.

- [53] Blankensteijn JD, de Jong SECA, Prinssen M, van der Ham AC, Buth J, van Sterkenburg SMM, et al. Two-year outcomes after conventional or endovascular repair of abdominal aortic aneurysms. *N Engl J Med*. 2005 Jun 9;352(23):2398-2405.
- [54] Feezor RJ, Huber TS, Martin TD, Beaver TM, Hess PJ, Klodell CT, et al. Perioperative differences between endovascular repair of thoracic and abdominal aortic diseases. *J Vasc Surg*. 2007 Jan;45(1):86-89.
- [55] Gargiulo M, Gallitto E, Watzet H, Verzini F, Bianchini Massoni C, Loschi D, et al. Outcomes of endovascular aneurysm repair performed in abdominal aortic aneurysms with large infrarenal necks. *J Vasc Surg*. 2017 Oct;66(4):1065-1072.
- [56] Oliveira NFG, Bastos Gonçalves FM, Van Rijn MJ, de Ruyter Q, Hoeks S, de Vries J-PPM, et al. Standard endovascular aneurysm repair in patients with wide infrarenal aneurysm necks is associated with increased risk of adverse events. *J Vasc Surg*. 2017 Jun;65(6):1608-1616.
- [57] Umscheid T, Stelter WJ. Time-related alterations in shape, position, and structure of self-expanding, modular aortic stent-grafts: a 4-year single-center follow-up. *J Endovasc Surg*. 1999 Feb;6(1):17-32.
- [58] England A, Butterfield JS, Jones N, McCollum CN, Nasim A, Welch M, et al. Device migration after endovascular abdominal aortic aneurysm repair: experience with a Talent stent-graft. *J Vasc Interv Radiol*. 2004 Dec;15(12):1399-1405.
- [59] de la Motte L, Kehlet H, Vogt K, Nielsen CH, Groenvall JB, Nielsen HB, et al. Preoperative methylprednisolone enhances recovery after endovascular aortic repair: a randomized, double-blind, placebo-controlled clinical trial. *Ann Surg*. 2014 Sep;260(3):540-548; discussion 548-549.
- [60] Chaikof EL, Dalman RL, Eskandari MK, Jackson BM, Lee WA, Mansour MA, et al. The Society for Vascular Surgery practice guidelines on the care of patients with an abdominal aortic aneurysm. *J Vasc Surg*. 2018 Jan;67(1):2-77.e2.
- [61] Pennell RC, Hollier LH, Lie JT, Bernatz PE, Joyce JW, Pairolero PC, et al. Inflammatory abdominal aortic aneurysms: a thirty-year review. *J Vasc Surg*. 1985 Nov;2(6):859-869.
- [62] Bajardi G, Pecoraro F, Mirabella D, Bellisi MG. Inflammatory abdominal aortic aneurysm (IAAA). *Ann Ital Chir*. 2009 Jun;80(3):171-176.
- [63] Paravastu SCV, Ghosh J, Murray D, Farquharson FG, Serracino-Inglott F, Walker MG. A systematic review of open versus endovascular repair of inflammatory abdominal aortic aneurysms. *Eur J Vasc Endovasc Surg*. 2009 Sep;38(3):291-297.
- [64] Nakajima T, Kawazoe K, Komoda K, Sasaki T, Ohsawa S, Kamada T. Midline retroperitoneal versus midline transperitoneal approach for abdominal aortic aneurysm repair. *J Vasc Surg*. 2000 Aug;32(2):219-223.
- [65] Endo M, Kobayashi K, Tsubota M, Seki M, Sato H, Noto T, et al. Advantages of using the midline incision right retroperitoneal approach for abdominal aortic aneurysm repair. *Surg Today*. 1996;26(1):1-4.
- [66] Fassiadis N, Roidl M, Hennig M, South LM, Andrews SM. Randomized clinical trial of vertical or transverse laparotomy for abdominal aortic aneurysm repair. *Br J Surg*. 2005 Oct;92(10):1208-1211.
- [67] Kawaharada N, Morishita K, Fukada J, Yamada A, Muraki S,

- Hachiro Y, et al. Minilaparotomy abdominal aortic aneurysm repair versus the retroperitoneal approach and standard open surgery. *Surg Today*. 2004;34(10):837-841.
- [68] Edwards JM, Teefey SA, Zierler RE, Kohler TR. Intraabdominal paraanastomotic aneurysms after aortic bypass grafting. *J Vasc Surg*. 1992 Feb;15(2):344-350; discussion 351-353.
- [69] Coscas R, Greenberg RK, Mastracci TM, Eagleton M, Kang WC, Morales C, et al. Associated factors, timing, and technical aspects of late failure following open surgical aneurysm repairs. *J Vasc Surg*. 2010 Aug;52(2):272-281.
- [70] Kadakol AK, Nypaver TJ, Lin JC, Weaver MR, Karam JL, Reddy DJ, et al. Frequency, risk factors, and management of perigraft seroma after open abdominal aortic aneurysm repair. *J Vasc Surg*. 2011 Sep;54(3):637-643.
- [71] Djavani Gidlund K, Wanhainen A, Björck M. Intra-abdominal hypertension and abdominal compartment syndrome after endovascular repair of ruptured abdominal aortic aneurysm. *Eur J Vasc Endovasc Surg*. 2011 Jun;41(6):742-747.
- [72] Capoccia L, Speziale F, Menna D, Esposito A, Sirignano P, Rizzo AR, et al. Preliminary Results from a National Enquiry of Infection in Abdominal Aortic Endovascular Repair (Registry of Infection in EVAR--R.I.EVAR). *Ann Vasc Surg*. 2016 Jan;30:198-204.
- [73] Cernohorsky P, Reijnen MMPJ, Tielliu IFJ, van Sterkenburg SMM, van den Dungen JJAM, Zeebregts CJ. The relevance of aortic endograft prosthetic infection. *J Vasc Surg*. 2011 Aug;54(2):327-333.
- [74] Ducasse E, Calisti A, Speziale F, Rizzo L, Misuraca M, Fiorani P. Aortoiliac stent graft infection: current problems and management. *Ann Vasc Surg*. 2004 Sep;18(5):521-526.
- [75] O'Connor S, Andrew P, Batt M, Becquemin JP. A systematic review and meta-analysis of treatments for aortic graft infection. *J Vasc Surg*. 2006 Jul;44(1):38-45.
- [76] Heyer KS, Modi P, Morasch MD, Matsumura JS, Kibbe MR, Pearce WH, et al. Secondary infections of thoracic and abdominal aortic endografts. *J Vasc Interv Radiol*. 2009 Feb;20(2):173-179.
- [77] Grass F, Deglise S, Corpataux J-M, Saucy F. In situ aortobiiliac reconstruction of infected aneurysm using a single superficial femoral vein. *Vasc Endovascular Surg*. 2013 Jul;47(5):390-393.
- [78] Dorweiler B, Neufang A, Schmiedt W, Oelert H. Autogenous reconstruction of infected arterial prosthetic grafts utilizing the superficial femoral vein. *Thorac Cardiovasc Surg*. 2001 Apr;49(2):107-111.
- [79] Vogel TR, Symons R, Flum DR. The incidence and factors associated with graft infection after aortic aneurysm repair. *J Vasc Surg*. 2008 Feb;47(2):264-269.
- [80] Orandi BJ, Dimick JB, Deeb GM, Patel HJ, Upchurch GR. A population-based analysis of endovascular versus open thoracic aortic aneurysm repair. *J Vasc Surg*. 2009 May;49(5):1112-1116.
- [81] Milewicz DM, Dietz HC, Miller DC. Treatment of aortic disease in patients with Marfan syndrome. *Circulation*. 2005 Mar 22;111(11):e150-e157.
- [82] Pepin M, Schwarze U, Superti-Furga A, Byers PH. Clinical and genetic features of Ehlers-Danlos syndrome type IV, the vascular type. *N Engl J Med*. 2000 Mar 9;342(10):673-680.
- [83] Booher AM, Eagle KA. Diagnosis and management issues in thoracic aortic aneurysm. *Am Heart J*. 2011 Jul;162(1):38-46.e1.

- [84] Patterson BO, Holt PJ, Nienaber C, Fairman RM, Heijmen RH, Thompson MM. Management of the left subclavian artery and neurologic complications after thoracic endovascular aortic repair. *J Vasc Surg.* 2014 Dec;60(6):1491-1497.e1.
- [85] Klocker J, Koell A, Erlmeier M, Goebel G, Jaschke W, Fraedrich G. Ischemia and functional status of the left arm and quality of life after left subclavian artery coverage during stent grafting of thoracic aortic diseases. *J Vasc Surg.* 2014 Jul;60(1):64-69.
- [86] Maldonado TS, Dexter D, Rockman CB, Veith FJ, Garg K, Arko F, et al. Left subclavian artery coverage during thoracic endovascular aortic aneurysm repair does not mandate revascularization. *J Vasc Surg.* 2013 Jan;57(1):116-124.
- [87] Riesenman PJ, Farber MA, Mendes RR, Marston WA, Fulton JJ, Keagy BA. Coverage of the left subclavian artery during thoracic endovascular aortic repair. *J Vasc Surg.* 2007 Jan;45(1):90-94; discussion 94-95.
- [88] Simonte G, Parlani G, Farchioni L, Isernia G, Cieri E, Lenti M, et al. Lesson Learned with the Use of Iliac Branch Devices: Single Centre 10 Year Experience in 157 Consecutive Procedures. *Eur J Vasc Endovasc Surg.* 2017 Jul;54(1):95-103.
- [89] O'Callaghan A, Mastracci TM, Greenberg RK, Eagleton MJ, Bena J, Kuramochi Y. Outcomes for supra-aortic branch vessel stenting in the treatment of thoracic aortic disease. *J Vasc Surg.* 2014 Oct;60(4):914-920.
- [90] Leon LR, Mills JL, Jordan W, Morasch MM, Kovacs M, Becker GJ, et al. The risks of celiac artery coverage during endoluminal repair of thoracic and thoracoabdominal aortic aneurysms. *Vasc Endovascular Surg.* 2009 Mar;43(1):51-60.
- [91] Najibi S, Terramani TT, Weiss VJ, Mac Donald MJ, Lin PH, Redd DC, et al. Endoluminal versus open treatment of descending thoracic aortic aneurysms. *J Vasc Surg.* 2002 Oct;36(4):732-737.
- [92] Cheung AT. An evolving role of anesthesiologists in the management of thoracic aortic diseases. *Anesth Analg.* 2010 Aug;111(2):259-260.
- [93] Acher CW, Wynn M. A modern theory of paraplegia in the treatment of aneurysms of the thoracoabdominal aorta: An analysis of technique specific observed/expected ratios for paralysis. *J Vasc Surg.* 2009 May;49(5):1117-1124; discussion 1124.
- [94] Eggebrecht H, Thompson M, Rousseau H, Czerny M, Lönn L, Mehta RH, et al. Retrograde ascending aortic dissection during or after thoracic aortic stent graft placement: insight from the European registry on endovascular aortic repair complications. *Circulation.* 2009 Sep 15;120(11 Suppl):S276-S281.
- [95] Connolly JE. Hume Memorial lecture. Prevention of spinal cord complications in aortic surgery. *Am J Surg.* 1998 Aug;176(2):92-101.
- [96] Czerny M, Eggebrecht H, Sodeck G, Verzini F, Cao P, Maritati G, et al. Mechanisms of symptomatic spinal cord ischemia after TEVAR: insights from the European Registry of Endovascular Aortic Repair Complications (EuREC). *J Endovasc Ther.* 2012 Feb;19(1):37-43.
- [97] Buth J, Harris PL, Hobo R, van Eps R, Cuypers P, Duijm L, et al. Neurologic complications associated with endovascular repair of thoracic aortic pathology: Incidence and risk factors. a study from the European Collaborators on Stent/Graft Techniques for Aortic Aneurysm Repair (EUROSTAR) registry. *J Vasc Surg.* 2007 Dec;46(6):1103-1110; discussion 1110-1111.

- [98] Greenberg RK, Lu Q, Roselli EE, Svensson LG, Moon MC, Hernandez AV, et al. Contemporary analysis of descending thoracic and thoracoabdominal aneurysm repair: a comparison of endovascular and open techniques. *Circulation*. 2008 Aug 19;118(8):808-817.
- [99] Zoli S, Roder F, Etz CD, Brenner RM, Bodian CA, Lin H-M, et al. Predicting the risk of paraplegia after thoracic and thoracoabdominal aneurysm repair. *Ann Thorac Surg*. 2010 Oct;90(4):1237-1244; discussion 1245.
- [100] Berg P, Kaufmann D, van Marrewijk CJ, Buth J. Spinal cord ischaemia after stent-graft treatment for infra-renal abdominal aortic aneurysms. Analysis of the Eurostar database. *Eur J Vasc Endovasc Surg*. 2001 Oct;22(4):342-347.
- [101] Takayama H, Borger MA. Preventing spinal cord injury during thoracic aortic surgery: simpler than we thought? *J Thorac Cardiovasc Surg*. 2015 Jan;149(1):366-368.
- [102] Di Luozzo G. Visceral and spinal cord protection during thoracoabdominal aortic aneurysm repair: clinical and laboratory update. *J Thorac Cardiovasc Surg*. 2013 Mar;145(3 Suppl):S135-S138.
- [103] Svensson LG, Kouchoukos NT, Miller DC, Bavaria JE, Coselli JS, Curi MA, et al. Expert consensus document on the treatment of descending thoracic aortic disease using endovascular stent-grafts. *Ann Thorac Surg*. 2008 Jan;85(1 Suppl):S1-41.
- [104] Vaddineni SK, Taylor SM, Patterson MA, Jordan WD. Outcome after celiac artery coverage during endovascular thoracic aortic aneurysm repair: preliminary results. *J Vasc Surg*. 2007 Mar;45(3):467-471.
- [105] Nordon IM, Karthikesalingam A, Hincliffe RJ, Holt PJ, Loftus IM, Thompson MM. Secondary interventions following endovascular aneurysm repair (EVAR) and the enduring value of graft surveillance. *Eur J Vasc Endovasc Surg*. 2010 May;39(5):547-554.
- [106] Perek B, Juszkat R, Kulesza J, Jemielity M. Stent grafts separation 6 years after endovascular repair of a thoracic aortic aneurysm. *J Vasc Interv Radiol*. 2014 Oct;25(10):1650-1652.
- [107] Shukla AJ, Jeyabalan G, Cho J-S. Late collapse of a thoracic endoprosthesis. *J Vasc Surg*. 2011 Mar;53(3):798-801.
- [108] Matsumura JS, Cambria RP, Dake MD, Moore RD, Svensson LG, Snyder S, et al. International controlled clinical trial of thoracic endovascular aneurysm repair with the Zenith TX2 endovascular graft: 1-year results. *J Vasc Surg*. 2008 Feb;47(2):247-257; discussion 257.
- [109] Makaroun MS, Dillavou ED, Wheatley GH, Cambria RP, Gore TAG Investigators. Five-year results of endovascular treatment with the Gore TAG device compared with open repair of thoracic aortic aneurysms. *J Vasc Surg*. 2008 May;47(5):912-918.
- [110] Scali ST, Beck AW, Butler K, Feezor RJ, Martin TD, Hess PJ, et al. Pathology-specific secondary aortic interventions after thoracic endovascular aortic repair. *J Vasc Surg*. 2014 Mar;59(3):599-607.
- [111] Szeto WY, Desai ND, Moeller P, Moser GW, Woo EY, Fairman RM, et al. Reintervention for endograft failures after thoracic endovascular aortic repair. *J Thorac Cardiovasc Surg*. 2013 Mar;145(3 Suppl):S165-S170.
- [112] Dake MD, Miller DC, Mitchell RS, Semba CP, Moore KA, Sakai T. The "first generation" of endovascular stent-grafts for patients with aneurysms of the

descending thoracic aorta. *J Thorac Cardiovasc Surg.* 1998 Nov;116(5):689-703; discussion 703-704.

[113] Shapira OM, Aldea GS, Cutter SM, Fitzgerald CA, Lazar HL, Shemin RJ. Improved clinical outcomes after operation of the proximal aorta: a 10-year experience. *Ann Thorac Surg.* 1999 Apr;67(4):1030-1037.

[114] Achneck HE, Rizzo JA, Tranquilli M, Elefteriades JA. Safety of thoracic aortic surgery in the present era. *Ann Thorac Surg.* 2007 Oct;84(4):1180-1185; discussion 1185.

[115] Arabkhani B, Mookhoek A, Di Centa I, Lansac E, Bekkers JA, De Lind Van Wijngaarden R, et al. Reported Outcome After Valve-Sparing Aortic Root Replacement for Aortic Root Aneurysm: A Systematic Review and Meta-Analysis. *Ann Thorac Surg.* 2015 Sep;100(3):1126-1131.

[116] David TE, Feindel CM, Bos J. Repair of the aortic valve in patients with aortic insufficiency and aortic root aneurysm. *J Thorac Cardiovasc Surg.* 1995 Feb;109(2):345-351; discussion 351-352.

[117] Wheat MW, Wilson JR, Bartley TD. SUCCESSFUL REPLACEMENT OF THE ENTIRE ASCENDING AORTA AND AORTIC VALVE. *JAMA.* 1964 May 25;188:717-719.