



Adult onset unilateral high myopia in a female patient: A case report

Saleh Saif Al Messabi^a, Mohamed Dirani^{b,c,d}, Shobhana Mukhi-Marathe^{a,*}

^a Samaya Specialised Eye Center, Al Bateen Street, Abu Dhabi, United Arab Emirates

^b Singapore Eye Research Institute, Singapore National Eye Centre, Singapore, Singapore

^c Ophthalmology and Vision Sciences Academic Clinical Program, Duke-National University of Singapore Medical School, Singapore

^d Plano Pte Ltd, Singapore

ARTICLE INFO

Keywords:

Adult-onset myopia
Unilateral myopia
Progressive myopia
Emmetropisation

ABSTRACT

Purpose: We report a rare case of unilateral progressive adult-onset myopia in a healthy 27 year old female patient.

Observations: The patient presented to our clinic in 2014 with gradual decrease in vision in the right eye since one and a half years. Her uncorrected visual acuity (UCVA) in the right eye was 0.05, improving to 1.0 with -2.25 Diopter Sphere (DS). The left eye uncorrected visual acuity was 1.0 partial improving to 1.0 with -0.50 Diopter Cylinder (DC) at 10° . The myopia in her right eye continued to increase steadily until her last detailed ophthalmic examination in November 2018, at the age of 31 years, showed a refractive error of -6.75 Diopter Sphere with -0.5 Diopter Cylinder at 170° . Ocular biometry readings showed an axial length (AL) of 25.79mm in the right eye compared to 25.05mm in 2015. The ocular examination of both eyes including clinical examination of anterior and posterior segment, corneal topography, lens densitometry, ultrasound B scan all were within normal limits. Over the last two years she has gradually developed moderate constant esotropia in the right eye, currently $+30$ Prism Diopters. A short visit to the clinic in December 2019, showed a refraction of -6.75 DS with -0.5 DC at 170° in the right eye and -0.50 DC at 10° in the left eye.

Conclusions and importance: The abrupt onset of myopia in one eye in a healthy individual in this case, the degree of myopia, the nature and rate of progression, absence of risk factors, and otherwise normal ocular examination except for progressive increase in axial length is unusual. Our case brings us to conjecture the role of powerful local factors in the intrinsic regulation of eyeball growth going askew. We believe more and more reporting of myopia cases deviating from natural history and their study might provide clues in a new direction about myopia pathogenesis and our understanding and tackling of one of the oldest eye disease with an ever increasing prevalence.

1. Introduction

Myopia development is suggested to be the result of interplay between genetic and environmental factors.¹⁻³ In most people, myopia develops during childhood⁴ and stabilizes in the teenage years. Nonetheless, in some people myopia may be adult-onset.⁴ Most cases of adult-onset myopia are bilateral, of low to moderate degree⁵ and associated with risk factors, such as studying habits and work habits,⁶ occupations requiring extensive near-work tasks and/or close proximity near-work.⁷ Other proposed factors include decreased outdoor activities, Vitamin D deficiency, high AC/A ratio. We report a rare case of adult onset, unilateral myopia that continues to progress in the absence of any risk factors in an otherwise normal eye.

2. Case report

A 27 year old female presented to our center in 2014 with a history of gradual decrease in vision in the right eye since one and a half years. She wished to explore options for refractive surgery. There was no history of glasses or contact lens use. There was no history of myopia in the family. Systemic history and examination were unremarkable. The patient was not receiving any medication.

The uncorrected visual acuity (UCVA) in her right eye was 0.05, improving to 1.0 with -2.25 DS. The left eye UCVA was 1.0 partial, improving to 1.0 with -0.50 DC at 10° . She was prescribed glasses and contact lenses and was asked to return after 6 months to confirm stability of the refractive error. She used her glasses and contact lenses on

* Corresponding author.

E-mail address: drshobhana006@gmail.com (S. Mukhi-Marathe).

and off until she returned for follow up a year and a half later. This time the myopia in her right eye had increased to -3.50 DS while the left eye was still stable. Subsequent visits in 2016 and 2017 showed progressively increasing myopia in the right eye.

Her last refractions as on November 2018 and December 2019 show -6.75 DS with -0.50 DC at 170° in the right eye and -0.50 DC at 10° in the left eye. On clinical examination, ocular adnexa, orbit and extraocular movements were normal. Slit lamp examination of both eyes was unremarkable. Serial IOPs for both eyes from 2015 to 2019 were within normal range and symmetrical with no inter-ocular variability on any of the visits. Gonioscopy showed grade III open, non occludable angles in both eyes. There were no lenticular changes. Fundus examination was normal and symmetric in both eyes without any myopic changes or posterior staphyloma (Fig. 1). Ocular biometry readings performed in November 2018 showed an axial length of 25.79mm in the right eye and 23.5mm in the left eye. Orthoptic evaluation showed normal extraocular movements and AC/A ratio of 5:1 by lens gradient method. Right eye esotropia of 30 Prism Diopter with good fixation was documented in the 2018 visit. B scan ultrasound of both eyes showed attached retina without posterior vitreous detachment. There was no evidence of posterior staphyloma suggesting uniform elongation of eyeball rather than ectasia at posterior pole (Fig. 2). Macular OCT showed normal foveal and choroidal architecture with no significant abnormalities for both eyes. Corneal tomography performed on Pentacam showed normal refractive and elevation maps and normal Belin Ambrosio displays. Both eyes topographic parameters were almost similar in values and the keratometry readings have been stable over time (Fig. 3). Higher order aberrations of cornea as measured by Pentacam were found to be symmetrical and in normal range for both eyes. Lens densitometry performed on Pentacam showed PNS 0 on PNS staging both eyes. Anterior Segment Optical Coherence Tomography (AS-OCT) performed on the MS 39, showed comparable values for aqueous depth, equator length, and lens thickness measurements in both eyes, thus ruling out any difference in radius of curvature or lenticular power between the two eyes. The patient was called back to the clinic for a quick evaluation of binocular functions in December 2019. Tests for binocular function performed on December 2019 showed right eye suppression on the Worth Four Dot Test. Stereopsis on Lang's test was found to be 400" in the right eye and 1200" in the left eye. On detailed checking of past notes, it was observed that the dominant eye as checked in the clinic in the 2014 visit was the right eye.

The findings of auto refraction and subjective acceptance after cycloplegic refraction over last four visits are shown in Tables 1 and 2

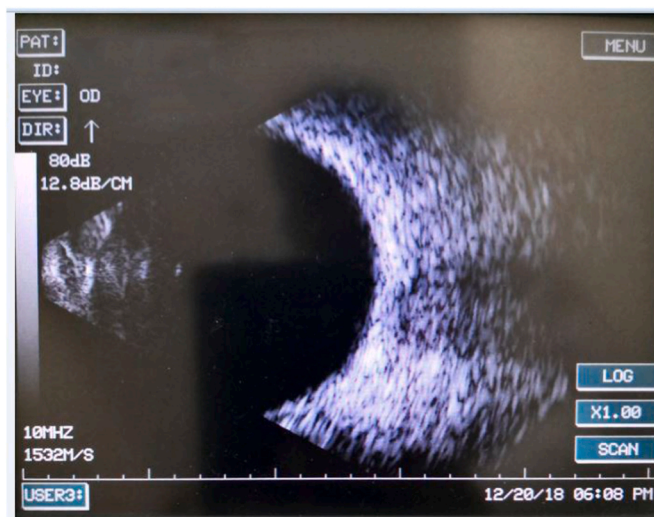


Fig. 2. B scan Right eye.

respectively. The cycloplegic agents used were cyclopentolate 1% in the 2015 and 2016 visits. After she presented with esotropia in the 2017 visit, we performed refraction under atropine 1% for this visit and the subsequent visit. The refractive status did not show much change compared to cyclopentolate refractions performed in earlier years.

The readings for serial optical biometry performed on the same machine for both eyes for the years 2015, 2017 and 2018 are shown in Table 3.

3. Discussion

Most cases of adult-onset myopia are reported to be low to moderate with a slow rate of progression, and in some cases associated with occupations requiring intensive amounts of near work activity. We report a case of adult-onset myopia with an unusual natural history. The rare presentation of the case is characterized by the unilateral nature, degree of myopia, nature and rate of progression, absence of any risk factors, and an otherwise normal ocular examination except for progressive increase in axial length and recently acquired esotropia.

Several factors associated with development of myopia include near work and reading, intensity of reading, urban areas, professionals,

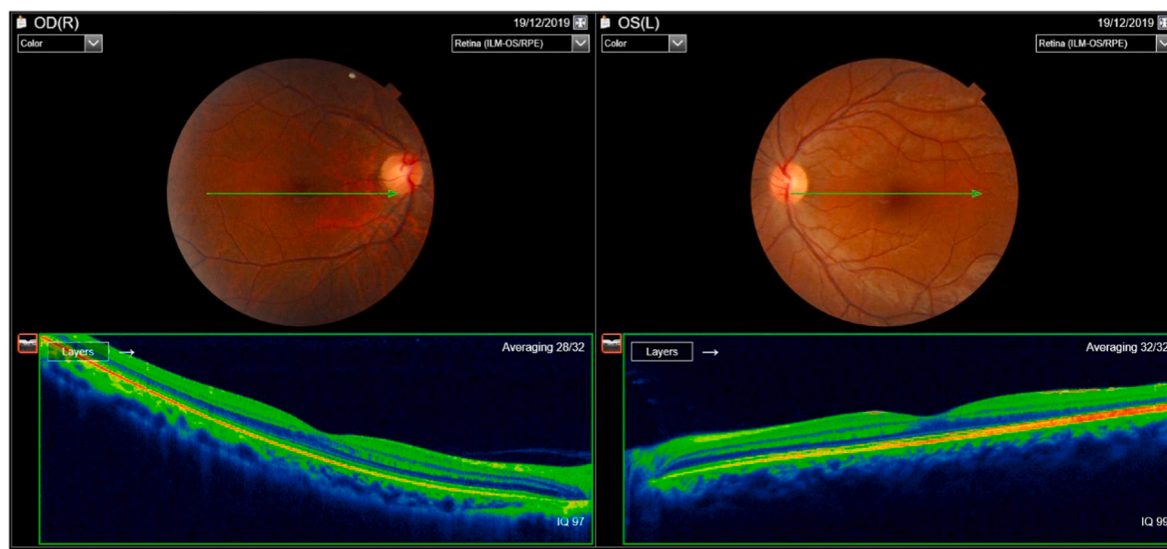


Fig. 1. Fundus photograph and OCT optic disc and macula (9mm scans) both eyes.

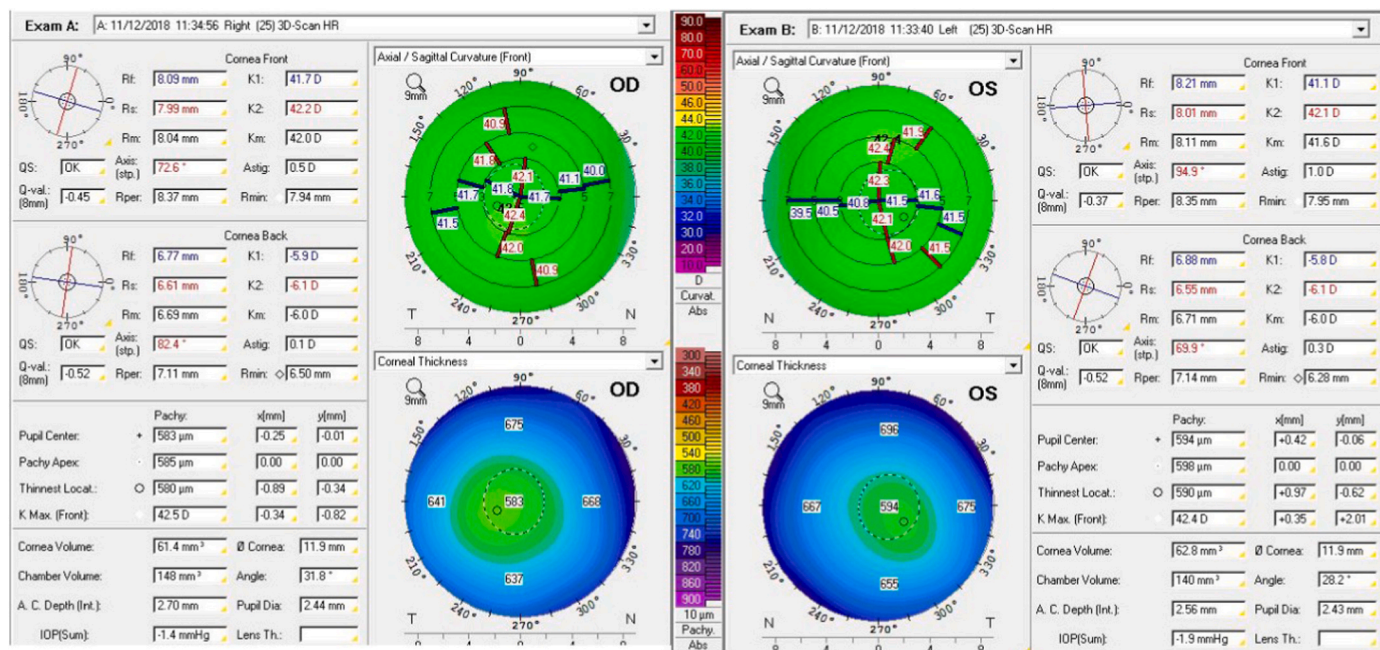


Fig. 3. Corneal topography both eyes.

Table 1

Auto refraction after cycloplegic refraction over last four visits.

AutoRef	OD			OS		
	SPH	CYL	AXIS	SPH	CYL	AXIS
2014	-2.25	0	-	-0.25	-0.50	25
2015	-4.0	0	-	0	-0.5	15
2016	-5.25	-0.5	175	-0.5	-0.5	40
2018	-6.75	-0.75	175	-0.25	-0.50	10

Table 2

Subjective acceptance after cycloplegic refraction over last four visits.

	OD				OS			
	SPH	CYL	AXIS	V/A	SPH	CYL	AXIS	V/A
2014	-2.25	0	-	1.0	-0.25	-0.25	25	1.0
2015	-3.50	0	-	1.0	0	-0.5	10	1.0
2016	-5.0	-0.5	170	1.0	-0.25	-0.5	30	1.0
2018	-6.75	-0.5	170	1.0	-0.25	-0.5	10	1.0

Table 3

Serial A – scan biometry.

Axial length	OD	OS
2014	-	-
2015	25.05	23.48
2017	25.37	23.47
2018	25.79	23.50

education, computer use, university students, increased intelligence, lack of outdoor activity.¹ The risk factors studied for adult myopia include time spent in near work, performing near work at close distance, high response AC/A ratio, high accommodative lag, violet light transmission.^{8,15} Our patient is a homemaker, was not a student with intensive reading or excessive time spent in near work around the onset of myopia. There is a history of intermittent computer use at work which is neither for prolonged duration of the day nor for continuous long hours.

Adult-onset myopia has been suggested to be associated with family

history of myopia.^{9,10} In this case there is no family history of myopia or wearing glasses in parents or siblings. Some cases of adult-onset myopia of high degree are mentioned in literature but there is an associated ocular or systemic pathology like diabetes or glaucoma.⁴ Our patient has normal systemic and ocular evaluations.

The GEM Twin Study⁵ mentions around 30% of cases of adult onset myopia to be unilateral, however all these cases were low to moderate degree, there wasn't any continued progression nor was the rate of progression so high. Further they had a strong genetic component.

Another interesting thing to note in this patient is the possible difference in baseline axial lengths in both eyes. Prof Calvas in his review article mentions compensatory mechanisms of lens and cornea at the onset of myopia,¹² Any increase in AL would cause a serious shift to myopia, which is however offset by corresponding changes in other parts of the eye structure. For example, the lens will reduce its refractive power when AL increases.¹³ The existence of an active emmetropisation mechanism in the eye is a widely accepted theory, As per the history of our patient, assuming she was emmetropic prior to presentation, her axial length at presentation was 25.05mm compared to the other eye that was 23.48mm, that is a difference of 1.57mm between the myopic and emmetropic eye accounting for myopia of 2.25D. Over 2015 until 2018 however, the increase in the axial length was only 0.74mm with a disproportionate increase in myopia by 4.5D. This might suggest that compensatory mechanisms towards emmetropisation do play a role at least at the onset of visual blur. Animal studies show that the signaling cascade regulating refractive eye development is within the eye itself and does not require a feedback from the brain.¹ This is supported by the fact that the eye responds to local blur with local changes even when the optic nerve is severed. Rada et al.¹⁴ reported that the retina provides remodeling signals to the sclera by which the eye alters its shape to place an image on the retina, that is, emmetropisation.

Our patient was an emmetrope in both eyes as per her memory about her visual acuity tests performed for the driving license process when she turned 18 years. She continued to remain emmetropic in both eyes until around a year and half prior to her presentation at the age of 27 years when she noticed a decrease vision in the right eye. She had visited another center a few months prior to visiting our clinic where she was prescribed glasses for her right eye. She used those glasses intermittently and in 2014 visited our clinic wishing to explore options for refractive

surgery. At her initial visit to our clinic she was prescribed glasses and contact lenses for her myopia of -2.25 Diopters and was asked to return after 6 months to confirm stability of the refractive error. Thereafter on subsequent visits her myopia in the right eye continued to increase and her BCVA was maintained at 6/6 with progressively higher correction. At the time of writing this paper, her most recent examination was November 2018, where her myopia stood at $-6.5D$ and she was also found to have right constant esotropia of 30 PD with good fixation. Extraocular movements were normal. AC/A ratio was found to be 5:1 both eyes by lens gradient method. There were no lenticular changes and the IOP was normal. The corneal topography, AC depth, crystalline lens thickness, lens densitometry and morphology were normal. Records of axial length showed increase from 25.06mm in 2015 (unfortunately we do not have axial length records prior to 2015) to 25.79mm in 2018 for the right eye. The left eye axial length remained almost constant from 23.48mm in 2015 to 23.55mm in 2018. The posterior segment evaluation showed normal optic disc and macula and absence of posterior staphyloma. We got an opportunity to see the patient again in December 2019 for a quick visit to assess the binocular functions. The refraction and axial length for both eyes were comparable to the November 2018 visit (the time this manuscript was drafted).

All the above findings strongly point towards the increase in axial length being the only measurable contributor to the increase in myopia in this patient. We chose not to elaborate on the esotropia since it appeared much later than the onset of asymmetry suggesting the process of myopia progression had already set in earlier. Further, we believe it is very likely that the suppression and low stereopsis are secondary to the esotropia, and possibly a result of the anisometropia rather than the cause. The fact that the dominant eye was the right eye to begin with, also supports this opinion.

The abrupt onset of myopia in only one eye, the degree of myopia, nature and rate of progression, absence of any risk factors, and otherwise normal ocular examination except for progressive increase in axial length was unusual in our case. For an eye that is structurally normal, has a normal fellow eye, does not have any predisposing history or genetic factors, what could be the ongoing stimulus causing it to continue to grow in an uncontrolled manner? There appears to be some trigger for the myopia to start in our patient and there are factors that are causing this steady, ongoing eyeball growth. Both the trigger and the responsible factors could possibly even be local to the right eye as the other eye seems totally unaffected in spite of the continuing stimulus. Several interventions have been evaluated for their efficacy to arrest progression of myopia without conclusive evidence.¹¹ If we assume that there are more powerful local factors at play, more research into these factors might provide some clues about intrinsic regulation of eyeball growth gone askew and give a new direction to our understanding and tackling of myopia. Meanwhile, our patient still awaits refractive surgery at 32 years, in spite of normal corneal profiles and BCVA 1.0, as her myopia is still not stable.

4. Conclusion

This is a rare case of unilateral high myopia, with an unusual natural

history. The rare presentation in our patient was characterized by unilateral nature in an adult, high myopia, rate of progression, absence of any risk factors and otherwise normal ocular examination except for progressive increase in axial length.

Patient consent

Written consent for publication was obtained from patient before working on the manuscript.

Funding

No funding or grant support

Authorship

All authors attest that they meet the current ICMJE criteria for Authorship.

Declaration of competing interest

The following authors have no financial disclosures:

Saleh Saif Al Messabi, Mohamed Dirani, Shobhana Mukhi-Marathe.

References

- Cooper J, Tkatchenko AV. A Review of current concepts of the etiology and treatment of myopia. *Eye Contact Lens*. 2018;44:231–247.
- Flitcroft DI. Ophthalmologists should consider the causes of myopia and not simply treat its consequences. *Br J Ophthalmol*. 1998;82:210–211.
- Dirani M, Chamberlain M, Shekar SN, et al. Heritability of refractive error and ocular biometrics: the genes in myopia (GEM) Twin study. *Invest Ophthalmol Vis Sci*. 2006;47:4756–4761.
- Fledelius HC. Adult onset myopia: oculometric features. *Acta Ophthalmol Scand*. 1995;73:397–401.
- Dirani M, Shekar SN, Baird PN. Adult-onset myopia: the genes in myopia (GEM) Twin study. *Invest Ophthalmol Vis Sci*. 2008;49:3324–3327.
- Saw SM, Chia SE, Chew SJ. Relation between work and myopia in Singapore women. *Optom Vis Sci*. 1999;76:393–396.
- Simensen B, Thorud LO. Adult-onset myopia and occupation. *Acta Ophthalmol*. 1994;72:469–471.
- Bullimore MA. The study of progression of adult nearsightedness (SPAN): design and baseline characteristics. *Optom Vis Sci*. 2006;83:594–604.
- Iribarren R, Iribarren G, Castagnola MM, et al. Family history and reading habits in adult-onset myopia. *Curr Eye Res*. 2002;25(5):309–315.
- Onal S, Toker E, Akingol Z, et al. Refractive errors of medical students in Turkey: one year follow-up of refraction and biometry. *Optom Vis Sci*. 2007;84:175–180.
- Saw SM, Gazzard G, Au Eong G-G, Tan DTH. Myopia: attempts to arrest progression. *Br J Ophthalmol*. 2002;86:1306–1311.
- Meng W, Butterworth J, Malecaze F, Calvas P. Axial length of myopia: a review of current research. *Ophthalmologica*. 2011;225:127–134.
- Brown NP, Koretz JF, Bron AJ. The development and maintenance of emmetropia. *Eye (Lond)*. 1999;13(Pt 1):83–92.
- Rada JA, Shelton S, Norton TT. The sclera and myopia. *Exp Eye Res*. 2006;82:185–200.
- Torii H, Ohnuma K, Kurihara T, et al. Violet light transmission is related to myopia progression in adult high myopia. *Sci Rep*. 2017;7(1):14523.



Minerva Access is the Institutional Repository of The University of Melbourne

Author/s:

Al Messabi, SS; Dirani, M; Mukhi-Marathe, S

Title:

Adult onset unilateral high myopia in a female patient: A case report.

Date:

2020-12

Citation:

Al Messabi, S. S., Dirani, M. & Mukhi-Marathe, S. (2020). Adult onset unilateral high myopia in a female patient: A case report.. Am J Ophthalmol Case Rep, 20, pp.100941-.
<https://doi.org/10.1016/j.ajoc.2020.100941>.

Persistent Link:

<http://hdl.handle.net/11343/271946>

File Description:

Published version

License:

CC BY-NC-ND