



LUND UNIVERSITY

Endovascular treatment of complex abdominal aortic aneurysm disease

Sveinsson, Magnus

2021

Document Version:

Publisher's PDF, also known as Version of record

[Link to publication](#)

Citation for published version (APA):

Sveinsson, M. (2021). *Endovascular treatment of complex abdominal aortic aneurysm disease*. Lund University, Faculty of Medicine.

Total number of authors:

1

General rights

Unless other specific re-use rights are stated the following general rights apply:

Copyright and moral rights for the publications made accessible in the public portal are retained by the authors and/or other copyright owners and it is a condition of accessing publications that users recognise and abide by the legal requirements associated with these rights.

- Users may download and print one copy of any publication from the public portal for the purpose of private study or research.
- You may not further distribute the material or use it for any profit-making activity or commercial gain
- You may freely distribute the URL identifying the publication in the public portal

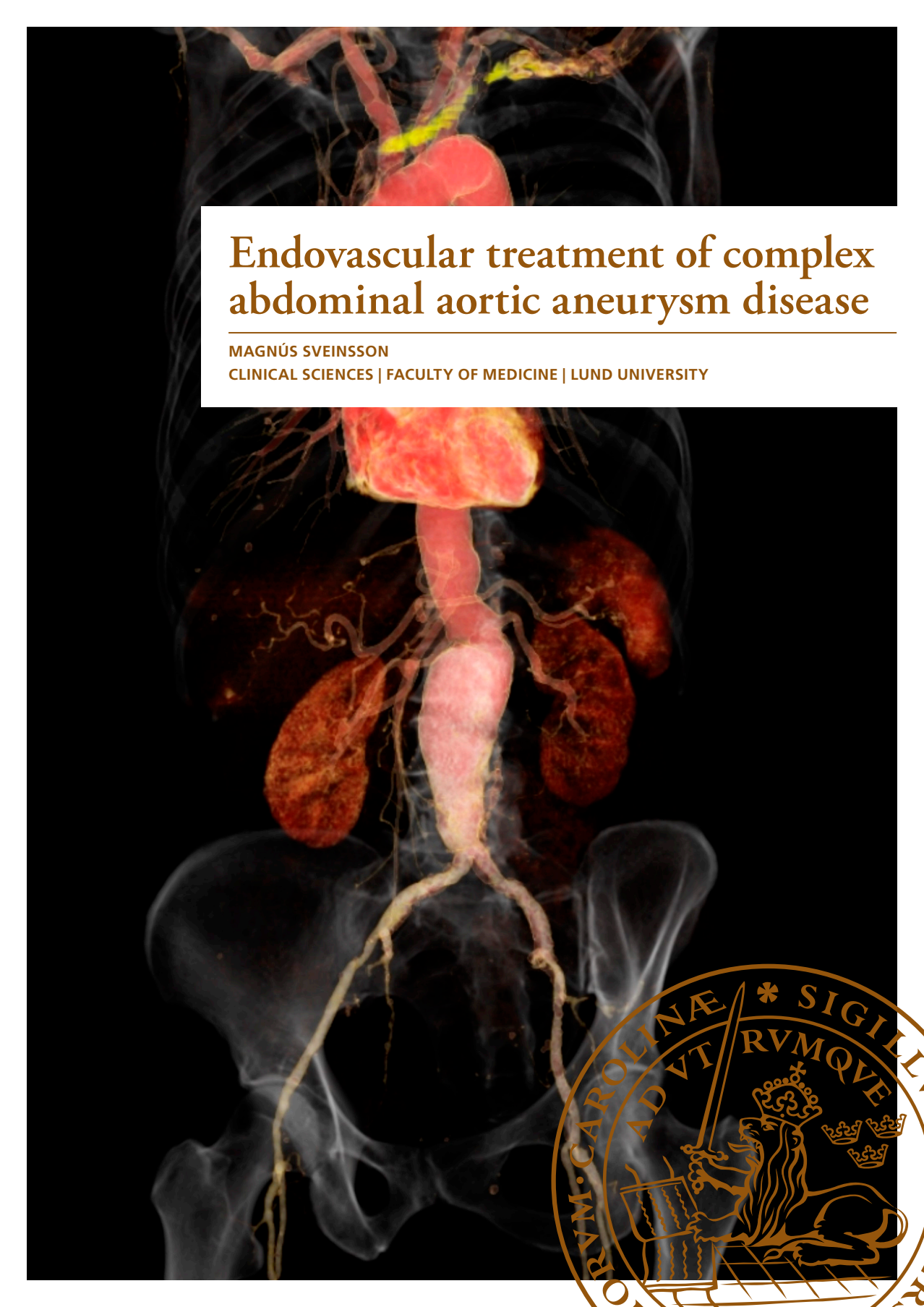
Read more about Creative commons licenses: <https://creativecommons.org/licenses/>

Take down policy

If you believe that this document breaches copyright please contact us providing details, and we will remove access to the work immediately and investigate your claim.

LUND UNIVERSITY

PO Box 117
221 00 Lund
+46 46-222 00 00



Endovascular treatment of complex abdominal aortic aneurysm disease

MAGNÚS SVEINSSON

CLINICAL SCIENCES | FACULTY OF MEDICINE | LUND UNIVERSITY



MAGNÚS SVEINSSON was born in Reykjavík, Iceland in 1977. He received his medical degree from the University of Iceland in 2006. Moving with his family to Helsingborg Sweden he completed specialization in general surgery in 2013, and subsequently specialized in vascular surgery in 2018 after training at Helsingborg Regional Hospital as well as in Vascular Center Malmö in Sweden where the research projects in this thesis were undertaken.



Endovascular treatment of complex abdominal aortic aneurysm disease

Magnús Sveinsson



LUND
UNIVERSITY

DOCTORAL DISSERTATION

by due permission of the Faculty of Medicine, Lund University, Sweden.
To be defended at Skåne University Hospital Malmö, 22nd of May 2021 at 09:00.

Faculty opponent

Professor Emeritus Jan Brunkwall.
Dep. of Vascular and Endovascular Surgery, University of Cologne, Germany

Organization LUND UNIVERSITY Department of Clinical Sciences Vascular Center, Skåne University Hospital Author: Magnús Sveinsson		Document name: Doctoral dissertation
		Date of issue: May 22nd 2021
		Sponsoring organization
Title: Endovascular treatment of complex abdominal aortic aneurysm disease		
Abstract		
<p>Endovascular treatment options for abdominal aortic aneurysm disease have evolved rapidly in the last years. Continuous efforts aim towards securing patient safety and durable stentgrafts. Juxtarenal abdominal aortic aneurysms (jAAA) pose a specific challenge, demanding complex device design and detailed planning, as well as various technical difficulties during fenestrated endovascular aneurysm repair (FEVAR). Adequate proximal seal and durable target vessel patency are of particular concern, driving continuous research and innovation in graft design and methodical advances. Similarly to primary endovascular repair for juxtarenal aneurysm, FEVAR is increasingly used as secondary repair after failed previous aneurysm reconstruction. Variable aneurysm anatomy requires individually tailored grafts in each case, which is a limitation in urgent settings. Stentgrafts with a standardized configuration, available "off-the-shelf", have been designed to address this issue with promising short-term results. FEVAR is a safe and effective means of managing jAAA with good short-term outcomes, but long-term data is limited.</p> <p>The specific aim of this thesis was:</p> <ol style="list-style-type: none"> 1. To evaluate the impact of experience of FEVAR on graft design and clinical outcome in patients with jAAA 2. To evaluate short-term performance and outcome of fenestrated and branched stentgrafts when used as secondary proximal repair after previous infrarenal aortic reconstruction 3. To evaluate the performance and long-term clinical outcome of the COOK Zenith p-Branch device for jAAA in elective and emergent settings 4. To evaluate the long-term outcome of FEVAR in patients with jAAA <p>FEVAR is an effective and safe treatment option for jAAA disease. Increasing experience results in decreased intra-operative fluoroscopy time and contrast medium load despite more complex stentgraft design. FEVAR as secondary repair after failed previous infrarenal treatment for AAA is safe and effective, but meticulous pre-operative imaging and planning is essential. The COOK Zenith p-Branch device performs well in treatment of jAAA both electively and emergently in selected patient groups, particularly in urgent circumstances. However, a custom made device should be favored in appropriate cases. With increasing experience a reduction is seen in operative mortality, 5-year mortality and over-all aneurysm sac diameter, as well as increased 5-year re-intervention free survival. FEVAR is a safe and effective treatment for jAAA with good outcomes in the short- and long-term, although the need for re-intervention remains high.</p>		
Key words: FEVAR, fenestrated, aortic aneurysm, AAA, juxtarenal, off-the-shelf, p-Branch, t-Branch		
Classification system and/or index terms (if any)		
Supplementary bibliographical information		Language: English
ISSN: 1652-8220		ISBN: 978-91-8021-054-6
Recipient's notes	Number of pages	Price
	Security classification	

I, the undersigned, being the copyright owner of the abstract of the above-mentioned dissertation, hereby grant to all reference sources permission to publish and disseminate the abstract of the above-mentioned dissertation.

Signature



Date 2019-04-15

Endovascular treatment of complex abdominal aortic aneurysm disease

Magnús Sveinsson



LUND
UNIVERSITY

Coverphoto and figure 1 from Shutterstock ©

Figure 2, 3, 5, 6, 7: Permission for use granted by COOK Medical, Bloomington, Indiana.

Copyright pp 1-70 Magnús Sveinsson

Paper 1 © Elsevier Inc.

Paper 2 © Elsevier Inc.

Paper 3 © Elsevier B.V.

Paper 4 © by the Authors (Manuscript unpublished)

Lund University, Faculty of Medicine
Department of Clinical Sciences

ISBN 978-91-8021-054-6

ISSN 1652-8220

Printed in Sweden by Media-Tryck, Lund University
Lund 2021



Media-Tryck is a Nordic Swan Ecolabel certified provider of printed material. Read more about our environmental work at www.mediatryck.lu.se

MADE IN SWEDEN 

To my family

“Nothing worth having comes easy”

-Theodore Roosevelt-

Table of Contents

Abbreviations	8
Original Papers	9
Introduction	11
Abdominal aortic aneurysm disease	13
History	13
Aetiology	14
Epidemiology	15
Diagnosis	16
Invasive treatment	17
Open surgical repair.....	17
Endovascular aneurysm repair.....	18
Post-operative imaging surveillance.....	19
Fenestrated aortic stentgrafts	21
History	21
Stentgraft material and design	22
Sealing zones and endoleak.....	26
Aims	29
Material and methods	31
Patients	31
Stentgrafts	31
Imaging and measurements	32
Statistics.....	32
Ethical aspects	32
Results	35
Paper I.....	35
Paper II	36
Paper III.....	38

Paper IV	40
Discussion	43
Conclusions.....	47
Future perspectives.....	49
Populärvetenskaplig sammanfattning	50
Samantekt á Íslensku.....	52
Acknowledgements	55
References.....	57
Appendix.....	69

Abbreviations

AAA	Abdominal aortic aneurysm
BEVAR	Branched endovascular aortic repair
CBCT	Cone beam computed tomography
CMD	Custom made device
CT	Coeliac trunc
CTA	Computed tomography angiogram
DSA	Digital subtraction angiography
DUS	Doppler ultrasound
EL	Endoleak
EVAR	Endovascular aortic repair
ESVS	European Society for Vascular Surgery
FEVAR	Fenestrated endovascular aortic repair
FU	Follow-up
GFR	Glomerular filtration rate
ICU	Intensive care unit
IMA	Inferior mesenteric artery
IV	Intravenous
jAAA	Juxtarenal abdominal aortic aneurysm
OSR	Open surgical repair
OTS	Off-The-Shelf
rAAA	Ruptured abdominal aortic aneurysm
SMA	Superior mesenteric artery
TV	Target vessel

Original Papers

This thesis is based on the following papers, referred to hereafter by their Roman numerals:

- I. Sveinsson M, Sobocinski J, Resch T, Sonesson B, Dias N, Haulon S, Kristmundsson T. Early versus late experience in fenestrated endovascular repair for abdominal aortic aneurysm. *J Vasc Surg.* 2015 Apr;61(4):895-901
- II. Sveinsson M, Kristmundsson T, Dias N, Sonesson B, Mani K, Wanhainen, Resch T. Juxtarenal endovascular therapy with fenestrated and branched stent grafts after previous infrarenal repair. *J Vasc Surg.* 2019 Dec;70(6):1747-1753
- III. Sveinsson M, Sonesson B, Dias N, Björse K, Kristmundsson T, Resch T. Five year results of off the shelf fenestrated endografts for elective and emergency repair of juxtarenal abdominal aortic aneurysm. *Eur J Vasc Endovasc Surg.* 2021 Apr;61(4):550-558
- IV. Sveinsson M, Sonesson B, Kristmundsson T, Dias N, Resch T. Long-term outcomes after FEVAR for juxtarenal aortic aneurysm. *Manuscript, submitted.*

Papers are reprinted with permission from respective publishers.

Introduction

The aorta is the largest artery in the human body. It arises from the base of the heart and runs its course longitudinally through the torso, delivering oxygenated blood to the rest of the body and so sustaining life in all body parts and organs. As in all blood vessels, the tubular wall of the aorta is comprised of three layers, the innermost intima, the media, and the enveloping adventitia.

Aneurysm formation has been described in most large arteries of the body. The formation of an aneurysm of the abdominal aorta has wide implications and can develop into a life-threatening situation in the advent of a rupture. When rupture occurs great volumes of blood are lost from the circulation which in many cases is instantly lethal. Great progress has been made in the recent decades regarding diagnosis and treatment as well as understanding the underlying pathology and risk factors involved. An aneurysm can form anywhere along the aorta, but is most commonly localized in the abdominal part of the vessel. Roughly half of abdominal aortic aneurysms form below the arterial branches that supply abdominal organs such as liver, spleen, intestines and kidneys with blood. The other half have more complex anatomy and form close to, or directly involve these visceral branches which calls for more extensive and complicated treatment strategies.

Invasive or surgical treatment of aortic aneurysm disease is primarily aimed at preventing a rupture of the vessel, or the life-saving containment of a bleeding should rupture occur. Different treatment modalities are available, but they share the common purpose of effectively replacing the vessel wall of the affected aortic segment with a prosthetic graft, thus relieving the strain of systolic blood pressure to which all arteries of the body are ceaselessly subjected. These aortic grafts can be produced from a variety of materials but are primarily manufactured from synthetic fabric.

One treatment option is endovascular aortic repair (EVAR). This minimally invasive method involves placing an aortic prosthesis in the site of the aneurysm through percutaneous access to the arterial system via the groin vessels. The minimally invasive nature of the procedure adds to its attractiveness for both patient and physician. This methodology for treating aortic aneurysms has evolved tremendously in the past decades, and recent studies have showed some favourable outcomes when compared with the more traditional open surgical approach. Furthermore, this principle of treatment has been implemented in the management

of complex aneurysm disease with the addition of fenestrations to the design of the prosthesis, through which blood flow to the abdominal organs is secured. This treatment method is called fenestrated endovascular aortic repair (FEVAR).

The aim of this thesis was to investigate the feasibility of FEVAR in treating abdominal aortic aneurysm disease by scrutinizing device design and patient outcomes after treatment.

Abdominal aortic aneurysm disease

History

Due to the outstanding preservation techniques practiced in Egypt 3500 years ago studies have revealed that arterial calcification was not uncommon in the region, and even earlier papyrus writings suggest the identification of aortic aneurysm formation by contemporary physicians¹. Records describe surgical treatment for aortic aneurysms in Greece as early as the 2nd century AD, with ligatures applied to the arteries entering and leaving the aneurysm and subsequent evacuation of the aneurysm contents but leaving the sac in place^{2, 3}.

The formation of an aneurysm (the dilation of an artery) was a known affliction through the centuries to come but reasonable attempts to find a cure or effective treatment did not emerge until the middle of the 20th century. The term aortic aneurysm was introduced to western medicine by Paré and Vesalius in the mid sixteenth century⁴. Some 200 years later physicians began to give serious thought to definitive treatment options to prevent rupture of aortic aneurysms. The earliest attempts were concentrated on exclusion of the aneurysm from active circulation. The combination of both proximal and distal ligation of the aneurysm proved most successful but inevitably rendered patients vulnerable for severe ischemia in the lower extremities⁵. Some attempts to induce coagulation inside the aneurysm were made, often by introducing metal wire and electrothermic coagulation, with varying success^{6, 7}. The principal of stimulating perianeurysmal fibrosis with cellophane wrapping of the aorta gained some foothold later on^{8, 9}. The results were surprisingly good albeit unpredictable.

Direct surgical repair began to evolve after the pivotal work of Matas in 1888 when he described *obliterative endoaneurysmorrhaphy*, an approach based on conserving arterial lumen with intravascular suturing of arterial openings inside the aneurysmal sac¹. Subsequently he described a reconstructive technique of excising parts of the aneurysm wall and restoring continuity of the vessel with *arterioraphy* using the remaining arterial tissue^{10, 11}. His efforts paved the way for Carrel and Guthrie³ who shortly thereafter began experimenting with aortic repair using homografts and vascular anastomoses. With further advancements in homograft preservation methods the stage was set for modern open surgical aortic repair.

The first successful repair of an abdominal aortic aneurysm with human homograft replacement was performed by Dubost in 1951¹². After this pivotal case, numerous reports of operations with successful outcome saw the light of day in the following years¹³⁻¹⁶. In the wake of these events the hunt for suitable synthetic materials to replace homografts as a base for aortic reconstruction led to the development of the elasticized woven Dacron graft still used in open surgical aortic repair (OSR) to this day.

The minimally invasive approach to managing aortic aneurysm disease emerged with the introduction of Endovascular Aortic Aneurysm Repair (EVAR) described by Parodi in 1991¹⁷. He demonstrated how blood flow through the aorta can be maintained while excluding the aneurysm by using a Dacron tube with a metal scaffolding introduced using cannulation of the common femoral artery. Ironically the discovery had already been made by Volodos in 1986¹⁸, but never reached the community of western medicine due to geographical and linguistic barriers. In the three decades that have passed since EVAR has gained a decisive worldwide foothold in the management of aortic aneurysms with steadily growing experience in device design, patient selection and operative techniques¹⁹⁻²¹.

Aetiology

An abdominal aortic aneurysm (AAA) is defined as a focal and persistent dilation of the vessel beyond 150% of the diameter of an adjacent healthy vessel segment²², or more practically a >30 mm dilation of the artery^{23, 24}. Direct external and environmental factors such as arterial inflammatory disease, connective tissue disorders and trauma account for a small portion of AAAs, while the remaining majority constitute degenerative AAAs²⁵. The degenerative formation of an AAA is a complex multifactorial process of which the exact mechanism is not well understood, but it is generally accepted that inflammation and matrix degeneration in the media combine in a resulting weakening of the vessel wall which ultimately leads to dilation^{26, 27}. Degradation of elastin and collagen as well as apoptosis of smooth muscle cells in the media, driven by the release of proteolytic enzymes such as metalloproteinase from white blood cells, affects the structural integrity of the vessel wall rendering it unfit to combat the strain of systemic blood pressure^{25, 28}. Studies have shown significantly greater metalloprotease activity in the distal parts of the aorta compared to more proximally, partly explaining why AAA is five times more likely than thoracic aneurysms²⁹.

All parts of the aorta are subject to aneurysm formation. Formation below the diaphragm is collectively called abdominal aortic aneurysm. An AAA located exclusively below the renal arteries is referred to as infrarenal, while AAAs close to or involving the level of the renal arteries are known as juxtarenal and pararenal

respectively. Suprarenal AAA refers to aneurysm formation that proximally exceeds the level of the splanchnic arteries³⁰.

True aortic aneurysms can vary in morphology, generally divided into fusiform (95%) and saccular aneurysms (5%)³¹. A widely accepted hypothesis states that saccular aneurysms have a different aetiology, related to localized infection, atherosclerotic plaque instability or trauma, and are more prone to rupture³². Evidence for this is however not undisputed³³.

Epidemiology

Figures on the prevalence of AAA rely heavily on studies predominantly including men due to higher incidence among members of the male gender. The incidence of AAA has been decreasing in the last 30 years owing to less smoking and healthier lifestyle. Prevalence differs in geographical regions of the world, probably due to differences in exposure to risk factors³⁴. According to recent studies the prevalence in Sweden is 1.5-2.6% in men at the age of 65^{35, 36}.

A number of independent risk factors for the development of AAA have been identified. The most common risk factors are history of smoking, age, male gender, family history, hypertension, hyperlipidaemia, obesity and chronic obstructive pulmonary disease (COPD)^{34, 37, 38} while protective factors include black race, Diabetes Mellitus and regular exercise³⁹. Recent studies have shown that smoking or a history of smoking increases the risk of aneurysm formations as high as elevenfold^{35, 37}, and men are six times more likely to develop AAA compared to women^{35, 40}.

Studies have shown a mean annual aneurysmal growth rate of 1.2 – 3.6 mm/year, and the growth rate seems to increase exponentially as the aneurysm diameter increases^{26, 37}.

It is estimated that mortality rate for patients with ruptured AAA (rAAA) is 65-85%⁴¹⁻⁴³, and about 4-600 persons die due to rAAA in Sweden each year^{35, 36}. The risk of rupture is associated with maximum AAA diameter. Estimations indicate a yearly risk of approximately 1%, 3%, 4% and 6% in AAAs of 40-54 mm, 55-60 mm, 60-70 mm and respectively⁴⁴⁻⁴⁶, although the estimated risk of rupture for AAA ≥ 70 mm has been reported to be as high as 30%⁴⁷. Mortality associated with rAAA in developed countries has been declining in recent years due to healthier living standards, technical advances, better pre- and post-operative management and the introduction of screening⁴⁸. Although the overall incidence of AAA is lower among females, studies have shown up to fourfold rupture rate in women^{49, 50} highlighting the need for further focus on gender differences in the natural history of AAA.

Diagnosis

The majority of AAA are asymptomatic and accidentally diagnosed. Symptoms of AAA include pulsating abdominal mass and/or abdominal, back or flank discomfort or pain^{25, 51}. These symptoms may be due to aneurysmal pressure on adjacent retroperitoneal structures, inflammation, rapid AAA growth or rupture. Additionally, an AAA may cause indirect symptoms such as embolic events in the lower extremities, heart failure due to aortocaval fistula or lower extremity oedema due to compression of the inferior vena cava²⁸. However, the clinical diagnosis of AAA is often hard with physical examination alone since symptomatic aneurysms are uncommon. It is estimated that 66-75% of AAA are asymptomatic⁵².

Ultrasonography is a safe and readily accessible method for initial assessment and follow-up surveillance of AAA, as well as for screening purposes²⁵, and is generally the method of choice in these regards. With reported 95-100% sensitivity and close to 100% specificity, DUS is an excellent tool for initial evaluation of AAA size in anteroposterior, transverse and longitudinal dimensions⁵³⁻⁵⁵. The imaging modality has certain limitations. Results of DUS are equipment- and operator-dependent, and factors such as abdominal girth and bowel gas hamper diagnostic capacity in up to 2% of cases^{56, 57}.

As aneurysm diameter progresses to the level of treatment indication, CTA is usually the preferred imaging modality to more closely assess the size and anatomy of the aneurysm as a part of pre-operative planning⁵⁸⁻⁶¹. CTA has also been shown to be highly effective in the diagnosis of rAAA⁶². This imaging method requires the administration of IV contrast medium to enhance the lumen of the vessel, and offers an excellent platform for mapping and measurement of aneurysm morphology. Images can further be reconstructed in dedicated three-dimensional computer software to produce a longitudinal centre-line through the entire aorta, providing valuable aid for the surgeon in the choice of optimal treatment strategy^{63, 64}.

Early detection of AAA through screening programmes is an effective way of reducing mortality⁶⁵. An AAA-screening programme was launched in 2006 in Sweden, reaching nation-wide coverage in 2015³⁶. A similar programme was implemented in the UK in 2009⁶⁶, and various AAA-screening programs exist in the United States as well^{67, 68}. An early diagnosis of AAA greatly improves the possibility of prophylactic treatment and thereby reducing the incidence of often fatal aneurysm rupture^{67, 69}. In Sweden all men are invited to a single DUS scan at the age of 65. Attendance between 2006 and 2014 was 84% and it is estimated that 90 premature deaths are avoided yearly³⁶.

Invasive treatment

As the aneurysm diameter increases, a threshold is eventually reached when the risk of aneurysm rupture surpasses the risks involved with invasive treatment. Earlier, aortic reconstruction was considered feasible at a cut-off point of 5 cm AAA diameter. In the wake of the UKSAT trial⁷⁰ and the ADAM trial⁴⁵, both concluding no benefit of intervention over surveillance of small AAAs, a more standardized conformity among physicians began to take shape⁷¹⁻⁷³. Current guidelines recommend invasive management of asymptomatic fusiform AAA at a maximal diameter of >55 mm for men and >50 mm for women^{40, 74}. Two main methods of invasive treatment AAA are practiced to varying degrees depending on local traditions and available resources; open surgical repair and endovascular aneurysm repair.

Open surgical repair

In OSR a large abdominal incision is performed under general anaesthesia to access the abdominal cavity and the retroperitoneal space. After cross-clamping the aorta superiorly and inferiorly to the aortic aneurysm, a graft is sutured in place of the aneurysm to provide a stable and durable artificial substitution for the diseased portion of the vessel and thus alleviating the risk of rupture (figure 1). This procedure is among the most trying interventions in medical practice for the individual to be treated, with reported peri-operative mortality 2.7-5.7%^{75, 76}, and is highly resource consuming in terms of hospital care and long patient convalescence. The risk of peri-operative morbidity and mortality is elevated in the case of

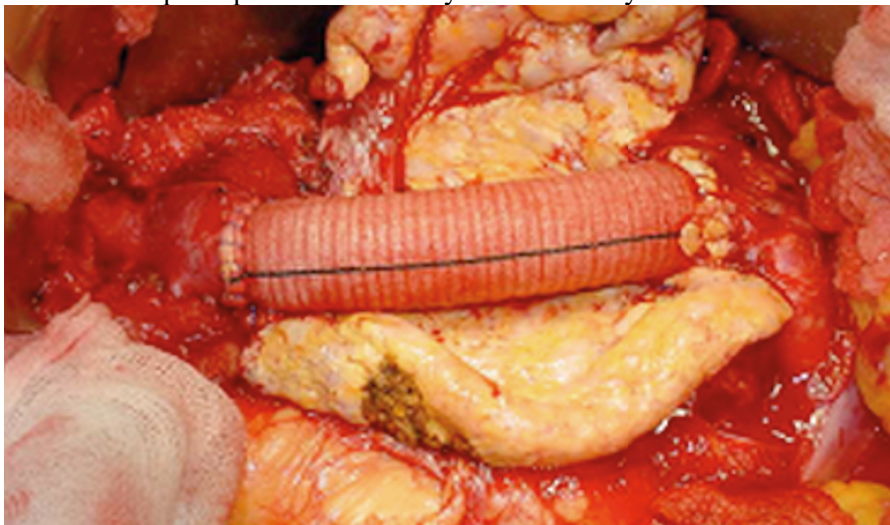

Figure 1. Open Surgical repair.
A woven Dacron graft is sutured end-to-end, replacing the AAA.

juxtarenal- and pararenal AAA surgery, where the level of cross-clamping may temporarily result in restricted blood-flow to viscera and kidneys during surgery. Visceral and renal arteries may in some cases need reimplantation for complete aneurysm repair with a risk of renal function impairment and bowel ischemia⁷⁷.

Endovascular aneurysm repair

EVAR is a minimally invasive method of managing AAA and has increasingly been implemented around the world in the last three decades. With the Seldinger-technique⁷⁸ access is gained to the arterial system bilaterally through the CFA. A multi-modular endovascular graft system is then introduced and deployed trans-luminally at the site of AAA using fluoroscopic guidance with DSA, thus reinforcing the vessel wall (figure 2). Great care must be taken to ensure adequate adhesion of the graft system to a healthy aortic segment both proximally and distally to the AAA to secure total exclusion of the aneurysm from pressurized blood-flow. Standard-EVAR requires >15 mm healthy aortic segment below the level of the renal arteries to achieve an adequate proximal seal.

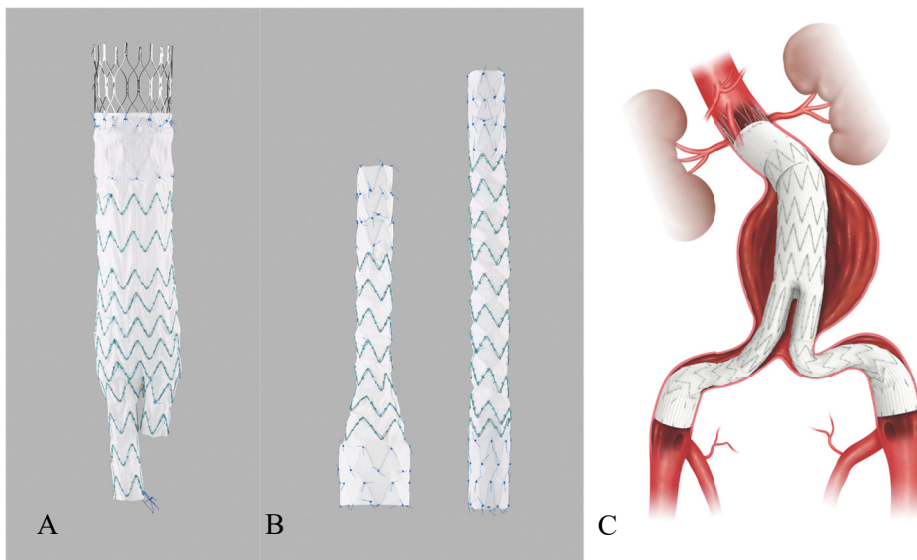


Figure 2. EVAR.

Figures of the infrarenal main component (A), iliac leg extensions (B) and the complete EVAR system after deployment (C).

Aneurysm neck-anatomy (distance from lowest renal artery to aneurysm sac) plays a significant role in the invasive management of AAA disease. Neck length of <10 mm, neck angulation of >60°, conical shape and high degree of calcification or thrombus is considered unfavourable⁷⁹, although the requirements of different devices vary. These factors increase the complexity of the aneurysm, and thus the

choice of treatment strategy. Studies on AAA neck suitability for infrarenal endovascular repair differ, with reports of 40-65%⁸⁰⁻⁸⁴ depending on patient gender and choice of device.

The endovascular management of complex AAAs with FEVAR is based on the same principles as EVAR, but requires an endograft modified with fenestrations in the graft fabric to ensure unrestricted blood-flow to visceral and renal arteries, as the level of proximal sealing of the graft involves the take-off of these vessels to varying degrees⁸⁵. The graft fenestrations are in turn fitted with smaller stentgrafts protruding from the TV into the main aortic component to ensure total aneurysm exclusion and uninterrupted blood-flow to the end organ. Treatment with FEVAR comes with a specific set of challenges in terms of pre-operative planning and technical difficulties during deployment. Studies have reported mid-term re-intervention rates of 6.7-16.4%⁸⁶⁻⁹⁰ and 1.5-5.2% mortality^{88, 91-93} after FEVAR for jAAA. Issues regarding TV patency are a particular concern as they constitute a notable share of re-interventions. Studies have reported freedom from TV loss of 89-91%^{88, 94, 95} after 5 years. Impairment of renal function is another concern after treatment of jAAA due to manipulation of the renal arteries. Not only are the kidneys subjected to nephrotoxic contrast medium during endovascular procedures, but the multitude of guidewires and catheters used during FEVAR can inflict physical damage to the vessels resulting in diminished blood-flow. Reported incidence of declining renal function after FEVAR is 17-29% of cases over time⁹⁵⁻⁹⁹.

Post-operative imaging surveillance

CTA has traditionally been the modality of choice in radiologic post-operative surveillance after FEVAR¹⁰⁰ and remains the gold-standard with good inter-observer reproducibility^{101, 102}. The modality provides detailed images in terms of aneurysm sac diameter and morphology, stentgraft performance and endoleak¹⁰³⁻¹⁰⁵. Imaging with CTA comes however with drawbacks. It is costly and exposes the patient to ionizing radiation¹⁰⁶ and nephrotoxic contrast medium¹⁰⁷. Estimates indicate that 1.5-2.0% of all cancers developed in the United States may be attributable to radiation from computed tomography scans¹⁰⁸.

Fenestrated aortic stentgrafts

History

Real progress in the successful surgical management of aortic aneurysm diseases did not emerge until the 1950s with the introduction of the synthetic vascular graft^{12, 109}. OSR remained the standard of care for several decades until the independent simultaneous discoveries of great minds around the world led to the birth of EVAR¹¹⁰. Based on the pivotal work of Charles Dotter performing the first transluminal angioplasty of a femoral artery in 1964¹¹¹, innovation towards endovascular treatment of aortic lesions began to take shape. After years of preclinical experiments, histological research and durability calculations Volodos and his team performed the first EVAR in a human patient successfully treating a thoracic aneurysm in 1991¹¹², and subsequently implementing the technique to successfully treat an AAA with EVAR in 1993¹¹³. Concurrently and independently, the vascular surgeon Parodi had also been experimenting with stentgraft design, and went on to successfully treat a patient with AAA in 1991¹⁷. In the wake of these events the technique spread rapidly, and the first EVAR procedure using an aorto-uni-iliacal design was performed by Ivancev et al in Malmö in 1993¹¹⁴. Due to the fact that abdominal aortic aneurysm diseases often extends to involve the distal aorta and proximal iliac arteries, and thus rendering straight tubular endografts ineffective for complete aneurysm exclusion, efforts quickly arose to design branched endografts extending to the iliac arteries. This resulted in the first multi-modular aorto-bi-iliac stentgraft, the Zenith endograft from COOK inc (Bloomington, IN, USA)¹¹⁰. In addition to the tendency of distal extension of AAA, aneurysms often extend proximally to involve the infrarenal neck (jAAA) or even include the renal arteries (pararenal AAA). With increasing usage and improved techniques it became apparent that further innovations were needed to preserve perfusion to the aortic branches when managing these complex aneurysms. This gave rise to the implementing of fenestrations in the fabric of stentgrafts. The procedure was first described by Park et al in South Korea¹¹⁵ and the first successful FEVAR was performed on a patient with jAAA by Andersson in Australia in 1998¹¹⁰. In Malmö Vascular Center, FEVAR was started in late 2002⁹⁰, and has with increasing experience become the standard of care for complex AAAs. Moreover, FEVAR has increased significantly worldwide in the past decade, particularly in the wake of the approval of the Zenith® fenestrated AAA endovascular graft in the European Union

in 2005 and the United States in 2012. The current ESVS guidelines support FEVAR as the primary choice in elective jAAA repair⁴⁰.

Stentgraft material and design

There are currently two different fenestrated CMDs commercially available, the COOK Zenith[®] fenestrated device (used in all papers included in this thesis) and the Fenestrated Anaconda[™] device (Terumo Aortic, Inchinnan, Scotland, UK). Studies have shown good short- and long-time results after treatment with the Anaconda device^{99, 116-120}, although issues with graft limb thromboses and early type I EL have been reported. For the purposes of this thesis, main focus will be on the COOK Zenith[®] fenestrated and branched AAA endovascular grafts.

The full Zenith[®] fenestrated stentgraft system (figure 3) is comprised of three components; the fenestrated main body graft, the bifurcated unibody graft and one iliac leg extension graft. The grafts are made of woven polyester sutured to a scaffolding of self-expandable steel stents ensuring that the device takes a native tubular shape once released from its delivery system inside the AAA. The radial force of the stents ensures a tight seal between the graft and healthy vessel wall as well as the between the overlapping material of the joining components, thus facilitating a total exclusion of the aneurysm. In addition, the top stent is free from graft material and fitted with outwards-facing barbes that effectively latch on to the inside of the vessel wall reducing the risk for device migration after deployment¹²¹.

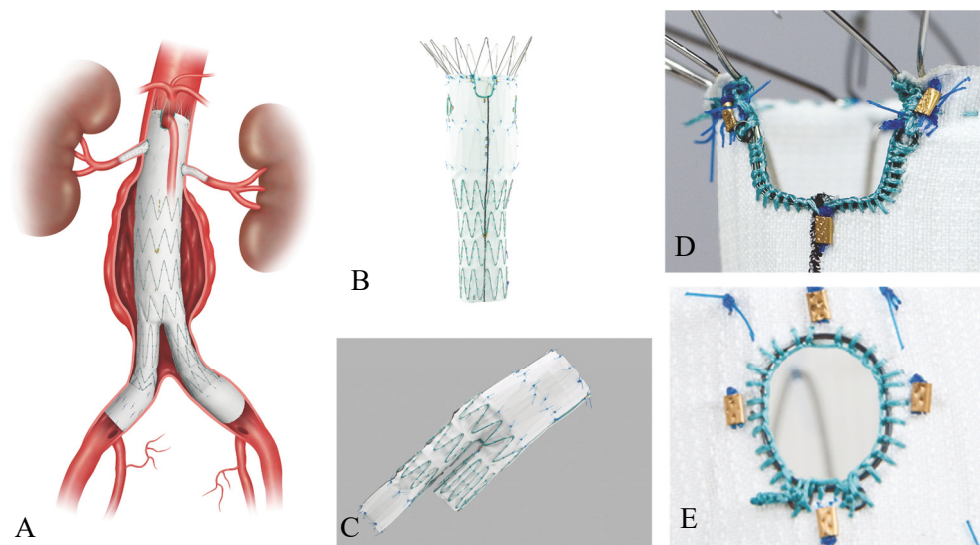


Figure 3. FEVAR.

Figures of the Zenith fenestrated system. Complete FEVAR after deployment (A), fenestrated main body (B), the bifurcated unibody (C), scallop (D) and fenestration (E).

Fenestrations (holes) or scallops (cut-outs) in the graft fabric are located on the proximal portion of the main body graft, reinforced with nitinol rings and indicated with radio-opaque markers. The precise location of the fenestrations is uniquely tailored to the anatomy of the aneurysm to be treated in each individual case, since they have to fit the exact position of the ostium of the TV to which blood-flow must be preserved. A smaller stentgraft is usually placed in the TV through the fenestration to channel the uninterrupted flow directly to the TV without leakage into the aneurysm sac outside the stentgraft system. A tight seal between the TV stent and the fenestration is accomplished by inflating a balloon in the junction.

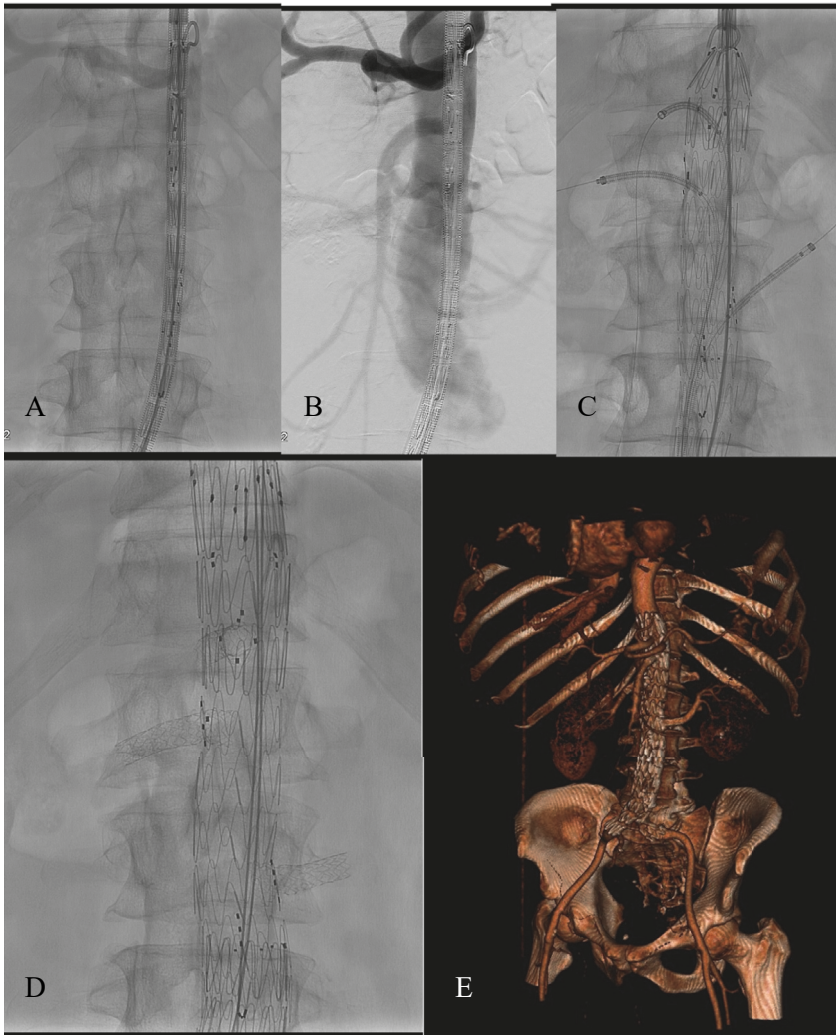


Figure 4. The procedure of FEVAR.

The fenestrated main body folded inside the delivery sheath (A), orientation of the fenestrated graft using digital subtraction angiography (B), placement of introducer sheaths into target vessels (C), fully deployed system with TV stentgrafts in place (D) and post-operative computed tomography reconstruction (E).

When the fenestrated main body has been deployed and all respective TVs stented (figure 4), the system is extended distally with the bifurcated unibody and iliac leg extension to complete the exclusion of the aneurysm. All junctions between the stentgraft system and healthy aortic segments as well as overlaps between system components are finally dilated with a large balloon to ensure a tight fit.

Due to the individually tailored nature of CMDs their designing process and delivery can take up to 6-8 weeks, limiting their use to elective aneurysm repair. In the case of more urgent treatment, such as symptomatic aneurysms, rapidly growing aneurysms or ruptures, OTS devices such as the p-Branch and the t-Branch were developed. These devices are designed with standardized configurations of scallops, fenestrations or branches to accommodate as many anatomic aneurysm variations as possible, and thereby readily available “off-the-shelf” in cases requiring emergent treatment of complex AAAs¹²².

The p-Branch device from COOK Medical (figure 5A) is based on the Zenith platform and is as of yet not commercially available. It is designed with a scallop for the CT and fenestrations for the SMA and renal arteries¹²²⁻¹²⁴. The SMA fenestration serves as the reference point to which the remaining fenestrations are measured and plotted on a grid (figure 5B). The renal fenestrations have preloaded guidewires and a funnel shaped pivoted design, with two nitinol rings interlocked by fabric, allowing for a certain degree of movement to adjust the fenestration to adequately fit the ostium of the TV (figure 6). This device is available in two different configurations, A and B, and has been shown to be anatomically applicable in 50-75% of jAAAs¹²⁵⁻¹²⁸. Early and intermediate results support the safety and feasibility of the p-Branch device^{122, 123}.

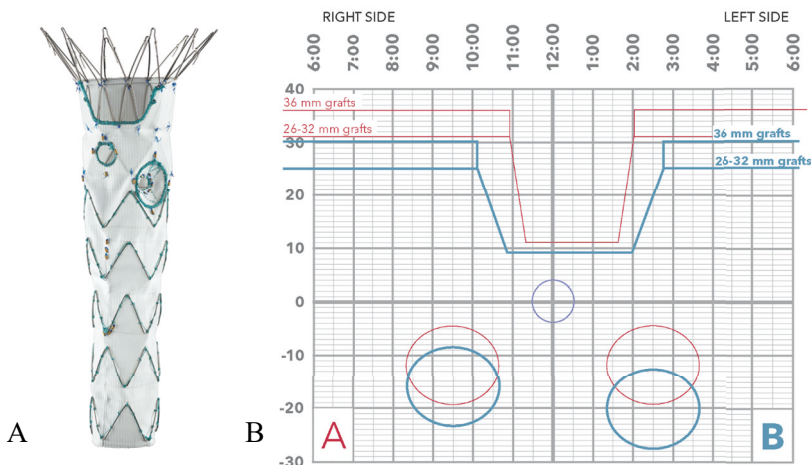


Figure 5. The COOK Zenith® p-Branch device and planning grid.

Figures of the p-Branch fenestrated device (A) and the planning grid for measurements of suitability (B).

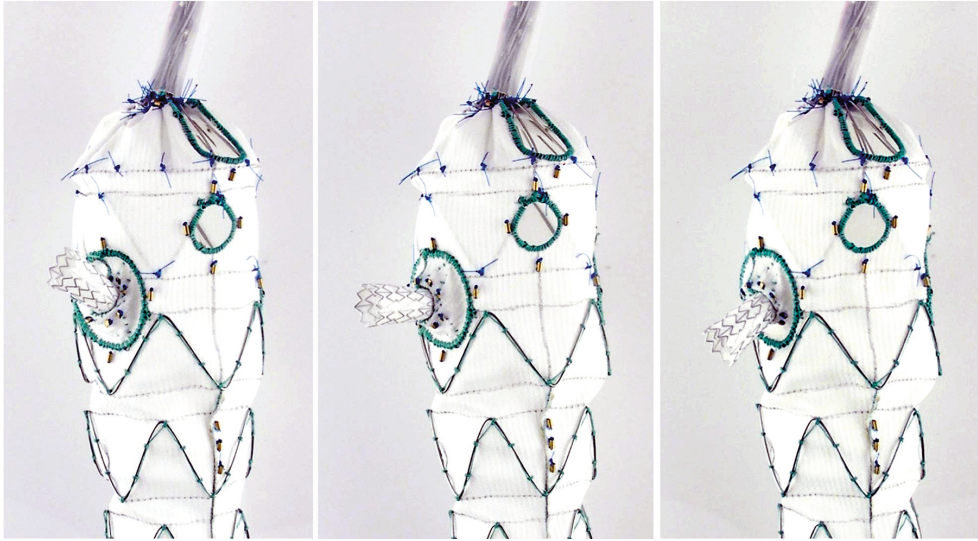


Figure 6. The COOK Zenith® p-Branch with a stented pivot renal fenestration.
Courtesy of COOK Medical inc.

The Zenith® t-Branch™ OTS device (figure 7) was launched in 2012 and is primarily intended for management of TAAA¹²⁹. Thus, its sealing zone extends proximally to the distal descending aorta. The device is designed with side-branches for all four TVs of the visceral segment of the vessel and through these the TVs are cannulated and stented to ensure uninterrupted blood-flow to the abdominal viscera and kidneys¹³⁰⁻¹³². The device is designed to ideally leave a 1-2 cm gap between a side-branch and its corresponding TV to facilitate cannulation. Reports indicate that the t-Branch endograft is safe¹²⁹ and applicable in 65-80% of thoracoabdominal aneurysms^{133, 134}. A recent meta-analysis of 7 studies with mean FU of 6-43 months reported a pooled rate of 93% technical success and 6% mortality rate after elective and urgent treatment¹³⁵.

Similarly to the Zenith Fenestrated device, the p-Branch and the t-Branch devices are extended distally with a bifurcated unibody and iliac leg extension for complete exclusion of the aneurysm.

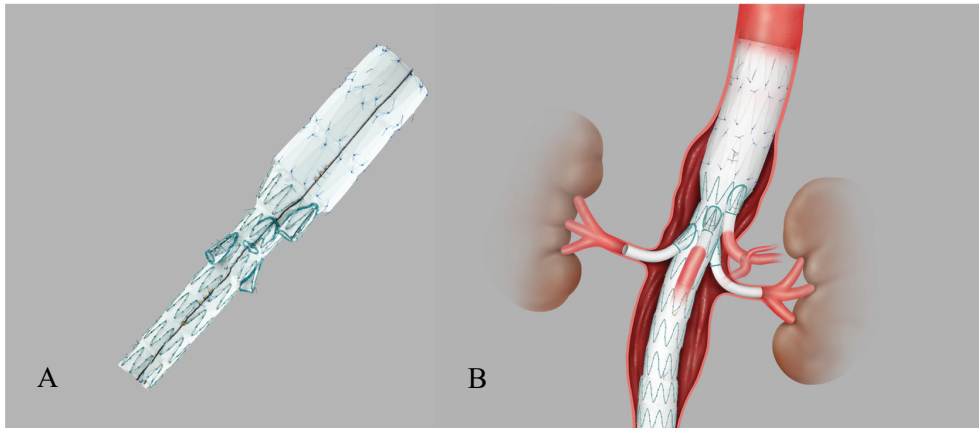


Figure 7. The COOK Zenith® t-Branch™ device.

The t-Branch main body device (A), and t-Branch after deployment of main device and branch stentgrafts.

Sealing zones and endoleak

Successful exclusion of the AAA by the stentgraft system is crucial. This is only achieved through absolute adhesion between stentgraft and healthy aorta both proximally and distally to the aneurysm itself, as well as between the different components of the completed stentgraft system. The instructions of use for Zenith® AAA systems dictate a proximal sealing zone >15 mm between the stentgraft and a healthy aortic segment, and distally a minimum of 10 mm in the distal iliac arteries. When all components have been placed in their respective locations with adequate overlap between the conjoined components, a large balloon is inflated in all sealing zones securing that all graft components are tightly conjoined, eliminating all pressurized blood-flow from the weakened aneurysm wall. Failure to do so may result in endoleak (EL) and continued strain on the vessel wall with a risk of rupture¹³⁶. EL is one of the main causes for late rupture after endovascular aneurysm repair¹³⁷, and reports show that 13-28% of re-interventions after FEVAR are EL related^{138, 139}.

Table I illustrates the different types of EL. Type 1 EL refers to leak between the graft fabric and vessel wall into the aneurysm sac, where type 1a refers to the proximal sealing zone and type 1b refers to the distal sealing zones in the iliac arteries. Type 2 EL is a retrograde leak from smaller branches in the AAA wall such as the IMA and lumbar arteries. Type 3 EL means leakage between graft components, and type 4 is a leak through the graft fabric, either as a lingering ooze between the woven filaments of the graft material (usually self-limiting) or due to a tear in the fabric¹⁴⁰. Additionally TV branch EL is described as type 1c if there is leakage into the aneurysm sac from the distal end of the TV stent, and type 3 if there

is a leak through a fenestration due to incomplete sealing between the main graft component and the TV stent³⁰.

Table 1. Different types of endoleak

AAA: abdominal aortic aneurysm, TV: target vessel, IMA: inferior mesenteric artery.

Endoleak	Description
Type 1	Flow into the AAA sac due to incomplete sealing. 1a proximal, 1b distal, 1c from TV
Type 2	Retrograde flow into the AAA sac from lumbar arteries, IMA or accessory renal arteries
Type 3	Flow into the AAA sac due to incomplete seal between graft system components
Type 4	Leak through the graft fabric

Aims

In the last decades endovascular means of treating AAA have taken a decisive role, shifting the focus from the more traditional method of OSR with robust evidence of comparable and even favorable outcomes regarding effectiveness and patient safety. About half of AAAs are complex with short or hostile neck anatomy, demanding new means of minimally invasive management. The development of fenestrated stentgrafts is under constant refinement to meet the needs of patients with complex AAA anatomy to provide an effective and sustainable repair with FEVAR, both elective and emergent.

The specific aims of this thesis were:

1. To evaluate the impact of experience of FEVAR on graft design and clinical outcome in patients with jAAA.
2. To evaluate short-term performance and outcome of fenestrated and branched stentgrafts when used as secondary proximal repair after previous infrarenal aortic reconstruction.
3. To evaluate the performance and long-term clinical outcome of the COOK Zenith[®] p-Branch device for jAAA in elective and emergent settings.
4. To evaluate the long-term outcome of FEVAR in patients with jAAA.

Material and methods

Patients

The majority of patients included in the studies in this thesis were treated in Vascular Center Malmö, with additions from other national and international hospitals in two studies. Paper I was a collaboration between Vascular Center in Malmö and Aortic Centre in Lille. Patients with jAAA deemed unfit or high risk for OSR or standard EVAR due to hostile aneurysm neck anatomy and treated with FEVAR between 2002 and 2011 were included in this retrospective study. Patients with thoraco-abdominal disease or with follow-up <12 months were excluded. Paper II was collaborative work in association with the department of vascular surgery in Akademiska Hospital in Uppsala Sweden. Patients receiving fenestrated or branched endografts as a secondary repair due to failing previous open or endovascular infrarenal repair between 2002 and 2015 were included. Patients with thoraco-abdominal disease were excluded. Paper III prospectively included patients meeting the inclusion criteria for the COOK Zenith® p-Branch device (appendix) treated electively and emergently from July 2012 to September 2015. Paper IV was a retrospective cohort study including patients with available FU data from the late-phase cohort from paper I treated at Vascular Center Malmö between 2007 and 2011.

Stentgrafts

The Zenith® Fenestrated AAA endovascular graft (COOK medical ltd., Perth, Australia) was used in all cases in papers I and IV. The Zenith® Fenestrated device and the Zenith® t-Branch® thoracoabdominal device were used in paper II. Paper III evaluated the Zenith® p-Branch device which was exclusively used in all cases. All beforementioned devices were completed with the Zenith® Universal distal body endovascular graft as well as appropriate Zenith® iliac leg extension stentgrafts, except for selected cases in paper II. All fenestration/scallop stents were covered and balloon-expandable. In the earliest treated patients in paper I, small fenestrations were selectively stented and scallops were left unstented. As the treatment experience grew, all fenestrations were progressively stented and scallops were selectively stented depending on TV anatomy and scallop fit. Technical

success was defined in accordance with the SVS/ICCVS reporting standards¹⁴⁰ in papers I-III, the and the SVS reporting standards for complex AAA³⁰ in paper IV.

Imaging and measurements

Pre-operative imaging consisted of CTA in all studies. The earliest scans performed on patients in paper I were selectively done with catheter directed contrast injection from an arterial groin access. As the technology progressed CTA scans with iv contrast injection from a hypodermic needle became standard. Pre-operative images were reconstructed with a mid-lumen center-line in a dedicated 3D-workstation for measurement purposes (*Aquarius iNtuition*, TeraRecon®, CA, USA). Infrarenal aneurysm neck anatomy was considered hostile if total length was <10 mm, conical in shape or if angulation between neck and aneurysm was >60°. In all papers, the Siemens Artis Zee fixed imaging system (Siemens Medical Solutions, Erlangen, Germany) was used for patient treatment in Vascular Center Malmö, and the same system was used at dep. of Vascular Surgery at Akademiska hospital in Uppsala in paper II. Treatment of patients in Lille France in paper I was performed with OEC 9900 Elite MD mobile C-arm (GE Healthcare, Buc, France). Imaging FU was with CTA as well as plain abdominal X-ray at 1 month (and 6 months in Lille, France) and 1 year post-operatively in paper I. In papers II and IV FU imaging with CTA and plain X-ray was at 1 month and one year post-operatively, and yearly thereafter. In paper III the same protocol was applied with a clinical evaluation at all intervals, with an additional control at 6 months post-operatively. Images were evaluated at the investigative site and by a centralized core laboratory.

Statistics

Statistical analysis was done in IBM® SPSS® Statistics versions 22-26 (SPSS Inc, Chicago, IL). In paper I one-way analysis of variance was used for continuous data, and for percentage comparisons the χ^2 test was used. $P < 0.5$ was considered significant. In papers I-IV continuous data was presented as mean (\pm standard deviation) or median (range). In papers II-IV survival, re-intervention free survival and TV patency were assessed with Kaplan-Meier analysis.

Ethical aspects

In paper I approval of institutional review board was waived as patients were treated under standard clinical practice. All patients gave informed for the procedure and

FU. Paper II was approved by the Regional Ethics Committees at Lund University (2014/732) and at Uppsala University (2017/027). Informed consent was obtained from all participating patients. Paper III was a physician sponsored study. COOK Medical inc. provided stentgrafts. The study was approved by the Regional Ethics Board at Lund University (2012/52) and all participating patients gave written consent. Paper IV was approved by the Regional Ethics Committee at Lund University (2014/732) and all participating patients gave informed consent.

Results

Paper I

A total of 288 patients were included, 100 in the early phase group and 188 in the late phase group. Patient age and comorbidities were not significantly different in the groups apart from the prevalence of hypertension (59% vs 78%, $p < 0.01$) and renal insufficiency (26% vs 14%, $p = 0.05$) as is shown in table II. Median follow up was 11.5 ± 2 and 11.7 ± 2 months in the early and late groups respectively. Mean number of employed scallops/fenestrations increased between the groups from 2.7 ± 0.8 to 3.2 ± 0.7 ($p < 0.001$), and more TVs were stented (64% vs 77%, $p < 0.01$). Technical success increased from 92% to 98%. Procedure time was unchanged, but fluoroscopy time and iodine load both decreased by 20% (table III). Less use of contrast media did however not result in better plasma creatine levels at patient discharge. Operative mortality was unchanged between the two groups (2% vs 2.1%, $P = \text{NS}$), and there was no significant difference in AAA related mortality (3% vs 3.2%, $p = \text{NS}$) nor overall mortality (4% vs 7%, $p = \text{NS}$). There was no significant difference in the ratio of decreasing aneurysm diameter at one year (54% vs 62%, $p = 0.3$), and the frequency of reinterventions and EL was not significantly changed (table IV).

Table II. Patient demographics

AAA: abdominal aortic aneurysm, COPD: chronic obstructive pulmonary disease, GFR: glomerular filtration rate, CVI: cerebrovascular insult, NS: not significant. Early and *late* denote early and late groups.

	Early, %	Late, %	P
Male	91	87	ns
Age (years)	72 ± 7	72 ± 7	ns
AAA diameter (mm)	58.9	59.3	ns
Smoking	82	79	ns
Hypertension	59	78	< 0.01
Diabetes	18	17	ns
Coronary heart disease	49	47	ns
COPD	39	37	ns
Renal failure (GFR < 60)	26	14	0.05
CVI	14	11	ns

Table III. Operative resultsNS: not significant. Early and *late* denote early and late groups.

	Early	Late	P
Procedure time (min)	276	280	ns
Fluoroscopy time (min)	84	68	0.05
Contrast volume (ml)	254	184	<0.05
Target vessels	2.7	3.2	<0.01
Stented target vessels	64%	77%	<0.01
30-day mortality	2.0%	2.1%	ns

Table IV. Results at 1-year follow-upAAA: abdominal aortic aneurysm, NS: not significant. Early and *late* denote early and late groups.

	Early, %	Late, %	P
Type I endoleak	1.2	1.0	ns
TV patency	98	98	ns
Re-interventions	8	12	ns
Decreasing AAA diameter	54	61	ns
AAA-mortality	3.0	3.2	ns
Overall mortality	4	7	ns

Paper II

43 patients were included, 37 (86%) male and 6 (14%) female. Indications for secondary proximal endovascular repair with F/BEVAR was type Ia EL (58%), proximal AAA or pseudo-aneurysm formation (30%) and migration of a previous EVAR system (12%). EVAR was the most common form of previous repair (75%). A fenestrated repair was used in 34 (79%) cases, a branched repair in 8 (19%) cases and in one case a hybrid graft with a branch for the CT and fenestrations for the SMA and renal arteries. A total number of 146 vessels (mean 3.4) were targeted of which 119 (82%) were stented. Technical success was 93%. Major complications were recorded in 20.9% of cases and minor complications in 16.3% in the first 30 days post-operatively. Mean hospital admission duration was 9 days (table V) and 70% of patients needed no ICU care. Median FU was 33 (range 3-120) months, and mean time from primary repair to secondary intervention was 59 (range 5-180) months. TV patency was 97.3% at one month and 95.2% at one year of FU. 12 (28%) patients needed reintervention during the FU period. Peri-operative and 1 year mortality was 0% and 4.7% respectively (table VI), and only one patient died of AAA related causes during the FU period.

Table V. Operative results
SD: standard deviation of mean

	Mean	+/- SD
Procedure time (min)	331	151
Fluoroscopy time (min)	104	36
Contrast load (g)	34.5	19.6
Fenestrations	3.4	
Stented target vessels	2.8	
Days in hospital	8.9	10.0

Table VI. Follow-up results
TV: target vessel, FU: follow-up

	n	%
Type I endoleak	3	7
TV patency	138/146	94.5
Re-intervention	12	27.9
30 day mortality	0	0
1 year mortality	2	4.7
FU time (mean months)	33	

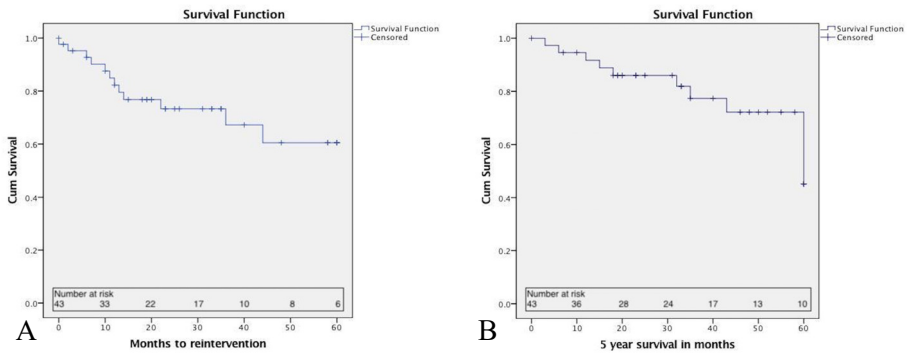


Figure 8. Kaplan-Meier estimates of re-interventions and survival
Time to first re-intervention in months (A), and all-cause mortality after 5 years (B).

Paper III

25 patients treated electively and emergently with the p-Branch device were included in the study. Two patients were subsequently excluded on anatomical grounds, one patient withdrew from the study and one patient was lost to FU. 23 patients were thus part of the peri-operative analysis and 21 patients completed FU. 12 cases were elective repair and 11 emergent. Table VII shows operative outcomes. Mean time to primary intervention was 67 (range 20-112) days in elective cases and 28 (range 0-122) hours in urgent cases. Device configuration A was employed in 15 (65%) of cases and configuration B in the remaining eight (35%) cases. Technical success was 91%. The most common post-operative adverse events were related to renal function with 3 (14%) patients suffering renal insufficiency during the study period. Two patients suffered a myocardial infarction and one developed transient bowel ischemia. No cases of spinal ischemia occurred. Primary TV patency was 98.8% at 30 days, 96.4% at one year, 95.2% at three years and 94.0% at five years, with assisted primary TV patency and secondary TV patency of 100% at all timepoints. 16 reinterventions were performed on 10 (48%) patients (figure 9a). Emergently treated patients were overrepresented, needing 11 reinterventions in 6 patients. The majority of reinterventions were due to TV instability and instability of the iliac extensions. All-cause mortality was 24% and there was no AAA- or procedure related mortality (figure 9b).

Table VII. Operative outcomes.

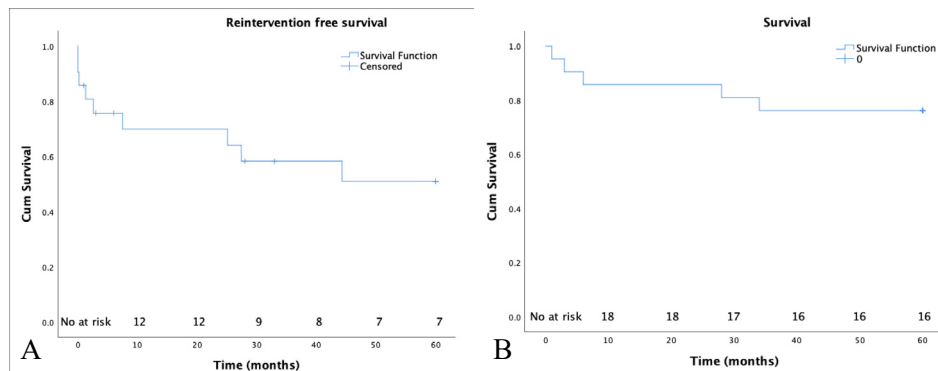
ICU: intensive care unit. Data are presented as *n* (%) or median (range).

	All patients (n = 23)	Elective patients (n = 12)	Emergent patients (n = 11)
Type of graft			
A	15 (65)	8 (67)	7 (64)
B	8 (35)	4 (33)	4 (36)
Blood loss (ml)	500 (200 - 1200)	500 (300-1000)	700 (200-1200)
Transfusion units	0 (0)	0 (0)	(0)
Procedure time (min)	283 (161 - 475)	266 (161-475)	284 (200-418)
Fluoroscopy time (min)	89 (47 - 170)	81 (47-170)	96 (48-126)
Contrast media dose (ml)	189 (81 - 332)	148 (81-294)	197 (98-332)
Technical success	21 (91)	12 (100)	9 (82)
Endoleak at completion			
1a	0 (0)	0 (0)	0 (0)
1b	0 (0)	0 (0)	0 (0)
2	3 (13)	2 (17)	1 (9)
3	0 (0)	0 (0)	0 (0)
Hospital days	8 (4 - 57)	6 (4-30)	14 (6-57)
ICU days	1 (0 - 22)	1 (0-1)	1 (0-22)

Table VIII. Follow-up outcomes.

AAA: abdominal aortic aneurysm. Data are presented as n (%), mean \pm standard deviation or median (range)

	Patients (n = 21)
Mean follow-up (months)	45 \pm 24.4
AAA diameter	
Increase >5 mm	1 (5)
Unchanged	7 (33)
Decrease >5mm	13 (62)
Device endoleak	
Type 1a	0 (0)
Type 1b	1 (5)
Type 2	6 (29)
Branch endoleak	
Type 1c	1 (5)
Type 3	2 (10)
Branch patency	
Occlusion	2 (10)
Stenosis	3 (14)
Device related outcomes	
Migration	1 (5)
Fracture	0 (0)
Graft limb occlusion	1 (5)
Days to reintervention (mean)	469 (0 - 1567)
Days to death (mean)	436 (35 - 1747)
All deaths	5 (24)
AAA related deaths	0 (0)



Paper IV

94 patients were included in the study, of which 24% were women and 76% were men. Median FU was 89 (range 0-152) months. 280 fenestrations/scallops were employed of which 205 were stented. Technical success was 89.4%. Primary TV patency was $94\% \pm 1\%$ at 1 year, $90\% \pm 2\%$ at 3 years and $89\% \pm 2\%$ at 5 years (figure 10), and assisted primary patency was 98.8% at 1 year, 98.4 at 3 years and 97.5 at 5 years. 70 reinterventions were undertaken in 37 (39.4%) patients of which 11 (16%) were prompted by endoleak, 27 (39%) were due to failed TV patency, 12 (17%) graft-limb related and 20 (29%) for other causes (table IX). Re-intervention free survival was $88\% \pm 3\%$ at 1 year, $70\% \pm 5\%$ at 3 years and $60\% \pm 5\%$ at 5 years (figure 11). Over-all survival was 39.4% with $95.7\% \pm 2.1\%$ at 1 year, $87.1\% \pm 3.5\%$ at 3 years and $71.0 \pm 4.7\%$ at 5 years (figure 12). 5 (5.3) patients died of AAA related causes. Aneurysm diameter was decreased or unchanged in 91% of cases. Mean GFR decreased from 59.2 ± 14.9 ml/min/1.73m² pre-operatively to 50.0 ± 18.6 ml/min/1.73 m² at end of FU, and 5 (5.3%) patients developed dialysis dependency during FU.

Table IX. Re-interventions.

Frequency of re-interventions performed with percentage prompted by findings on routine follow-up. AAA: abdominal aortic aneurysm, rAAA: ruptured abdominal aortic aneurysm, n: number of patients, FU: follow-up.

	n	Routine FU n (%)
Endoleak		
Type Ia	3	1 (33%)
Type Ib	3	3 (100%)
Type Ic	1	1 (100%)
Type II	3	3 (100%)
Type III	1	0 (0%)
Target vessel		
Stenosis	21	16 (76%)
Occlusion	6	2 (30%)
Limb		
Stenosis	7	7 (100%)
Occlusion	5	2 (40%)
Other		8 (40%)
Compartment syndrome	3	
Pseudoaneurysm	3	
Graft limb extension	3	
Seroma drainage	3	
Graft infection	2	
Guidewire perforation	2	
Completing renal stent	1	
Embolus from graft limb	1	
rAAA	1	
Proximal AAA formation	1	

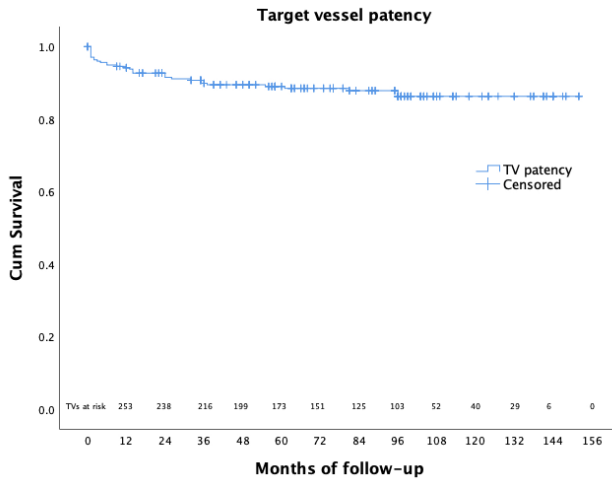


Figure 10. Kaplan-Meier estimate of primary target vessel patency during follow-up
TV: target vessel

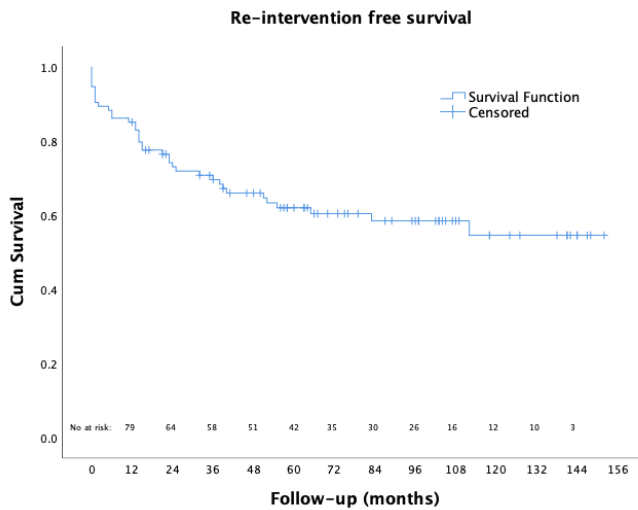


Figure 11. Kaplan-Meier estimate of re.intervention free survival.

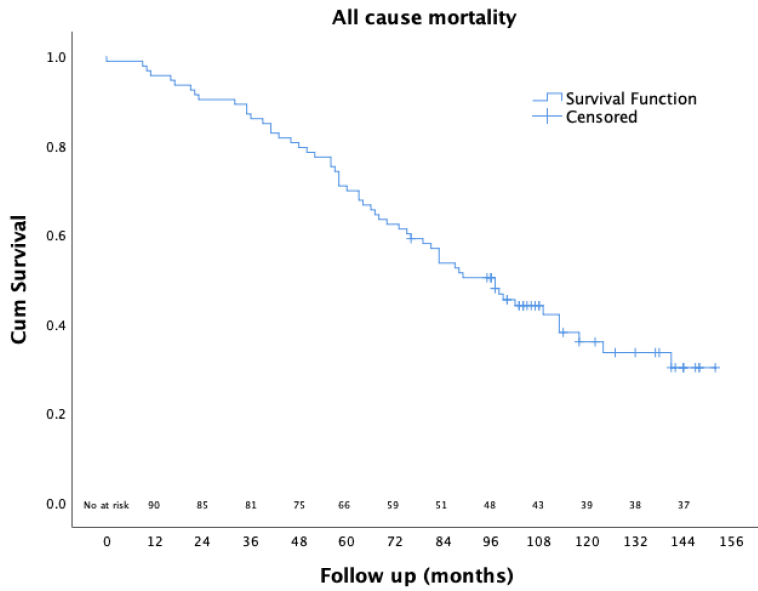


Figure 12. Kaplan-Meier estimate of all-cause mortality during follow-up

Discussion

Endovascular management of infrarenal AAA has been shown to be a safe and effective method of repair, with outcomes fully comparable to and in some regards even superior to OSR. The COOK Zenith® Fenestrated abdominal aortic endograft was made commercially available in Europe in 2005, and in 2012 in the United States¹⁴¹. In the following years its use has increased explosively, and FEVAR is now supported as the primary choice for managing jAAA⁴⁰.

Complex AAAs pose considerable challenges in endovascular repair as the proximal sealing zone involves the visceral segment of the abdominal aorta. Early on in our experience the technically challenging catheterization of TV was a limiting factor resulting in increased operative time, radiation time and contrast media volumes compared to infrarenal EVAR. With increasing experience however, we saw a significant reduction in these factors in spite of trends towards including more TVs. Increasing experience also revealed patency issues with unstented scallops, particularly for the SMA. Initially these were left unstented in the belief that accurate per-operative planning would render the scallop positioned correctly. It gradually became apparent that this was not to be taken for granted and operating surgeons increasingly opted to stent scallops as well to avoid post-operative instability in these TVs due to a shuttering effect of the device. Gradually a tendency to replace SMA scallops with large fenestrations evolved without affecting operative outcomes or long-term durability. Interestingly, incorporating a higher number of TVs did not lead to decreased type Ia EL, and TV patency remained unaffected when comparing long-term outcomes between patients treated early and late in our experience, casting some doubt on the value of this trend, although aneurysm sac shrinkage and survival improved.

Redo surgery is required in up to 10% of infrarenal aortic repair due to failing endografts or proximally advancing aneurysm formation¹⁴². OSR in these circumstances involves substantial trauma for the patient with high risk of procedure-related morbidity, and mortality rates have been reported to be 17-22%¹⁴²⁻¹⁴⁴. Similarly to primary repair of jAAA, an endovascular approach in secondary repair with F/BEVAR can be a feasible treatment option¹⁴⁵. It does however come with its own set of challenges. In paper II we experienced longer operating times and lower technical success rate compared to primary fenestrated repair with CMDs, as well as increased rates of type Ia EL and re-interventions. A number of factors likely contribute to these outcomes. Advancement of delivery

systems and catheters is hampered due to friction against pre-existing graft material which can cause difficulties in correctly orientating fenestrated grafts. This unwanted effect can be counteracted with a “trough-and-through” brachial-femoral access. TV orifices may be difficult to access due to crossing struts of an original EVAR system adding time-consuming technical challenges. This issue can be met with pre-operative angiography during which cannulation of TVs can be tested and stent struts bended if necessary, using balloon angioplasty¹⁴⁶. In our series 65% of cases were managed with a fenestrated or branched cuff only, resulting in an adequate seal between the cuff and the pre-existing infrarenal graft. In many cases however, a complete relining of the original repair with a complementary bifurcated aorto-iliac system is required to obtain sufficient distal sealing. Pre-existing grafts with a short main body may cause problems with delivery of bifurcated extensions, which can be overcome with an inverted contralateral limb¹⁴⁷. Accurate orientation and delivery of endovascular stentgrafts relies heavily on radio-opaque markers, the multitude of which can impede visualization of fenestrations as old and new grafts intersect in the field of vision. A preloaded fenestrated graft can be valuable in this regard, as the system comes with preloaded guidewires through the renal fenestrations. Introducers to the renal arteries are advanced over the wires and reach their target with relative ease facilitating cannulation of the TV effectively and safely¹⁴⁸. Secondary fenestrated and branched repair after previous infrarenal repair is a valid alternative to OSR, but detailed planning is essential to obtain good results.

For patients with jAAA in urgent need of repair, as is the case for rapidly growing AAA, symptomatic AAA or in the case of rupture, the time-consuming manufacturing and shipping of CMDs is a limiting factor. The COOK Zenith p-Branch device was developed to address this issue, readily available “off-the-shelf” in emergent settings, and anatomically applicable in up to 50-70% of jAAAs¹²⁵⁻¹²⁷. In paper III we found early outcomes comparable with CMDs, although re-intervention rates were somewhat inferior. Adequate proximal seal was achieved in all cases, indicating that the graft-configuration with fenestrations to the SMA and renal arteries and a scallop for the CT is sufficient to this end. Other studies have shown a gain in infra-coeliac seal compared to supra-coeliac regarding survival, spinal ischemia and over-all branch re-intervention rates^{149, 150}. In our series long-term outcomes were in some aspects comparable with repair with CMDs, such as survival and diminishing aneurysm sac diameter. TV stability, renal function and re-intervention rates were however inferior to outcomes after CMDs^{75, 90, 151, 152}. Outcomes for patients treated in emergent settings carry weight in these results, perhaps understandably since it is well known that urgent surgery often arises outside office hours and demands hurried planning and action in patients in poor clinical condition. Another likely explanation is the pivoted design of the renal fenestrations. Not only are they more challenging to cannulate compared to the more rigid fenestrations of CMDs as the targeted arteries are often offset by a larger margin, but they are additionally prone to fluctuate during cannulation as well as after deployment due to pulsating blood-flow¹⁵³. Overall, performance of the p-

Branch device is somewhat inferior to CMDs. It can be a suitable choice in urgent settings when patients are deemed unfit for OSR and infrarenal EVAR is not an option.

FEVAR has been shown to be a safe and efficient option for managing jAAA in the short- and mid-term¹⁵⁴. However, long-term data is lacking. A previous report showed promising 5-year outcomes after the first 54 patients treated with FEVAR in Vascular Center Malmö⁹⁰. In paper IV, a median FU of 89 months in 94 succeeding patients offers an extended insight regarding long-term outcomes and graft performance. TV patency was 94%, 90% and 89% after one, three and five years respectively which is similar to similar studies^{88, 94}. Unstented SMA scallops were at greater risk of resulting in compromised patency, as other studies have shown¹⁵⁵. Branch EL occurred in only one (0.5%) TV, which compares favourably to earlier reports of rates up to 4-5%¹⁵⁶. 65% of reinterventions were performed to address EL or TV instability, highlighting the impact of these adverse outcomes after fenestrated repair. Impact on renal function after FEVAR is a well-known issue. Per-operative guidewire- and catheter-related injuries in the renal arteries during cannulation as well as post-operative stent dysfunction are contributing factors, and studies have shown declining renal function in 25-29% of cases^{95, 96}. However, there is some evidence indicating no difference in renal impairment after FEVAR compared to EVAR¹⁵⁷. Studies have found a lower incidence of renal dysfunction after FEVAR compared to OSR^{75, 158}, perhaps indicating that FEVAR should be favoured in the management of jAAA. Long-term FU in our series indicates favourable outcomes regarding renal function with 16% of patients with normal GFR pre-operatively developing insufficiency to some degree. Comparing long-term outcomes between the early-phase and the late-phase cohorts from paper I we saw a reduction in operative mortality (3.7% vs 1%), in 5-year mortality (40% vs 29%) and over-all aneurysm sac diameter (71% vs 91%), as well as increased 5-year re-intervention free survival (56% vs 60%) respectively. This may point to a benefit in increased experience and more extensive endovascular repair regarding long-term survival. A sizable portion of re-interventions were prompted by findings outside of regular FU, often instigated by patient symptoms. The majority of TV instability was detected early during FU. This may imply that the cause for instability arises early post-operatively or may already be present albeit undetected at the end of the initial procedure. Studies have shown that CBCT outperforms CTA and DSA in the detection of EL after FEVAR¹⁵⁹, and the technique is also more sensitive than DSA for detection of device kinking after EVAR¹⁶⁰. Re-intervention rates might have been reduced with the aid of a final CBCT intra-operatively, which by extension could in turn lessen the need for repeated CTA controls later during FU. As the application of CBCT was gradually introduced at Vascular Center during the study inclusion period and thus not applied in all cases, CBCT data was not analyzed in this study. Almost all cases of EL were accompanied by aneurysm sac enlargement. Sac diameter measurements and TV EL detection is quite feasible using DUS^{161, 162}. It is possible that a combination of intra-operative CBCT and

extended application of DUS during FU may alleviate the need for post-operative CTA surveillance, in turn minimizing patient radiation exposure and nephrotoxicity.

Conclusions

1. With increasing experience FEVAR design has become more complex involving more TVs and moving the sealing-zone more proximally. This has not resulted in longer procedure durations or increased complications and operative risk remains low. Despite an increased number of fenestrations, radiation time and contrast-media load are reduced.
2. Despite technical difficulties and necessary meticulous planning, F/BEVAR for type 1a endoleaks, proximal aneurysm or pseudoaneurysm formation and device migration after previous infrarenal AAA repair is a safe and effective treatment method, and a reasonable alternative to OSR.
3. The COOK Zenith p-Branch device is a safe and effective means of managing jAAA both electively and emergently in selected patients, with acceptable long-term outcomes. Treatment with CMD is preferable in applicable circumstances.
4. Long-term outcomes after FEVAR for jAAA remain good with improved overall survival and AAA related mortality with increased experience despite a larger number of fenestrations. Survival and renal function compare favourably to OSR, although the need for reinterventions remains a challenge.

Future perspectives

Abdominal aortic aneurysm repair has progressed decisively in the last decades after a period of stagnation when open surgical techniques reached their peak. With endovascular abdominal aortic repair a new era emerged bringing extended possibilities. As only about half of AAAs are suitable for infrarenal repair, a continuous development of fenestrated graft design is called for. Design and deployment of these devices is complex, and increased experience in pre-operative planning as well as intra-operative techniques is of the essence to assure the best possible outcome for each individual patient. Managing jAAA disease in urgent settings brings an additional spectrum of concerns, as the current waiting time for custom made grafts is not realistic in these cases. OTS devices have been developed to address this issue, but further innovation is warranted to overcome problems with device performance and durability. Particular focus needs to be aimed at fenestration stability while simultaneously preserving a degree of manoeuvrability to facilitate a secure TV perfusion.

The main concerns in managing jAAA with FEVAR revolve around proximal EL and TV instability, and early identification and proper handling of these issues is key to minimize the risk of adverse outcomes and patient harm. Intra-operative measures such as CBCT may reduce the risk of missed EL and graft kinking as studies have illustrated. Increased employment of this technique may further reduce the need for re-interventions and the risk of negative outcomes, and many centres have the application available. Recent work with DUS as a modality for FU after FEVAR has also shown promising outcomes in detecting EL and TV patency. By such preventive measures it can be argued that the need for rigorous post-operative follow-up using CTA could be diminished, thereby reducing patient radiation exposure, iodine-based contrast medium exposure and health care cost. More research is needed to address this issue.

Populärvetenskaplig sammanfattning

Bukaortaaneurysm är ett tillstånd när dilatation sker på stora kroppspulsådern i buken. Tillståndet föreligger hos upp till 1.5-2.6% av svenska befolkningen vid 65 års ålder och drabbar i synnerhet män. Orsaker till att detta äger rum är flera, men främst föreligger ett samband mellan aneurysmbildning och rökning, ärftlighet, högt blodtryck, ålder och manligt kön. Ju större aneurysmet är desto mer ökar risken för att kärlet brister med ödesdigra konsekvenser för patienten. Då sker en omfattande invärtes blödning som i många fall leder till döden. Tidigare forskning har visat att risken för ruptur överstiger den risk som ett förebyggande kirurgiskt ingrepp medför när kärldvidningen når 5.5 cm diameter hos män och 5.0 cm hos kvinnor. Huvudsakligen används två olika behandlingsmetoder: Öppen kirurgi då den drabbade delen av aorta byts ut mot en insydd tub av tyg via ett stort snitt på buken, alternativt en minimal-invasiv endovaskulär metod (EVAR) då en metallförstärkt protes av tyg införskaffas i genomlysning via punktionshål i ljumskpulsåderna och fodrar kärlets vägg. Den sistnämnda metoden har de senaste åren utvecklats i rask takt för att även användas för komplexa bukaortaaneurysm som innefattar kärllavgångar till viktiga bukorgan som lever, tarmar och njurar. Då kallas ingreppet FEVAR (fenestrerad EVAR). Protesen är då försedd med hål eller urgröpningar i tyget så att blod ska rinna ohindrat till de olika bukorganen. Proteserna har individuell design i varje enskilt fall beroende på aneurysmets anatomi.

Behandling med FEVAR innebär ett flertal tekniska utmaningar. Protesen måste läggas med stor precision avseende höjd och rotation så att fenestreringarna ska hitta sina respektive kärllavgångar, som i sin tur även förses med mindre, tubulära proteser för att förhindra läckage. Själva huvudprotesen behöver därutöver förankras till ett friskt segment av aorta ovanför aneurysmet och nedanför till pulsådern i bäckenet så att en hållbar tätning kan uppnås. Noggrann planering med hjälp av kontrastförstärkt datortomografi krävs före ingreppet, och uppföljning efter behandlingen sker årligen med regelbundna kontroller. Flera studier har visat att FEVAR ger bra resultat på kort sikt, men långtidsresultat är bristvara.

Syftet med denna avhandling var att utvärdera utfallet av behandling med FEVAR av komplexa bukaortaaneurysm avseende patientsäkerhet och protesernas hållbarhet. Den består av fyra olika delarbeten (I-IV).

Studiernas specifika syfte var att:

- I. Utvärdera hur erfarenhet av FEVAR påverkar protesernas design, operationsförförande och kliniskt utfall.
- II. Utvärdera användbarhet av FEVAR som kompletterande åtgärd efter tidigare ingrepp på bukaorta.
- III. Utvärdera hållbarhet och kliniskt utfall av FEVAR med en standardiserad protes i planerade och akuta fall.
- IV. Utvärdera långtidsresultat efter FEVAR.

Delarbete I var samarbete mellan Kärll centrum SUS Malmö och Aortic Centre i Lille Frankrike. Patienter behandlade mellan 2002 och 2011 delades i två grupper, tidig och sen, som jämfördes avseende teknisk framgång, komplikationer och överlevnad i en retrospektiv analys. Delarbete II var samarbete med Kärll kliniken på Akademiska sjukhuset i Uppsala. Patienter som behandlades med FEVAR mellan 2002 och 2015 pga otillräcklig effekt av tidigare ingrepp på bukaorta ingick i retrospektiv analys av teknisk framgång, komplikationer och överlevnad. Delarbete III var en prospektiv studie där patienter behandlades mellan 2012 och 2015 med en standardiserad protes (p-Branch). Teknisk framgång, protesens hållbarhet, komplikationer och överlevnad analyserades. I delarbete IV inkluderades patienter från delarbete I som behandlades i Sverige och ingick ursprungligen i den sena gruppen. Data analyserades retrospektivt avseende protes hållbarhet, komplikationer och överlevnad.

Med ökad erfarenhet minskade genomlysningstid och kontrastmängd, och tendens ökade till antal fenestreringar i protesdesign. Överlevnad efter FEVAR förbättras även med ökad erfarenhet. Kompletterande behandling med FEVAR efter tidigare ingrepp på bukaorta med otillräcklig effekt är en säker och hållbar behandlingsmetod, men tekniska utmaningar kallar på noggrann bilddiagnostisk planering. Behandling med standardiserad protes av komplexa bukaortaaneurysm ger tillfredsställande resultat för utvalda patienter, i synnerhet under brådskande förhållanden. FEVAR är en säker och hållbar behandling på lång sikt, och bör favoriseras över öppen kirurgi om adekvat kompetens och lokala resurser föreligger.

Slutsatserna av denna avhandling är att FEVAR är en säker behandlingsmetod för komplexa bukaortaaneurysm. Förbättrad överlevnad och sjunkande komplikationsfrekvens motiverar att FEVAR framhålls som första behandlingsalternativ. Metoden är relativt ny, och fortsatt forskning kring stentgrafters hållbarhet på lång sikt är befogad.

Samantekt á Íslensku

Ósæðargúll í kviðarholi myndast er víkkun á ósæðinni á sér stað. Algengi ósæðargúls í kviðarholi er 1.5-2.6% við 65 ára aldur hjá sænsku þjóðinni og er algengara í karlmönnum. Myndun ósæðargúls á sér margar ástæður, áhættuþættir eru einkum reykingar, hár blóðþrýstingur, hækkandi aldur, erfðir og karlkyn. Æðagúlar geta stækkað með tímanum, og með aukinni æðavíkkun eykst hætta á rofi með alvarlegum afleiðingum. Þá verður umfangsmikil innvortis blæðing sem í flestum tilvikum leiðir til dauða sjúklingsins. Rannsóknir hafa sýnt að hætta á rofi er meiri en áhætta við fyrirbyggjandi aðgerð ef þvermál ósæðagúls nær 5.5 cm hjá karlmönnum og 5.0 cm hjá konum, og við þau mörk er sjúklingum almennt ráðlögð aðgerð. Tvær mismunandi aðgerðir standa sjúklingum til boða: opin aðgerð þegar framanverður kviðveggur er skorinn upp og sjúka hluta ósæðarinnar er skipt út fyrir gerviað sem saumuð er föst, eða innæðaaðgerð (EVAR) þegar málmstyrktri gerviað er komið fyrir í gúlum innanverðum gegnum stungur á náraslagæðum með hjálp gegnumlýsingar með röntgentækni. EVAR hefur þróast hratt síðustu ár, ekki síst hvað varðar flóknari gerðir ósæðargúla sem myndast við æðagreinar er veita blóði til mikilvægra kviðarholslíffæra, svo sem lifrar, þarma og nýrna. Sú tegund innæðaaðgerðar er nefnd FEVAR (fenestrated EVAR). Gerviaðin sem þá er notuð er framleidd með götum eða úrtekt úr efni gerviaðarinnar sem veita óhindrað blóðflæði til líffæra. Í þessum tilfellum er gerviaðin sérstaklega hönnuð og framleidd fyrir hvern einstakling þar sem ósæð hvers og eins er einstök í útliti og formgerð.

Aðgerð með FEVAR er flókin í framkvæmd frá tæknilegu sjónarmiði séð. Mikilvægt er að gerviaðinni sé rétt komið fyrir hvað varðar nákvæma staðsetningu gatanna aðlægt þeim æðagreinum sem þeim er ætlað að hleypa blóði til. Minni gerviaðum er svo komið fyrir milli greinar og gats svo að blóðflæði til hinna ýmsu líffæra sé tryggt án þess að leki sé til staðar. Aðalhluti gerviaðarinnar í sjálfri ósæðinni verður þar að auki að ná góðri festu í frískum hluta æðarinnar, bæði ofan gúlsins og neðan svo að tryggt sé að blóðflæði sé einungis gegnum hana og þannig sé öllum þrýstingi á vegg gúlsins aflétt. Nákvæm skipulagning aðgerðarinnar og kortlagning gúlsins fæst með hjálp tölvusneiðmynda með skuggaefni, sem einnig er mikilvægur þáttur í reglulegri eftirfylgni sjúklingsins eftir aðgerð. Margar rannsóknir hafa sýnt fram á notagildi FEVAR til skamms tíma, en langtíma rannsóknir eru af skornum skammti.

Tilgangur þessarar ritgerðar var að meta árangur aðgerða með FEVAR vegna flókinna ósæðagúla í kviðarholi með tilliti til öryggis sjúklinga og haldbærni greviæða. Hún samanstendur af fjórum rannsóknum (I-IV)

Tilgangur rannsókna var að:

- I. Meta áhrif reynslu í framkvæmd FEVAR á hönnun gerviaæða, aðgerðaraðferðir og klínískar niðurstöður.
- II. Meta notagildi FEVAR sem úrræði við ófullnægjandi áhrifum af fyrri aðgerðum vegna ósæðargúls í kvið.
- III. Meta haldbærni og klínískar niðurstöður eftir FEVAR með staðlaðri gerviað í valkvæðum aðgerðum og bráðaaðgerðum.
- IV. Meta langtímaárangur eftir aðgerð með FEVAR.

Rannsókn I var samstarf milli Kärilcentrum SUS Malmö og Aortic Centre í Lille Frakklandi. Sjúklingum sem gengust undir FEVAR milli árána 2002 og 2011 var skipt í tvo hópa, fyrri og seinni, sem bornir voru saman varðandi aðgerðar-niðurstöður, fylgikvilla og lifun. Rannsókn II var afturvirk greining í samstarfi við æðadeildina á Akademiska sjukhuset í Uppsala. Allir sjúklingar sem gengust undir FEVAR milli árána 2002 og 2015 vegna ófullnægjandi árangurs fyrri aðgerða á ósæðargúl í kvið voru teknir með í aftursæja greiningu á aðgerðarniðurstöðum, fylgikvillum og lifun. Rannsókn III var framsæ greining á aðgerðarniðurstöðum, haldbærni gerviaæða, fylgikvillum og lifun eftir FEVAR með staðlaðri gerviað (p-Branch) milli 2012 og 2015. Í rannsókn IV var þeim sjúklingum úr seinni hóp rannsókna I sem gengust undir aðgerð í Svíþjóð fylgt eftir á aftursæjan hátt með áherslu á endingu gerviaæðanna, fylgikvilla og lifun til langs tíma.

Með aukinni reynslu minnkaði tími gegnumlýsingar og notkun skuggaefnis í aðgerðum þrátt fyrir flóknari hönnun gerviaæða. Lifun eftir aðgerð jókst milli hópa með aukinni reynslu. Viðbótaraðgerð með FEVAR eftir fyrri aðgerðir á ósæðargúl í kviðarholi er örugg og haldbær, en tæknilegar áskoranir krefjast nákvæmrar forvinnu við myndgreiningu og kortlagningar gúls. Góðar niðurstöður fást eftir FEVAR með staðlaðri gerviað hjá völdum hópi sjúklinga, einkum eftir bráðaaðgerð. FEVAR er örugg og haldbær aðgerð til langs tíma, og er tilvalið fyrsta úrræði við meðhöndlun flókinna ósæðargúla í kvið ef reynsla og staðbundnar aðstæður leyfa.

Niðurstöður ritgerðar þessarar sýna því að FEVAR er örugg meðhöndlun við flóknum ósæðargúl í kviðarholi. Bætt lifun og fækkun fylgikvilla ýtir undir FEVAR sem fyrsta aðgerðarval. Aðferðin er tiltölulega ný, og fleiri rannsókna er varða langtíma haldbærni er þörf.

Acknowledgements

I would like to express my utmost gratitude to the following people:

Professor **Timothy Resch**, my principal supervisor, mentor and friend. Thank you for everything! Your tireless advice and commitment have been invaluable through the process from start to finish. Thank you for all your support, in good times and bad. You are truly my bottomless source of inspiration.

Associate professor **Þórarinn Kristmundsson**, my co-supervisor and friend. Your spotless work ethics have guided me more than you know, and I am forever grateful for your direction and support.

My co-authors **Björn Sonesson**, **Nuno Dias** and **Katarina Björse**s for their valuable input and guidance.

My colleagues in the Vascular unit in Helsingborg, **Johan Magnusson**, **Hans Lindgren**, **Tobias Kühme**, **Magnus Garbergs**, **Gustav Torstensson** and **Christian von Heijne** for cheering me on and for making room in in our schedule for my research.

All my colleagues at the Department of Surgery in Helsingborg and in Vascular Center Malmö for your friendship and support.

Kjerstin Ädel Malmborg and **Margareta Warvsten**, the masters of misplaced folders.

My parents **Kristín Bragadóttir** and **Sveinn Magnússon**, and my siblings **Sigríður Sveinsdóttir**, **Bragi Sveinsson** and **Kristín Björg Sveinsdóttir**. Thank you all for believing in me.

My beloved wife and soulmate **Þóra Briem**, and my children **Tinna** and **Sveinn**. I think we all deserve a big hug-fest!

References

1. Thompson JE. Early history of aortic surgery. *J Vasc Surg.* 1998;28(4):746-52.
2. Crowe SJ. Halsted of Johns Hopkins: the man and his men. Springfield, Ill.,: Thomas; 1957. ix, 247 p. p.
3. Cooley DA. Aortic aneurysm operations: past, present, and future. *Ann Thorac Surg.* 1999;67(6):1959-62; discussion 79-80.
4. Antoniou GA, Antoniou AI, Antoniou SA, Lazarides MK. A historical perspective of medical terminology of aortic aneurysm. *J Vasc Surg.* 2011;54(5):1527-8.
5. Cooley DA. A Brief History of Aortic Aneurysm Surgery. *Aorta (Stamford).* 2013;1(1):1-3.
6. Blakemore AH. Progressive constrictive occlusion of the abdominal aorta with wiring and electrothermic coagulation, a one-stage operation for arteriosclerotic aneurysms of the abdominal aorta. *Ann Surg.* 1951;133(4):447-62.
7. Moore CH, Murchison C. On a new method of procuring the consolidation of Fibrin in certain incurable Aneurisms: With the Report of a case in which an Aneurism of the ascending Aorta was treated by the insertion of Wire. *Med Chir Trans.* 1864;47:129-49.
8. Harrison PW, Chandy J. A Subclavian Aneurysm Cured by Cellophane Fibrosis. *Ann Surg.* 1943;118(3):478-81.
9. Poppe JK. Cellophane treatment of syphilitic aneurysms with report of results in six cases. *Am Heart J.* 1948;36(2):252-6.
10. Matas R. I. An Operation for the Radical Cure of Aneurism based upon Arteriorrhaphy. *Ann Surg.* 1903;37(2):161-96.
11. Matas R. Some Experiences and Observations in the Treatment of Arteriovenous Aneurisms by the Intrascacular Method of Suture (Endo-Aneurismorrhaphy) with Special Reference to the Transvenous Route. *Ann Surg.* 1920;71(4):403-27.
12. Dubost C, Allary M, Oeconomos N. Resection of an aneurysm of the abdominal aorta: reestablishment of the continuity by a preserved human arterial graft, with result after five months. *AMA Arch Surg.* 1952;64(3):405-8.
13. Julian OC, Grove WJ, Dye WS, Olwin J, Sadove MS. Direct surgery of arteriosclerosis; resection of abdominal aorta with homologous aortic graft replacement. *Ann Surg.* 1953;138(3):387-403.
14. Brock RC, Rob CG, Forty F. Discussion on reconstructive arterial surgery. *Proc R Soc Med.* 1953;46(2):115-30.

15. De Bakey ME, Cooley DA. Surgical treatment of aneurysm of abdominal aorta by resection and restoration of continuity with homograft. *Surg Gynecol Obstet.* 1953;97(3):257-66.
16. Bahnson HT. Considerations in the excision of aortic aneurysms. *Ann Surg.* 1953;138(3):377-86.
17. Parodi JC, Palmaz JC, Barone HD. Transfemoral intraluminal graft implantation for abdominal aortic aneurysms. *Ann Vasc Surg.* 1991;5(6):491-9.
18. Volodos NL, Shekhanin VE, Karpovich IP, Troian VI, Gur'ev Iu A. [A self-fixing synthetic blood vessel endoprosthesis]. *Vestn Khir Im I I Grek.* 1986;137(11):123-5.
19. Patel R, Sweeting MJ, Powell JT, Greenhalgh RM, investigators Et. Endovascular versus open repair of abdominal aortic aneurysm in 15-years' follow-up of the UK endovascular aneurysm repair trial 1 (EVAR trial 1): a randomised controlled trial. *Lancet.* 2016;388(10058):2366-74.
20. Setacci C, Sirignano P, Fineschi V, Frati P, Ricci G, Speziale F. A clinical and ethical review on late results and benefits after EVAR. *Ann Med Surg (Lond).* 2017;16:1-6.
21. Powell JT, Sweeting MJ, Ulug P, Blankensteijn JD, Lederle FA, Becquemin JP, et al. Meta-analysis of individual-patient data from EVAR-1, DREAM, OVER and ACE trials comparing outcomes of endovascular or open repair for abdominal aortic aneurysm over 5 years. *Br J Surg.* 2017;104(3):166-78.
22. Johnston KW, Rutherford RB, Tilson MD, Shah DM, Hollier L, Stanley JC. Suggested standards for reporting on arterial aneurysms. Subcommittee on Reporting Standards for Arterial Aneurysms, Ad Hoc Committee on Reporting Standards, Society for Vascular Surgery and North American Chapter, International Society for Cardiovascular Surgery. *J Vasc Surg.* 1991;13(3):452-8.
23. McGregor JC, Pollock JG, Anton HC. The value of ultrasonography in the diagnosis of abdominal aortic aneurysm. *Scott Med J.* 1975;20(3):133-7.
24. Wanhainen A. How to define an abdominal aortic aneurysm--influence on epidemiology and clinical practice. *Scand J Surg.* 2008;97(2):105-9; discussion 9.
25. Sakalihan N, Limet R, Defawe OD. Abdominal aortic aneurysm. *Lancet.* 2005;365(9470):1577-89.
26. Schmitz-Rixen T, Keese M, Hakimi M, Peters A, Bockler D, Nelson K, et al. Ruptured abdominal aortic aneurysm-epidemiology, predisposing factors, and biology. *Langenbecks Arch Surg.* 2016;401(3):275-88.
27. Golledge J. Abdominal aortic aneurysm: update on pathogenesis and medical treatments. *Nat Rev Cardiol.* 2019;16(4):225-42.
28. Ullery BW, Hallett RL, Fleischmann D. Epidemiology and contemporary management of abdominal aortic aneurysms. *Abdom Radiol (NY).* 2018;43(5):1032-43.
29. Kuivaniemi H, Ryer EJ, Elmore JR, Tromp G. Understanding the pathogenesis of abdominal aortic aneurysms. *Expert Rev Cardiovasc Ther.* 2015;13(9):975-87.

30. Writing Committee G, Oderich GS, Forbes TL, Chaer R, Davies MG, Lindsay TF, et al. Reporting standards for endovascular aortic repair of aneurysms involving the renal-mesenteric arteries. *J Vasc Surg.* 2020.
31. Kristmundsson T, Dias N, Resch T, Sonesson B. Morphology of Small Abdominal Aortic Aneurysms Should be Considered before Continued Ultrasound Surveillance. *Ann Vasc Surg.* 2016;31:18-22.
32. Karthaus EG, Tong TML, Vahl A, Hamming JF, Dutch Society of Vascular Surgery tSCotDSAA, the Dutch Institute for Clinical A. Saccular Abdominal Aortic Aneurysms: Patient Characteristics, Clinical Presentation, Treatment, and Outcomes in the Netherlands. *Ann Surg.* 2019;270(5):852-8.
33. Shang EK, Nathan DP, Boonn WW, Lys-Dobradin IA, Fairman RM, Woo EY, et al. A modern experience with saccular aortic aneurysms. *J Vasc Surg.* 2013;57(1):84-8.
34. Sidloff D, Stather P, Dattani N, Bown M, Thompson J, Sayers R, et al. Aneurysm global epidemiology study: public health measures can further reduce abdominal aortic aneurysm mortality. *Circulation.* 2014;129(7):747-53.
35. Fattahi N, Rosenblad A, Kragsterman B, Hultgren R. Risk factors in 50-year-old men predicting development of abdominal aortic aneurysm. *J Vasc Surg.* 2020.
36. Wanhainen A, Hultgren R, Linne A, Holst J, Gottsater A, Langenskiold M, et al. Outcome of the Swedish Nationwide Abdominal Aortic Aneurysm Screening Program. *Circulation.* 2016;134(16):1141-8.
37. Lindholt JS, Diederichsen AC, Rasmussen LM, Frost L, Steffensen FH, Lambrechtsen J, et al. Survival, Prevalence, Progression and Repair of Abdominal Aortic Aneurysms: Results from Three Randomised Controlled Screening Trials Over Three Decades. *Clin Epidemiol.* 2020;12:95-103.
38. Joergensen TM, Christensen K, Lindholt JS, Larsen LA, Green A, Houliand K. Editor's Choice - High Heritability of Liability to Abdominal Aortic Aneurysms: A Population Based Twin Study. *Eur J Vasc Endovasc Surg.* 2016;52(1):41-6.
39. Xiong J, Wu Z, Chen C, Wei Y, Guo W. Association between diabetes and prevalence and growth rate of abdominal aortic aneurysms: A meta-analysis. *Int J Cardiol.* 2016;221:484-95.
40. Wanhainen A, Verzini F, Van Herzelee I, Allaire E, Bown M, Cohnert T, et al. Editor's Choice - European Society for Vascular Surgery (ESVS) 2019 Clinical Practice Guidelines on the Management of Abdominal Aorto-iliac Artery Aneurysms. *Eur J Vasc Endovasc Surg.* 2019;57(1):8-93.
41. Sakalihan N, Michel JB, Katsargyris A, Kuivaniemi H, Defraigne JO, Nchimi A, et al. Abdominal aortic aneurysms. *Nat Rev Dis Primers.* 2018;4(1):34.
42. Kniemeyer HW, Kessler T, Reber PU, Ris HB, Hakki H, Widmer MK. Treatment of ruptured abdominal aortic aneurysm, a permanent challenge or a waste of resources? Prediction of outcome using a multi-organ-dysfunction score. *Eur J Vasc Endovasc Surg.* 2000;19(2):190-6.
43. Thompson MM. Controlling the expansion of abdominal aortic aneurysms. *Br J Surg.* 2003;90(8):897-8.

44. Powell JT, Brown LC, Forbes JF, Fowkes FG, Greenhalgh RM, Ruckley CV, et al. Final 12-year follow-up of surgery versus surveillance in the UK Small Aneurysm Trial. *Br J Surg*. 2007;94(6):702-8.
45. Lederle FA, Wilson SE, Johnson GR, Reinke DB, Littooy FN, Acher CW, et al. Immediate repair compared with surveillance of small abdominal aortic aneurysms. *N Engl J Med*. 2002;346(19):1437-44.
46. Parkinson F, Ferguson S, Lewis P, Williams IM, Twine CP, South East Wales Vascular N. Rupture rates of untreated large abdominal aortic aneurysms in patients unfit for elective repair. *J Vasc Surg*. 2015;61(6):1606-12.
47. Lederle FA, Johnson GR, Wilson SE, Ballard DJ, Jordan WD, Jr., Blebea J, et al. Rupture rate of large abdominal aortic aneurysms in patients refusing or unfit for elective repair. *JAMA*. 2002;287(22):2968-72.
48. Mani K, Bjorck M, Wanhainen A. Changes in the management of infrarenal abdominal aortic aneurysm disease in Sweden. *Br J Surg*. 2013;100(5):638-44.
49. Sweeting MJ, Thompson SG, Brown LC, Powell JT, collaborators R. Meta-analysis of individual patient data to examine factors affecting growth and rupture of small abdominal aortic aneurysms. *Br J Surg*. 2012;99(5):655-65.
50. Collaborators R, Bown MJ, Sweeting MJ, Brown LC, Powell JT, Thompson SG. Surveillance intervals for small abdominal aortic aneurysms: a meta-analysis. *JAMA*. 2013;309(8):806-13.
51. Fink HA, Lederle FA, Roth CS, Bowles CA, Nelson DB, Haas MA. The accuracy of physical examination to detect abdominal aortic aneurysm. *Arch Intern Med*. 2000;160(6):833-6.
52. Crawford CM, Hurtgen-Grace K, Talarico E, Marley J. Abdominal aortic aneurysm: an illustrated narrative review. *J Manipulative Physiol Ther*. 2003;26(3):184-95.
53. Scott RA, Ashton HA, Kay DN. Abdominal aortic aneurysm in 4237 screened patients: prevalence, development and management over 6 years. *Br J Surg*. 1991;78(9):1122-5.
54. Lee TY, Korn P, Heller JA, Kilaru S, Beavers FP, Bush HL, et al. The cost-effectiveness of a "quick-screen" program for abdominal aortic aneurysms. *Surgery*. 2002;132(2):399-407.
55. Fleming C, Whitlock EP, Beil TL, Lederle FA. Screening for abdominal aortic aneurysm: a best-evidence systematic review for the U.S. Preventive Services Task Force. *Ann Intern Med*. 2005;142(3):203-11.
56. Beales L, Wolstenhulme S, Evans JA, West R, Scott DJ. Reproducibility of ultrasound measurement of the abdominal aorta. *Br J Surg*. 2011;98(11):1517-25.
57. Scott RA, Bridgewater SG, Ashton HA. Randomized clinical trial of screening for abdominal aortic aneurysm in women. *Br J Surg*. 2002;89(3):283-5.
58. Davis CA. Computed tomography for the diagnosis and management of abdominal aortic aneurysms. *Surg Clin North Am*. 2011;91(1):185-93.
59. Nyman R, Eriksson MO. The future of imaging in the management of abdominal aortic aneurysm. *Scand J Surg*. 2008;97(2):110-5.

60. Broeders IA, Blankensteijn JD. Preoperative imaging of the aortoiliac anatomy in endovascular aneurysm surgery. *Semin Vasc Surg.* 1999;12(4):306-14.
61. NICE Guideline Updates Team (UK). Imaging techniques to diagnose abdominal aortic aneurysms: Abdominal aortic aneurysm: diagnosis and management: Evidence review B. London2020.
62. Biancari F, Paone R, Venermo M, D'Andrea V, Perala J. Diagnostic accuracy of computed tomography in patients with suspected abdominal aortic aneurysm rupture. *Eur J Vasc Endovasc Surg.* 2013;45(3):227-30.
63. van Keulen JW, Moll FL, Tolenaar JL, Verhagen HJ, van Herwaarden JA. Validation of a new standardized method to measure proximal aneurysm neck angulation. *J Vasc Surg.* 2010;51(4):821-8.
64. Lee WA. Endovascular abdominal aortic aneurysm sizing and case planning using the TeraRecon Aquarius workstation. *Vasc Endovascular Surg.* 2007;41(1):61-7.
65. Ali MU, Fitzpatrick-Lewis D, Miller J, Warren R, Kenny M, Sherifali D, et al. Screening for abdominal aortic aneurysm in asymptomatic adults. *J Vasc Surg.* 2016;64(6):1855-68.
66. Jacomelli J, Summers L, Stevenson A, Lees T, Earnshaw JJ. Impact of the first 5 years of a national abdominal aortic aneurysm screening programme. *Br J Surg.* 2016;103(9):1125-31.
67. Svensjo S, Bjorck M, Wanhainen A. Update on screening for abdominal aortic aneurysm: a topical review. *Eur J Vasc Endovasc Surg.* 2014;48(6):659-67.
68. Force USPST, Owens DK, Davidson KW, Krist AH, Barry MJ, Cabana M, et al. Screening for Abdominal Aortic Aneurysm: US Preventive Services Task Force Recommendation Statement. *JAMA.* 2019;322(22):2211-8.
69. Guirguis-Blake JM, Beil TL, Senger CA, Coppola EL. Primary Care Screening for Abdominal Aortic Aneurysm: Updated Evidence Report and Systematic Review for the US Preventive Services Task Force. *JAMA.* 2019;322(22):2219-38.
70. Mortality results for randomised controlled trial of early elective surgery or ultrasonographic surveillance for small abdominal aortic aneurysms. The UK Small Aneurysm Trial Participants. *Lancet.* 1998;352(9141):1649-55.
71. Cao P, De Rango P, Verzini F, Parlani G, Romano L, Cieri E, et al. Comparison of surveillance versus aortic endografting for small aneurysm repair (CAESAR): results from a randomised trial. *Eur J Vasc Endovasc Surg.* 2011;41(1):13-25.
72. Ouriel K, Clair DG, Kent KC, Zarins CK. Positive Impact of Endovascular Options for treating Aneurysms Early I. Endovascular repair compared with surveillance for patients with small abdominal aortic aneurysms. *J Vasc Surg.* 2010;51(5):1081-7.
73. Filardo G, Powell JT, Martinez MA, Ballard DJ. Surgery for small asymptomatic abdominal aortic aneurysms. *Cochrane Database Syst Rev.* 2015(2):CD001835.
74. Chaikof EL, Dalman RL, Eskandari MK, Jackson BM, Lee WA, Mansour MA, et al. The Society for Vascular Surgery practice guidelines on the care of patients with an abdominal aortic aneurysm. *J Vasc Surg.* 2018;67(1):2-77 e2.
75. Jones AD, Waduud MA, Walker P, Stocken D, Bailey MA, Scott DJA. Meta-analysis of fenestrated endovascular aneurysm repair versus open surgical repair of

- juxtarenal abdominal aortic aneurysms over the last 10 years. *BJS Open*. 2019;3(5):572-84.
76. Drazic OD, Zarate CF, Valdes JF, Kramer AH, Bergoeing MP, Marine LA, et al. Juxtarenal Abdominal Aortic Aneurysm: Results of Open Surgery in an Academic Center. *Ann Vasc Surg*. 2020;66:28-34.
 77. Tsai S, Conrad MF, Patel VI, Kwolek CJ, LaMuraglia GM, Brewster DC, et al. Durability of open repair of juxtarenal abdominal aortic aneurysms. *J Vasc Surg*. 2012;56(1):2-7.
 78. Seldinger SI. Catheter replacement of the needle in percutaneous arteriography; a new technique. *Acta radiol*. 1953;39(5):368-76.
 79. Marone EM, Freyrie A, Ruotolo C, Michelagnoli S, Antonello M, Speziale F, et al. Expert Opinion on Hostile Neck Definition in Endovascular Treatment of Abdominal Aortic Aneurysms (a Delphi Consensus). *Ann Vasc Surg*. 2020;62:173-82.
 80. Kristmundsson T, Sonesson B, Dias N, Malina M, Resch T. Anatomic suitability for endovascular repair of abdominal aortic aneurysms and possible benefits of low profile delivery systems. *Vascular*. 2014;22(2):112-5.
 81. Park KH, Lim C, Lee JH, Yoo JS. Suitability of endovascular repair with current stent grafts for abdominal aortic aneurysm in Korean patients. *J Korean Med Sci*. 2011;26(8):1047-51.
 82. Hultgren R, Vishnevskaya L, Wahlgren CM. Women with abdominal aortic aneurysms have more extensive aortic neck pathology. *Ann Vasc Surg*. 2013;27(5):547-52.
 83. Carpenter JP, Baum RA, Barker CF, Golden MA, Mitchell ME, Velazquez OC, et al. Impact of exclusion criteria on patient selection for endovascular abdominal aortic aneurysm repair. *J Vasc Surg*. 2001;34(6):1050-4.
 84. Gimenez-Gaibar A, Gonzalez-Canas E, Solanich-Valldaura T, Herranz-Pinilla C, Rioja-Artal S, Ferraz-Huguet E. Could Preoperative Neck Anatomy Influence Follow-up of EVAR? *Ann Vasc Surg*. 2017;43:127-33.
 85. Kristmundsson T, Sonesson B, Malina M, Bjorses K, Dias N, Resch T. Fenestrated endovascular repair for juxtarenal aortic pathology. *J Vasc Surg*. 2009;49(3):568-74; discussion 74-5.
 86. Katsargyris A, Oikonomou K, Kouvelos G, Mufty H, Ritter W, Verhoeven ELG. Comparison of outcomes for double fenestrated endovascular aneurysm repair versus triple or quadruple fenestrated endovascular aneurysm repair in the treatment of complex abdominal aortic aneurysms. *J Vasc Surg*. 2017;66(1):29-36.
 87. Oikonomou K, Kasprzak P, Schierling W, Kopp R, Pfister K. Graft Complexity-Related Outcomes of Fenestrated Endografting for Abdominal Aortic Aneurysms. *J Endovasc Ther*. 2017;24(2):230-6.
 88. Roy IN, Millen AM, Jones SM, Vallabhaneni SR, Scurr JRH, McWilliams RG, et al. Long-term follow-up of fenestrated endovascular repair for juxtarenal aortic aneurysm. *Br J Surg*. 2017;104(8):1020-7.
 89. Perot C, Sobocinski J, Maurel B, Millet G, Guillou M, d'Elia P, et al. Comparison of short- and mid-term follow-up between standard and fenestrated endografts. *Ann Vasc Surg*. 2013;27(5):562-70.

90. Kristmundsson T, Sonesson B, Dias N, Tornqvist P, Malina M, Resch T. Outcomes of fenestrated endovascular repair of juxtarenal aortic aneurysm. *J Vasc Surg.* 2014;59(1):115-20.
91. O'Donnell TFX, Boitano LT, Deery SE, Schermerhorn ML, Schanzer A, Beck AW, et al. Open Versus Fenestrated Endovascular Repair of Complex Abdominal Aortic Aneurysms. *Ann Surg.* 2020;271(5):969-77.
92. Gallitto E, Faggioli G, Giordano J, Pini R, Mascoli C, Fenelli C, et al. Early and Mid-term Efficacy of Fenestrated Endograft in the Treatment of Juxta-Renal Aortic Aneurysms. *Ann Vasc Surg.* 2020;66:132-41.
93. Cross J, Gurusamy K, Gadhvi V, Simring D, Harris P, Ivancev K, et al. Fenestrated endovascular aneurysm repair. *Br J Surg.* 2012;99(2):152-9.
94. Mastracci TM, Greenberg RK, Eagleton MJ, Hernandez AV. Durability of branches in branched and fenestrated endografts. *J Vasc Surg.* 2013;57(4):926-33; discussion 33.
95. Martin-Gonzalez T, Pincon C, Maurel B, Hertault A, Sobocinski J, Spear R, et al. Renal Outcomes Following Fenestrated and Branched Endografting. *Eur J Vasc Endovasc Surg.* 2015;50(4):420-30.
96. Tran K, Fajardo A, Ullery BW, Goltz C, Lee JT. Renal function changes after fenestrated endovascular aneurysm repair. *J Vasc Surg.* 2016;64(2):273-80.
97. Deslarzes-Dubuis C, Tran K, Colvard BD, Lee JT. Renal Stent Complications and Impact on Renal Function after Standard Fenestrated Endovascular Aneurysm Repair. *Ann Vasc Surg.* 2020.
98. Locham S, Faateh M, Dhaliwal J, Nejm B, Dakour-Aridi H, Malas MB. Outcomes and cost of fenestrated versus standard endovascular repair of intact abdominal aortic aneurysm in the United States. *J Vasc Surg.* 2019;69(4):1036-44 e1.
99. Shahverdyan R, Gray D, Gawenda M, Brunkwall J. Single Centre Results of Total Endovascular Repair of Complex Aortic Aneurysms with Custom Made Anaconda Fenestrated Stent Grafts. *Eur J Vasc Endovasc Surg.* 2016;52(4):500-8.
100. White RA, Donayre CE, Walot I, Woody J, Kim N, Kopchok GE. Computed tomography assessment of abdominal aortic aneurysm morphology after endograft exclusion. *J Vasc Surg.* 2001;33(2 Suppl):S1-10.
101. van Keulen JW, van Prehn J, Prokop M, Moll FL, van Herwaarden JA. Potential value of aneurysm sac volume measurements in addition to diameter measurements after endovascular aneurysm repair. *J Endovasc Ther.* 2009;16(4):506-13.
102. Hong H, Yang Y, Liu B, Cai W. Imaging of Abdominal Aortic Aneurysm: the present and the future. *Curr Vasc Pharmacol.* 2010;8(6):808-19.
103. Truijers M, Resch T, Van Den Berg JC, Blankensteijn JD, Lonn L. Endovascular aneurysm repair: state-of-art imaging techniques for preoperative planning and surveillance. *J Cardiovasc Surg (Torino).* 2009;50(4):423-38.
104. Hallett RL, Ullery BW, Fleischmann D. Abdominal aortic aneurysms: pre- and post-procedural imaging. *Abdom Radiol (NY).* 2018;43(5):1044-66.

105. Stavropoulos SW, Charagundla SR. Imaging techniques for detection and management of endoleaks after endovascular aortic aneurysm repair. *Radiology*. 2007;243(3):641-55.
106. Berrington de Gonzalez A, Mahesh M, Kim KP, Bhargavan M, Lewis R, Mettler F, et al. Projected cancer risks from computed tomographic scans performed in the United States in 2007. *Arch Intern Med*. 2009;169(22):2071-7.
107. Chandiramani R, Cao D, Nicolas J, Mehran R. Contrast-induced acute kidney injury. *Cardiovasc Interv Ther*. 2020;35(3):209-17.
108. Brenner DJ, Hall EJ. Computed tomography--an increasing source of radiation exposure. *N Engl J Med*. 2007;357(22):2277-84.
109. Yao JS. Commentary: Surgical treatment of aortic aneurysm: 50-some years later. *Cardiovasc Surg*. 2003;11(5):413-5.
110. Ivancev K, Vogelzang R. A 35 Year History of Stent Grafting, and How EVAR Conquered the World. *Eur J Vasc Endovasc Surg*. 2020;59(5):685-94.
111. Dotter CT, Judkins MP. Transluminal Treatment of Arteriosclerotic Obstruction. Description of a New Technic and a Preliminary Report of Its Application. *Circulation*. 1964;30:654-70.
112. Volodos NL, Karpovich IP, Shekhanin VE, Troian VI, Iakovenko LF. [A case of distant transfemoral endoprosthesis of the thoracic artery using a self-fixing synthetic prosthesis in traumatic aneurysm]. *Grudn Khir*. 1988(6):84-6.
113. Volodos NL. Historical perspective: The first steps in endovascular aortic repair: how it all began. *J Endovasc Ther*. 2013;20 Suppl 1:13-23.
114. Ivancev K, Malina M, Lindblad B, Chuter TA, Brunkwall J, Lindh M, et al. Abdominal aortic aneurysms: experience with the Ivancev-Malmo endovascular system for aortomoniliac stent-grafts. *J Endovasc Surg*. 1997;4(3):242-51.
115. Park JH, Chung JW, Choo IW, Kim SJ, Lee JY, Han MC. Fenestrated stent-grafts for preserving visceral arterial branches in the treatment of abdominal aortic aneurysms: preliminary experience. *J Vasc Interv Radiol*. 1996;7(6):819-23.
116. de Niet A, Zeebregts CJ, Reijnen M, Fenestrated Anaconda Study g. Outcomes after treatment of complex aortic abdominal aneurysms with the fenestrated Anaconda endograft. *J Vasc Surg*. 2020;72(1):25-35 e1.
117. Kotelis D, Schleimer K, Foldenauer C, Jalaie H, Grommes J, Jacobs MJ, et al. Operative and Midterm Outcomes of the Fenestrated Anaconda Stent-Graft in the Endovascular Treatment of Juxtarenal, Suprarenal, and Type IV Thoracoabdominal Aortic Aneurysms. *J Endovasc Ther*. 2016;23(6):930-5.
118. Blankensteijn LL, Dijkstra ML, Tielliu IF, Reijnen MM, Zeebregts CJ, Dutch Fenestrated Anaconda Research G. Midterm results of the fenestrated Anaconda endograft for short-neck infrarenal and juxtarenal abdominal aortic aneurysm repair. *J Vasc Surg*. 2017;65(2):303-10.
119. Colgan FE, Bungay PM, Burfitt N, Hatrick A, Clarke MJ, Davies AH, et al. Operative and 1-Year Outcomes of the Custom-Made Fenestrated Anaconda Aortic Stent Graft-A UK Multicenter Study. *Ann Vasc Surg*. 2018;46:257-64.

120. Midy D, Becquemin JP, Mialhe C, Frisch N, Martinez R, Caradu C, et al. Results of the French Multicentric Study of ANACONDA Fenestrated Endografts in the Treatment of Complex Aortic Pathologies (EFEFA Registry). *Ann Vasc Surg.* 2017;43:151-65.
121. Brunkwall J. How to design the optimal stent graft--what have we learnt? *Scand J Surg.* 2008;97(2):191-4.
122. Farber MA, Eagleton MJ, Mastracci TM, McKinsey JF, Vallabhaneni R, Sonesson B, et al. Results from multiple prospective single-center clinical trials of the off-the-shelf p-Branch fenestrated stent graft. *J Vasc Surg.* 2017;66(4):982-90.
123. Kitagawa A, Greenberg RK, Eagleton MJ, Mastracci TM. Zenith p-branch standard fenestrated endovascular graft for juxtarenal abdominal aortic aneurysms. *J Vasc Surg.* 2013;58(2):291-300.
124. Resch TA, Dias NV, Sobocinski J, Sonesson B, Roeder B, Haulon S. Development of off-the-shelf stent grafts for juxtarenal abdominal aortic aneurysms. *Eur J Vasc Endovasc Surg.* 2012;43(6):655-60.
125. Sobocinski J, d'Utra G, O'Brien N, Midulla M, Maurel B, Guillou M, et al. Off-the-shelf fenestrated endografts: a realistic option for more than 70% of patients with juxtarenal aneurysms. *J Endovasc Ther.* 2012;19(2):165-72.
126. Ou J, Cheng SW, Chan YC. The compatibility of p-branch "off-the-shelf" fenestrated endovascular graft in Asian patients with juxtarenal aortic aneurysm. *J Vasc Surg.* 2015;61(6):1417-23.
127. Kristmundsson T, Sveinsson M, Bjorses K, Tornqvist P, Dias N. Suitability of the Zenith p-Branch Standard Fenestrated Endovascular Graft for Treatment of Ruptured Abdominal Aortic Aneurysms. *J Endovasc Ther.* 2015;22(5):760-4.
128. Bargay-Juan P, Gomez-Palones FJ, Pepen-Moqueete LA, Plaza-Martinez A, Zaragoza-Garcia JM, Morales-Gisbert SM. Applicability of Zenith p-branch Standard Fenestrated Endograft in Our Series. *Ann Vasc Surg.* 2016;33:187-93.
129. Bosiers M, Kolbel T, Resch T, Tsilimparis N, Torsello G, Austermann M. Early and mid-term results from a postmarket observational study of Zenith t-Branch thoracoabdominal endovascular graft. *J Vasc Surg.* 2021.
130. Malekpour F, Scott CK, Kirkwood ML, Timaran CH. Sequential Catheterization and Progressive Deployment of the Zenith(R) t-Branch Device for Branched Endovascular Aortic Aneurysm Repair. *Cardiovasc Intervent Radiol.* 2021;44(1):156-60.
131. Spanos K, Theodorakopoulou M, Debus ES, Rohlffs F, Heidemann F, Kolbel T, et al. Accurate Orientation of the t-Branch Off-the-Shelf Multibranched Endograft After Deployment in Urgent Cases. *J Endovasc Ther.* 2018;25(4):442-9.
132. Tsilimparis N, Fiorucci B, Debus ES, Rohlffs F, Kolbel T. Technical Aspects of Implanting the t-Branch Off-the-Shelf Multibranched Stent-Graft for Thoracoabdominal Aneurysms. *J Endovasc Ther.* 2017;24(3):397-404.
133. Bisdas T, Donas KP, Bosiers M, Torsello G, Austermann M. Anatomical suitability of the T-branch stent-graft in patients with thoracoabdominal aortic aneurysms treated using custom-made multibranched endografts. *J Endovasc Ther.* 2013;20(5):672-7.

134. Gasper WJ, Reilly LM, Rapp JH, Grenon SM, Hiramoto JS, Sobel JD, et al. Assessing the anatomic applicability of the multibranched endovascular repair of thoracoabdominal aortic aneurysm technique. *J Vasc Surg.* 2013;57(6):1553-8; discussion 8.
135. Konstantinou N, Antonopoulos CN, Jerkku T, Banafsche R, Kolbel T, Fiorucci B, et al. Systematic review and meta-analysis of published studies on endovascular repair of thoracoabdominal aortic aneurysms with the t-Branch off-the-shelf multibranched endograft. *J Vasc Surg.* 2020;72(2):716-25 e1.
136. AbuRahma AF, Campbell J, Stone PA, Nanjundappa A, Jain A, Dean LS, et al. The correlation of aortic neck length to early and late outcomes in endovascular aneurysm repair patients. *J Vasc Surg.* 2009;50(4):738-48.
137. Galanakis N, Kontopodis N, Tavlas E, Tsetis D, Ioannou CV. Does a previous aortic endograft confer any protective effect during abdominal aortic aneurysm rupture? Systematic review and meta-analysis of comparative studies. *Vascular.* 2020;28(3):241-50.
138. Bannazadeh M, Beckerman WE, Korayem AH, McKinsey JF. Two-year evaluation of fenestrated and parallel branch endografts for the treatment of juxtarenal, suprarenal, and thoracoabdominal aneurysms at a single institution. *J Vasc Surg.* 2020;71(1):15-22.
139. Ou J, Chan YC, Cheng SW. A Systematic Review of Fenestrated Endovascular Repair for Juxtarenal and Short-Neck Aortic Aneurysm: Evidence So Far. *Ann Vasc Surg.* 2015;29(8):1680-8.
140. Chaikof EL, Blankensteijn JD, Harris PL, White GH, Zarins CK, Bernhard VM, et al. Reporting standards for endovascular aortic aneurysm repair. *J Vasc Surg.* 2002;35(5):1048-60.
141. Unno N, Yamamoto N, Higashiura W, Suzuki M, Mano Y, Sano M, et al. Early experience with fenestrated stent grafts for treatment of juxtarenal aortic aneurysm. *Ann Vasc Dis.* 2013;6(3):642-50.
142. Kelso RL, Lyden SP, Butler B, Greenberg RK, Eagleton MJ, Clair DG. Late conversion of aortic stent grafts. *J Vasc Surg.* 2009;49(3):589-95.
143. Tiesenhausen K, Hessinger M, Konstantiniuk P, Tomka M, Baumann A, Thalhammer M, et al. Surgical conversion of abdominal aortic stent-grafts--outcome and technical considerations. *Eur J Vasc Endovasc Surg.* 2006;31(1):36-41.
144. Kansal V, Nagpal S, Jetty P. Editor's Choice - Late Open Surgical Conversion after Endovascular Abdominal Aortic Aneurysm Repair. *Eur J Vasc Endovasc Surg.* 2018;55(2):163-9.
145. Martin Z, Greenberg RK, Mastracci TM, Eagleton MJ, O'Callaghan A, Bena J. Late rescue of proximal endograft failure using fenestrated and branched devices. *J Vasc Surg.* 2014;59(6):1479-87.
146. Verhoeven EL, Katsargyris A, Bekkema F, Oikonomou K, Zeebregts CJ, Ritter W, et al. Editor's Choice - Ten-year Experience with Endovascular Repair of Thoracoabdominal Aortic Aneurysms: Results from 166 Consecutive Patients. *Eur J Vasc Endovasc Surg.* 2015;49(5):524-31.

147. Jain V, Banga P, Vallabhaneni R, Eagleton M, Oderich G, Farber MA. Endovascular treatment of aneurysms using fenestrated-branched endografts with distal inverted iliac limbs. *J Vasc Surg.* 2016;64(3):600-4.
148. Maurel B, Resch T, Spear R, Roeder B, Bracale UM, Haulon S, et al. Early experience with a modified preloaded system for fenestrated endovascular aortic repair. *J Vasc Surg.* 2017;65(4):972-80.
149. Mastracci TM, Eagleton MJ, Kuramochi Y, Bathurst S, Wolski K. Twelve-year results of fenestrated endografts for juxtarenal and group IV thoracoabdominal aneurysms. *J Vasc Surg.* 2015;61(2):355-64.
150. Simons JP, Podder S, Dossabhoy SS, Wyman AS, Arous EJ, Judelson DR, et al. Fenestrated/Branched Endovascular Aortic Aneurysm Repair Using a Supraceliac Aortic Proximal Seal Zone Versus an Infraceliac Aortic Proximal Seal Zone. *Ann Vasc Surg.* 2020;62:213-22.
151. Motta F, Crouner JR, Kalbaugh CA, Marston WA, Pascarella L, McGinagle KL, et al. Outcomes and complications after fenestrated-branched endovascular aortic repair. *J Vasc Surg.* 2019;70(1):15-22.
152. Dossabhoy SS, Simons JP, Crawford AS, Aiello FA, Judelson DR, Arous EJ, et al. Impact of acute kidney injury on long-term outcomes after fenestrated and branched endovascular aortic aneurysm repair. *J Vasc Surg.* 2019.
153. Ou J, Tang AYS, Chiu TL, Chow KW, Chan YC, Cheng SWK. Haemodynamic Variations of Flow to Renal Arteries in Custom-Made and Pivot Branch Fenestrated Endografting. *Eur J Vasc Endovasc Surg.* 2017;53(1):133-9.
154. Mohamed N, Galyfos G, Anastasiadou C, Sachmpatzidis I, Kikiras K, Papapetrou A, et al. Fenestrated Endovascular Repair for Pararenal or Juxtarenal Abdominal Aortic Aneurysms: a Systematic Review. *Ann Vasc Surg.* 2020;63:399-408.
155. England A, Garcia-Finana M, Fisher RK, Naik JB, Vallabhaneni SR, Brennan JA, et al. Migration of fenestrated aortic stent grafts. *J Vasc Surg.* 2013;57(6):1543-52.
156. Karkkainen JM, Tenorio ER, Jain A, Mendes BC, Macedo TA, Pather K, et al. Outcomes of target vessel endoleaks after fenestrated-branched endovascular aortic repair. *J Vasc Surg.* 2020;72(2):445-55.
157. de Souza LR, Oderich GS, Farber MA, Haulon S, Banga PV, Pereira AH, et al. Editor's Choice - Comparison of Renal Outcomes in Patients Treated by Zenith((R)) Fenestrated and Zenith((R)) Abdominal Aortic Aneurysm Stent grafts in US Prospective Pivotal Trials. *Eur J Vasc Endovasc Surg.* 2017;53(5):648-55.
158. Shahverdyan R, Majd MP, Thul R, Braun N, Gawenda M, Brunkwall J. F-EVAR does not Impair Renal Function more than Open Surgery for Juxtarenal Aortic Aneurysms: Single Centre Results. *Eur J Vasc Endovasc Surg.* 2015;50(4):432-41.
159. Tenorio ER, Oderich GS, Sandri GA, Ozbek P, Karkkainen JM, Vrtiska T, et al. Prospective nonrandomized study to evaluate cone beam computed tomography for technical assessment of standard and complex endovascular aortic repair. *J Vasc Surg.* 2020;71(6):1982-93 e5.
160. Tornqvist P, Dias N, Sonesson B, Kristmundsson T, Resch T. Intra-operative cone beam computed tomography can help avoid reinterventions and reduce CT follow up after infrarenal EVAR. *Eur J Vasc Endovasc Surg.* 2015;49(4):390-5.

161. Tran K, McFarland G, Sgroi M, Lee JT. Duplex ultrasound surveillance of renal branch grafts after fenestrated endovascular aneurysm repair. *J Vasc Surg.* 2019;70(4):1048-55.
162. George J, Tadros RO, Rao A, Png CYM, Han DK, Ilonzo N, et al. Duplex Ultrasound Can Successfully Identify Endoleaks and Renovisceral Stent Patency in Patients Undergoing Complex Endovascular Aneurysm Repair. *Vasc Endovascular Surg.* 2020:1538574420980605.

Appendix

Study inclusion- and exclusion criteria for paper III, provided by Cook Research Incorporated.

Inclusion Criteria

Pararenal or juxtarenal AAA ≥ 5.0 cm in diameter

Pararenal or juxtarenal AAA with history of growth ≥ 5.0 cm / year

Exclusion Criteria

General

Age < 18 years

Life expectancy < 2 years

Pregnant or breast feeding

Inability or refusal to give informed consent

Unwilling or unable to comply with follow-up schedule

Medical

Cultural objection to receipt of blood or blood products

Allergy to stainless steel, polyester, solder, gold or nitinol

Anaphylactic reaction to contrast that cannot be adequately pre-medicated

Uncorrectable coagulopathy

Previous orificial stent in any vessel to be accommodated with the SMA fenestration or pivot fenestrations that protrudes into the aorta

Anatomical

Proximal sealing zone length < 15 mm (between the distal-most aspect of the celiac artery and the proximal end of the aneurysmal aorta)

Greater than 10% increase in diameter over the length of the proximal sealing zone

Proximal sealing zone angulated > 60 degrees relative to the centerline of the aneurysm and > 45 degrees relative to the supraceliac aorta

Aortic neck diameter > 31 mm or < 21 mm (outer diameter)

Renal and visceral vessel anatomy incompatible with graft

Non-bifurcated segment of any artery to be stented < 15 mm in length if use of covered stents is planned

Renal artery or SMA stenosis $> 80\%$

Inability to maintain at least one patent hypogastric artery

Prohibitive occlusive disease, tortuosity, calcification, or thrombus of the proximal sealing zone

Tortuosity, calcification, or arterial diameter not conducive to placement of the introducer with use of a conduit