



J Res Med Sci. 2013 Jul; 18(7): 623–625.

PMCID: PMC3897033

PMID: [24516498](#)

## A significant response to sunitinib in a patient with anaplastic thyroid carcinoma

[Enrique Grande](#), [Jaume Capdevila](#),<sup>1</sup> [Juan José Díez](#),<sup>2</sup> [Federico Longo](#), and [Alfredo Carrato](#)

Department of Medical Oncology, Ramón Y Cajal University Hospital, Madrid, Spain

<sup>1</sup>Department of Medical Oncology, Vall d'Hebrón University Hospital, Barcelona, Universidad Autónoma de Barcelona, Spain

<sup>2</sup>Department of Endocrinology, Ramón Y Cajal University Hospital, Madrid, Spain

**Address for correspondence:** Dr. Enrique Grande, Servicio de Oncología Médica, Hospital Ramón Y Cajal, Carretera de Colmenar Viejo Km 9, 100, Madrid, Spain. E-mail: [egrande@oncologiahrc.com](mailto:egrande@oncologiahrc.com)

Received 2012 Jul 22; Revised 2012 Dec 2; Accepted 2013 Jan 6.

**Copyright** : © Journal of Research in Medical Sciences

This is an open-access article distributed under the terms of the Creative Commons Attribution-Noncommercial-Share Alike 3.0 Unported, which permits unrestricted use, distribution, and reproduction in any medium, provided the original work is properly cited.

### Abstract

Anaplastic thyroid cancer (ATC) is a rare disease with an incidence of less than three cases per million of habitants in western countries. ATC accounts for 1-10% of all tumors derived from the thyroid gland. Classic chemotherapy approach based on platinum and anthracyclines regimens have been considered standard for the last decades. Novel multitarget agents have shown promising responses; however, no positive randomized clinical trials are available up to now. To our knowledge, the case we are presenting here is the first reported case showing clinical and visual activity using sunitinib as a salvage treatment in an ATC patient who was not fit to receive systemic chemotherapy treatment.

**Keywords:** Anaplastic thyroid cancer, angiogenesis, sunitinib

### INTRODUCTION

Thyroid cancer is the most common endocrine malignancy.[1] More than 90% of all thyroid cancers derive from the thyroid follicular cells, including papillary thyroid cancers (PTC), follicular thyroid cancers (FTC), or Hórhle cell carcinomas. Anaplastic thyroid cancers (ATC) are estimated to comprise 1.3-9.8% of thyroid malignancies and they usually arise from pre-existing PTC or FTC.[2] Despite more aggressive systemic therapies and better surgical techniques, survival of patients with ATC has barely changed in decades and median overall survival ranges from 5 to 7 months with only 20% of patients expected to be alive 1 year after diagnosis.[2] Therefore, new drugs are urgently needed for these patients.

A greater understanding in the molecular biology of thyroid cancer highlights the significance of several gene mutations of main intracellular pathways related with the pathogenesis of these tumors, such as p53 (55%), RAS (22%), BRAF (26%),  $\beta$ -catenin (38%), PI3K (17%), and PTEN (12%).[3] Additionally, amplification in gene copy number of epidermal growth factor receptor (EGFR), vascular endothelial growth factor receptor (VEGFR-1, and -2), platelet derived growth factor (PDGFR- $\alpha$  and - $\beta$ ), stem cell factor receptor (c-Kit), pyruvate dehydrogenase kinase (PDK1), protein kinase B AKT1, and hepatocyte growth factor receptor (c-MET) have also been observed. The thyroid gland is a highly vascular tissue and

angiogenesis plays a key role in tumor proliferation and dissemination of ATCs.[4] We currently have several multi-targeted tyrosine kinase inhibitors that block receptors involved not only in tumor growth but also in angiogenesis.

As far as we know, the case we are presenting here is the first reported case showing clinical and visual activity with sunitinib as a salvage treatment in an ATC patient.

## CASE PRESENTATION

---

A 79-year-old man with a medical history of hypertension and diabetes was diagnosed with a localized papillary thyroid carcinoma was admitted at the Ramón y Cajal University Hospital Madrid (Spain). There was no evidence of distant metastasis at diagnosis. The patient underwent a total thyroidectomy and a suspicious right-cervical lymph node was also resected. The pathological stage after surgery was pT2 pN1b M0. Following surgery, thyroid ablation therapy with 150 mCi of radioactive iodine ( $^{131}\text{I}$ ) was given. One year later, although no evidence of distant spread of the disease was observed in a whole body scan, serum thyroglobulin levels were 24 ng/ml (normal range <3 ng/mL), despite suppressive thyroxin therapy. Therefore, a second course of  $^{131}\text{I}$  was administered, achieving a total dose of 350 mCi of  $^{131}\text{I}$ . Two years after surgery, during a follow-up visit, it was noted that the patient had recurrence of his disease, due to a rapid appearance of a midline hard, rigid, painful, and violet neck mass, just below the scar of previous thyroidectomy, and bilateral cervical lymph nodes [Figure 1a] together with moderate dyspnoea. Macroscopic neck mass size was initially measured as 6.5 × 3.5 cm. Multiple and bilateral lung metastasis were detected in a computer tomography (CT) scan. Fine needle aspiration cytology of the thyroid mass revealed anaplastic thyroid carcinoma cells. Based on recent reported data with multi-target tyrosine kinase inhibitors in iodine-refractory thyroid cancer patients added to the age, performance status, and comorbidities of the patient, we decided to start treatment with sunitinib (SUTENT<sup>®</sup>, Pfizer Inc, NY) as a single agent under “off-label” use request from a clinical trial. The patient signed the appropriate informed consent and local legal procedures were followed. Sunitinib was administered orally at 50 mg per day for 4 weeks followed by 2 weeks of rest. A weekly follow up was undertaken and at the first week of treatment a reduction in neck tumor bulk was noted (6.0 × 3.0 cm) with clinical improvement of pain and less violet neck mass [Figure 1b]. After the start of the treatment for 4 weeks the tumor mass clearly showed a reduction in size (3.0 × 1.5 cm) and skin color was almost normal [Figure 1c]. The patient reported neither pain nor dyspnoea at this time and Eastern Cooperative Oncology Group (ECOG) performance status was 0. After the end of second cycle, 12 weeks from the beginning of treatment, a complete macroscopic response of the ATC in the neck was achieved [Figure 1d] and it was maintained for 8 more weeks. Tolerability of sunitinib was acceptable with grade 2 asthenia and grade 2 neutropenia with only one week of rest needed to recover after third cycle. However, response in tumor size over neck mass did not correlate with lung metastasis shrinkage that were stable after 12-20 weeks of treatment. Unfortunately, the patient died as a result of a massive upper gastrointestinal bleeding 5 months after the start of sunitinib treatment and while the patient was still on treatment.

## CONCLUSION

---

There is a lack of large clinical trials addressing the best treatment option for disseminated ATC patients. It has been reported recently, the largest ever randomized trial in ATC that compared carboplatin plus paclitaxel given for six cycles with or without CA4P (a vascular disrupting agent). Despite the fact that only 80 of 180 planned patients were recruited (due to a slow recruitment rate), a strong trend in improved overall survival was observed; 5.2 months versus 4.0 months for the CA4P and control arm respectively (Hazard Ratio 0.95:95% CI, 0.38-1.10).[5] Nagaiah *et al.* reported the treatment of 16 metastatic ATC patients with sorafenib.[6] Two (13%) out of 15 evaluable patients achieved partial response by Response Evaluation Criteria In Solid Tumors (RECIST) criteria, however, median progression free survival was only 1.9 months (95% CI: 1.7-4.1) and median overall survival was 3.9 months (95% CI: 2.7-7.1). Our group tested sorafenib activity in patients with metastatic thyroid carcinomas including three patients with ATC. One out of 3 (33%) patients achieved an objective partial response with a median overall survival of 5 months.[7] Axitinib is a novel multitarget agent with a more selective kinase inhibition profile against angiogenesis-involved receptors. Two of the 60 patients with thyroid cancer treated with axitinib in a non-

controlled phase 2 trial had ATC histology. One of these two patients achieved partial response radiologically and the authors concluded that the activity of axitinib was independent of tumor histology. [8]

Sunitinib is an oral multitargeted inhibitor of several tyrosine kinase receptors including glial cell line-derived neurotrophic factor (RET) and angiogenesis-related VEGFRs (-1, -2 and -3) and PDGFRs ( $\alpha$  and  $\beta$ ) receptors.[9] Up to five non-controlled trials have been reported up to now with sunitinib as a single agent treatment of differentiated thyroid cancer (DTC) and/or medullary thyroid cancer (MTC) thyroid cancers.[10,11,12,13,14] The largest study was conducted by Cohen *et al.* in 43 patients, mostly DTC. Clinical benefit rate, including complete and partial responses plus disease stabilizations was 81% in those patients with DTC histology.[11] Ravaud *et al.* conducted a trial in 12 patients with DTC and 8 patients with MTC.[13] The clinical benefit was 75-100% in DTC and MTC respectively. Recently, Carr *et al.* reported a study that included 35 patients (28 DTC, 7 MTC).[10] Objective responses were observed in 11 patients (31%; 95 CI: 16-47%) including one patient who achieved a complete response. The median time to tumor progression was 12.8 months (95% CI, 8.9 months-not reached). Unfortunately, none of the recruited patients in these trials treated with sunitinib presented ATC histologic subtype and thus the effect that this drug may have on the treatment of these patients remains elusive.

To our knowledge, this is the first reported case showing clinical activity with sunitinib in ATC patients. The impressive response induced in neck tumor mass with no impact in distant metastases suggests that there may be different genetic features between primary and secondary lesions. Although not frequent, it has been largely described as the existence of paradoxical responses between the primary tumor and the distant metastasis. Tumor heterogeneity and the accumulation of molecular aberrations when tumor progresses make that metastasis may become more resistance to local and systemic treatment than the primary tumors.[15]

Despite the aggressive behavior of ATC, we have seen a rapid response of a targeted agent showing the efficacy of these drugs in this setting. However, effective predictive biomarkers are needed, especially in this scenario where second options are rarely available due to the dramatic outcome of these patients.

The toxicity profile of targeted therapies has been generally described as favorable when compared with classical cytotoxic drugs, although, potentially fatal side effects have been reported, mainly related with anti-angiogenic effects and cardiovascular toxicity.[16]

Patients with tumors with an undifferentiated histology are more difficult to recruit in trials and thus we cannot extrapolate results from differentiated samples due to differences in tumor biology. However, there is an increasing body of evidence showing that counteracting angiogenesis may become a valid strategy in aggressive thyroid carcinomas. Further prospective and randomized trials are needed to evaluate the efficacy and also the quality of life of patients treated with novel oral targeted agents when compared with the classical chemotherapy-based approach of doxorubicin, platinum, and combinations of taxanes.

## Footnotes

---

**Source of Support:** Nil

**Conflict of Interest:** None declared.

## REFERENCES

---

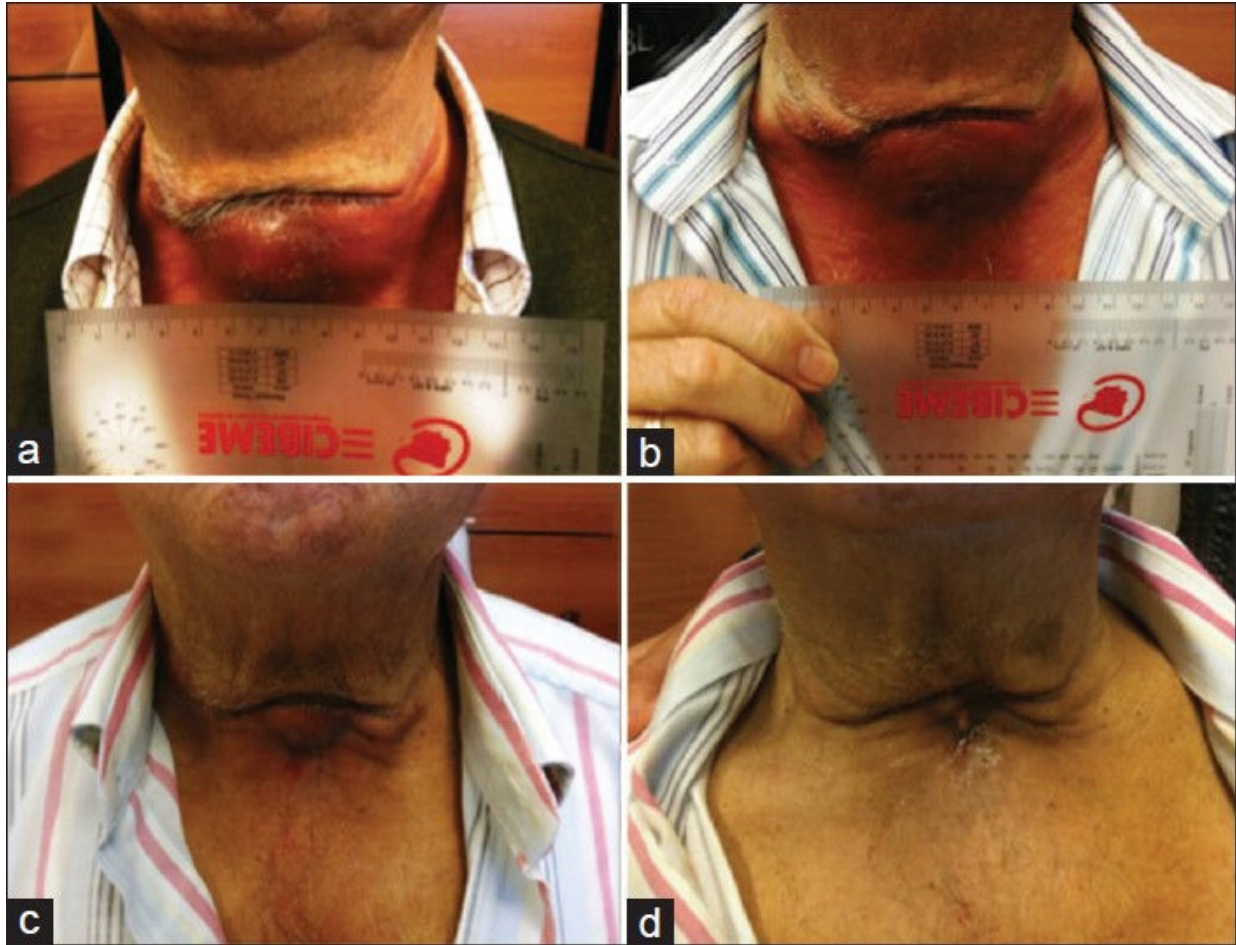
1. Jemal A, Bray F, Center MM, Ferlay J, Ward E, Forman D. Global cancer statistics. *CA Cancer J Clin.* 2011;61:69–90. [PubMed: 21296855]
2. Smallridge RC, Marlow LA, Copland JA. Anaplastic thyroid cancer: Molecular pathogenesis and emerging therapies. *Endocr Relat Cancer.* 2009;16:17–44. [PMCID: PMC2829440] [PubMed: 18987168]
3. Smallridge RC, Copland JA. Anaplastic thyroid carcinoma: Pathogenesis and emerging therapies. *Clin Oncol (R Coll Radiol)* 2010;22:486–97. [PMCID: PMC3905320] [PubMed: 20418080]
4. Gule MK, Chen Y, Sano D, Frederick MJ, Zhou G, Zhao M, et al. Targeted therapy of VEGFR2 and EGFR significantly inhibits growth of anaplastic thyroid cancer in an orthotopic murine model. *Clin Cancer Res.* 2011;17:2281–91. [PMCID: PMC3079006] [PubMed: 21220477]

5. Sosa JA, Elisei R, Jarzab B, Bal CS, Koussis H, Gramza AW, et al. A randomized phase II/III trial of a tumor vascular disrupting agent foscetabulin tromethamine (CA4P) with carboplatin (C) and paclitaxel (P) in anaplastic thyroid cancer (ATC): Final survival analysis for the FACT trial. *J Clin Oncol*. 2011;29(15):5502.
6. Savvides P, Nagaiah G, Lavertu PN, Fu P, Wright JJ, Chapman R, et al. Phase II Trial of Sorafenib in Patients with Advanced Anaplastic Carcinoma of the Thyroid. *Thyroid*. 2012;27:15–16. [PMCID: PMC3643255] [PubMed: 23113752]
7. Capdevila J, Iglesias L, Halperin I, Segura A, Martínez-Trufero J, Vaz MA, et al. Sorafenib in metastatic thyroid cancer. *Endocr Relat Cancer*. 2012;19(2):209–16. [PubMed: 22285864]
8. Cohen EE, Rosen LS, Vokes EE, Kies MS, Forastiere AA, Worden FP, et al. Axitinib is an active treatment for all histologic subtypes of advanced thyroid cancer: Results from a phase II study. *J Clin Oncol*. 2008;26:4708–13. [PMCID: PMC4859206] [PubMed: 18541897]
9. Faivre S, Raymond E, Boucher E, Douillard J, Lim HY, Kim JS, et al. Safety and efficacy of sunitinib in patients with advanced hepatocellular carcinoma: An open-label, multicentre, phase II study. *Lancet Oncol*. 2009;10:794–800. [PubMed: 19586800]
10. Carr LL, Mankoff DA, Goulart BH, Eaton KD, Capell PT, Kell EM, et al. Phase II study of daily sunitinib in FDG-PET-positive, iodine-refractory differentiated thyroid cancer and metastatic medullary carcinoma of the thyroid with functional imaging correlation. *Clin Cancer Res*. 2010;16:5260–8. [PMCID: PMC3063514] [PubMed: 20847059]
11. Cohen EE, Needles BM, Cullen KJ, Wong SJ, Wade JL, Ivy SP, et al. Phase 2 study of sunitinib in refractory thyroid cancer. *J Clin Oncol*. 2008;26:6025.
12. Harvey RD, Kauh JS, Ramalingam SS, Lewis CM, Chen Z, Lonial S, et al. Combination therapy with sunitinib and bortezomib in adult patients with radioiodine refractory thyroid cancer. *J Clin Oncol*. 2010;28:15s.
13. Ravaud A, de la Fouchardiere C, Courbon F, Asselineau J, Klein M, Nicoli-Sire P, et al. Sunitinib in patients with refractory advanced thyroid cancer: The THYSU phase II trial. *J Clin Oncol*. 2008;26:6058.
14. De Souza JA, Busaidy N, Zimrin A, Seiwert TY, Villaflor VM, Poluru KB, et al. Phase II trial of sunitinib in medullary thyroid cancer (MTC) *J Clin Oncol*. 2010;28:15s.
15. Gerlinger M, Rowan AJ, Horswell S, Larkin J, Endesfelder D, Gronroos E, et al. Intratumor heterogeneity and branched evolution revealed by multiregion sequencing. *N Engl J Med*. 2012;366:883–92. [PMCID: PMC4878653] [PubMed: 22397650]
16. Tuttle RM, Ball DW, Byrd D, Dilawari RA, Doherty GM, Duh QY, et al. Thyroid carcinoma. *J Natl Compr Canc Netw*. 2010;8:1228–74. [PubMed: 21081783]

## Figures and Tables

---

Figure 1



Dramatic objective response with over secondary anaplastic thyroid cancer developed under the scarce of a previous thyroidectomy of a differentiated tumor, (a) tumor before starting sunitinib, (b and c) response induced by sunitinib after 1 and 4 weeks of systemic treatment with sunitinib respectively, (d) a complete response after 2 cycles (sunitinib given at 50 mg/day for 4 weeks followed by 2 weeks of rest per cycle)

---

Articles from Journal of Research in Medical Sciences : The Official Journal of Isfahan University of Medical Sciences are provided here courtesy of **Wolters Kluwer -- Medknow Publications**