

BMJ Case Reports

Bilateral osteochondral defects of the patellae in an 11-year-old girl

Journal:	<i>BMJ Case Reports</i>
Manuscript ID	bcr-2020-240790.R1
Manuscript Type:	Case report
Date Submitted by the Author:	06-Mar-2021
Complete List of Authors:	Rodriguez Ruiz, Miguel; Royal Free London NHS Trust, Trauma and Orthopaedics; University College London Igah, Ibidumo; Royal Free London NHS Trust, Trauma and Orthopaedics Iranpour, Farhad; Royal Free London NHS Trust, Trauma and Orthopaedics; Imperial College London, MSK Lab Patel, Akash; Royal Free London NHS Trust, Trauma and Orthopaedics; University College London
Keywords:	Orthopaedic and trauma surgery < Surgery, Patellofemoral pain < Sports and exercise medicine, Sports and exercise medicine

BMJ Case Reports

TITLE OF CASE

Bilateral osteochondral defects of the patellae in an 11-year-old girl

SUMMARY

Osteochondral defect of osteochondritis dissecans (OCD) of the knee usually affects young, active populations. It is a challenging diagnosis as patients typically present with poorly localised activity-related pain, which is non-specific and covers many differentials.

We present an active 11-year old girl with bilateral osteochondral defects of the patellae: a rare clinical disorder which was affecting her sporting activities. She had a 12-month history of bilateral anterior knee pain before the diagnosis was achieved with appropriate imaging. Her pain significantly improved with activity modification and physiotherapy. Follow-up will require outpatient clinic assessment and imaging to determine if non-operative management continues to be successful or surgery may be required. This case report emphasizes the importance of appropriate high index of suspicion when managing patients with non-specific knee pain. It also demonstrates the importance of judicious use of imaging to avoid a missed or delayed diagnosis.

BACKGROUND

Osteochondral defects (OCDs) are acquired focal areas of damaged subchondral bone and overlying articular cartilage. These lesions can remain stable in situ or become unstable: either partially attached to their normal position in a joint, or completely detached to form a loose body, with subsequent potential development of degenerative joint disease. OCD was classified by Clanton and DeLee into stages 1-4 (table 1) according to the stability of the osteochondral lesion. Stage 1 and 2 lesions are stable whilst stage 3 and 4 lesions are deemed unstable.[1]

Table 1:

Clanton Classification of Osteochondritis Dissecans (Clanton and DeLee)

Stage 1	Depressed osteochondral fracture with intact overlying cartilage
Stage 2	Incomplete avulsion of osteochondral fragment, still attached by osseous bridge
Stage 3	Complete avulsion leads to a detached, non-displaced osteochondral fragment
Stage 4	Displaced osteochondral fragment as a loose body

The natural history and exact pathophysiological mechanism of OCDs remain poorly understood and controversial.[2,3] Proposed causes include trauma, repetitive microtrauma, local ischaemia and hereditary factors.[4] The juvenile form of OCD occurs in skeletally immature patients who have open physes whereas the adult form occurs in skeletally mature patients whose physes

have now closed. OCDs are rarely seen below the age of 6 and most commonly affect juvenile patients between the ages of 12-19 with an incidence of 11.2 per 100,000.[5] However, some OCDs remain undetected and untreated until later adult life when a poorer prognosis is expected.[6]

The most common site for juvenile OCD in the knee is in the posterolateral aspect of the medial femoral condyle.[7,8,9] A study by Hefti et al. showed 77% of lesions affected the medial femoral condyle (lateral aspect 51%, central aspect 19% and medial aspect 7%), 17% affected the lateral femoral condyle, 7% affected the patella, 1% affected the trochlea and only 0.2% affected the tibial plateau.[10] The frequency of bilateral OCDs varies in the literature, typically in the range of 14 – 30 % with no preference for laterality.[4]

Most juvenile patients with OCD present with vague activity-related knee pain and/or swelling, often leading to a considerable delay in diagnosis which is dependent on plain radiographs and MRI.[11] It is vital to make an early diagnosis to maximize the opportunity for conservative management and avoid the need for surgical intervention, which carries a poorer prognosis especially for OCDs sited in rare locations.[12, 13]

CASE PRESENTATION

An 11-year-old girl was referred by her general practitioner (GP) to our orthopaedics outpatient clinic with bilateral non-specific anteroinferior knee pain of 12-month duration. Her pain was worse in the right knee compared to the left knee. The GP initially thought the patient was suffering from a benign condition, such as Osgood-Schlatter's disease or Sinding-Larsen-Johansson disease but made the referral after plain radiography showed possible bilateral retropatella OCDs (figures 1 and 2).

On review in the orthopaedic outpatient clinic, the patient described diffuse pain over the medial and lateral aspects of both knee joints. She denied any preceding trauma to her knees. However, she was very active, taking part in football, dodgeball and rounders at school regularly. These sporting activities aggravated her pain and her mobility was impaired if she ran extensively. She had a background history of left femoral torsion, which was being managed non-operatively under the care of a paediatric orthopaedic surgeon.

On examination, there was no leg length discrepancy or muscle wasting in her lower limbs. There was left femoral torsion with an increased hip anteversion of about 20° compared with the right hip (internal rotation in the left 80° while right was 60°). Abduction, adduction, flexion and extension were similar in both hips. On examination of the knees, there was no swelling or tenderness around her quadriceps or patellar tendon. The active range of motion in both knees was 0-130°. She had normal patella tracking and ligament examination bilaterally. Both lower limbs were neurovascularly intact.

INVESTIGATIONS

At her first orthopaedic visit, the patient had plain radiographs of the hip and repeat plain radiographs of the knees; anterior-posterior (AP), lateral and skyline views (merchant views). Plain radiographs of the hip were unremarkable. The AP views of the knees showed no significant finding (figure 3), but the lateral and skyline views detected bilateral retropatella OCDs (Figure 4 and Figure 5). MRI scans of her knees were subsequently requested and reviewed in the follow-up clinic. These confirmed the diagnoses, assessed the stability of the OCDs, and aided in the management planning.

The MRI confirmed bilateral OCDs located in the inferior poles of the lateral patellar facets. It also showed borderline bilateral patella alta (Biedert Patellotrochlear Index of 0.18) and trochlear dysplasia.[14] The OCD in the right knee (figure 6) measured 1.2 cm in width and approximately 1.5 cm in the craniocaudal dimension. There was associated thinning of the overlying cartilage with synovial fluid tracking behind the unstable OCD (stage 3).[9] The OCD in the left knee (figure 7) was smaller, measuring approximately 1.5cm in width and 0.5cm craniocaudally. The overlying articular cartilage was preserved, and there was minimal extension of fluid partially between the osteochondral fragment and subarticular marrow (due to the osseous bridge), making it a stable OCD (stage 2).

DIFFERENTIAL DIAGNOSIS

Based on the clinical history and activity level of the patient, the differential diagnosis for the bilateral non-specific knee pain was extensive. This included: patellofemoral pain syndrome, Osgood-Schlatter Disease, Sinding-Larsen-Johansson syndrome, patellar tendinopathy, chondromalacia patellae, Hoffa's fat pad syndrome, OCD, Brodie's abscess, chronic osteomyelitis, dorsal defect of the patella (DDP) and chondroblastoma. It is also important to remember that hip pathology such as slipped upper femoral epiphyses can present as referred pain to the knee. However, on review of the radiological images we were able to narrow down the diagnosis to DDP, OCD and chondroblastoma of the patella.

Chondroblastoma's predominantly occur in young patients but tend to cause periosteal reaction and marked surrounding marrow and soft tissue oedema on MRI.[15] DDP is the main differential for OCD of the patella, especially in this case as DDP is bilateral in up to 1/3 of patients.[16] However DDP is commonly asymptomatic and, in comparison to OCD, does not involve the overlying cartilage.[17] DDP tends to present as a round lytic lesion in the superolateral aspect of the patella with intact smooth overlying cartilage whereas OCD is in the convexity of the patella, and in this patient the OCDs were located inferiorly involving the subchondral bone and articular cartilage.[17,18]

TREATMENT

At her first outpatient clinic visit, the diagnosis and management options were discussed with the patient and her parents. Since the patient was 11 years old (skeletally immature with physes open) and her symptoms were well controlled, the decision was made to pursue non-operative treatment in the first instance. She was initially managed with protected weight bearing with crutches as required for 6 weeks and referred for physiotherapy. This was specifically for hamstring stretch exercises, low impact adductors and quadriceps strengthening exercises with focus on improving proprioception and range of motion. She was advised against heavy impact and sporting activities.

OUTCOME AND FOLLOW-UP

The patient's non-operative treatment occurred during a prolonged school holiday period (because of the Covid-19 lockdown in the UK) and she was compliant with non-operative measures. Her clinical symptoms improved after 3-4 months of non-operative measures. However, she has not returned to her regular sport activities. The patient will require further imaging including plain radiographs and MRI scans to assess the progression of healing or resolution after 6 months of non-operative treatment. If she develops significant symptoms she may be a candidate for surgical intervention. Depending on intraoperative findings, this may include fragment removal/microfracture, fixation of the osteochondral fragment with bioabsorbable chondral darts or autograft osteochondral transplantation.[19-23] Our preference, if possible, would be fixation with bioabsorbable chondral darts.

DISCUSSION

Although the pathophysiology of juvenile OCDs is still unknown, OCDs are particularly observed in young active patients who perform a lot of sporting activity. The latter has led to 'repetitive microtrauma' being currently one of the most accepted aetiologies.[11,24,25,26] This is further supported by a study which showed that 60% of patients with an OCD were involved in high-level competitive sport.[8] Finally, Cahill and Ahten noted that many individuals in their study were multi-sport athletes as well.[11] Our patient's active participation in several sporting activities correlates with these theories. There is also a male predominance in the literature for juvenile OCD's with male: female ratios between 2:1 and 4:1.[5,9] However, studies have reported increasing female incidence coinciding with increased female participation in sports, further reinforcing the microtrauma hypothesis.[2,11] It is also likely that the left femoral torsion contributed to this patient's rare retro-patella OCD, specifically by inducing severe alterations to the natural biomechanics of the patellofemoral joint.[27] However, as we mentioned earlier, the cause of OCDs is still unknown and the above theory is controversial since the lesion in the right knee appears more severe than the lesion in the left knee.

OCD of the patella was first described by Rombold in 1936 and is an uncommon location for an OCD to

affect the knee.[3,28,29] Its incidence ranges from 5% to 10%, and bilateral OCDs of the patellae are even rarer.[30] Up to 1988, 78 cases of patella OCD had been described in the literature, with only 11 patients having bilateral lesions.[31] In a more recent report of OCD in the patellofemoral joint, Kramer et al. described 3 out of 26 patients had bilateral OCDs.[30] Until very recently, there was a scarcity for published data regarding the diagnosis and treatment of retropatella OCDs, which means no consensus for optimal conservative or surgical treatment has been developed yet.[30,32]

Management of OCD aims to relieve pain, restore function and reduce the risk of early degenerative progression to arthritis.[29] Treatment of patellae osteochondral lesions can be conservative or operative. This decision is based on patient age, skeletal maturity (physeal maturity), lesion appearance (size, location and stability), damage to the fragment, acuity of injury and clinical symptoms.[2] In children with open physes (as in the patient above) the prognosis with conservative treatment is better than in adults since there is greater healing potential as the child continues to grow.[24,33] Conservative management should be based on patient symptoms, as well as both the biology of the lesion at the bone cartilage interface and the cartilage health.[34] This may involve an initial functional knee immobilisation with weight bearing restriction for 4-6 weeks; followed by functional rehabilitation with emphasis on low impact strengthening exercises and range of motion exercises. Heavy impact activity and competitive sporting activity are usually restricted. Our patient had a delayed presentation with bilateral lesions of varying severity. Therefore, we initially encouraged protected weight bearing for 6 weeks with crutches. Management also included physiotherapy and activity modification for 3 months with good outcome.

Surgery is generally indicated for symptomatic skeletally mature patients, patients with worsening pain, unstable OCDs and stable OCDs that fail to improve with 3-6 months of non-operative treatment.[26,35] The goal of surgical management is to re-establish joint surface, improve fragment blood supply, rigid fixation and early motion. However, surgical treatment of patella OCD remains a challenge due to the thickness of the lesions, the surgical approach of the area (arthroscopic and/or open) and associated surgical risks.[36] Surgical options depend on the severity, acuity of injury, stability of the lesion, size of the lesion, age of the patient and availability of surgical expertise and facility. Surgical management is required in failed non-operative management, expanding OCD on imaging, impending closure of physes and clinical signs of instability. Following arthroscopic assessment, suitable lesions can be fixed by interfragmentary compression using non-absorbable or absorbable screws. Also, stable lesions on arthroscopy or lesions < 2-4cm² in size can be managed by subchondral drilling.[37,38] Subchondral drilling (with k-wire or drill) can either be performed retrograde or transchondral but this form of treatment has a theoretical risk of thermal necrosis. Both in situ fixation and subchondral drilling act by stimulating vascular ingrowth to the subchondral bone resulting in fibrocartilage healing.[24] Treatment of unstable lesions can also vary in relation to their size and severity. Small full thickness lesions (1cm²) can be managed with fragment excision and microfracture, especially in non-weight bearing areas of the patella. Small lesions in weight bearing areas and small to medium sized lesions (1-4cm²) can be addressed with osteochondral autograft.[39,40] Fragment excision and microfracture should be avoided in weight bearing areas of the patella and small to medium sized lesions as this has been shown to give short-term relief but symptoms worsen with time.[39,41]

Medium to large lesions (2-10cm²) are usually treated with autologous chondrocyte implantation.

However, larger deep lesions with significant subchondral bone erosion may require reconstruction with osteochondral allograft.[19-23] If symptoms remain refractory to these interventions and/or the OCDs progress to late stage, recent studies demonstrating satisfying functional results with autologous osteochondral mosaicplasty and matrix-assisted chondrocyte implantation (MACI) provide hopeful alternative options in young patients.[42-45] Our preferred surgical treatment if non-operative management had failed, especially for the unstable lesion in the right knee, would have been diagnostic arthroscopy followed by fixation of the OCD with bioabsorbable chondral darts or restoration with osteochondral autograft. However, dependent on intraoperative findings, fixation would have been the initial surgical management of choice by our senior authors.

Early diagnosis of OCD is vital in order to prevent a stable lesion from deteriorating and progressing to instability, fragmentation and loose body formation, which can cause additional mechanical symptoms such as catching and locking. At the later stage in symptomatic patients, the use of conservative management would be limited, and surgery would be indicated with its accompanied poorer prognosis. Unfortunately, 80% of juvenile OCD patients have vague activity-related knee pain for 14 months before detection.[11] This delay in diagnosis is largely due to the non-specific nature of early symptoms and clinical findings on examination that can be camouflaged among many other benign knee-pain conditions seen in young active individuals, such as Osgood-Schlatter's disease and Sinding-Larsen-Johansson syndrome.[24] Given the potential for future joint instability and accelerated joint degeneration in OCD, a high degree of suspicion should be considered when young active individuals present with chronic knee pain and adequate imaging should be obtained.[29]

The diagnosis of OCD relies on good clinical history taking and examination, plain radiographs and MRI to stage the lesion. A retropatella OCD requires particularly careful examination of plain radiographs since many cases are often missed due to their rare location.[36] Lateral and patella skyline views have been reported in the literature to be particularly useful in obtaining the correct diagnosis as was exemplified in this case.[30,36] It is still important to obtain MRI scans since plain radiographs alone cannot stage the lesion, which is imperative in informing the management plan. Staging using MRI is also invaluable in monitoring the progression of lesions when following up patients.

LEARNING POINTS/TAKE HOME MESSAGES 3-5 bullet points

- Osteochondral defect or osteochondritis dissecans (OCD) of the knee is common in young active populations; however, most patients are diagnosed more than a year after the onset of symptoms.
- Juvenile OCD of the patella is a rare cause of activity-related knee pain. It can lead to early degenerative changes if the diagnosis is missed at presentation or delayed.
- Diagnosis of patella OCD is dependent on obtaining appropriate radiological images. This should include lateral and skyline plain radiographic views.
- Management of patella OCD could be either non-operative or operative. The latter is

currently associated with a poor prognosis. Thus, early referral of patients to the orthopaedic surgeon is important to adequately explore non-operative measures.

- Patient symptoms, age and MRI findings are important in assessing the stability of an OCD, determining management and monitoring response to treatment.

REFERENCES

1. Clanton, TO, DeLee, JC. Osteochondritis dissecans. History, pathophysiology and current treatment concepts. *Clin Orthop Relat Res* 1982; 167: 50–64.
2. Kocher MS, Tucker R, Ganley TJ, Flynn JM. Management of osteochondritis dissecans of the knee: current concepts review. *Am J Sports Med*. 2006 Jul;34(7):1181-91. doi: 10.1177/0363546506290127. PMID: 16794036.
3. Flynn JM, Kocher MS, Ganley TJ. Osteochondritis dissecans of the knee. *J Pediatr Orthop*. 2004 Jul-Aug;24(4):434-43. doi: 10.1097/00004694-200407000-00015. PMID: 15205627.
4. Masquijo J, Kothari A. Juvenile osteochondritis dissecans (JOCD) of the knee: current concepts review. *EFORT Open Rev*. 2019 May 17;4(5):201-212. doi: 10.1302/2058-5241.4.180079. PMID: 31191988; PMCID: PMC6541052.
5. Kessler JI, Nikizad H, Shea KG, Jacobs JC Jr, Bebachuk JD, Weiss JM. The demographics and epidemiology of osteochondritis dissecans of the knee in children and adolescents. *Am J Sports Med*. 2014 Feb;42(2):320-6. doi: 10.1177/0363546513510390. Epub 2013 Nov 22. PMID: 24272456.
6. Leung R, Thomas P. An uncommon chronic osteochondral defect in the lateral tibial plateau detected after a separate injury. *BMJ Case Rep*. 2018 Mar 7;2018:bcr2017224065. doi: 10.1136/bcr-2017-224065. PMID: 29514837; PMCID: PMC5848003.
7. Schindler OS .Osteochondritis dissecans of the knee. *Curr Orthop* 2007;**21**:47–58. doi:10.1016/j.cuor.2006.11.006
8. Aichroth P. Osteochondritis dissecans of the knee. A clinical survey. *J Bone Joint Surg Br*. 1971 Aug;53(3):440-7. PMID: 5562371.
9. Lindén B. The incidence of osteochondritis dissecans in the condyles of the femur. *Acta Orthop Scand*. 1976 Dec;47(6):664-7. doi: 10.3109/17453677608988756. PMID: 1015263.
10. Hefti F, Beguiristain J, Krauspe R, Möller-Madsen B, Riccio V, Tschauer C, Wetzel R, Zeller R. Osteochondritis dissecans: a multicenter study of the European Pediatric Orthopedic Society. *J Pediatr Orthop B*. 1999 Oct;8(4):231-45. PMID: 10513356.

11. Cahill BR, Ahten SM. The three critical components in the conservative treatment of juvenile osteochondritis dissecans (JOCD). Physician, parent, and child. *Clin Sports Med*. 2001 Apr;20(2):287-98, vi. doi: 10.1016/s0278-5919(05)70307-0. PMID: 11398359
12. Samora WP, Chevillet J, Adler B, Young GS, Klingele KE. Juvenile osteochondritis dissecans of the knee: predictors of lesion stability. *J Pediatr Orthop*. 2012 Jan- Feb;32(1):1-4. doi: 10.1097/BPO.0b013e31823d8312. PMID: 22173379.
13. Wall EJ, Heyworth BE, Shea KG, Edmonds EW, Wright RW, Anderson AF, Eismann EA, Myer GD. Trochlear groove osteochondritis dissecans of the knee patellofemoral joint. *J Pediatr Orthop*. 2014 Sep;34(6):625-30. doi: 10.1097/BPO.0000000000000212. PMID: 25126843.
14. Biedert RM, Albrecht S. The patellotrochlear index: a new index for assessing patellar height. *Knee Surg Sports Traumatol Arthrosc*. 2006 Aug;14(8):707-12. doi: 10.1007/s00167-005-0015-4. Epub 2006 Feb 23. PMID: 16496126.
15. Weatherall PT, Maale GE, Mendelsohn DB, Sherry CS, Erdman WE, Pascoe HR. Chondroblastoma: classic and confusing appearance at MR imaging. *Radiology*. 1994 Feb;190(2):467-74. doi: 10.1148/radiology.190.2.8284401. PMID: 8284401.
16. Haswell DM, Berne AS, Graham CB. The dorsal defect of the patella. *Pediatr Radiol*. 1976 Aug 20;4(4):238-42. doi: 10.1007/BF02461532. PMID: 15822879.
17. Gerrie BJ, McCulloch PC, Labis JS, Lintner DM, Harris JD. Dorsal Defect of the Patella in a Teenage Male Football Player: A Case Report and Differential Diagnosis of Lytic Patellar Lesion. *Orthop J Sports Med*. 2016 Sep 9;4(9):2325967116665580. doi: 10.1177/2325967116665580. PMID: 27652286; PMCID: PMC5019194.
18. Zhang J, Sia DS, Singh G, Singbal SB, Hallinan JTP. Recap of the Knee Cap: A "Leave Alone" Lesion. *Ann Acad Med Singap*. 2017 Oct;46(10):410-412. PMID: 29177371.
19. Minas T, Bryant T. The role of autologous chondrocyte implantation in the patellofemoral joint. *Clin Orthop Relat Res*. 2005; (436):30–39. [PubMed: 15995417]
20. M. Krishnan SP, Skinner JA, Bartlett W, et al. Who is the ideal candidate for autologous chondrocyte implantation? *J Bone Joint Surg Br*. 2006; 88:61–64. [PubMed: 16365122]
21. Bugbee WD, Convery RF. Osteochondral allograft transplantation. *Clin Sports Med*. 1999; 18:67–75. [PubMed: 10028117]
22. Torga Spak R, Teitge RA. Fresh osteochondral allografts for patellofemoral arthritis: long-term followup. *Clin Orthop Relat Res*. 2006; 444:193–200. [PubMed: 16523140]
23. Donoso R, Figueroa D, Espinoza J, Yañez C, Saavedra J. Osteochondral Autologous Transplantation for Treating Patellar High-Grade Chondral Defects: A Systematic Review.

Orthop J Sports Med. 2019 Oct 17;7(10):2325967119876618. doi: 10.1177/2325967119876618. PMID: 31667196; PMCID: PMC6798165

24. Eismann EA, Pettit RJ, Wall EJ, Myer GD. Management strategies for osteochondritis dissecans of the knee in the skeletally immature athlete. *J Orthop Sports Phys Ther.* 2014 Sep;44(9):665-79. doi: 10.2519/jospt.2014.5140. Epub 2014 Aug 6. PMID: 25098196.
25. Accadbled F, Vial J, Sales de Gauzy J. Osteochondritis dissecans of the knee. *Orthop Traumatol Surg Res.* 2018 Feb;104(1S):S97-S105. doi: 10.1016/j.otsr.2017.02.016. Epub 2017 Nov 29. PMID: 29197636.
26. Edmonds EW, Polousky J. A review of knowledge in osteochondritis dissecans: 123 years of minimal evolution from König to the ROCK study group. *Clin Orthop Relat Res.* 2013;471(4):1118-1126. doi:10.1007/s11999-012-2290-y
27. Lee TQ, Morris G, Csintalan RP. The influence of tibial and femoral rotation on patellofemoral contact area and pressure. *J Orthop Sports Phys Ther.* 2003 Nov;33(11):686-93. doi: 10.2519/jospt.2003.33.11.686. PMID: 14669964.
28. Rombold, C. : Osteochondritis dissecans of the patella: A case report. *J Bone Joint Surg*18: 230–231, 1936
29. D'Angelo K, Kim P, Murnaghan ML. Juvenile Osteochondritis Dissecans in a 13-year-old male athlete: A case report. *J Can Chiropr Assoc.* 2014;58(4):384-394
30. Kramer DE, Yen YM, Simoni MK, Miller PE, Micheli LJ, Kocher MS, Heyworth BE. Surgical management of osteochondritis dissecans lesions of the patella and trochlea in the pediatric and adolescent population. *Am J Sports Med.* 2015 Mar;43(3):654-62. doi: 10.1177/0363546514562174. Epub 2015 Jan 2. PMID: 25556222.
31. Schwarz C, Blazina ME, Sisto DJ, Hirsh LC. The results of operative treatment of osteochondritis dissecans of the patella. *Am J Sports Med.* 1988 Sep-Oct;16(5):522-9. doi: 10.1177/036354658801600516. PMID: 3189687.
32. Bauer KL. Osteochondral Injuries of the Knee in Pediatric Patients. *J Knee Surg.* 2018 May;31(5):382-391. doi: 10.1055/s-0038-1625956. Epub 2018 Jan 30. PMID: 29381884.
33. Durur-Subasi I, Durur-Karakaya A, Yildirim OS. Osteochondral Lesions of Major Joints. *Eurasian J Med.* 2015;47(2):138-144. doi:10.5152/eurasianjmed.2015.50
34. T. Cahill BR. Osteochondritis dissecans of the knee: treatment of juvenile and adult forms. *J Am Acad Orthop Surg.* 1995;3(4):237-247.
35. Schulz JF, Chambers HG. Juvenile osteochondritis dissecans of the knee: current concepts in diagnosis and management. *Instr Course Lect.* 2013;62:455-67. PMID: 23395050.

36. Peters TA, McLean ID. Osteochondritis dissecans of the patellofemoral joint. *Am J Sports Med.* 2000 Jan-Feb;28(1):63-7. doi: 10.1177/03635465000280012201. PMID: 10653545.
37. Miller BS, Briggs KK, Downie B, Steadman JR. Clinical outcomes following the microfracture procedure for chondral defects of the knee: a longitudinal data analysis. *Cartilage* 2010;1:108–112.
38. Goyal D, Keyhani S, Lee EH, Hui JH. Evidence-based status of microfracture technique: a systematic review of level I and II studies. *Arthroscopy* 2013;29:1579–1588.
39. Kreuz PC, Steinwachs MR, Erggelet C, et al. Results after microfracture of full-thickness chondral defects in different compartments in the knee. *Osteoarthritis Cartilage.* 2006; 14:1119–1125.[PubMed: 16815714]
40. Bobic V. Arthroscopy osteochondral autogenous graft transplantation in anterior cruciate ligament reconstruction: A preliminary report. *Knee Surg Sports Traumatol Arthros.* 1996; 3:262–264.
41. Anderson AF, Pagnani MJ. Osteochondritis dissecans of the femoral condyles: long-term results of excision of the fragment. *Am J Sports Med.* 1997;25(6):830-834
42. Figueroa D, Calvo Rodriguez R, Donoso R, Espinoza J, Vaisman A, Yañez C. High-Grade Patellar Chondral Defects: Promising Results From Management With Osteochondral Autografts. *Orthop J Sports Med.* 2020;8(7):2325967120933138. Published 2020 Jul 15. doi:10.1177/2325967120933138
43. Solheim E, Hegna J, Inderhaug E. Clinical outcome after mosaicplasty of knee articular cartilage defects of patellofemoral joint versus tibiofemoral joint. *J Orthop.* 2019 Oct 31;18:36-40. doi: 10.1016/j.jor.2019.10.010. PMID: 32189881; PMCID: PMC7068006.
44. Chadli L, Cottalorda J, Delpont M, Mazeau P, Thouvenin Y, Louahem D. Autologous osteochondral mosaicplasty in osteochondritis dissecans of the patella in adolescents. *Int Orthop.* 2017 Jan;41(1):197-202. doi: 10.1007/s00264-016-3198-z. Epub 2016 Apr 27. PMID: 27118373.
45. Jones KJ, Cash BM. Matrix-Induced Autologous Chondrocyte Implantation With Autologous Bone Grafting for Osteochondral Lesions of the Femoral Trochlea. *Arthrosc Tech.* 2019 Feb 11;8(3):e259-e266. doi: 10.1016/j.eats.2018.10.022. PMID: 31019883; PMCID: PMC6470391

Table 1 Clanton Classification of Osteochondritis Dissecans (Clanton and DeLee)

Figure 1 Lateral radiograph of the left knee taken at the general practitioner practice showing possible bilateral retropatella osteochondral defects.

Figure 2 Lateral radiograph of the right knee taken at the general practitioner practice showing possible bilateral retropatella osteochondral defects.

Figure 3 Anterior-posterior X-rays of both knees taken at the first orthopaedic clinic consultation showing no evidence of osteochondral defects.

Figure 4 Lateral radiographs of the left and right knee taken at the first orthopaedic clinic consultation. Bilateral irregularities in the articular surface of the patellae show retropatella osteochondral defects.

Figure 5 Skyline view radiographs of the left and right knee taken at the first orthopaedic clinic consultation. Bilateral irregularities in the articular surface of the patellae show retropatella osteochondral defects.

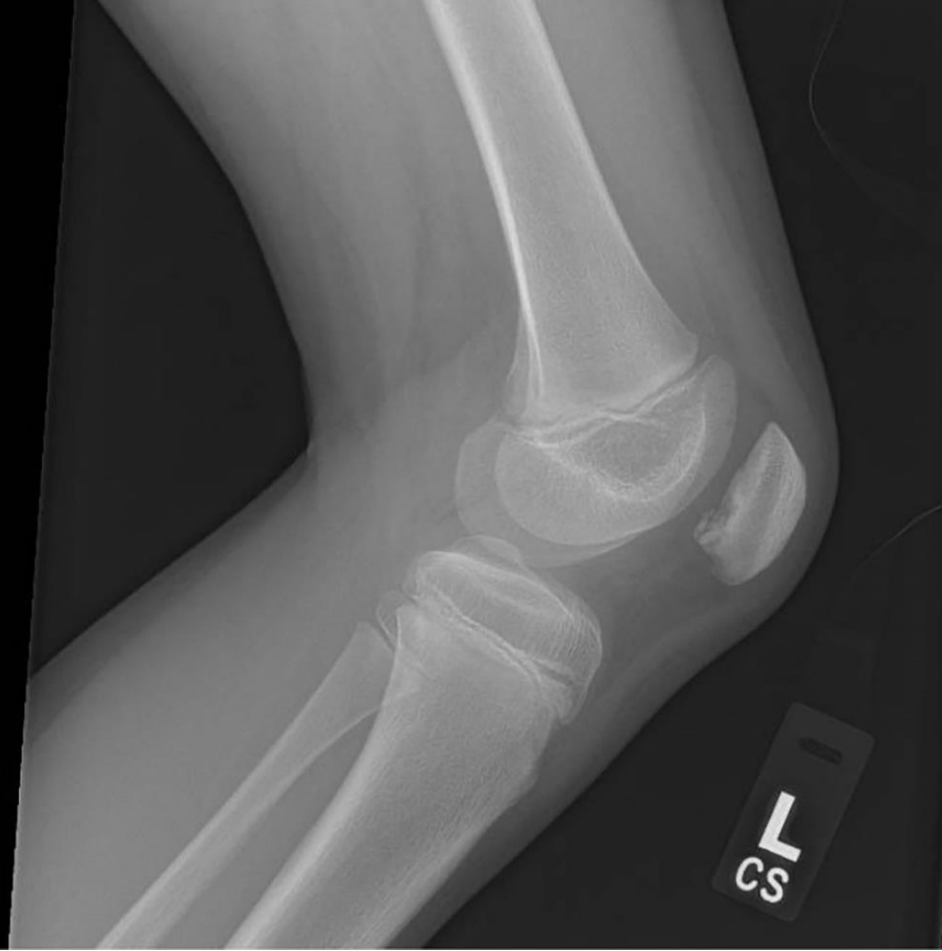Figure 6 MRI of the right knee showing an unstable osteochondral defect in the inferior pole of the lateral patellar facet. Fluid is seen tracking between the osteochondral fragment and parent bone with impaction of the underlying patella (all MRI images are T2 weighted except the bottom left image which is T1 weighted).

Figure 7 MRI of the left knee showing a stable osteochondral fragment in the inferior pole of the lateral patellar facet (all MRI images are T2 weighted except the bottom left image which is T1 weighted).

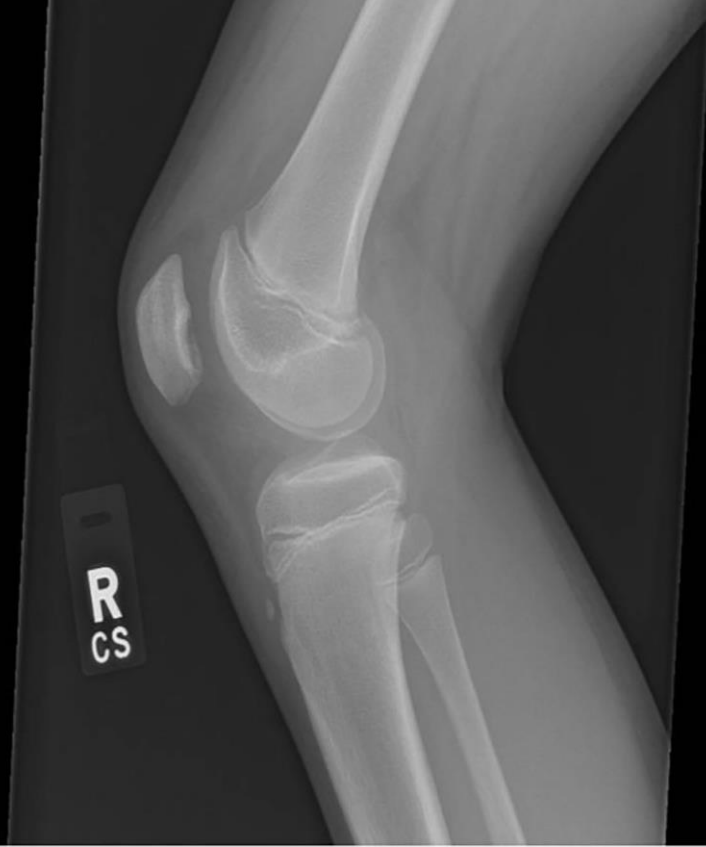INTELLECTUAL PROPERTY RIGHTS ASSIGNMENT OR LICENCE STATEMENT

I, **Miguel Rodriguez Ruiz**, the Author has the right to grant and does grant on behalf of all authors, an exclusive licence and/or a non-exclusive licence for contributions from authors who are: i) UK Crown employees; ii) where BMJ has agreed a CC-BY licence shall apply, and/or iii) in accordance with the relevant stated licence terms for US Federal Government Employees acting in the course of their employment, on a worldwide basis to the BMJ Publishing Group Ltd ("BMJ") and its licensees, to permit this Work (as defined in the below licence), if accepted, to be published in BMJ Case Reports and any other BMJ products and to exploit all rights, as set out in our licence [author licence](#).

Date: 26/10/2020



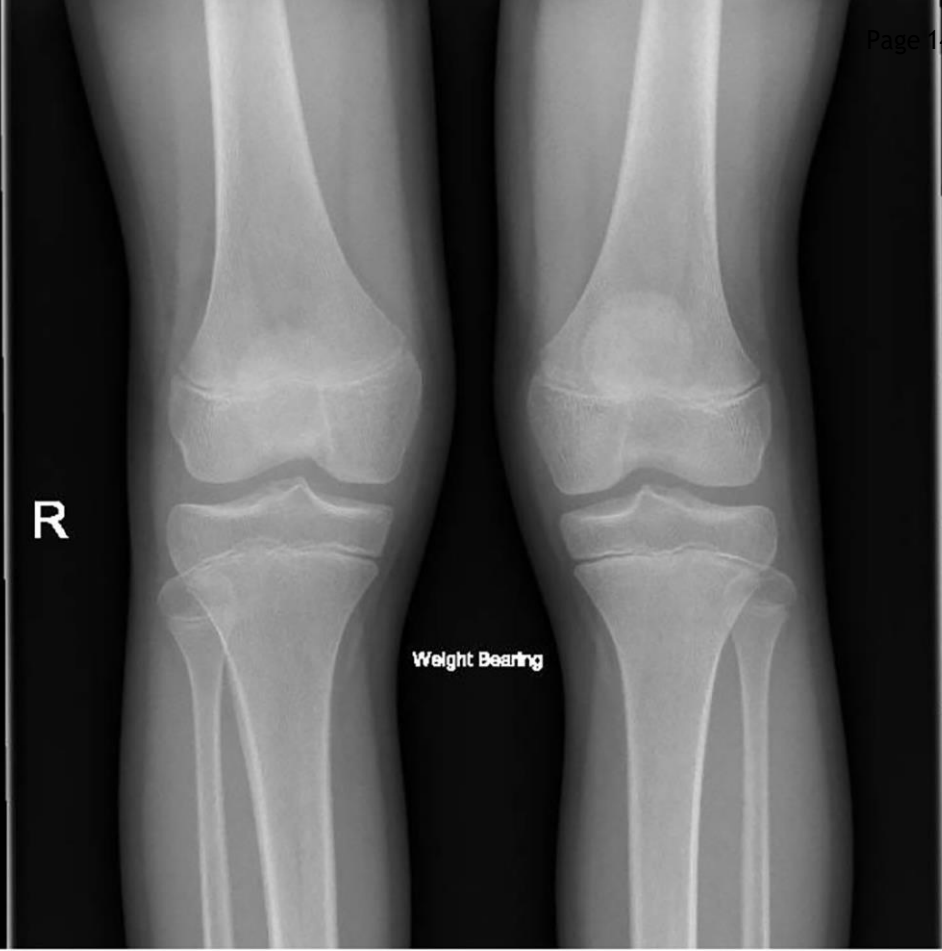L
CS



R
CS

R

Weight Bearing

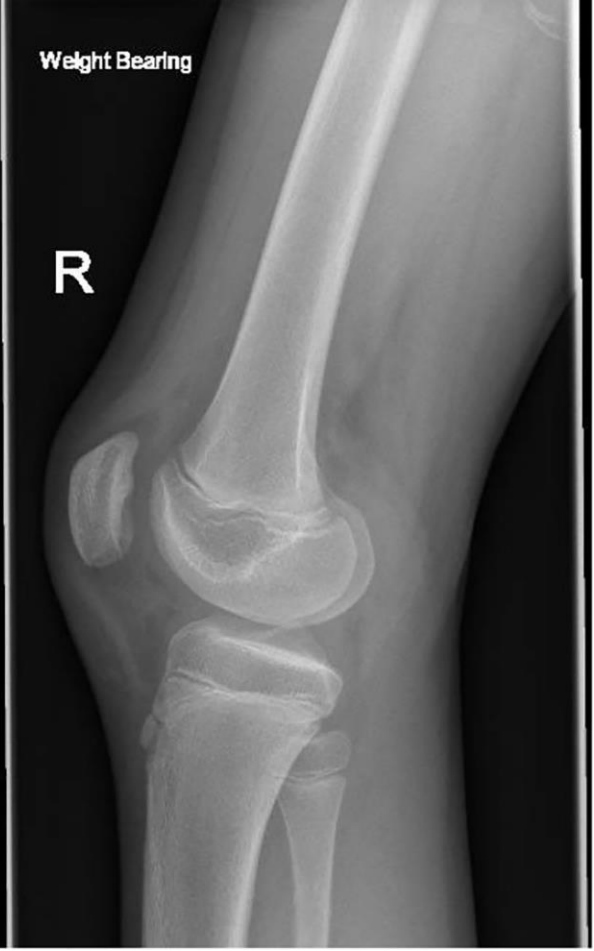
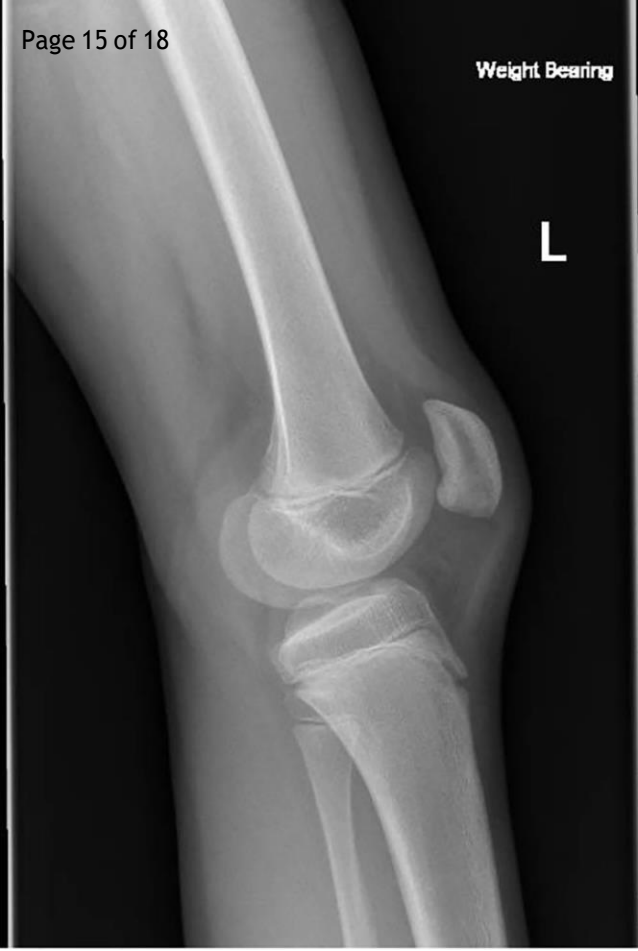

Weight Bearing

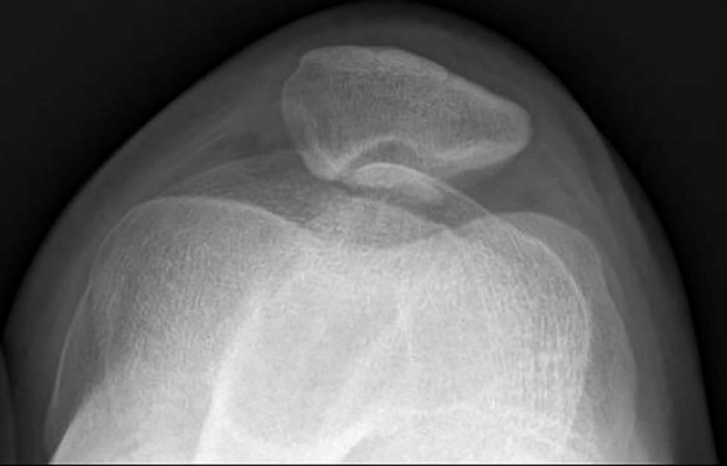
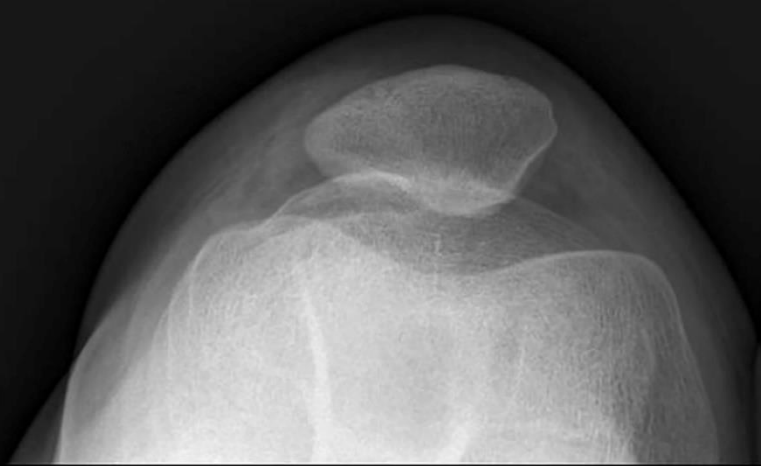
L

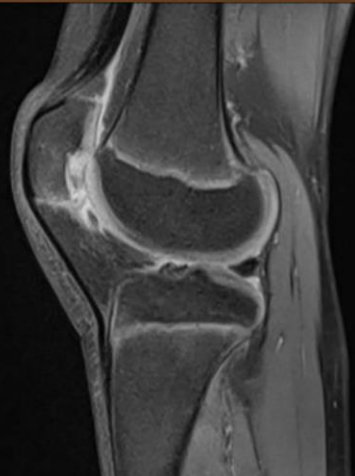
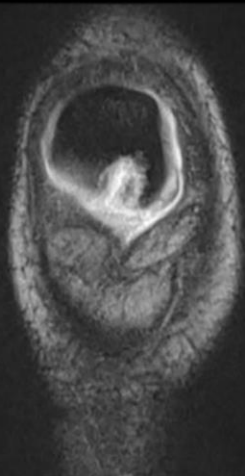
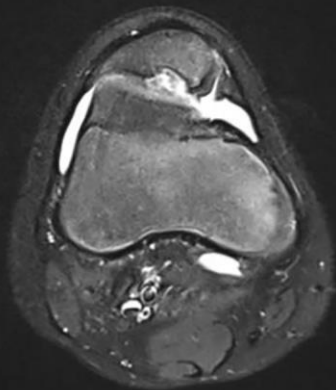
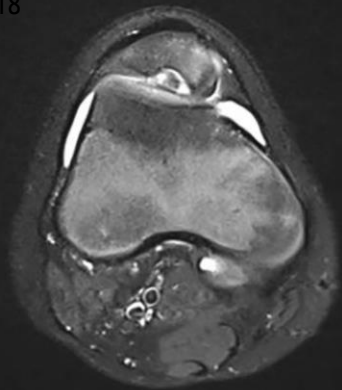
Weight Bearing

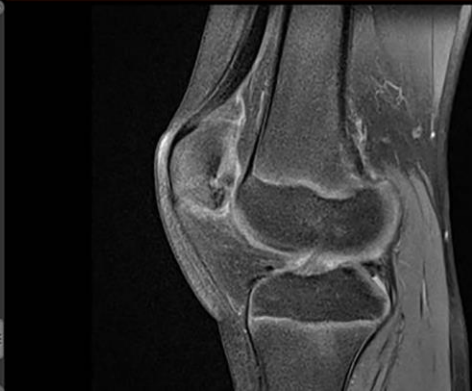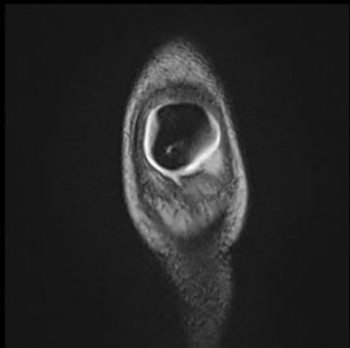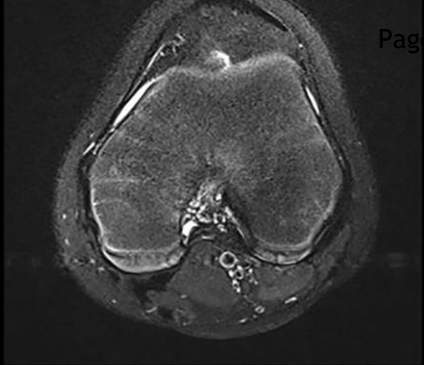
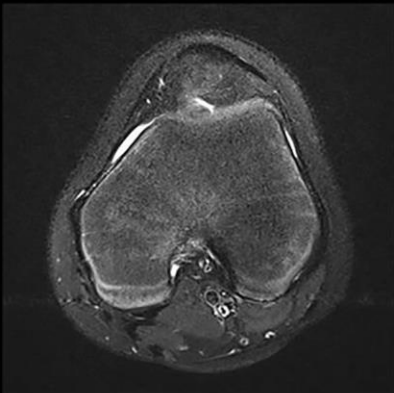
R



L







III

III