

Cardiac resynchronisation therapy after percutaneous trans-coronary-venous mitral annuloplasty

Terapia resynchronizująca serca po przezskórnej plastyce pierścienia zastawki mitralnej z dojścia przez żyły wieńcowe

Tomasz Siminiak, Olga Jerzykowska, Piotr Kalmucki, Rafał Link, Artur Baszko

Department of Interventional Cardiology, HCP Medical Centre, Poznan University of Medical Sciences, Poznan, Poland

Abstract

We present a case of a 45-year-old man with symptomatic heart failure and ischaemic functional mitral regurgitation (FMR), who underwent a successful percutaneous trans-coronary venous mitral annuloplasty with the Carillon™ system. The procedure resulted in clinical improvement as well as in a decrease in the degree of MR as assessed by echocardiography. Fifteen months later, the patient underwent cardiac resynchronisation (CRT) device implantation, resulting in a further improvement in echocardiographic measures of FMR. This case not only confirms the feasibility of CRT after percutaneous trans-coronary-venous mitral annuloplasty, but also suggests a possible synergistic effect of both therapies, warranting future clinical trials.

Key words: cardiac resynchronisation, mitral regurgitation, percutaneous mitral annuloplasty

Kardiol Pol 2013; 71, 12: 1293–1294

INTRODUCTION

Functional mitral regurgitation (FMR) as a result of left ventricular dilatation remains an important clinical problem. Since cardiac surgery in symptomatic patients with FMR is associated with an increased procedural risk, novel percutaneous techniques are under development, including trans-coronary-venous mitral annuloplasty. The clinical effects of combined percutaneous mitral annuloplasty and cardiac resynchronisation therapy (CRT) in FMR patients with heart failure remain unknown.

CASE REPORT

A 45-year-old male with advanced chronic heart failure (NYHA class III), history of myocardial infarction and diagnosed FMR was referred to our centre for percutaneous mitral annuloplasty. Left ventricular dilatation and severe MR with no organic changes within the mitral apparatus were confirmed by echocardiography. Diagnostic coronary angiography showed no significant coronary changes requiring interventional or surgical treatment. The patient underwent

percutaneous trans-coronary-venous mitral annuloplasty with the Carillon™ system as previously described [1–3]. Briefly, under fluoroscopic control, a 9 F guiding catheter was introduced via the jugular approach into the coronary sinus and great cardiac vein and the distal anchor of the device was released. After the application of tension, which resulted in a decrease in the degree of MR, the device proximal anchor was implanted (Fig. 1). Coronary angiography was performed before completion of the procedure to ensure lack of coronary artery compression by the device.

The implantation of the Carillon™ device resulted in an improvement of all echocardiographic FMR parameters: effective regurgitant orifice area (EROA) from 0.21 to 0.17 cm², vena contracta from 0.53 to 0.38 cm, MR jet area/left atrium area from 46.1% to 30.2%, as well as regurgitant volume from 27.0 to 12.9 mL (Fig. 1, right). The procedure resulted also in an improvement in heart failure symptoms and increased exercise tolerance, observed at discharge and during monthly follow-up visits. B-type natriuretic peptide decreased from 3,467 at baseline to 176 pg/mL at six months visit.

Address for correspondence:

Tomasz Siminiak, MD, PhD, FESC, FACC, FSCAI, Professor of Cardiology, Department of Interventional Cardiology, HCP Medical Centre, Poznan University of Medical Sciences, ul. 28 Czerwca 1956 roku Nr 194, 61–485 Poznań, Poland, e-mail: tomasz.siminiak@usoms.poznan.pl

Received: 03.07.2013

Accepted: 10.07.2013

Copyright © Polskie Towarzystwo Kardiologiczne

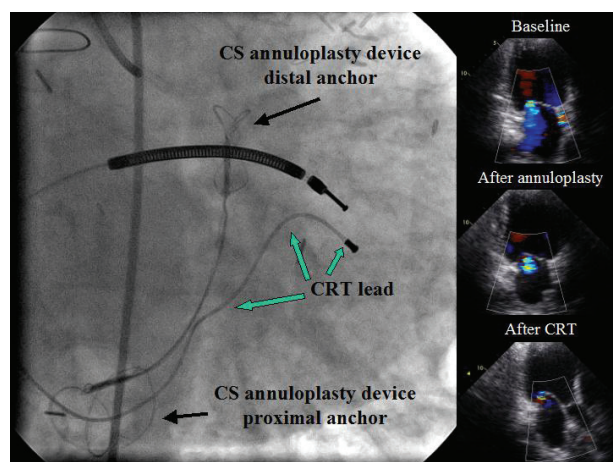


Figure 1. Left: Fluoroscopy of cardiac resynchronisation therapy (CRT) implantation in a patient after mitral annuloplasty with the Carillon™ device. Black arrows indicate Carillon™ anchors in the coronary sinus (CS) and great cardiac vein, green arrows show CRT lead. Right: Echocardiography at baseline, after mitral annuloplasty, and after CRT

Fifteen months after the procedure, the patient collapsed. Holter monitoring showed episodes of ventricular tachycardia and pauses > 2 s. Due to borderline QRS duration (120 ms), the patient was referred to the implantation of an implantable cardioverter-defibrillator device with CRT function. The implantation of CRT lead (Fig. 1, green arrows) into the coronary sinus was very easy due to the visibility of Carillon™ device during fluoroscopy as well as wide opening of the coronary sinus ostium by the proximal anchor of the device. The echo parameters of FMR further improved as a result of CRT (Fig. 1, right): EROA to 0.15 cm², MR jet area/left atrium area to 19.3%, and regurgitant volume to 10.2 mL, although vena contracta remained unchanged: 0.38 cm.

DISCUSSION

FMR is a common finding in heart failure patients with both ischaemic and dilated cardiomyopathy. Despite important prognostic implications, increased operative risk of these patients results in low referral and high denial rates for mitral surgery.

The efficacy of percutaneous mitral annuloplasty with the Carillon™ device in the treatment of FMR has been evaluated in the AMADEUS [2, 3] and TITAN [4] clinical trials. The main limitation of the procedure is related to anatomical variants: placing of traction on the Carillon™ delivery system may also affect the circumflex artery lying under the great cardiac vein. In such cases, the technique enables safe recapture of the device and its repositioning, or termination of the procedure. Coronary artery compromise precludes permanent device implantation in approximately 15% of patients [4]. Recently published results of the TITAN trial confirmed significant im-

provement of FMR as assessed by both echocardiography and functional tests that persisted up to 24 months after the procedure. In addition, a significant decrease in the left ventricular diastolic volume, indicating reverse remodelling as a result of the Carillon™ device implantation, was observed [4].

CRT is known to be a potential therapeutic option in heart failure patients with FMR [5, 6]. It may improve FMR by correcting several underlying mechanisms, including reduced contractility, ventricular remodelling, loss of annular function as well as ventricular asynchrony [6]. MR improvement after CRT predicts superior survival compared to nonimprovers, consisting of approximately 50% of patients with FMR and high operative risk [5].

Whether CRT may exert an additional beneficial effect in patients undergoing percutaneous mitral annuloplasty remains to be established. To the best of our knowledge, this is the first demonstration of successful CRT after percutaneous trans-coronary-venous mitral annuloplasty that shows not only its feasibility but also a possible synergistic effect of both therapies. The verification of the clinical effects of combined Carillon™ implantation and CRT requires future clinical studies. It should be noted however, that the presence of a coronary sinus lead remains an exclusion criterion for Carillon™ device implantation. Therefore the patients will have to undergo mitral annuloplasty before CRT.

CONCLUSIONS

CRT after successful percutaneous trans-coronary-venous mitral annuloplasty may have a synergistic effect in patients with FMR. Future clinical trials are warranted.

Conflict of interest: TS was an investigator in clinical studies funded by Cardiac Dimensions Inc. The other authors have nothing to disclose.

References

1. Siminiak T, Firek L, Jerzykowska O et al. Percutaneous valve repair for mitral regurgitation using the Carillon™ Mitral Contour System™. Description of the method and case report. *Kardiologia Pol.* 2007; 65: 272–278.
2. Siminiak T, Hoppe UC, Schofer J et al. Effectiveness and safety of percutaneous coronary sinus-based mitral valve repair in patients with dilated cardiomyopathy (from the AMADEUS trial). *Am J Cardiol.* 2009; 104: 565–570.
3. Schofer J, Siminiak T, Haude M et al. Percutaneous mitral annuloplasty for functional mitral regurgitation. Results of the CARILLON mitral annuloplasty device european union study. *Circulation.* 2009; 120: 326–333.
4. Siminiak T, Wu CW, Haude M et al. Treatment of functional mitral regurgitation by percutaneous annuloplasty: results of the TITAN trial. *Eur J Heart Fail.* 2012; 14: 931–938.
5. van Bommel RJ, Marsan NA, Delgado V et al. Cardiac resynchronization therapy as a therapeutic option in patients with moderate-severe functional mitral regurgitation and high operative risk. *Circulation.* 2011; 124: 912–919.
6. Porciani MC, Macioce R, Demarchi G et al. Effects of cardiac resynchronization therapy on the mechanisms underlying functional mitral regurgitation in congestive heart failure. *Eur J Echocardiography.* 2006; 7: 31–39.