

Patient with atrial fibrillation and myocardial infarction due to coronary artery embolism treated with thrombus aspiration

Zawał serca powstały w wyniku zatoru tętnicy wieńcowej u osoby z migotaniem przedsionków, leczony trombektomią aspiracyjną

Wojciech Zasada¹, Stanisław Bartuś¹, Tadeusz Królikowski², Dariusz Dudek¹

¹2nd Department of Cardiology, Jagiellonian University Medical College, Krakow, Poland

²1st Department of Cardiology and Hypertension, Jagiellonian University Medical College, Krakow, Poland

Abstract

We present the case of a 77 year-old male patient diagnosed with ST-segment elevation myocardial infarction of anterior wall due to coronary embolism secondary to paroxysmal atrial fibrillation. The patient was qualified for emergent coronary angiography and aspiration thrombectomy. Due to lack of atherosclerotic lesions and probable embolic origin of the occlusion of the infarct-related artery, the patient underwent a successful thrombus aspiration procedure without stent implantation, followed by oral anticoagulant therapy.

Key words: coronary embolism, myocardial infarction, atrial fibrillation

Kardiol Pol 2013; 71, 1: 99–101

CASE REPORT

A 77 year-old male was admitted to the emergency department due to chest pain, which had occurred for the first time two days before admission and relieved after 15 minutes of rest, but had recurred 12 hours before admission. The patient was not taking any medications, and he did not have any disease previously diagnosed. ECG revealed atrial fibrillation (AF) and ST-segment elevation in V₃–V₅ leads up to 0.5 mV. Blood tests revealed a high level of myocardial necrotic enzymes — troponin I 20.54 µg/L (N: < 0.01), CK-MB 144 U/L (N: 3–25), CK 1384 U/L (N: 20–200), but others parameters, such as complete blood count, electrolytes and creatinine were within the normal range. Afterwards, the patient was transferred for urgent coronary angiography.

Physical examination on admission to our primary-percutaneous coronary intervention (PCI) centre revealed an arrhythmic pulse 78/min, without any other abnormalities. Blood pressure on admission was 147/83 mm Hg. Due to the chest pain, ischaemic ECG changes and the elevated cardiac enzymes, a diagnosis of anterior wall ST-elevation myocar-

dial infarction (STEMI) was confirmed. The patient received loading doses of acetylsalicylic acid (300 mg), clopidogrel (600 mg), and unfractionated heparin (5,000 U).

Urgent coronary angiography performed from the femoral access showed normal left circumflex and right coronary arteries, with no evidence of atherosclerotic lesions. The left anterior descending artery was occluded in the middle part (Fig. 1A). We performed thrombus aspiration with a 6 F aspiration catheter (guiding catheter: Launcher 6 FJL4.0, Medtronic; guidewire: BMW, Abbott Vascular; aspiration catheter: Export AP, Medtronic), as standard procedure in thrombus-containing lesions. After the first passage, a large thrombus was removed from the artery (Fig. 2A). However, only a slight improvement of the distal flow was confirmed in the control angiogram (Fig. 1B). After the next two passages, additional parts of the thrombus were removed (Fig. 2B). An optimal distal flow in the infarct-related artery was achieved. There was no evidence of dissection, stenosis or atherosclerotic lesion in the infarct-related artery (Fig. 1C). Considering the clinical characteristics of the patient (AF) and angiographic fin-

Address for correspondence:

Wojciech Zasada, MD, 2nd Department of Cardiology, University Hospital in Krakow, ul. Kopernika 17, 31–501 Krakow, Poland, tel: + 48 12 424 71 74, e-mail: zasada.wojciech@gmail.com

Copyright © Polskie Towarzystwo Kardiologiczne

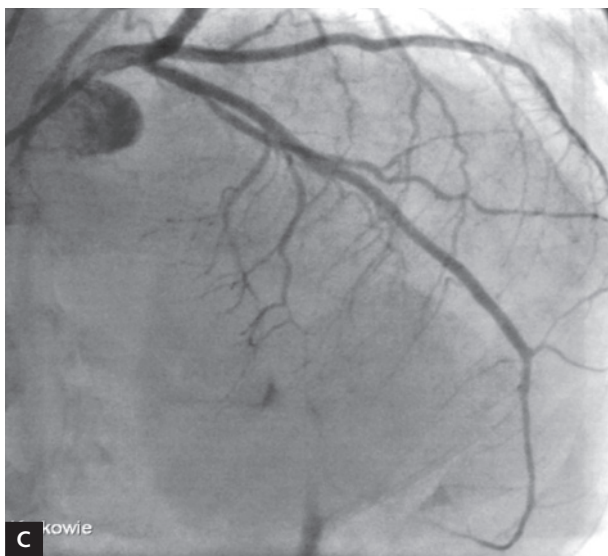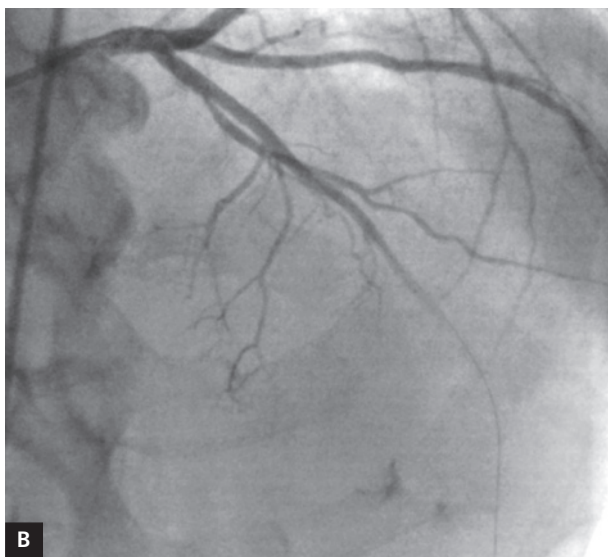

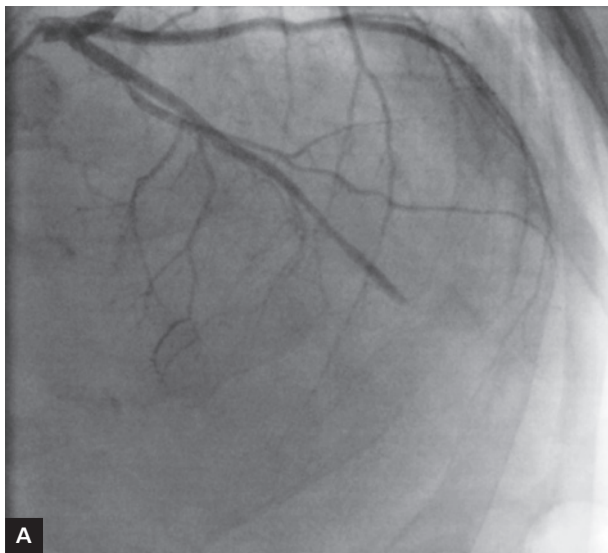
Figure 1. **A.** Initial angiogram of the left anterior descending artery; **B.** Control angiogram after first thrombectomy passage; **C.** Final angiogram

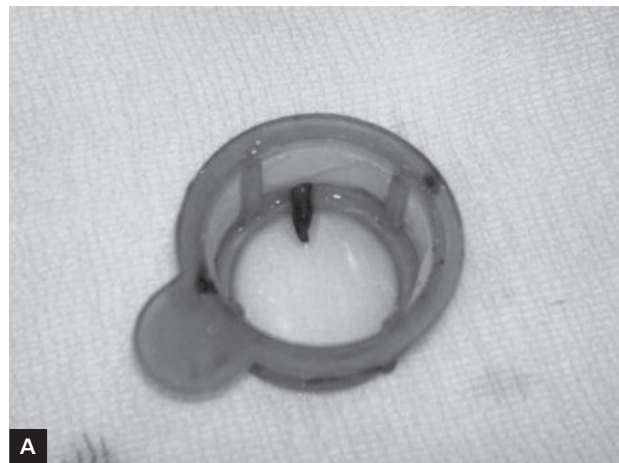

Figure 2. **A.** Thrombus from first passage; **B.** Thrombus, final

dings (lack of evidence of atherosclerotic lesions), a diagnosis of embolic origin of the infarction was made, and the procedure was stopped at this point.

Peak troponin I level on the second day of hospitalisation was 21.91 ng/mL. ECG performed post PCI procedure revealed restoration of sinus rhythm, with regular heart rate of 85 bpm. Several echocardiography assessments performed during the hospital stay revealed improved left ventricular ejection fraction (from 30% the day after the procedure up to 40% at discharge).

Due to the AF which was observed on admission, low molecular weight heparin (enoxaparin) was introduced from the second day of hospitalisation. On the sixth day of hospitalisation, a 24-hour ECG monitoring was performed, which revealed several episodes of paroxysmal AF. The patient was given oral anticoagulation. Additionally, the patient had an oral glucose tolerance test which revealed recent diabetes mellitus: the patient's treatment was updated for oral hypoglycaemic medication (gliclazide). On the 11th day, the patient was discharged home in good condition.

DISCUSSION

Thrombectomy followed by coronary artery stenting in MI of the anterior wall is a standard procedure of invasive treatment. However, this strategy has to be reconsidered in patients with MI and suspicion of embolic origin of the coronary occlusion. Embolism of coronary artery could be a cause of acute coronary syndrome (ACS), but this situation is unusual. The described aetiologies of this embolic material are quite wide: thrombotic material from native aortic and mitral valves: usually after infectious endocarditis, from prosthetic valves after valve surgery, several iatrogenic causes, and paradoxical coronary embolism as a consequence of lower limb venous thromboembolism in patients with patent foramen ovale [1].

There are also a group of case reports regarding ACS in patients with AF due to coronary embolism. These describe several methods of treatment in this clinical situation. The therapeutic options are usually thrombolytic or anticoagulation based therapy, or PCI, especially together with aspiration of the thrombus [2–5].

Thrombus aspiration is a very effective method of treating MI [6], especially in STEMI patients who have evidence of thrombus in the coronary artery. There is some evidence that this method could be effective and could help to restore blood flow and reduce distal embolisation, but in almost every case thrombus aspiration is followed by coronary stent implantation. It is unusual that this method is used as an individual, one-step procedure, as in the described case [7–9].

Our patient had had STEMI diagnosed, and met the criteria for early invasive strategy. In our case report, early coronary angiography revealed thrombus material in the left anterior descending coronary artery without any signs of atherosclerosis. Based on these findings, we performed only thrombus aspiration, because there was no atherosclerotic basis and there was no need for coronary stent implantation. After three passages of aspiration catheter, blood flow in the infarct-related artery was completely restored. Therefore, thrombus aspiration in this particular case was the optimal therapy.

In conclusion, STEMI due to non-atherosclerotic, coronary embolism is very rare, but may occur especially in a specific, predisposed group of patients. Treatment of ACS in these patients is mostly based on aspiration thrombectomy, but, due to lack of clear therapeutic standards, and a fairly diverse population, each treatment strategy should be individualised.

Thrombus aspiration may very often be an effective solution for treatment in this group of patients.

Conflict of interest: none declared

References

1. Rigatelli G. Normal angiogram in patients with acute coronary syndrome: searching for unusual substrates of myocardial ischemia. *Int J Cardiol*, 2005; 99: 25–27.
2. Ratti C, Grassi L, Magnavacchi P, Bompani B. Acute myocardial infarction following persistent atrial fibrillation. Consequence, common etiology or a case? *Recent Prog Med*, 2010; 101: 112–114.
3. Camaro C, Aengevaeren WR. Acute myocardial infarction due to coronary artery embolism in a patient with atrial fibrillation. *Neth Heart J*, 2009; 17: 297–299.
4. Acikel S, Dogan M, Aksoy MM, Akdemir R. Coronary embolism causing non-ST elevation myocardial infarction in a patient with paroxysmal atrial fibrillation: treatment with thrombus aspiration catheter. *Int J Cardiol*, 2011; 149: e33–e35.
5. Kleczyński P, Dziewierz A, Rakowski T et al. Cardioembolic acute myocardial infarction and stroke in a patient with persistent atrial fibrillation. *Int J Cardiol*, 2012; 161: e46–e47.
6. Dudek D, Mielecki W, Burzotta F et al. Thrombus aspiration followed by direct stenting: a novel strategy of primary percutaneous coronary intervention in ST-segment elevation myocardial infarction. Results of the Polish-Italian-Hungarian Randomized Thrombectomy Trial (PIHRATE Trial). *Am Heart J*, 2010; 160: 966–972.
7. Rochon B, Chami Y, Sachdeva R et al. Manual aspiration thrombectomy in acute ST elevation myocardial infarction: new gold standard. *World J Cardiol*, 2011; 3: 43–47.
8. Costopoulos C, Gorog DA, Di Mario C, Kukreja N. Use of thrombectomy devices in primary percutaneous coronary intervention: a systematic review and meta-analysis. *Int J Cardiol*, 2011 Dec 3. [Epub ahead of print].
9. Kleczyński P, Bartus S, Legutko J et al. Use of aspiration thrombectomy in a 102-year-old patient with acute inferior ST-segment elevation myocardial infarction. *Int J Cardiol*, 2012; 160: e46–e47.