

Late proarrhythmia on sotalol therapy triggered by emotional stress

Późny efekt proarytmiczny w trakcie terapii sotalolem wywołany stresem emocjonalnym

Hanna Wachowiak-Baszyńska, Ewa Straburzyńska-Migaj, Romuald Ochotny, Stefan Grajek

1st Department of Cardiology, Poznan University of Medical Sciences, Poznan, Poland

Abstract

We present a case of significant QTc prolongation with torsade de pointes in a female patient with a DDD pacemaker, who had been treated with an established dose of sotalol for two years. The most probable trigger factor of this adverse event was a strong emotional stress. The discontinuation of treatment with sotalol resulted in clinical recovery and QTc normalisation.

Key words: late proarrhythmia, sotalol, emotional stress, QTc

Kardiol Pol 2011; 69, 7: 721–723

INTRODUCTION

Sudden emotional stress may be connected with a transient increase in catecholamine concentration, which in some individuals can have an unfavourable effect on the heart. We present the case of a post-menopausal woman who experienced a significant late proarrhythmic adverse event during sotalol treatment, in strict connection with strong emotional stress, which caused a dramatic QTc prolongation with torsade de pointes episodes, without any other signs of stress cardiomyopathy.

CASE REPORT

A 71 year-old woman with systemic hypertension, type 2 diabetes mellitus, abdominal obesity and sick sinus syndrome with paroxysmal atrial fibrillation, three years after the implantation of a dual-chamber pacemaker, was admitted to hospital because of recurrent pre-syncopal episodes, which had started the previous evening shortly after extremely strong emotional stress. For two years the patient had been taking 320 mg of sotalol daily for rhythm control as lower doses had proved ineffective. Concomitant pharmacotherapy included ramipril, losartan, indapamide, glimepiride and acenocumol with established doses of all the mentioned medications.

Electrocardiogram (ECG) on admission revealed paced rhythm of 70 bpm with QTc prolongation to 666 ms, polymorphic ventricular extrasystoles with short runs of torsade de pointes ventricular tachycardia (Figs. 1A, B). Her previous ECGs from the pacemaker control centre showed only minor QTc prolongation up to 475 ms (on the same dose of sotalol with ventricular pacing) and there was no previous clinical evidence for ventricular arrhythmia. Laboratory tests on admission excluded acute myocardial infarction, hypokaliemia or hypomagnesaemia and kidney dysfunction. Echocardiography revealed moderate eccentric hypertrophy of the left ventricle (13 mm thickness of the interventricular septum and the posterior wall), with impaired diastolic, but preserved systolic function with no regional diminished wall motion. Cessation of treatment with sotalol, infusions with magnesium sulphate and treatment with atenolol 100 mg daily resulted in a resolution of the symptoms. In two days, QTc decreased to 432 ms and remained the same at a 14-day follow-up visit (Fig. 2).

DISCUSSION

Decisions regarding pharmacological prevention of atrial fibrillation must always be made after considering the risk of side effects [1, 2]. Our patient, having metabolic syndrome,

Address for correspondence:

Hanna Wachowiak-Baszyńska, MD, PhD, 1st Department of Cardiology, Poznań University of Medical Sciences, ul. Długa 1/2, 61–848 Poznań, Poland, tel: +48 61 8549146, fax: +48 61 8549094, e-mail: hanna.baszyńska@skpp.edu.pl

Copyright © Polskie Towarzystwo Kardiologiczne

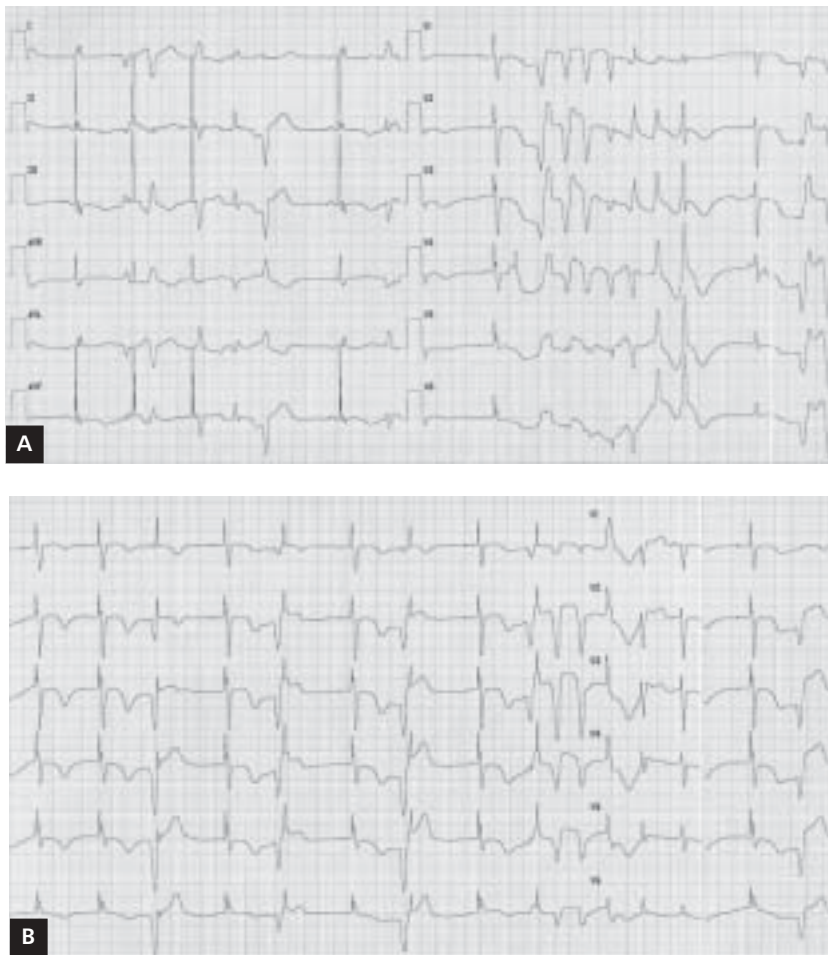

Figure 1A, B. Paced rhythm 70 bpm, with QTc prolongation to 666 ms, polymorphic ventricular extrasystoles with several short runs of torsade de pointes ventricular tachycardia

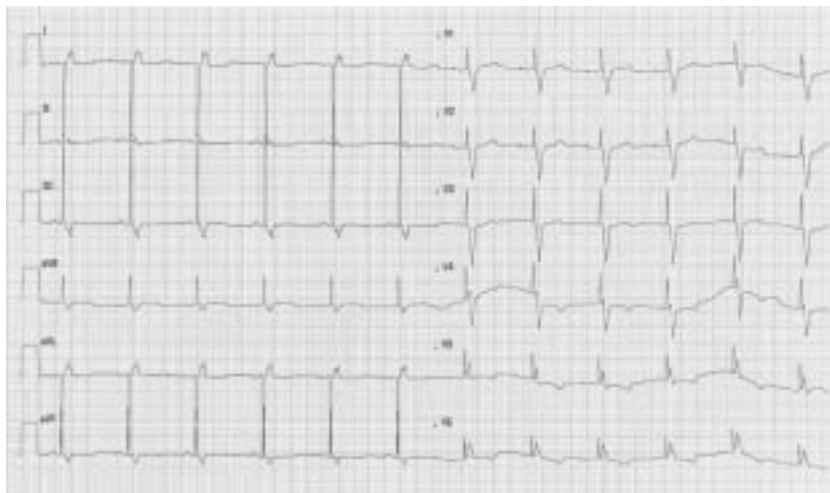


Figure 2. Standard 12-lead ECG after two days of discontinuation of sotalol. Paced rhythm 70 bpm, QTc = 423 ms

moderate left ventricle hypertrophy and a high risk of ischemic heart disease, was not the ideal candidate for treatment with sotalol. But this however seemed to be the best option. Amiodarone was contraindicated in her case due to a history of hyperthyroidism eight years previously, while propafenone had proved to be ineffective in the past and the patient did not accept radiofrequency ablation. As she received a dual chamber pacing device, the risk of proarrhythmia due to bradycardia was diminished [2] and treatment with sotalol was introduced with a careful follow-up and QTc assessment after each dosage increase, although because of ventricular pacing we accepted QTc longer than 450 ms, but not exceeding 500 ms. The period of the highest risk of proarrhythmia (the first three days of treatment [1, 2]) was uneventful. Torsade de pointes appeared after strong emotional stress (for two years the patient had been on the same medication dose) and were related to significant prolongation of QTc during paced rhythm. We found no trigger factor for this adverse event other than mental stress. Significant QTc prolongation may be induced by a higher concentration of catecholamines [3] and has been described in cases of pheochromocytoma [4], strong emotional stress [5] and also in patients with Tako-Tsubo syndrome [6]. Beta-adrenergic stimulation has also been proved to induce early afterdepolarisation in an animal model [3]. Female sex and left ventri-

cular hypertrophy are important risk factors for proarrhythmia with sotalol [2], but this unusual case, featuring such a late arrhythmic adverse event, could be caused by a sudden increase in sympathetic activity due to emotional stress. Catecholamines may contribute to significant QT prolongation, resulting in torsade de pointes, especially in patients with high risk of this arrhythmia: not only with congenital long QT syndrome, but also with prolonged QT interval secondary to pharmacological management.

Conflict of interest: none declared

References

1. Camm AJ. Safety considerations in the pharmacological management of atrial fibrillation. *Int J Cardiol*, 2008; 127: 299–306.
2. Wolbrette DL. Risk of proarrhythmia with class III antiarrhythmic agents: sex-based differences and other issues. *Am J Cardiol*, 2003; 91 (suppl.): 39D–44D.
3. Priori SG, Corr PB. Mechanisms underlying early and delayed afterdepolarizations induced by catecholamines. *Am J Physiol Heart Circ Physiol*, 1990; 258: H1796–H1805.
4. Viskin S, Fish R, Roth A, Schwartz PJ, Belhassen B. QT or not QT. *NEJM*, 2000; 343: 352–356.
5. Merz CN, Pardo Y. Mental versus physical stress, QT prolongation and the autonomic nervous system. *Circulation*, 2000; 101: E213–E214.
6. Yoshiteru A, Kondo M, Matsuoka R, Araki M, Dohyama K, Tanio H. Assessment of clinical features in transient left ventricular apical ballooning. *J Am Coll Cardiol*, 2003; 41: 737–742.