

Percutaneous retrograde paramitral leak closure through a mechanical aortic valve

Karol Zbroński¹, Robert Sabiniewicz², Piotr Scisło¹, Anna Siennicka¹, Janusz Kochman¹, Zenon Huczek¹

¹ 1st Department of Cardiology, Medical University of Warsaw, Warsaw, Poland

² Department of Pediatric Cardiology and Congenital Heart Diseases, Medical University of Gdańsk, Gdańsk, Poland

Paravalvular regurgitation is present in up to 17% of patients undergoing valve replacement surgery.¹ The preferred treatment of choice is surgical reintervention; however, the percutaneous approach is a valid alternative in symptomatic patients at high surgical risk.²

A 24-year-old man with a history of aortic valve replacement with a mechanical bileaflet prosthesis (29 mm), mitral valve annuloplasty (32 mm), and tricuspid annuloplasty (de Vega type) was admitted due to heart failure symptoms. An index surgery for acute heart failure with severe valvular dysfunction was performed 2 months earlier; an underlying connective tissue disorder was suspected. Transthoracic echocardiography demonstrated global hypokinesis of the left ventricle with an ejection fraction of 26%. Transesophageal echocardiography (2- and 3-dimensional) revealed significant mitral regurgitation due to periannular anterior mitral leaflet perforation by a surgical suture (effective regurgitation orifice, 0.47 cm²; regurgitant volume, 51 ml) (Supplementary material, *Figure S1, Panel A1–A3*).

Owing to high risk of redo surgery and the medial location of the leak, the patient was referred for a percutaneous procedure via a retrograde transaortic approach. The procedure was performed under general anesthesia under 2- and 3-dimensional TEE guidance. Using a hydrophilic guidewire and an extra back-up guiding catheter, the defect was crossed and the guidewire was secured in the left upper pulmonary vein (*FIGURE 1A*). Next, a delivery sheath was inserted (*FIGURE 1B*), whose presence across the mechanical aortic prosthesis resulted in a temporary movement obstruction of one of the discs, although without a significant blood pressure drop. Based on 3-dimensional TEE, an Amplatzer Vascular

Plug III (10 × 5 mm) was selected, introduced through the delivery sheath (*FIGURE 1C*), and deployed. Once the correct implant position and stability, as well as leak reduction, was confirmed by TEE (mild para-device regurgitation; Supplementary material, *Figure S1, Panel B1–B3*), the plug was released (*FIGURE 1D*). The postprocedural course was uneventful. During 18 months of follow-up, the patient's exercise tolerance increased significantly. Control transthoracic echocardiography demonstrated a mild residual leak.

Percutaneous paravalvular regurgitation closure can be performed using an anterograde transseptal, retrograde transapical, or retrograde transaortic approach. The closure of medially located leaks anterogradely is challenging without a steerable sheath. Furthermore, a transseptal puncture may be difficult in previously operated patients with a potentially thickened or calcified septum. The transapical approach ensures a direct access to paraseptal defects; however, it may result in postoperative bleeding and hemothorax in up to 19% of patients.³

The retrograde transaortic approach is suitable for medially located defects, but in patients with mechanical aortic valve prosthesis, it must be performed with caution owing to the risk of obstruction. Unsuccessful attempts with hemodynamic deterioration have been reported.⁴ A successful retrograde procedure through a mechanical prosthesis has also been described, but in a different clinical setting, namely, in 2 older patients with preserved ejection fraction, less severe heart failure symptoms, and lateral leak location.⁵

Correspondence to:

Karol Zbroński, MD,
1st Department of Cardiology,
Medical University of Warsaw,
ul. Banacha 1a, 02-097 Warszawa,
Poland, phone: +48 22 599 19 58,
email: karol.zbronski@gmail.com
Received: December 12, 2018.

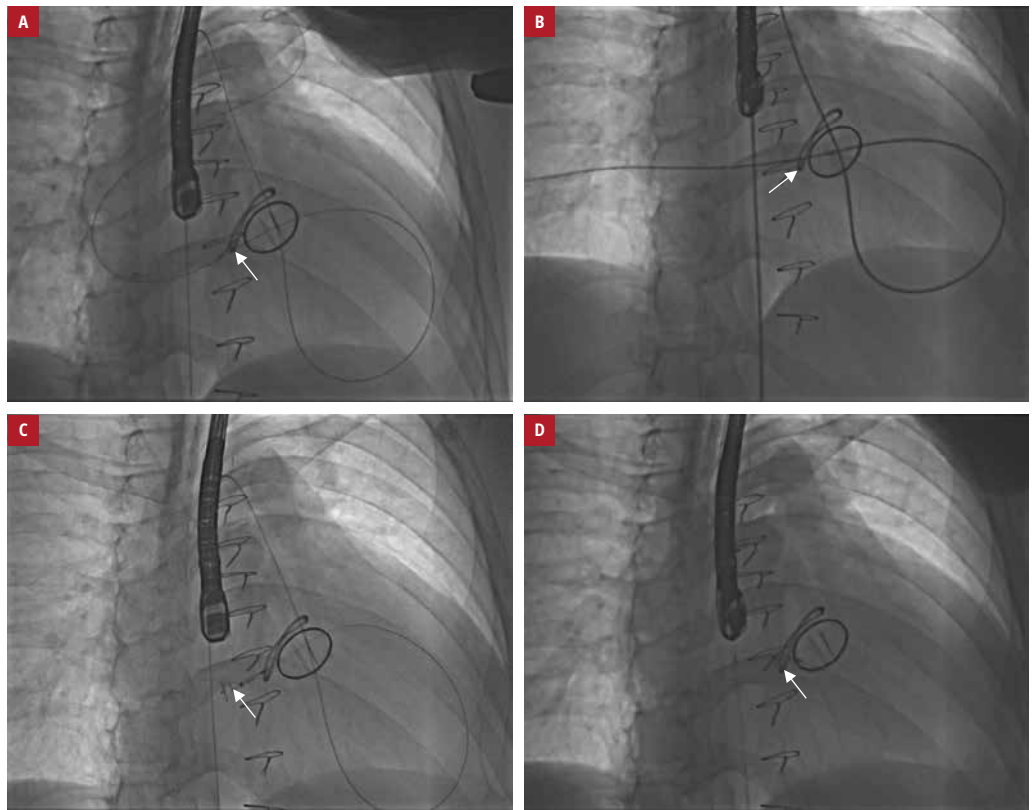
Revision accepted:
February 15, 2019.

Published online: April 25, 2019.
Kardiol Pol. 2019; 77 (4): 482–483
doi:10.33963/KP.14799

Copyright by Polskie Towarzystwo
Kardiologiczne, Warszawa 2019

FIGURE 1

A – a guidewire crossing the mechanical aortic valve and the paramitral leak secured in the left upper pulmonary vein (arrow); **B** – a delivery sheath crossing the mechanical aortic valve and the paramitral leak secured in the right lower pulmonary vein (arrow); **C** – partial deployment of the device in the left atrium (arrow); **D** – final effect with the device fully deployed and released (arrow)



SUPPLEMENTARY MATERIAL

Supplementary material is available at www.mp.pl/kardiologiapolska.

ARTICLE INFORMATION

CONFLICT OF INTEREST None declared.

HOW TO CITE Zbroński K, Sabiniewicz R, Scisło P, et al. Percutaneous retrograde paramitral leak closure through a mechanical aortic valve. *Kardiol Pol.* 2019; 77: 482-483. doi:10.33963/KP.14799

REFERENCES

- 1 Rihal CS, Sorajja P, Booker JD, et al. Principles of percutaneous paravalvular leak closure. *JACC Cardiovasc Interv.* 2012; 5: 121-130.
- 2 Nishimura RA, Otto CM, Bonow RO, et al. 2014 AHA/ACC guidelines for the management of patients with valvular heart disease. *J Am Coll Cardiol.* 2014; 63: 2438-2488.
- 3 Pitta SR, Cabalka AK. Complications associated with left ventricular puncture. *Catheter Cardiovasc Interv.* 2010; 76: 993-997.
- 4 Larman M, Lasa G, Sanmartín JC, Gaviria K. Transapical technique as an alternative approach to paravalvular leak closure. *Rev Esp Cardiol.* 2011; 64: 80-82.
- 5 Zhou D, Pan W, Guan L, et al. Retrograde transcatheter closure of mitral paravalvular leak through a mechanical aortic valve prosthesis: 2 successful cases. *Tex Heart Inst J.* 2016; 43: 137-141.