

CLINICAL VIGNETTE

Stent delivery failure: a new indication for rotational atherectomy?

Oscar Rakotoarison¹, Wojciech Zimoch^{1,2}, Piotr Kübler^{1,2}, Michał Kosowski^{1,2}, Brunon Tomasiewicz^{1,2}, Krzysztof Reczuch^{1,2}

¹Department of Heart Diseases, Medical University of Wrocław, Wrocław, Poland

²Department of Cardiology, 4th Military Hospital in Wrocław, Wrocław, Poland

An 86-year-old patient was admitted to our centre to undergo an elective percutaneous coronary intervention (PCI) of the right coronary artery (RCA). The patient had a history of acute inferior ST-segment elevation myocardial infarction (MI) with an unsuccessful PCI of the left circumflex artery a month earlier (in a different hospital), arterial hypertension, and persistent atrial fibrillation. He was referred for PCI due to recurrence of typical angina (Canadian Cardiovascular Society class III). A coronary angiography, performed during MI, revealed three-vessel disease. The patient did not consent to coronary artery bypass grafting. A multilevel RCA lesion without heavy calcification was targeted for this stage of percutaneous treatment. The procedure was performed via the right radial artery. After RCA intubation with a 6-F Amplatz Right 2 guiding catheter (Medtronic, Minneapolis, MN, USA), a Hi-Torque Balance Middleweight Universal II guidewire (Abbott, Lake Bluff, IL, USA) was placed distally in the artery. Multiple pre-dilatations of the medial RCA (mRCA) using 2.5-mm NC Quantum Apex non-compliant balloons (Boston Scientific, Marlborough, MA, USA) were performed with full balloon expansion (Fig. 1A). However, stent delivery to the lesion was not possible (Fig. 1B). Delivery of a 2.5-mm Flextome cutting balloon (Boston Scientific) also failed. Stent delivery failure was at first managed with buddy wire technique using a Cruiser Hydro ES-HF guidewire (Biotronik, Berlin, Germany) and Hi-Torque Balance Middleweight Universal II guidewire (Abbott), but it proved ineffective. Anchoring technique was rejected owing to the likelihood of complications [1]. A Guidion guide extension catheter (IMDS, Roden, the Netherlands) also did not allow stent delivery. Given the high efficacy of this device [2], which provides very good back-up support, other potential systems, e.g. straight child catheters, mother-child [3], mother-child-grandchild methods, could needlessly extend the procedure and were abandoned. Operators considered two other ways of managing this problem: using a bigger non-compliant balloon or rotational atherectomy (rotablation). Considering our experience in rotablation and its safety, it was our procedure of choice. RotaWire Extra Support (Boston Scientific) was introduced to the distal part of the RCA via a Finecross MG microcatheter (Terumo, Tokyo, Japan) [4]. Subsequently, rotablation of the mRCA was performed using a 1.75-mm RotaLink Plus burr (Boston Scientific). Five runs at 140,000 rpm were performed, of which the last one was successful. This strategy allowed a very easy (no resistance at all) delivery and implantation of three stents: distal RCA (2.75/22-mm Orsiro [Biotronik]), mRCA (3.0/12-mm Xience ProX [Abbott]), and proximal RCA (3.5/15-mm Xience ProX [Abbott]). An optimal angiographic result was obtained, and no postprocedural complications occurred (Fig. 1C). Standard pharmacotherapy was recommended. Attempts at stent delivery with a strong back-up through calcified, narrowed lesions are frequently connected with the use of excessive force and are, in our opinion, less predictable than a fully controlled burr passage. Using additional force may put the patient at risk of damaging the polymer, drug coating, or even stent struts. Uncrossable and undilatable coronary lesions remain classic indications for rotablation. Based on the presented case, the problem of stent delivery failure, even without severe calcifications and with full expansion of non-compliant balloons during lesion preparation, may sometimes be easily solved with rotablation.

References

1. Fiocca L, Bernelli C, Sirbu V, et al. How to perform distal anchoring technique by 6F french radial approach in complex coronary procedures. *Cardiovasc Revasc Med.* 2016; 17(5): 339–343, doi: [10.1016/j.carrev.2016.02.010](https://doi.org/10.1016/j.carrev.2016.02.010), indexed in Pubmed: [27053437](https://pubmed.ncbi.nlm.nih.gov/27053437/).
2. Huang MS, Wu CI, Chang FH, et al. The efficacy and safety of using extension catheters in complex coronary interventions: a single center experience. *Acta Cardiol Sin.* 2017; 33(5): 468–476, doi: [10.6515/ACS20170523B](https://doi.org/10.6515/ACS20170523B), indexed in Pubmed: [28959098](https://pubmed.ncbi.nlm.nih.gov/28959098/).
3. Takahashi A, Taniguchi N, Yamada T, et al. The novel 4.5F CoKatte catheter for stent delivery facilitation in complex coronary artery lesions. *Cardiovasc Revasc Med.* 2014; 15(6-7): 346–349, doi: [10.1016/j.carrev.2014.08.004](https://doi.org/10.1016/j.carrev.2014.08.004), indexed in Pubmed: [25204492](https://pubmed.ncbi.nlm.nih.gov/25204492/).
4. Barbato E, Carrié D, Dardas P, et al. European expert consensus on rotational atherectomy. *EuroIntervention.* 2015; 11(1): 30–36, doi: [10.4244/EIJV1111A6](https://doi.org/10.4244/EIJV1111A6), indexed in Pubmed: [25982648](https://pubmed.ncbi.nlm.nih.gov/25982648/).

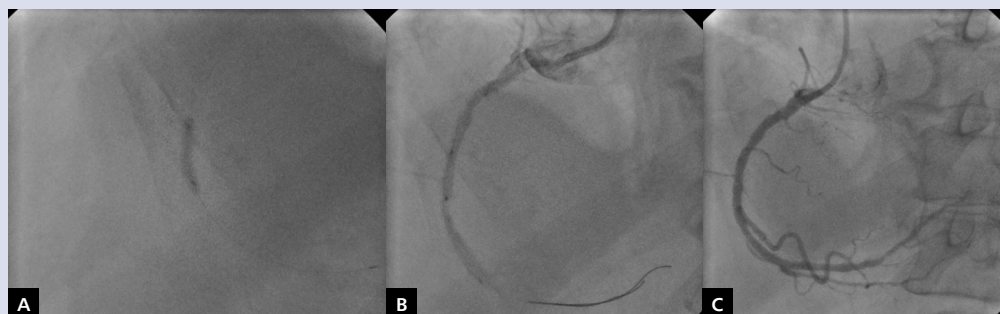


Figure 1. **A.** Fully expanded 2.5-mm non-compliant balloon; **B.** Stent delivery failure; **C.** Final result of percutaneous coronary intervention

Address for correspondence:

Oscar Rakotoarison, MD, Department of Heart Diseases, Medical University of Wrocław, ul. Weigla 5, 53–114 Wrocław, Poland, tel/fax: +48 261 660 275, e-mail: oscar.rakotoarison@gmail.com

Conflict of interest: none declared

Kardiologia Polska Copyright © Polish Cardiac Society 2018