

Is anthracycline-induced heart failure reversible?

Aneta Klotzka¹, Joanna Kufel-Grabowska², Michał Zembala³, Przemysław Mitkowski¹, Maciej Lesiak¹

¹ 1st Department of Cardiology, University of Medical Sciences, Poznań, Poland

² Chemotherapy Ward, the Greater Poland Cancer Center, Poznań, Poland

³ Department of Cardiac Surgery and Transplantology, Silesian Centre for Heart Diseases, Zabrze, Poland

A 38-year-old woman was referred to an oncologist due to multifocal left breast cancer as well as overexpression of estrogen receptor and human epidermal growth factor receptor 2 (HER2). Metastases to the axillary nodes were confirmed.

Prior to oncological treatment, left ventricular ejection fraction (LVEF) was 71%. The patient received 4 cycles of anthracycline with a total dose of 240 mg/m². The control LVEF was 60% before the administration of paclitaxel and trastuzumab. After the second trastuzumab cycle, the patient reported shortness of breath. LVEF decreased to 35%. The patient was hospitalized due to resting shortness of breath and peripheral edema. Laboratory tests showed N-terminal pro-B-type natriuretic peptide level of 15 324 pg/ml (reference value, <125 pg/ml). On echocardiography at that time, LVEF was 15% and left global ventricular longitudinal strain was 5.1% (FIGURE 1A and 1B).

Due to no improvement after a dobutamine and furosemide infusion, levosimendan was added. An improvement in the patient's condition was observed. On the third day after the end of the infusion, a significant increase in LVEF from 15% to 35% and global ventricular longitudinal strain of 14% were noted. A follow-up study showed a gradual decrease in LVEF from day 7 up to a baseline of 15% by day 10. A second infusion of levosimendan was given. On the third day after the end of the second infusion, a mastectomy was performed. The patient was discharged home after a week. After 2 months, she was hospitalized again because of heart failure (HF) exacerbation. LVEF dropped to 15%. She received a third infusion of levosimendan. The patient qualified for an implantation of a left ventricular assist device (LVAD) using the Heart Mate III system

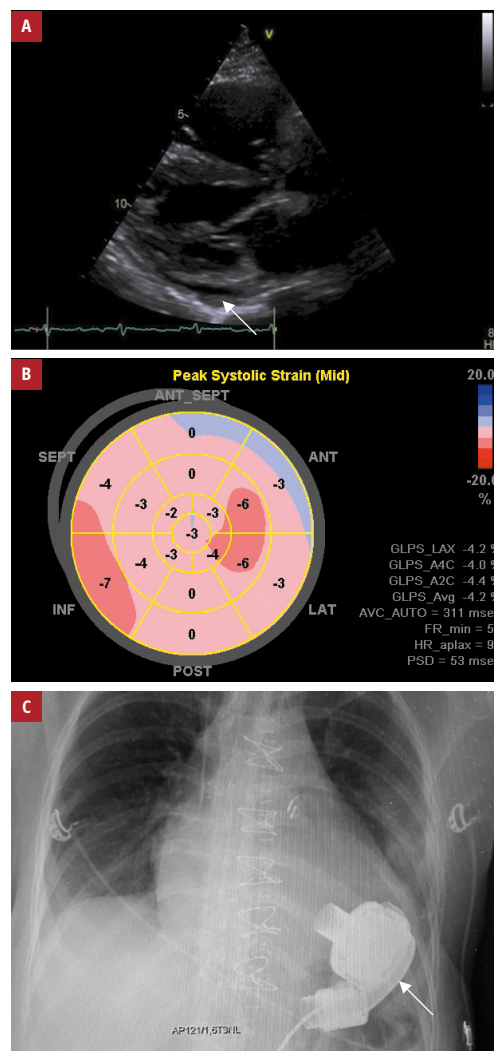


FIGURE 1 **A** – echocardiography, the parasternal view showing fluid in the pericardial sac (arrow); **B** – tissue Doppler echocardiography showing a reduced global longitudinal strain of the left ventricle; **C** – chest x-ray showing a left ventricular assist device (arrow)

Correspondence to:
Aneta Klotzka, MD,
1st Department of Cardiology,
University of Medical Sciences,
ul. Długa 1/2, 61-848 Poznań,
Poland, phone: +48 61 854 9146,
email: aneta.klotzka@skpp.edu.pl
Received: August 21, 2020.
Revision accepted:
October 1, 2020.
Published online:
October 6, 2020.
Kardiol Pol. 2020;
78 (12): 1295-1296
doi:10.33963/KP.15637
Copyright by the Author(s), 2020

(FIGURE 1C). The procedure was completed without complications. The 12-month follow-up visit showed an increase in LVEF to 50%. Currently, it is planned that the patient will discontinue the use of the device.

The prognosis of young patients with HER2-positive breast cancer with axillary lymph node metastases is usually poor, but the use of trastuzumab in combination with chemotherapy reduces the risk of recurrence by around 40%.

Anthracyclines lead to symptomatic HF in up to 10% of patients. The incidence of cardiotoxicity after the use of anthracyclines reaches 9%, and 98% of cases occur within the first year.^{1,2} The total dose of anthracyclines taken accumulates. At a dose of 400 mg/m², the risk of HF is about 5%; with a dose of 700 mg/m², it can reach up to 48%.^{3,4} Anthracycline metabolites accumulate in the myocardial cells and disturb calcium hemostasis. Levosimendan increases the contractility of the heart by rising the sensitivity of troponin C to calcium. In our case, we observed an increase in LVEF from 15% to 35%, which reduced the risk of mastectomy. There are 2 reports in the literature of a lasting improvement in left ventricular systolic function after the administration of levosimendan in patients with anthracycline-induced heart failure (ACT). This suggests that levosimendan may be an effective drug in patients with anthracycline-related HF. The question remains regarding when to administer levosimendan for ACT and how many drug doses are needed for improvement.

For the first 5 years after cancer diagnosis, a patient with HF cannot be a candidate for a heart transplant. LVAD may be a bridge for heart transplantation in patients with a good oncological prognosis.⁵ ACT is considered irreversible. Perhaps the support of the left ventricle in a short time from the introduction of a HF LVAD implantation allows myocardial regeneration.

ARTICLE INFORMATION

CONFLICT OF INTEREST None declared.

OPEN ACCESS This is an Open Access article distributed under the terms of the Creative Commons Attribution-Non Commercial-No Derivatives 4.0 International License (CC BY-NC-ND 4.0), allowing third parties to download articles and share them with others, provided the original work is properly cited, not changed in any way, distributed under the same license, and used for non-commercial purposes only. For commercial use, please contact the journal office at kardiologiapolska@ptkardio.pl.

HOW TO CITE Klotzka A, Kufel-Grabowska J, Zembala M, et al. Is anthracycline-induced heart failure reversible? *Kardiologia i Kardiologia Polska*. 2020; 78: 1295-1296. doi:10.33963/KP.15637

REFERENCES

- 1 Cardinale D, Colombo A, Bacchiani G, et al. Early detection of anthracycline cardiotoxicity and improvement with heart failure therapy. *Circulation*. 2015; 131: 1981-1988.
- 2 Anker MS, von Haehling S, Anker SD. Novel biomarkers in heart failure and cardio-oncology. *Kardiologia i Kardiologia Polska*. 2019; 77: 329-330.
- 3 Curigliano G, Mayer EL, Burstein HJ, et al. Cardiac toxicity from systemic cancer therapy: a comprehensive review. *Prog Cardiovasc Dis*. 2010; 53: 94-104.
- 4 Monsuez JJ, Charniot JC, Vignat N, et al. Cardiac side-effects of cancer chemotherapy. *Int J Cardiol*. 2010; 144: 3-15.

5 Salil V Deo, Sadeer G Al-Kindi, Guilherme H Oliveira. Management of advanced heart failure due to cancer therapy: the present role of mechanical circulatory support and cardiac transplantation. *Curr Treat Options Cardiovasc Med*. 2015; 17: 388.