

Cardiac fibroma in a neonate

Włókniak serca u noworodka

Marcin M. Gładki¹, Aleksandra Morka¹, Rafał Żurek¹, Beata Radzymińska-Chruściel², Janusz H. Skalski¹

¹Department of Paediatric Cardiosurgery, University Children's Hospital, Krakow, Poland

²Lab of Foetal Echocardiography, Medical Centre Ujastek, Poland

Cardiac tumours in children are rare; they often require immediate surgical intervention. Assertive, even aggressive, operations constitute the method of choice in the majority of cases. The author describes a female neonate (pregnancy 3, delivery 2) born by C-section at 38 weeks with a giant, extremely rare right ventricle (RV) tumour and impending cardiac tamponade. The 32-year-old mother presented

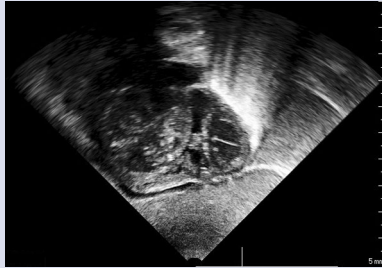


Figure 1. Transthoracic echocardiography right ventricular tumour

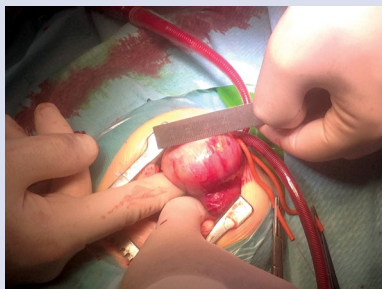


Figure 2. Right ventricular tumour

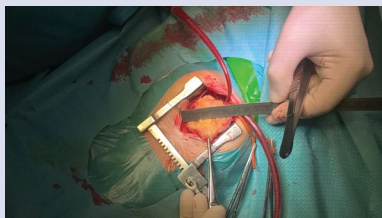


Figure 3. Intraoperative view of a cardiac fibroma

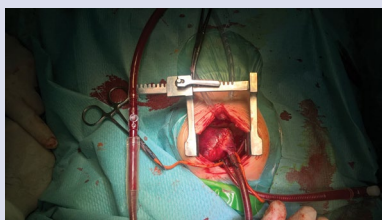

Figure 4. Cardiac fibroma after resection

with hypothyroidism and obesity. Prenatal ultrasonography at 24 weeks of gestation showed no abnormalities or structural cardiac and vascular lesions, possibly indicating an extremely dynamic tumour growth in the third trimester. On admission, physical examination showed significant dyspnoea and heart rate of 170/min. Immediately performed echocardiography demonstrated a giant tumour of the RV free wall, 20 × 30 mm in diameter, 6 cm² in surface area, which was non-encapsulated, showing no borderline between the ventricular muscle and tumour margins. The tumour mass was non-uniform, with hyper and hypoechogenic foci, significantly narrowing the RV lumen in the inflow tract, restricting the movement of the anterior and posterior tricuspid valve (TV) leaflet. TV — 5 mm opening, I/II° regurgitation with maximum RV/RA systolic gradient of approximately 22 mm Hg; left ventricle (LV) — 4 mL in volume, with normal systolic function (CiAo 2.4 L/min/m²); mitral valve — 0.97 cm; tricuspid competent aortic valve with 0.85 cm annulus; normal ostium and initial course of the coronary arteries. Pulmonary artery trunk and branches normal, no patent ductus arteriosus. Left aortic arch, normal aortic isthmus (Fig. 1). In view of the girl's state, angio-computed tomography was not performed. Following pharmacological stabilisation, she was prepared for surgery. Under cardiopulmonary bypass and deep hypothermia, subtotal tumour resection was performed involving the masses situated on the anterior cardiac wall and blocking the inflow to the TV. The post-resection margins on the anterior heart surface were approximated with continuous sutures. The resection was performed within the normal tissue limits, exercising extreme caution around the coronary circulation vessels. Tumour consistency resembled hard, cheese-like, poorly vascularised masses with numerous calcifications (Figs. 2, 3). The material was referred to histopathology, which confirmed the suspicion of fibroma. Having warmed the patient, aided by catecholamines and milrinone, cardiopulmonary by-pass was discontinued. Initially, her postoperative status was severe, with low arterial pressure requiring volaemia supplementation, levosimendan, and increased amine administration. Postoperative transthoracic echocardiography — TV diameter 6 mm, sub-TV tumour — 16 × 17 mm with non-uniform structure, restricting movement of the anterior TV cup, but showing significant inflow improvement as compared to preoperative results, decreased RV volume in the inflow tract, preserved RV trabecular outflow tract. Pulmonary valve diameter of approximately 9 mm (preserved blood outflow to the pulmonary trunk from the RV side); CiPV < 1 L/min/m²; CiAo approximately 3 L/min/m²; LV 1.6–1.7 cm; ejection fraction 70–75% (Fig. 4). In subsequent days, improvement of general status and echocardiographic picture was achieved; the latter showed regression of tumorous lesions that were non-resectable due to the risk of damaging important heart structures. She was extubated on day 10 postoperatively. Further postoperative course was uncomplicated. She is presently developing normally and is being followed-up by out-patient cardiology department. No recurrent fibroma has been seen, and tumour remnants are gradually disappearing. Assertive surgical intervention in such extremely dangerous cases is often the only correct management method.

Address for correspondence:

Marcin M. Gładki, MD, PhD, Department of Paediatric Cardiosurgery, University Children's Hospital, ul. Wielicka 265, 30-663 Kraków, Poland, tel: +48 12 658 20 11, e-mail: marcingladki@gmail.com

Conflict of interest: none declared

Kardiologia Polska Copyright © Polskie Towarzystwo Kardiologiczne 2017