

Left ventricle rupture during percutaneous coronary intervention

Pęknięcie wolnej ściany lewej komory podczas przezskórnej interwencji wieńcowej

Santiago Jesús Camacho Freire, Javier León Jiménez, Rosa Cardenal Piris, José Francisco Díaz Fernández

University Hospital Juan Ramón Jiménez, Huelva, Spain

Rupture of the free wall of the left ventricle (LV) after acute myocardial infarction (AMI) is a rare complication, with an incidence in the era of interventional cardiology of less than 1–2%. It accounts for 2–5% of hospital deaths in the context of AMI. Occurs in 50% of patients during the first five days after AMI, reaching 90% in the first two weeks. Older women, especially those with recurrent postinfarction angina, and patients with systemic hypertension more commonly experience myocardial rupture after AMI. Although transthoracic echocardiography is the urgent diagnostic technique of choice, there is rarely enough time to perform it given the rapid haemodynamic deterioration. Although only a few patients exceed the acute phase to reach the operating room, survival after surgery is over 70%. We report the case of a 79-year-old female patient with a history of hypertension and dyslipidaemia who was transferred to our unit with an evolved inferior ST segment elevation myocardial infarction (Fig. 1). Elective coronary angiography was performed 72 h later and showed a left dominant coronary tree, with a thrombotic occlusion of the mid circumflex artery (Suppl. Video 1 — see journal website). After wiring the thrombotic occlusion (white arrow in Fig. 2A, Suppl. Video 2 — see journal website) the patient suffered a sudden haemodynamic deterioration followed by electromechanical dissociation and cardiac arrest. Whereas the aortography ruled out acute aortic syndrome, (Suppl. Video 3 — see journal website) the ventriculography showed a significant pericardial effusion (white arrow in Fig. 2B, Suppl. Video 4 — see journal website) secondary to in-situ LV free wall rupture at inferoapical level (blue arrow in Fig. 2C, Suppl. Video 5 — see journal website). Despite advanced cardiopulmonary resuscitation and emergency pericardiocentesis, the patient eventually died. Diagnosis of free wall rupture is strongly suspected when a patient with a high-risk profile — age > 55 years, first transmural acute myocardial infarct, absence of overt heart failure, persistent ST segment elevation, prolonged pain during the acute phase — presents with sudden hypotension or electromechanical dissociation, often preceded by recurrence of chest pain, together with raised jugular venous pressure and a moderate-to-severe pericardial effusion on echocardiography/angiography. To avoid semantic confusion, it is proposed that the term “acute free wall rupture” be reserved for patients with cardiac arrest caused by electromechanical dissociation or severe hypotension. When cardiac arrest has occurred, management includes cardiac massage, ventilatory support, administration of inotropic agents and colloids, and pericardiocentesis. If improvement occurs, conservative management is then continued in close consultation with the surgical team. If initial management does not result in improvement, emergency thoracotomy is performed, preferably without cardiopulmonary bypass, and the rupture site is repaired with a Teflon patch glued to the epicardium. To the best of our knowledge, this is the first reported case, angiographically recorded, of LV rupture during percutaneous coronary intervention. Unfortunately, the patient eventually died.

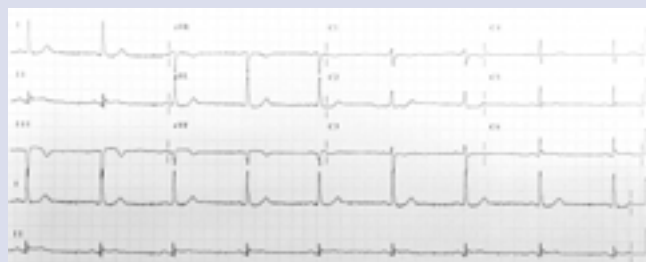


Figure 1. Electrocardiogram showing an evolved infero-posterior ST segment elevation myocardial infarction

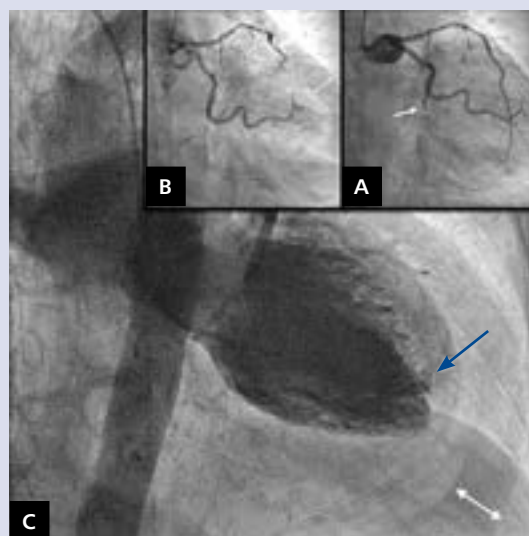


Figure 2. **A.** After wiring the thrombotic occlusion (white arrow); **B.** A significant pericardial effusion appears (white arrow); **C.** Ventriculography showing left ventricle free wall rupture at inferoapical level (blue arrow)

Address for correspondence:

Santiago Jesús Camacho Freire, MD, Interventional Cardiologist Department, University Hospital Juan Ramón Jiménez, ronda exterior norte s/n. ZC: 21005, Huelva, Spain, e-mail: navallana@hotmail.com

Conflict of interest: none declared

Kardiologia Polska Copyright © Polskie Towarzystwo Kardiologiczne 2016