

Emergency echocardiography to guide therapy in a patient with Takotsubo cardiomyopathy complicated with dynamic left ventricular outflow tract obstruction

Rola przyłózkowej echokardiografii w diagnostyce i leczeniu pacjenta z kardiomiopatią Takotsubo z dynamicznym zawężaniem drogi odpływu lewej komory

Radosław Nowak^{1,2}, Miłosz Jaguszewski^{1,3}, Aleksander Włodarczyk^{1,4}, Witold Dubaniewicz², Radosław Targoński²

¹1st Department of Cardiology, Medical University of Gdansk, Gdansk, Poland

²Pomeranian Cardiology Centre, Gdansk, Poland

³Department of Cardiology, Charité-Universitaetsmedizin Berlin, Campus Benjamin Franklin, Berlin, Germany

⁴Department of Cardiology, Voivodeship Specialist Hospital No. 4, Bytom, Poland

A 76-year-old woman with no previous cardiovascular history was admitted to an emergency setting with suspicion of ST-segment elevation acute myocardial infarction. She was suffering from retrosternal chest pain and dyspnoea just after a family quarrel. Clinical examination revealed a heart rate of 80 bpm, blood pressure of 110/50 mm Hg, and systolic murmur grade 4 in the Levine grading scale, with no signs of pulmonary congestion, peripheral oedema, or hepatomegaly. Electrocardiogram documented ST-segment elevation in precordial leads V_2 – V_6 and lead I (Fig. 1A), and highly sensitive troponin T level was significantly elevated (1.3 ng/mL). Urgent coronary angiography was performed and demonstrated TIMI II grade flow in the left anterior descending artery, with no obstructive coronary artery disease or angiographic evidence of acute plaque rupture (Fig. 1B, C). An echocardiogram performed immediately after heart catheterisation revealed ellipsoidal asymmetric hypertrophy of the basal septum, apical ballooning, hyperkinesia of basal segments with left ventricular ejection fraction of 37%, and pronounced systolic anterior motion (SAM) (Fig. 1D, arrow) of both mitral leaflets causing mild mitral regurgitation (MR) and dynamic left ventricular outflow tract obstruction (LVOTO). The maximal velocity was 5.6 m/s and maximal peak gradient was 126 mm Hg (Fig. 1E). Based on the clinical and echocardiographic findings, therapy with bisoprolol 2.5 mg and intravenous fluid infusion was carefully initiated. Control echocardiography five days later showed hypokinesia of previously akinetic segments, normokinesia of basal segments, and no signs of SAM and dynamic LVOTO. The patient was discharged home with no cardiac symptoms, with the diagnosis of typical variant of Takotsubo cardiomyopathy (TTC). TTC is a reversible cardiomyopathy, usually affecting postmenopausal women with clinical presentation mimicking acute coronary syndrome. Since up to 10% of patients develop severe complications, despite the favourable long-term prognosis, TTC remains a life-threatening disease in the acute phase. We present a case of a woman with TTC complicated by acute SAM with mild MR and dynamic, severe LVOTO. Elderly women, with relatively small left ventricle cavity and septal bulge, are more likely to develop such complications. In patients with LVOTO continuous infusion of catecholamines or excessive diuretic therapy can increase the intraventricular pressure gradient that leads to further haemodynamic compromise and is thus not recommended. In such a clinical scenario careful intravenous fluid therapy, as well as use of intra-aortic balloon pump, should be considered. In patients without circulatory compromise with concomitant LVOTO, beta-blocker therapy is strongly recommended. However, the efficacy and safety of such treatment should be evaluated in further studies. This case highlights the role of immediate bedside echocardiography in a patient with TTC and systolic murmur, to guide immediate treatment strategy.

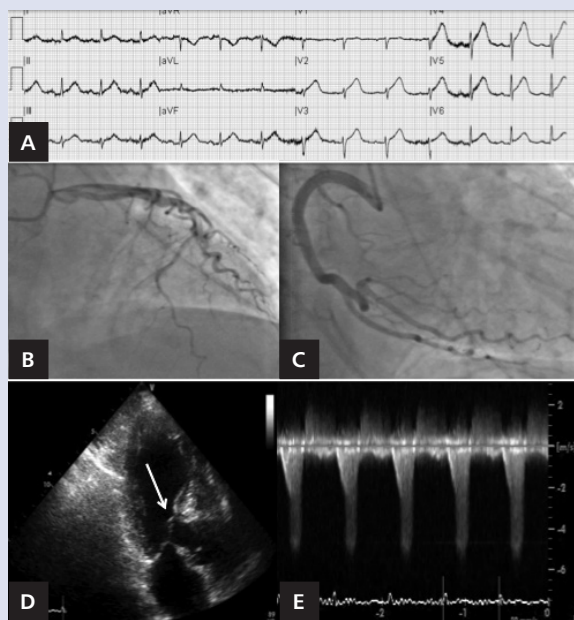


Figure 1. A. ST-segment elevation in precordial leads V_2 – V_6 and lead I. B, C. Coronary angiography with no obstructive coronary artery disease. D, E. Asymmetric hypertrophy of the basal septum, apical ballooning, pronounced SAM (D, arrow) and dynamic LVOTO (E)

Address for correspondence:

Witold Dubaniewicz, MD, PhD, Pomeranian Cardiology Centre, ul. Balewskiego 1, 83–200 Starogard Gdański, Poland, e-mail: w.dubaniewicz@centra-kardiologiczne.pl

Conflict of interest: none declared