

Renal artery atherosclerotic plaque ruptures visualised with intravascular ultrasound

Pęknięte blaszki miażdżycowe w tętnicach nerkowych zobrazowane za pomocą ultrasonografii wewnątrznaczyniowej

Sebastian Bujak¹, Łukasz Kalińczuk¹, Piotr N. Rudziński¹, Adam Witkowski², Marcin Demkow¹

¹Department of Coronary and Structural Heart Diseases, Institute of Cardiology, Warsaw, Poland

²Department of Interventional Cardiology and Angiology, Institute of Cardiology, Warsaw, Poland

Renal angiography frequently yields indeterminate results (particularly in aneurysms), that in coronaries were found to be plaque rupture sites. In this setting, use of intravascular ultrasound (IVUS) allows unique insights into actual lesion anatomy. We present three cases with striking in-vivo IVUS visualisation of renal artery atherosclerotic plaque rupture. Panels A, B, and C show three distinct angiograms with a 6 Fr guiding catheter positioned outside the renal artery ostium. Below each angiogram there are corresponding IVUS images (# — IVUS transducer). Panel A shows concentric narrowing of the proximal right renal artery. Panels A1–A3 present plaque rupture (a) with the evacuated cavity (b), the residual fibrous cap fragments (c), and the true vessel lumen (d). In Panel B there is concentric narrowing of the proximal right renal artery. Panels B1 and B2 show plaque rupture (a), evacuated cavity (b), and residual fibrous cap (c). Right renal angiogram presented in Panel C shows a tight ostial stenosis and moderate post-stenotic dilatation. IVUS images recorded from the distal (C1) to the proximal (C3) show a lateral tear in the fibrous cap (a), the residual fibrous cup fragments (b), the true lumen (c), and the false lumen (d). Note the thrombus that originates in the cavity of the rupture (*) and continues proximally. It was believed that renal artery disease exhibits a different pattern than that observed in coronaries and led mainly to calcium deposition rather than development of a vulnerable atherosclerotic plaque with necrotic core. Furthermore, stable plaque phenotype (pathological intimal thickening) was postulated to be predominant in renal artery disease with only a few consecutive cases of ruptured plaques (6%). However, these three in vivo IVUS studies document that renal artery plaque rupture might be characterised by the same underlying mechanism related to vascular vulnerability as seen in acute coronary syndromes. Although clinical significance of this phenomenon is unknown yet, the presence of ruptured plaque in renal arteries may correlate with ensuing cardiovascular events.

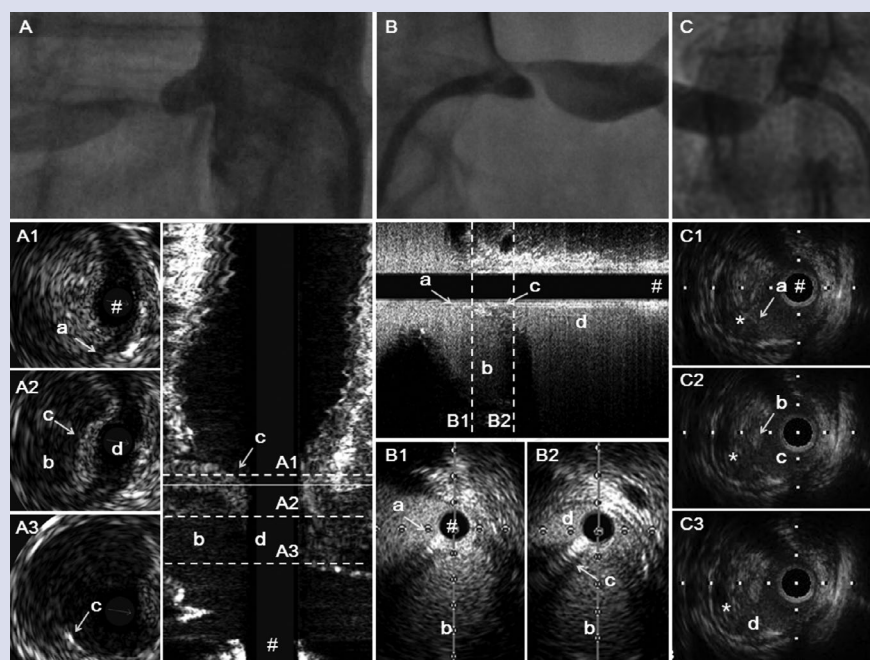


Figure 1. Angiograms of renal arteries and corresponding intravascular ultrasound images

Address for correspondence:

Sebastian Bujak, MD, Department of Coronary and Structural Heart Diseases, Institute of Cardiology, ul. Alpejska 42, 04–628 Warszawa, Poland, tel: +48 505 956 986, fax: +48 22 34 34 516, e-mail: sbujak@ikard.pl

Conflict of interest: none declared