

Patient with advanced coronary artery disease and psoriasis

Pacjent z zaawansowaną chorobą wieńcową i łuszczycą

Anna Wolska-Bułach¹, Lucyna Woźnicka-Leśkiewicz¹, Arkadiusz Niklas¹, Karolina Niklas², Andrzej Tykarski¹

¹Department of Hypertensiology, Angiology, and Internal Diseases, Poznan University of Medical Sciences, Poznan, Poland

²Department of Rheumatology and Internal Medicine, Poznan University of Medical Sciences, Poznan, Poland

A 67-year-old patient was admitted to the hospital due to the retrosternal pain appearing during moderately physical activity. An interview revealed the following: symptomatic angina pectoris, hypertension, diabetes type 2, and psoriasis with psoriatic arthritis for several years (Fig. 1). Laboratory results showed the following: elevated C-reactive protein, total cholesterol, and glycated haemoglobin. Electrocardiogram revealed the following: regular sinus rhythm, 68/min. Echocardiography: enlargement of the left ventricle with hypokinesis of the basal segment of the inferior wall and the septum, and ejection fraction 60%. Coronary angiography revealed the following: left main artery: minor changes; left anterior descending artery (LAD): aneurysmal extended, distally closed (Fig. 2), diagonal branch: closed; left circumflex artery: aneurysmal extended; 90% narrowing in first marginal branch (Fig. 3); right coronary artery: dominant, wide, 90% distally narrowing (Fig. 4); and posterior descending artery: closed. After the heart team consultation, the changes in coronary arteries were treated conservatively. Doppler ultrasound showed unobstructed both carotid arteries and intima-media thickness of 0.6 mm. An inflammatory process and hyperlipidaemia play roles in the development of atherosclerosis. Psoriasis is a chronic inflammatory disease that belongs to the dermatosis group. Its aetiology includes: genetic factors, vascular changes, and immunological phenomena, as well as environmental factors. The pathophysiology is associated with the inflammatory pathway response of cytokines released by Th1 and Th17 lymphocytes. Patients with psoriasis have increased risk of coronary artery disease (CAD); in this group the probability of myocardial infarction is significantly increased. Moreover, in coronary angiography up to 84% of patients had atherosclerotic lesions vs. 75% observed in the control group. Atherosclerotic lesions in LAD were observed more frequently compared with the general population, and their intensity correlated with the duration of the psoriasis. The inflammatory process is the connecting element between these two diseases. In the pathogenesis of psoriasis one of the main roles is played by the immune processes with the cascade of cytokines released by Th1 and Th17 lymphocytes (TNF- α , IFN- γ , IL-17, IL-12, IL-2, and IL-23). The activation of Th1 and its mediators (INF- γ , TNF- α , IL-1, IL-12, and IL-18) play a role in the pathogenesis of atherosclerosis. IL-12 and IFN- γ are the elements connecting these diseases. European Society of Cardiology guidelines list psoriasis as an independent risk factor for CAD. A key role is attributed to the immune process, especially T-helper response. Patients with concomitant psoriasis and CAD represent an uncommon and complicated group of patients who require significant cardiovascular prevention. It is also worth noting that such patients are good candidates for omega-3 fatty acids supplementation, which is known for both cardiovascular prevention and improvement of psoriasis symptoms.

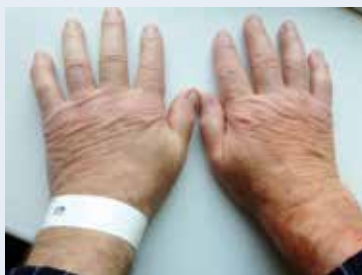

Figure 1. Psoriasis in the joints and nails of both hands

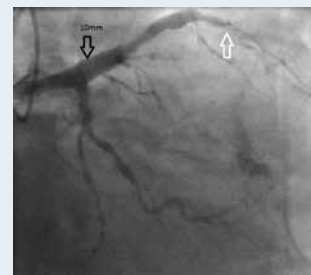


Figure 2. Left anterior descending artery — aneurysmal extended (black arrow), distally closed (white arrow)

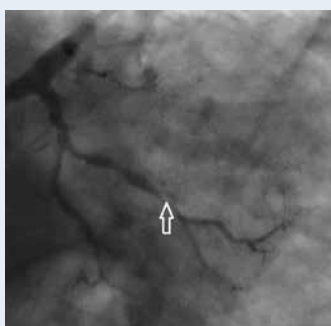


Figure 3. Left circumflex artery — narrowing in first marginal branch (arrow)

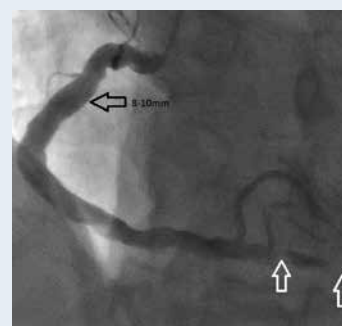


Figure 4. Dominant right coronary artery (black arrow), distally narrowing (white arrows)

Address for correspondence:

Anna Wolska-Bułach, MD, PhD, Department of Hypertension, Angiology, and Internal Medicine, Poznan University of Medical Sciences, ul. Długa 1/2, 61-848 Poznań, Poland, e-mail: annawolskabulach@gmail.com

Conflict of interest: none declared