

Complex interventional treatment in a patient with cardiogenic stroke

Kompleksowe leczenie interwencyjne u pacjenta z kardiogennym udarem mózgu

Anetta Lasek-Bal¹, Tomasz Urbanek², Jacek Kostyra², Damian Ziaja², Krzysztof Ziaja²

¹Department of Neurology, Medical University of Silesia, Medical Centre of Upper Silesia, Katowice, Poland

²Department of Surgery, Vascular Surgery, and Angiology, Medical University of Silesia, Medical Centre of Upper Silesia, Katowice, Poland

A 78-year-old patient was admitted to the Neurology Department due to sudden left limb weakness approximately 10 h earlier. The patient's history revealed hypertension, atrial fibrillation (AF), diabetes, and myocardial infarction (MI) 9 years earlier. Examination showed left-sided slight paresis (4/5 on the Lovett scale). Electrocardiogram recorded AF with ventricular action of 60 bpm. The computed tomography (CT) of the head showed no acute lesions, but ultrasound and angio-CT presented right-sided tandem stenosis of the internal carotid artery (ICA) with acute thrombus constricting the lumen by approximately 60%, and of the proximal middle cerebral artery section. The diagnosis related to stroke resulting from cardiogenic embolism, so heparin was administered. Left limb paresis abruptly worsened in the 20th h after onset (3/5 Lovett), and head CT revealed an ischaemic lesion in the right hemisphere; ultrasound/angio-CT confirmed ICA stenosis progression by 90% (Fig. 1A). Due to an unstable neurological state, the nature of the stenotic lesions, and ineffective current therapy, intra-arterial thrombolysis was performed with a catheter inserted into the common carotid artery, resulting in rapid neurological improvement but with still present ICA thrombosis refractory to thrombolytic treatment (Fig. 1B). Due to unstable lesions at the stenotic site (arteriography revealed segmental thrombosis), the patient was qualified for urgent surgical thromboendarterectomy — intraoperatively arterial embolism was recognised and embolectomy of proximal ICA was performed (Fig. 2). Only minor atherosclerotic plaques were found at the embolic site. Neurological examination on the day of discharge revealed discrete left limb weakness. As a secondary prevention rivaroxaban was administered. Treatment options for acute ischaemic stroke depend on the dynamics of the neurological changes, stroke aetiology, and angiographic/neuroimaging results. As per current recommendations, reperfusion methods are primarily considered. As in MI management, the benefits of reperfusion in stroke are time-limited. MI is usually caused by plaque rupture and thrombosis in situ (soft acute clot sensitive to recombinant tissue plasminogen activator [rt-PA]); however, stroke results from cardiogenic or arterio-arterial embolism, which is not easily subjected to drug action. Cardiogenic emboli are large and often form 'hard' fibrous lesions, and the chance of post-thrombolytic recanalisation of an artery with cardiogenic embolism > 8 mm² is small. With critically narrowed/closed, carotid artery complete recanalisation after rt-PA is observed in 10% of patients, while the clinical effect of additional intracranial section recanalisation is then transitory. Here, intra-arterial thrombolysis resulted in the patient's rapid neurological improvement and slight carotid artery recanalisation, which posed a risk of recurrent stroke. Embolectomy of the ICA was performed to remove the embolic material and prevent the ischaemia recurrence. In conclusion, surgical embolectomy may be considered as adjunctive therapy in selected patients with cardio-embolic stroke treated with intra-arterial thrombolysis.

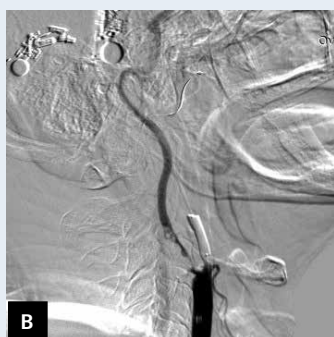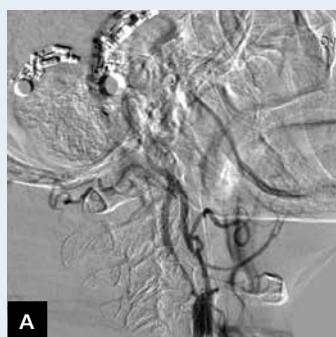


Figure 1. Left internal carotid artery before (A) and after (B) intra-arterial thrombolysis

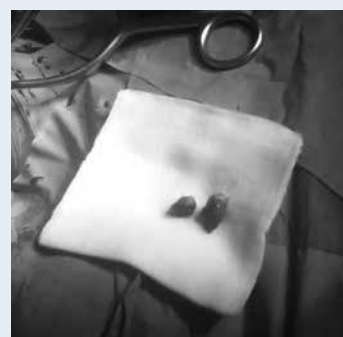

Figure 2. The embolism removed during carotid endarterectomy

Address for correspondence:

Anetta Lasek-Bal, MD, PhD, Department of Neurology, Medical University of Silesia, Medical Centre of Upper Silesia, ul. Ziołowa 45/47, 40-735 Katowice, Poland, e-mail: alasek@gcm.pl

Conflict of interest: none declared