

Subacute thrombosis after primary percutaneous coronary intervention with bioresorbable vascular scaffold implantation

Podostra zakrzepica w stencie po pierwotnej przezskórnej interwencji wieńcowej z implantacją stentu bioresorbowalnego

Mariusz Tomaniak, Janusz Kochman, Łukasz Kołtowski, Arkadiusz Pietrasik, Adam Rdzanek

1st Department of Cardiology, Medical University of Warsaw, Warsaw, Poland

Everolimus-eluting bioresorbable vascular scaffold (BVS) is a promising new technology recently applied in the treatment of coronary artery lesions that might overcome the limitations of the currently used drug eluting stents. There were no scaffold thromboses reported in the first-in-human trials with BVS implantation. However, the current body of evidence on its safety and incidence of early thrombotic complications in the setting of acute coronary syndromes is still limited. We present the case of a 58-year-old male who was admitted to a coronary care unit due to typical (two-hour long) chest pain with electrocardiographic signs of anterior wall ST segment-elevation myocardial infarction. Coronary angiography revealed

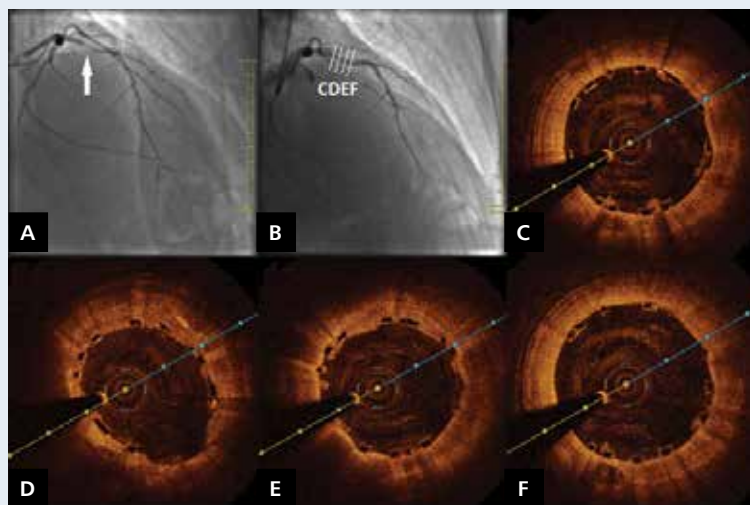


Figure 1. **A.** Coronary angiography revealing critical stenosis of the proximal left anterior descending artery (arrow); **B.** Good angiographic result of primary angioplasty with bioresorbable vascular scaffold implantation (TIMI 3); **C–F.** Good scaffold expansion and complete strut apposition in optical coherence tomography

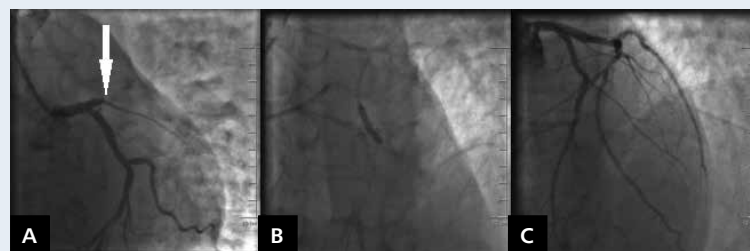


Figure 2. **A.** Occlusion of the proximal left anterior descending artery in the place of bioresorbable vascular scaffold implantation (arrow); **B.** Plain old balloon angioplasty performed in the occluded left anterior descending artery; **C.** Good final angiographic result of the treatment of scaffold thrombosis (TIMI 3)

critical stenosis of the proximal left anterior descending artery (Fig. 1A). Subsequent primary angioplasty with manual aspiration thrombectomy, balloon predilatation, and implantation of BVS (ABSORB, 3.5/28 mm, 12 atm.) was performed, with good angiographic result (TIMI 3 flow) (Fig. 1B). Optical coherence tomography (OCT) confirmed good scaffold expansion and complete strut apposition (Fig. 1C–F). Further in-hospital course was uneventful and the patient was discharged after five days of hospitalisation. On the ninth day after BVS implantation he presented again with acute severe chest pain and anterior ST-segment elevation in electrocardiogram. The patient confirmed that he discontinued both antiplatelet drugs (aspirin and clopidogrel) after discharge. Repeat coronary angiography revealed a subacute scaffold thrombosis (Fig. 2A). Manual aspiration thrombectomy, abciximab infusion, and plain old balloon angioplasty was performed (Fig. 2B), with good final angiographic result (TIMI 3) (Fig. 2C). Echocardiography revealed an impaired left ventricular ejection fraction of 38%, compared to 50% directly after the primary index procedure. As there was appropriate scaffold expansion and strut apposition in OCT directly after the index procedure, the most likely cause of scaffold thrombosis was the cessation of antiplatelet therapy.

Address for correspondence:

Mariusz Tomaniak, MD, 1st Department of Cardiology, Medical University of Warsaw, ul. Żwirki i Wigury 61, 02–091 Warszawa, Poland, tel: +48 22 599 19 51, fax: +48 22 599 19 57, e-mail: mariusz.tomaniak@interia.pl

Conflict of interest: none declared