

Extensive pericardial fat tissue mimicking paracardiac mass

Duże nagromadzenie osierdziejowej tkanki tłuszczowej imitujące masę przysercową

Ahmet Göktug Ertem¹, Mehmet Erdogan¹, Cemal Köseoğlu¹, Tahir Durmaz², Engin Bozkurt²

¹Department of Cardiology, Ataturk Training and Research Hospital, Ankara, Turkey

²Department of Cardiology, Yildirim Beyazit University, Ankara, Turkey

Epicardial adipose tissue has been recognised as a risk factor for the occurrence of cardiovascular disease. A 69-year-old woman was admitted to the outpatient cardiology clinic with dyspnoea. Before cardiological evaluation, she had been evaluated by the chest department for the same condition. During their evaluation, computed tomography revealed cardiomegaly and a hypodense area surrounding the heart (adipose tissue?) (Fig. 1A). She had a history of hypertension. On physical examination, there were no audible murmurs, rales or rhonci, and her blood pressure was 120/80 mm Hg. Laboratory test results were all within normal limits (LDL cholesterol: 125 mg/dL, creatinine: 0.85 mg/dL, and haemoglobin: 13.2 g/dL). Echocardiography showed left ventricular ejection fraction of 65%, diastolic dysfunction (E/A < 1, e': 5.07 cm/s, E/e': 15.4, mitral propagation velocity: 52 ms), and echogenic area in the neighbourhood of all heart chambers (lipoma or liposarcoma or epicardial fat tissue) (Fig. 1B). For further evaluation, cardiac magnetic resonance imaging (CMRI) was performed. This revealed the appearance of fatty tissue that surrounds the heart (widest thickness 9.6 mm) and localised pericardial thickness upon the lateral wall of left ventricle (thickness: 5.8 cm) (Fig. 1C). Contrast CMRI did not show any contrast enhancement, and thus liposarcoma was excluded (Fig. 1D).

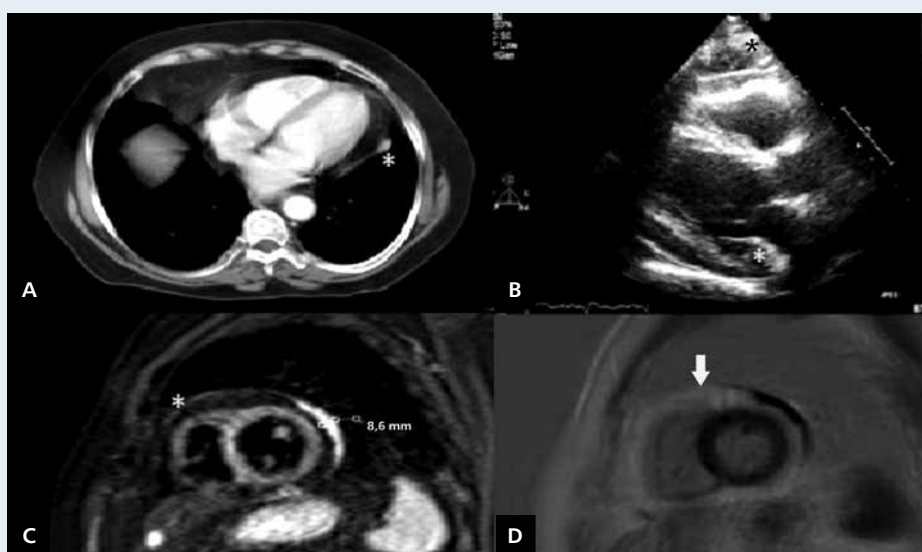


Figure 1. **A.** Computed tomography revealed cardiomegaly and hypodense area surrounding the heart (asterisk: adipose tissue); **B.** Echocardiography showed echogenic area in the neighbourhood of all heart chambers (asterisk: adipose tissue); **C.** T2 fat suppressed short axis imaging showed epicardial fat tissue (asterisk) and localised pericardial thickness upon the lateral wall of left ventricle; **D.** The lack of contrast enhancement in contrast and PSIR short axis cardiac magnetic resonance imaging; arrow — epicardial adipose tissue

Address for correspondence:

Dr Ahmet Göktug Ertem, Department of Cardiology, Ataturk Training and Research Hospital, 06946 Ankara Turkey, e-mail: agertem@hotmail.com

Conflict of interest: none declared