

Patent ductus arteriosus and an accessory structure in left ventricular outflow tract in a 68-year-old woman

Przetrwwały przewód tętniczy i dodatkowa struktura w drodze odpływu lewej komory u 68-letniej kobiety

Błażej Kusz, Joanna Wieczorek, Adrianna Berger-Kuczka, Michał Lelek, Katarzyna Mizia-Stec

1st Department of Cardiology, Medical University of Silesia, Katowice, Poland

Patent ductus arteriosus (PDA) is a well-known congenital disorder diagnosed mainly in children. In the case of a small shunt, the course of the defect can be asymptomatic for a long time and diagnosis significantly delayed. We present the case of a 68-year-old patient who was admitted to the Department of Cardiology with complaints of gradually worsening symptoms of heart failure (NYHA II) and cardiac chest pain of two years' duration. Her family history was negative. She denied smoking and alcohol consumption. Her physical examination did not reveal any specific findings except a systolic murmur heard best over the Erb point with a faint diastolic murmur in this localisation. Biochemistry panel was within normal reference limits. Electrocardiography revealed sinus rhythm (72 bpm), normal cardiac axis, high T waves in leads V_2 - V_5 and rS pattern in lead III. Transthoracic echocardiography (TTE) revealed PDA — parasternal short axis view showed the colour Doppler flow from the aorta to the pulmonary artery (PA) directed into the pulmonary valve (Fig. 1). Main PA diameter was 29 mm. In addition, mild enlargement of the left ventricle (LV; EDD 60 mm, ESD 40 mm) with global LV hypokinesis and ejection fraction of 50%, as well as left atrial dilatation (LA area 25 cm²) were observed. These changes coexisted with moderate mitral and tricuspid regurgitation. Further diagnostics included a computed tomography (CT) angiography (Figs. 2, 3) — PDA was assessed for 3.5 mm width and 5.6 mm length. Aortic calcifications were found at the level of pathology. There was no aortic coarctation. Since TTE raised doubts about an accessory structure in LV outflow tract (LVOT) (Fig. 4), we decided to perform transoesophageal echocardiography (TEE). 3D echocardiography imaging was also very helpful, as it allowed us to determine the character of the lesion — an equivocal structure turned out to be a stretched chorda tendinea located centrally in LVOT (Figs. 5, 6), 10 mm from the annulus, which did not cause any outflow obstruction. Coronary angiography did not reveal any significant stenosis. After outcomes analysis, she was qualified for percutaneous closure of PDA using a PDA II 6 × 6 mm Occluder, with good results.

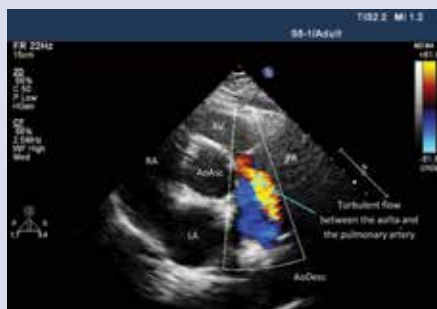

Figure 1. TTE, Doppler echocardiography

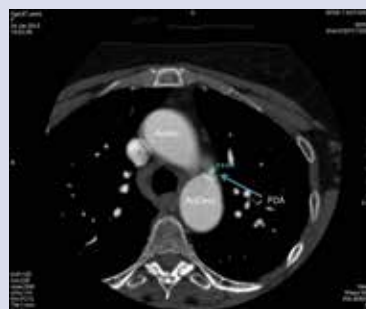


Figure 2. CT, assessment of the PDA

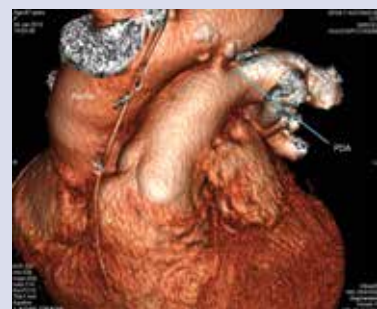

Figure 3. CT, image reconstruction

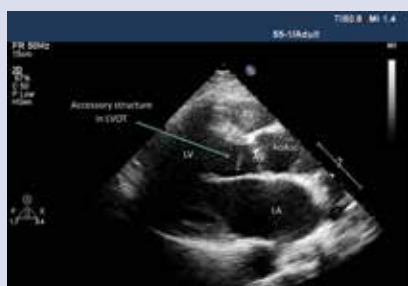

Figure 4. TTE, parasternal long axis view

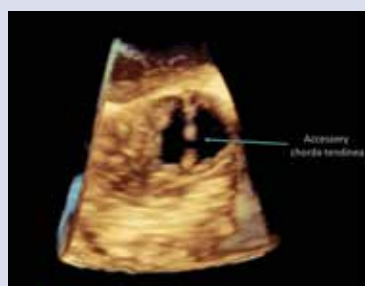

Figure 5. 3D TEE, view from the left ventricle

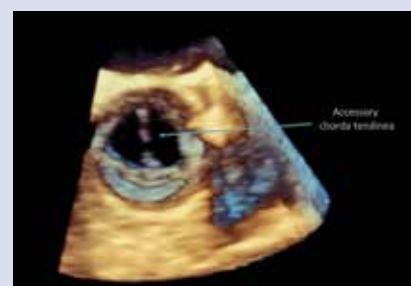

Figure 6. 3D TEE, view from the ascending aorta

Address for correspondence:

Błażej Kusz, 1st Department of Cardiology, Medical University of Silesia, ul. Ziołowa 45/47, 40-635 Katowice, Poland, e-mail: kuszblazej@gmail.com

Conflict of interest: none declared